

Study on the Sex Identification using Maxillary Sinus in Northern IndiaShamim Raza¹, Piyush Kumar Gangwar², Amrendra Kumar³¹Assistant Professor, Department of Forensic Medicine, Hind Institute of Medical Sciences Mau, Ataria, Sitapur, Uttar Pradesh, India²Assistant Professor, Department of Forensic Medicine, G.S.V.M Medical College, Kanpur, Uttar Pradesh³Assistant Professor, Department of Forensic Medicine, GMC, Azamgarh, Uttar Pradesh

Received: 05-09-2023 / Revised: 30-09-2023 / Accepted: 15-10-2023

Corresponding author: Dr. Piyush Kumar Gangwar

Conflict of interest: Nil

Abstract:

Introduction: In forensic identification, the pelvis, skull, and maxillary sinuses are used to determine sex. The comprehensive musculoskeletal imaging of “cone beam computed tomography (CBCT)” is helpful in forensic research. Post-mortem radiograph comparisons are used for radiological identification when DNA or fingerprints are unavailable. Radiological evaluation of maxillary sinus size helps determine gender in forensic anthropology and human remains because human maxillary sinuses show sexual dimorphism.

Aims and objectives: The objective of this research is to examine the efficacy of maxillary sinus features in Northern India as a means of determining the sex of individuals.

Methods: The cross-sectional observational study was conducted from June, 2022 to May, 2023. 70 Northern Indian non-pathological headache patients (40 male and 30 female) were examined. The right and left maxillary sinus height, depth, and breadth were measured using SYNGO software. Calculated maxillary sinus volumes. Descriptive statistics showed male and female measures, while t-tests or ANOVA estimated gender differences. We followed ethical guidelines and acquired patient permission for ethical research.

Results: Table 1 compares male and female right maxillary sinuses using Mann-Whitney U-tests. Male sinuses are higher, longer, broader, and larger than female ones. Table 2 mimics left maxillary sinus outcomes. Figures 1 and 2 show the major variations in height, length, and breadth in the right and left maxillary sinuses between men and women. It shows sexual dimorphism in maxillary sinus diameters.

Conclusion: The research shows gender-specific maxillary sinus characteristics for forensic identification. Sexual dimorphism is helped by maxillary sinus measures, notably right sinus volume. CT imaging properly measures these dimensions, improving forensic investigations.

Keywords: Maxillary sinuses, “deoxyribonucleic acid (DNA)”, fingerprints.

This is an Open Access article that uses a funding model which does not charge readers or their institutions for access and distributed under the terms of the Creative Commons Attribution License (<http://creativecommons.org/licenses/by/4.0>) and the Budapest Open Access Initiative (<http://www.budapestopenaccessinitiative.org/read>), which permit unrestricted use, distribution, and reproduction in any medium, provided original work is properly credited.

Introduction

Sex determination is a crucial factor in the field of forensic identification. The primary objective of medico-legal examination is to identify the gender of injured and mutilated deceased corpses or skeletal remains. The process of correlating distinct characteristics observed in deceased individuals with information documented during their lifetime is a crucial component in the field of forensics. This can be accomplished through various techniques such as the analysis of fingerprints, the analysis of “deoxyribonucleic acid (DNA)” matching, radiological methods, anthropological methods, and other approaches that aid in determining sex and age [1,2,3].

The determination of gender is accomplished by examining several anatomical structures, including long bones having an epiphysis & a metaphysis in

the skull, a foramen magnum, and skeletal remains, the pelvis, paranasal sinuses, and the mastoid process. In instances of explosions, conflicts, as well as other catastrophic events such as aeroplane crashes, it has been seen that the skull and other skeletal structures undergo severe disfigurement. Regrettably, the bones in question have been retrieved in a fragmented condition, hence posing challenges in determining the gender [4,5]. However, it has been shown that the maxillary sinuses exhibit notable resilience and tend to remain structurally intact. Maxillary sinuses [MS] are frequently the sole instances of denser bones that are commonly retrieved in a complete state. The dimensions of MS anatomy exhibit inter-individual variability and can even vary within the same individual, particularly in relation to age. The presence of this variant plays a crucial role in

determining gender. CBCT, or cone beam computed tomography, is frequently recognised as the best imaging technique modality in forensic research due to its ability to provide exact anatomical information about the musculoskeletal (MS) system. This makes it a great tool for forensic investigations [6,7].

The determination of the identity of human remains holds significant importance in contemporary society due to its crucial role in legal and ethical contexts. The process of ascertaining the identity of unidentified deceased individuals frequently commences prior to establishing the cause of their demise. The examination of sexual dimorphism in human beings holds significance in elucidating human evolutionary history and assessing the biological diversity of both historical and contemporary populations. Additionally, it proves valuable in accurately determining the sex of individuals for forensic anthropology applications [8-10].

Two sets of air-filled chambers called the sinuses of the upper jaw are situated inside the maxillary bone, exhibiting a range of sizes and shapes. The walls of their dwelling exhibit a need for more substantial thickness. The superior aspect of the sinuses has the potential to protrude and may enter the zygomatic process & inhabit the zygomatic bone. The elevation or perforation of the sinuses' floor can be caused by the root system of the canines, the initial three molars, and the alveolar process. [11,12].

The utilization of radiological identification holds significant importance within the field of forensic medicine, particularly when there is a lack of available comparable DNA samples and fingerprints. The determination relies on the comparative analysis of post-mortem radiographs, primarily obtained for clinical purposes, with post-mortem radiographs conducted to identify objectives [13].

Different radiological techniques, including traditional and digital radiography, were both used to measure the maxillary sinus's size. CT, or computed tomography is a highly effective modality for the evaluation of the maxillary sinus, offering comprehensive three-dimensional imaging capabilities. Sex determination can be achieved through the utilization of either morphological or metric approaches [14,15].

Sinus radiography has been employed for the purpose of ascertaining the identity of human remains, as well as for determining both ancestry and gender. The evaluation of the paranasal sinuses is done using a very effective imaging technique called a computed tomography (CT) scan. The evaluation offered provides an accurate assessment regarding the cranial bones, paranasal sinuses, or the level of pneumatization. in the sinuses. The technique offers comprehensive and intricate data

that is not readily obtainable using conventional radiographic methods. The utilization of computed tomography (CT) scans to assess the maxillary sinus measurements has shown to be a useful tool in aiding the process of gender determination [16,17].

Sexual dimorphism pertains to the inherent disparity in physical characteristics, encompassing variations of individuals of different sexes within a species that will have differences in form or size. Sexual dimorphism has been observed in the maxillary sinuses of several species. In current human societies, it has been shown the difference between genders in the size of their maxillary sinus [18,19].

Method

Research Design

The research strategy used in this cross-sectional observational study included the analysis of a sample of 70 patients (40 male and 30 female) presenting non-pathological headache symptoms in Northern India. The research used SYNGO software to assess the dimensions of the maxillary sinuses, specifically focusing on height, depth, and breadth measures of both the right and left sinuses. Height data were obtained from coronal pictures, while axial images were used to derive depth and width values. Furthermore, the calculation of maxillary sinus volumes was performed using the formula $\text{Volume} = (\text{height} \times \text{depth} \times \text{breadth} \times 0.5)$. The research used descriptive statistics to display the measures individually for males and females. Potential gender-based differences were examined by statistical analysis, including t-tests or ANOVA. Throughout the course of the study, the researchers diligently adhered to ethical concerns and obtained patient agreement, assuring the appropriate and ethical conduct of the research.

Inclusion and Exclusion

Inclusion Criteria

- Both genders of patients.
- Adults above the age of 18.
- The outpatient department of Mamata General Hospital in Khammam, Andhra Pradesh, is attended to by patients.
- People whose primary complaint is a headache.
- Patients who are native residents of the study location.
- Patients without maxillary sinus pathology.
- Patients who gave informed permission for research participation.

Exclusion Criteria

- Patients younger than 18 years old.
- Patients whose maxillary sinus pathology or surgery is well-documented.
- Patients with maxillary sinus trauma or recent facial traumas.

- CT scans may expose pregnant women to radiation.
- Contraindications for CT scans, such as pregnancy, kidney dysfunction, or severe allergies to contrast agents.

Statistical analysis

The Mann-Whitney U-test, a non-parametric test for comparing two independent groups, male and female patients, was used to analyze the measured dimensions. This test was used to compare maxillary sinus dimensions across genders, taking into account non-normal distribution and outliers. The Mann-Whitney U-test can identify gender-based discrepancies in maxillary sinus dimensions in this patient group.

Result

Table 1 uses Mann-Whitney U-tests to compare male and female right maxillary sinus features. In terms of "Height," male maxillary sinuses are taller than female ones, with a mean of 3.93 vs 3.07. In "Length," men had longer maxillary sinuses (mean: 3.73) than females (mean: 3.12). "Width" shows that men have broader sinuses (mean: 2.53) than females (2.20), although less so. In "Volume," men have 37.64 maxillary sinuses, while females have 21.10. These findings reveal that men have bigger and more elongated right maxillary sinuses than females, with height, length, and volume differing more than breadth.

Table 1: Male and female comparison of right maxillary sinus height, length, breadth, and volume using Mann-Whitney U-test

Parameters	Sex	n	Minimum	Maximum	Mean	Median	SD	SE	Z	P
Height	Male	40	3.12	4.48	3.93	3.94	0.35	0.08	-4.3760	0.00001*
	Female	30	2.69	3.34	3.07	3.12	0.17	0.05		
	Overall	70	2.69	4.48	3.55		0.52	0.09		
Length	Male	40	3.10	4.31	3.73	3.79	0.52	0.08	-4.0000	0.00001*
	Female	30	2.87	3.46	3.12	3.12	0.32	0.05		
	Overall	70	2.87	4.31	3.46		0.19	0.07		
Width	Male	40	2.07	3.29	2.53	2.46	0.40	0.09	-2.5330	0.0110*
	Female	30	1.87	2.75	2.20	2.15	0.36	0.06		
	Overall	70	1.87	3.29	2.39		0.21	0.06		
Volume	Male	40	24.12	56.32	37.64	38.71	0.34	2.36	-4.2900	0.00001*
	Female	30	18.15	27.07	21.10	20.11	9.73	0.79		
	Overall	70	18.15	56.32	30.47		11.19	2.04		

Table 2 compares male and female left maxillary sinus features using Mann-Whitney U-tests. In "Height," male maxillary sinuses are taller than female ones (8.85 vs. 3.11). In "Length," men have longer maxillary sinuses (mean: 3.81) than females (mean: 3.09). "Width" shows that men have somewhat wider sinuses (mean: 3.41) than females

(mean: 2.01). In "Volume," men have 34.89 maxillary sinuses, while females have 19.10. These results show that, like the right maxillary sinus, male left maxillary sinuses are bigger and more elongated than female ones, with height, length, and volume differing more than breadth.

Table 2: Male and female comparison of left maxillary sinus height, length, breadth, and volume using Mann-Whitney U-test

Parameters	Sex	n	Minimum	Maximum	Mean	Median	SD	SE	Z	P-value
Height	Male	40	3.10	4.89	3.85	3.56	0.29	0.05	-4.3759	0.00001*
	Female	30	2.25	3.34	3.11	3.13	0.15	0.04		
	Overall	70	2.71	4.48	3.46		0.44	0.04		
Length	Male	40	3.89	4.51	3.81	3.56	0.45	0.07	-4.0	0.00001*
	Female	30	2.01	3.01	3.09	3.12	0.21	0.06		
	Overall	70	2.45	3.89	3.11		0.22	0.06		
Width	Male	40	3.07	4.29	3.41	2.58	0.38	0.08	-2.4953	0.0110*
	Female	30	1.09	3.01	2.01	2.21	0.22	0.07		
	Overall	70	1.98	3.45	2.05		0.21	0.07		
Volume	Male	40	27.21	41.19	34.89	37.85	0.34	2.31	-4.3100	0.00001*
	Female	30	17.32	21.07	19.10	20.19	9.85	0.71		
	Overall	70	19.21	50.25	29.89		10.19	2.13		

Table 3 shows the proportion of right-side dimorphism in important parameters between men and women. Males are 21.89% taller than females on the right. Men are 19.489% longer on average. Males are 21.857% broader on average, although the

significance threshold is smaller ($p = 0.0701$). Males have 91.51% more right-sided volume than females. This data shows that height, length, and volume vary across sexes, whereas breadth is less obvious.

Table 3: Percentage of dimorphism of the right side

Parameter	Mean±SD		P	Percentage of dimorphism
	Male	Female		
Height	3.82±0.18	4.01±0.09	0.00001	21.89
Length	4.01±0.21	3.89±0.09	0.00001	19.489
Width	3.03±0.39	2.89±0.21	0.0701	21.857
Volume	41.18±8.89	19.89±2.87	0.00001	91.51

Table 4 shows the proportion of male-female left-side dimorphism across parameters. On average, men are 31.38% taller than women. Men are 19.547% longer on average. Males average 18.887% wider than females ($p = 0.0701$). The biggest difference is volume, with men averaging 89.43% more than females. This data shows significant variations in height, length, and volume between the sexes, with width being less apparent.

Table 4: Percentage of dimorphism of the left side

Parameter	Mean±SD		P-value	Percentage of dimorphism
	Male	Female		
Height	3.71±0.35	4.11±0.09	0.00001	31.38
Length	3.89±0.21	2.89±0.11	0.00001	19.547
Width	3.11±0.75	2.85±0.21	0.0701	18.887
Volume	40.11±8.72	20.89±2.71	0.00001	89.43

Figure 1 provides a visual contrast between men and females with respect to the right maxillary sinus's height, length, and breadth. Males average 4.01 feet in height, while ladies are just 3.12 feet tall on average. Males average 3.89 inches in length, while females are somewhat shorter at 3.25 inches. The

right maxillary sinus is likewise much broader in men than in girls, measuring 2.68 millimeters vs 2.25 millimeters. This diagram effectively illustrates the sex-related differences in the right maxillary sinus's anatomical features.

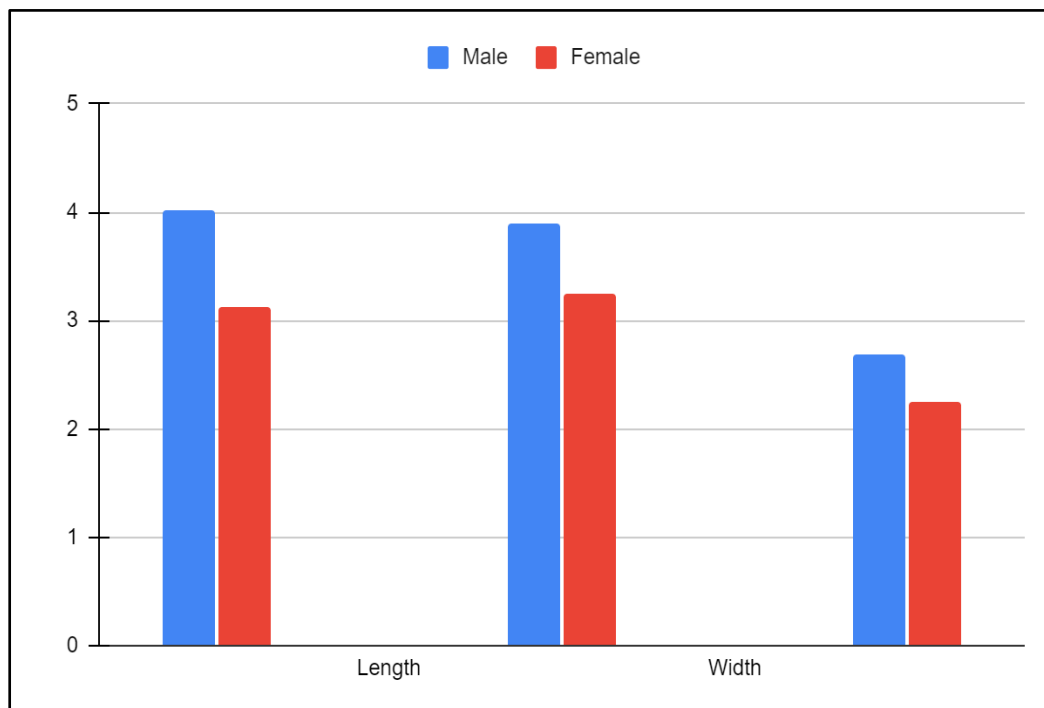


Figure 1: Comparison of males and females with respect to height, length and width on the right side of the maxillary sinus

Figure 2 shows a side-by-side depiction of the sex-related changes in the left maxillary sinus's dimensions between males and females. Males average 3.09 feet in height, while girls are somewhat shorter at 2.89 feet. The average guy is 3.91 inches tall whereas the average female is 2.71 inches.

Another obvious difference is the breadth of the left maxillary sinus, which is 4.01 mm in men and only 2.85 mm in females. This illustration shows how the left side of the maxillary sinus differs in appearance across the sexes.

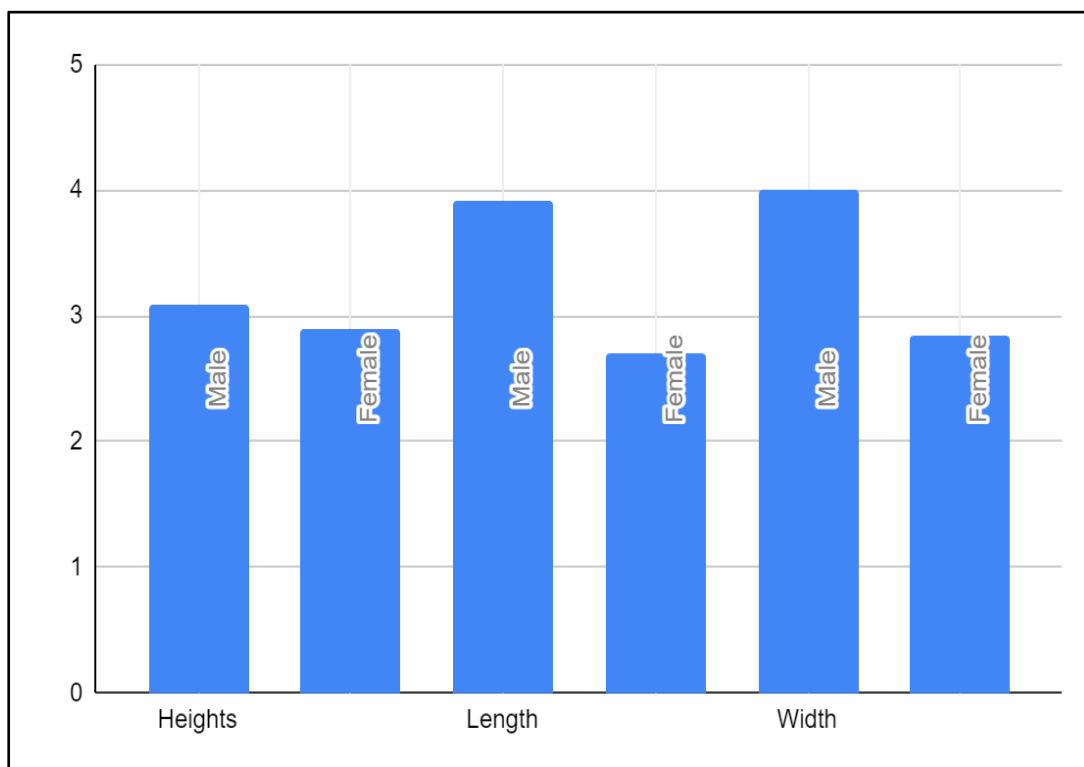


Figure 2: Comparison of males and females with respect to height, length and width on the left side of the maxillary sinus

Discussion

The issue of individual identity is a nuanced and frequently paramount concern in the context of large-scale catastrophes, traffic accidents, aircraft crashes, fires, or criminal inquiries. The correlation of distinct characteristics observed on a deceased body with information documented during an individual's lifetime is a crucial component of forensic science. This process involves the utilization of various techniques such as radiological methods, Determining an individual's age and sex may be done through methods including fingerprint analysis, anthropological techniques, deoxyribonucleic acid (DNA) pairing, as well as additional techniques [19]. Sinus radiography is a method that has been employed to ascertain the gender of a person. As a result, an effort is being made to use the different dimensions of the maxillary sinus to identify sex by looking at the coronal and axial regions of a conventional computed tomography (CT) scan. The utilization of Measurements taken of the maxillary sinus's height, length, width, and volume on both sides produced statistically significant results. outcomes in sex determination, particularly with regard to volume,

which exhibited a greater degree of sexual dimorphism. The correct diagnosis of sex can be facilitated by utilizing the amount of space of the right maxillary sinus as a diagnostic criterion [20].

An imaging method known as cone-beam computed tomography (CBCT) is non-invasive and has gained significant popularity in the field of dentistry for the visualization of dental anatomy and diseases. A study utilized existing CBCT records of patients exhibiting maxillary sinus conditions to investigate the sexual dimorphism associated with the maxillary sinus. A research investigation was undertaken using cone beam computed tomography (CBCT) to measure the maxillary sinuses' diameters and determine the utility of these measures in determining the sex of individuals. The measurement of maxillary sinus height has been established as a dependable radiographic indicator in the field of forensic odontology, specifically for the purpose of identifying a person's gender [21].

The identification of an unidentified human's sex remains is an essential aspect of forensic medicine, given the challenges associated with obtaining a complete and unbroken skeleton for analysis in

every case. The goal of the research was to assess the frontal and maxillary sinuses' reliability. measures in the process of determining the sex of individuals, utilizing Multidetector CT (MDCT) scans specifically obtained from a sample of Egyptian subjects. The utilization of multidetector computed tomography (MDCT) to assess various measurements, such as the size of the left maxillary sinuses, the right & left cephalo-caudal measures, the left transverse, has demonstrated promising potential in aiding the diagnosis of sex among individuals of Egyptian descent. Additionally, the examination of frontal sinuses and their associated factors has also shown valuable prospects in this regard [22].

The process of gender determination bears great significance in forensic medicine since it is essential to the identification process. The utilization of computed tomography (CT) imaging to assess the dimensions of maxillary sinuses has demonstrated the potential to aid the process of gender identification. A research investigation was carried out to investigate the reliability and accuracy of measuring the maxillary sinus dimensions for the purpose of classifying gender, utilizing reconstructed helical CT images. The accuracy rate for correctly determining the sex of maxillary sinuses was found to be 74%. Based on the findings, it can be inferred that the use of rebuilt CT images holds significant potential in obtaining precise measurements of the maxillary sinuses. Furthermore, in situations when alternative methods of sex determination yield inconclusive results, these reconstructed CT images may serve as a viable approach for determining the sex of an individual [23].

The purpose of the research was to evaluate the precision of gender identification by the utilization of computed tomography (CT) head and neck images, as well as volumetric analysis of the maxillary sinus. Research has revealed that there is a notable disparity in the size of the maxillary sinuses between sexes. making use of the maxillary sinuses enables the attainment of precise gender determination [24].

The determination of gender in unknown skeletons has historically relied on the examination of cranial, pelvic, and long bone features, including the presence of epiphyses and metaphyses. The objective The purpose of the study is to investigate the potential use of maxillary sinus measurements for determining gender. The results of The discriminative analysis showed that the precision of measurements of the maxillary sinus, particularly in terms of their capacity to distinguish between genders, was found to be 70.1% and 69.8% in men and females. Maxillary sinus CT measures have been proposed as a potentially useful technique in the discipline of forensic medicine to assist with

gender identification. But it's crucial to remember that this approach has a very low accuracy rate [25].

Sex estimation is a crucial component in determining the biological profile. In order to facilitate forensic identification, it is advantageous to utilize tools that rely on anatomical structures capable of retaining their integrity even in the face of harsh occurrences. The maxillary sinus, for instance, is one such structure that can be employed for this purpose. The goal of the study was to develop and validate a formula for identifying the sex of persons in a Brazilian community by analyzing measures taken from utilizing cone beam computed tomography (CBCT) images, of the maxillary sinuses. The formula derived from measurements conducted on imaging the maxillary sinus with CBCT demonstrated a sex estimation accuracy of 84.3%. This formula can serve as a supplementary approach for use in Brazilian society in identifying individuals [26].

Conclusion

The study concluded that forensic science relies on gender determination to identify people. This research emphasizes the gender-specific nature of maxillary sinus features. The research suggests using maxillary sinus measurements, particularly the right maxillary sinus volume, to explore sexual dimorphism. This study shows that CT imaging can accurately assess maxillary sinus dimensions. Our measures let forensic professionals and academics distinguish between males and women based on anatomical differences. By offering a practical and accurate gender determination tool, the research improves forensic investigations' accuracy and dependability.

References

1. Khangura RK, Sircar K, Singh S, Rastogi V. Sex determination using mesiodistal dimension of permanent maxillary incisors and canines. *J Forensic Dent Sci.* 2011;3:81–5.
2. Patil N, Karjodkar FR, Sontakke S, Sansare K, Salvi R. Uniqueness of radiographic patterns of the frontal sinus for personal identification. *Imaging Sci Dent.* 2012;42:213–7.
3. Teke HY, Duran S, Canturk N, Canturk G. Determination of gender by measuring the size of the maxillary sinuses in computerized tomography scans. *Surg Radiol Anat.* 2007; 29 :9–13.
4. Attia AM, Badrawy AM, Shebel HM. Gender identification from maxillary sinus using multidetector computed tomography. *Mansoura J Forensic Med Clin Toxicol.* 2012;20:17–26.
5. White PS, Robinson JM, Stewart IA, Doyle T. Computerized tomography mini-series: An alternative to standard paranasal sinus radiographs. *Aust N Z J Surg.* 1990;60:25–9.
6. Sahlstrand-Johnson P, Jannert M, Strömbeck A, Abul-Kasim K. Computed tomography

- measurements of different dimensions of maxillary and frontal sinuses. *BMC Med Imaging*. 2011;11:8.
7. Ukoha U, Egwu OA, Okafor IJ, Anyabolu AE, Ndukwe GU, Okpala I. Sexual dimorphism in the Foramen magnum of Nigerian adult. *Int J Biol Med Res*. 2011;2:878–81.
 8. Przysańska A, Kulczyk T, Rewekant A, Sroka A, Jończyk-Potoczna K, Gawriolek K, et al. The association between maxillary sinus dimensions and midface parameters during human postnatal growth. *Biomed Res Int* 2018; 2018: 10: 1.
 9. Lovasova K, Kachlik D, Rozpravkova M, Matuseska M, Ferkova J, Kluchova D. Three-Dimensional CAD/CAM imaging of the maxillary sinus in ageing process. *Ann Anat* 2018; 218: 69–82.
 10. Bhushan B, Rychlik K, Schroeder JW. Development of the maxillary sinus in infants and children. *Int J Pediatr Otorhinolaryngol* 2016; 91: 146–51.
 11. Arij Y, Kuroki T, Moriguchi S, Arij E, Kanda S. Age changes in the volume of the human maxillary sinus: a study using computed tomography. *Dentomaxillofac Radiol* 1994; 23: 163–8.
 12. Przysańska A, Kulczyk T, Rewekant A, Sroka A, Jończyk-Potoczna K, Lorkiewicz-Muszyńska D, et al. Introducing a simple method of maxillary sinus volume assessment based on linear dimensions. *Ann Anat* 2018; 215: 47–51.
 13. Radhakrishna SK, Shivarama CH, Ramakrishna A, Bhagya B. Morphometric analysis of foramen magnum for sex determination in North Indian population. *Nitte Univ J Health Sci*. 2012;2:20–2.
 14. Khatieeb MM. Sexual dimorphism of calvarial thickness parameter in different skeletal patterns. *Mustansiria Dent J*. 2011;8:144–51.
 15. Kawarai Y, Fukushima K, Ogawa T, Nishizaki K, Gunduz M, Fujimoto M, et al. Volume quantification of healthy paranasal cavity by three-dimensional CT imaging. *Acta Otolaryngol Suppl*. 1999;540:45–9.
 16. Fernandes CL. Forensic ethnic identification of crania: The role of the maxillary sinus - A new approach. *Am J Forensic Med Pathol*. 2004; 25:302–13.
 17. Amin MF, Hassan EI. Sex identification in Egyptian population using Multidetector Computed Tomography of the maxillary sinus. *J Forensic Leg Med*. 2012;19:65–9.
 18. Uthman AT, Al-Rawi NH, Al-Naaimi AS, Al-Timimi JF. Evaluation of maxillary sinus dimensions in gender determination using helical CT scanning. *J Forensic Sci*. 2011;56:403–8.
 19. Whyte, A., & Boeddinghaus, R. The maxillary sinus: Physiology, development and imaging anatomy. *Dentomaxillofacial Radiology*, 2019; 48(8).
 20. Kanthem, R. K., Guttikonda, V. R., Yeluri, S., & Kumari, G. Sex determination using maxillary sinus. *Journal of Forensic Dental Sciences*, 2015;7(2): 163-167.
 21. Deshpande, A. A., Munde, A. D., Mishra, S. S., Kawsankar, K. D., Sawade, R. V., & Mandar, B. Determination of sexual dimorphism of maxillary sinus using cone-beam computed tomography in a rural population of western Maharashtra – A retrospective, cross-sectional study. *Journal of Family Medicine and Primary Care*, 2022;11(4): 1257-1261.
 22. Ibrahim, M. A., Abdel-Karim, R. I., Ibrahim, M. S., & Dar, U. F. Comparative study of the reliability of frontal and maxillary sinuses in sex identification using multidetector computed tomography among Egyptians. *Forensic Imaging*, 2020;22: 200390.
 23. Uthman AT, Al-Rawi NH, Al-Naaimi AS, Al-Timimi JF. Evaluation of maxillary sinus dimensions in gender determination using helical CT scanning. *J Forensic Sci*. 2011 Mar;56 (2):403-8.
 24. Jaideepa, Jha A, Mehta DN, Singh V, Malawat K, Sinha S. Gender Determination from Maxillary Sinus using Computed Tomography Scans - A Radiographic Study. *J Pharm Bioallied Sci*. 2023 Jul;15(Suppl 2): S1010-S1012.
 25. Teke HY, Duran S, Canturk N, Canturk G. Determination of gender by measuring the size of the maxillary sinuses in computerized tomography scans. *Surg Radiol Anat*. 2007 Feb; 29(1): 9-13.
 26. Farias Gomes A, de Oliveira Gamba T, Yamasaki MC, Groppo FC, Haiter Neto F, Possobon RF. Development and validation of a formula based on maxillary sinus measurements as a tool for sex estimation: a cone beam computed tomography study. *Int J Legal Med*. 2019 Jul; 133(4):1241-1249.