

A Hospital-Based Study to Compare the Safety and Effectiveness of Sub Tenon's Anesthesia versus Peribulbar Anesthesia in Small Incision Cataract Surgeries

Nandani Priyadarshini¹, Rajesh Kumar Tiwary²

¹Senior Resident, Department of Ophthalmology, Nalanda Medical College and Hospital, Patna, Bihar, India

²Professor, Department of Ophthalmology, Nalanda Medical College and Hospital, Patna, Bihar, India

Received: 02-10-2023 / Revised: 19-11-2023 / Accepted: 28-12-2023

Corresponding Author: Dr. Nandani Priyadarshini

Conflict of interest: Nil

Abstract

Aim: The present study was conducted to compare the safety and effectiveness of sub tenon's anesthesia versus peribulbar anesthesia in small incision cataract surgeries.

Methods: A prospective longitudinal study was conducted among 100 patients who attended Ophthalmology OPD, Nalanda Medical College and Hospital, Patna, Bihar, India from March 2018 to February 2019, for cataract surgery. After obtaining ethical approval from our institutional review board and informed consent from the patients, patients of both sexes opting for SICS were enrolled in our study.

Results: In subtenon's group out of 50 patients 16 (32%) were males, 34 (68%) were females. In peribulbar group out of 50 patients 17 (34%) were males, 33 (66%) were females. Student T test showed no significant difference in sex distribution of study groups. In our study, patient's age in sub tenon's group was ranging from 40-80 years and in peribulbar group from 42-85 years. Student T test showed no significant difference in age distribution of the study groups. (P value = 0.340). In sub tenon's group mean IOP was 15.65 mmHg +/- 1.16 SD. In peribulbar group it was 16.42 mmHg +/- 1.40 SD. Student T test showed no statistical significant difference in the pre operative intraocular pressure between two groups. (P value = 0.07). In sub tenon's group mean IOP was 22.24 mmHg +/- 4.32 SD, In peribulbar group it was 26.62 mmHg +/- 6.40 SD. Student T test showed significant difference. (P value = 0.001). In subtenant's group mean IOP was 16.14 mmHg +/- 1.48 SD, In peribulbar group it was 16.64 mmHg +/- 1.48 SD. Student T test showed no significant difference between the two groups. (P value = 0.07).

Conclusion: Sub tenon's anesthesia and peribulbar anesthesia provide adequate analgesia, akinesia during cataract surgery. However there is slight difference between two groups in providing akinesia, Sub tenon's anesthesia has some partial residual movements which can be negotiated with patient cooperation or fixation forceps. The residual partial movements of subtenant's anesthesia did not hamper any steps in cataract surgery. Sub tenon's anesthesia is less painful during administration compared to peribulbar anesthesia.

Keywords: Sub tenon's anesthesia, Peribulbar anesthesia, Small Incision Cataract Surgery

This is an Open Access article that uses a funding model which does not charge readers or their institutions for access and distributed under the terms of the Creative Commons Attribution License (<http://creativecommons.org/licenses/by/4.0>) and the Budapest Open Access Initiative (<http://www.budapestopenaccessinitiative.org/read>), which permit unrestricted use, distribution, and reproduction in any medium, provided original work is properly credited.

Introduction

Sub-Tenon's anesthesia has progressively replaced peribulbar anesthesia for cataract surgery because it is a simple and effective technique that avoids the hazards inherent in introducing a sharp object into the orbit, as in a peribulbar injection. [1-3] In addition to being safe, an anesthesia technique must allow for effective surgical performance and be acceptable to the patient. Intraocular pressure elevation after peribulbar injection is common. [4] This has important implications when considering surgery for patients in whom ocular circulation may be compromised (e.g., glaucoma cases). Several precautions have been recommended to prevent this

pressure rise (e.g., pharmacological lowering of the IOP before surgery, fractionation of the anesthetic injection, and ocular compression before injection).

Effective and safe local ocular anesthesia that would not cause a rise in IOP is preferable, and our results show that sub-Tenon's anesthesia provides this benefit. The elevation in IOP with the sub-Tenon's injection was nonsignificant, while it was significant with peribulbar anesthesia. This finding agrees with that of Stevens. Regional anesthesia has been popularized in ophthalmic surgery because of its high success rate and a wide margin of safety. [5] It ensures quicker patient recovery thereby enabling

day-surgery cases and reduction in cost of surgery. [6] Multiple co-morbidities and multiple drug use are very common in cataract patients. [7] Therefore, researchers have focused on anesthetic techniques for cataract surgery that ensure patients' safety, comfort, and attain optimum safe conditions for the surgical procedure. [6] Retrobulbar block was hitherto the mainstay of local anesthesia for cataract surgery. [8] It has a fast onset of action with a small volume of anesthetic agent required. However, it is associated with vision and life-threatening complications.

Historically, retrobulbar anesthesia was used for a long time for cataract surgery but lost popularity due to its associated multiple potentially sight-threatening complications. Peribulbar anesthesia has become the most popular technique over the last decade. However, it is also not completely free from risks like perforation. [9] Ophthalmologists are now looking at sub tenon's anesthesia, in which the local anesthetic agent is directly injected into the sub tenon's space. After instilling topical anesthetic drops in the conjunctival fornix, a small opening is made in the conjunctiva and tenon's capsule. Through this opening a blunt cannula is inserted to deliver the anesthetic agent into the sub tenon's space. It is becoming popular because of its simplicity and decrease in the risk of needle related injuries and complications as the procedure of injecting into a blind space is prevented. The Sub tenon's anesthesia is being used in developed countries for phacoemulsification surgeries along with topical anaesthesia, [10] however, there are limited studies on the topic in our country.

The present study was conducted to compare the safety and effectiveness of sub tenon's anesthesia versus peribulbar anesthesia in small incision cataract surgeries.

Materials and Methods

A prospective longitudinal study was conducted among 100 patients who attended Ophthalmology OPD, Nalanda Medical College and Hospital, Patna, Bihar, India from March 2018 to February 2019, for cataract surgery. Informed consent from the patients, patients of both sexes opting for SICS were enrolled in our study.

A Total of 100 patients were selected for current study of which 50 patients underwent small incision cataract surgery under sub tenon's anesthesia and 50 under peribulbar anesthesia satisfying all inclusion and exclusion criteria.

Patients undergoing MSICS for age related cataracts were included in this study. Our exclusion criteria included patients who had sensitivity to the drugs used (lignocaine), > 85 years of age, history of previous ocular surgery, injury or inflammation of the eye, history of previous scleritis/episcleritis,

traumatic cataract/congenital cataract/ complicated cataract, patients on aspirin and clopidogrel, unable to follow or having difficulty understanding the scale for pain assessment, patient requesting for a phacoemulsification surgery, anxious patient, chronic alcohol and tobacco users and patient not willing to participate. Patients undergoing MSICS were divided into the two groups of peribulbar (P) and sub tenon's (ST) block by using a random number table. Intraoperatively oxygen saturation and pulse rate were monitored continuously till the end of surgery. The ophthalmic blocks were performed under strict asepsis by one of two consultant ophthalmologists with minimum of three years of experience in SICS and in administering peribulbar blocks and sub tenons blocks. Both consultants had limited 50 cases each experience of giving sub tenon's blocks.

Technique of peribulbar block

The cleaning and draping of the eye to be operated and the surrounding area was done with povidone iodine solution (5%) and then asked to look straight up so as to put the eye into the primary position. After palpating the inferior orbital rim, at the junction of the medial two-third and lateral one-third of the rim, a 10 ml syringe with a 24 gauge(G) needle (bevel facing towards the globe) is used to inject the anesthetic solution (4 ml of 2% lignocaine with 1:1,000 adrenaline, 4% bupivacaine and 75 IU/ml hyaluronidase) through the eyelid skin. The needle was advanced along the floor of the orbit (i.e. parallel to it) and kept tangential to the globe until the hub of the needle touched the eyelid skin. After ensuring there was no aspiration of blood in the syringe, 4-5ml of the anesthetic solution was injected. This was followed by a digital massage for 2 minutes to increase the spread of the anesthetic solution. Another 3-4 ml of the anesthetic solution was injected through the lid at the medial 1/3rd and lateral 2/3rd junction of the superior orbital rim followed by a digital massage for another 2 minutes and then 2 minutes later akinesia was assessed.

The assessment of akinesia was done with the help of a scale(transparent). Keeping the limbus as a landmark for each quadrant, movement from the primary position was assessed. No movement in three or more quadrants was considered "excellent akinesia", less than two millimeters movement in three or more quadrants was considered as "good akinesia" and movement of the eye to an amount greater than two millimeters in two or more quadrants was considered as "fair akinesia" for which additional anesthetic was required to be injected.

Technique for sub-tenon space block

To be operated eye and surrounding area was cleaned with povidone iodine (5%), two drops of

topical anesthetic (0.5%proparacaine) followed by insertion of a universal wire speculum. The patient was asked to look supero- temporally in order to expose the inferonasal quadrant. The conjunctiva along with the tenon's capsule was grasped with a Lim's forceps and a nick was made with a blunt Westcott scissor approximately 5-6 mm from the limbus, making sure to avoid direct injury to blood vessels. Blunt dissection of the tenon capsule was done using the Westcott scissors, making a narrow channel so as to avoid leakage of the anesthetic outside through it. After withdrawing the Westcott's, a curved, blunt tipped steel sub tenon's cannula (21G, 2.54-cm) was inserted through the channel created, keeping the cannula along the curvature of the globe. It was inserted till the hub of the cannula touched the external conjunctival opening. This position ensured that the cannula tip was placed posterior enough to help attain an effective block.

The anesthetic solution comprising of 6ml of lignocaine along with adrenaline, bupivacaine and 75 IU/ml hyaluronidase was injected slowly. Initially 3ml was injected as subtenant's Minimal digital compression was performed followed, 2 minutes later by assessment of akinesia. If akinesia was inadequate, additional 2ml was administered.

Pain assessment

Pain assessment was carried at multiple intervals i.e. during the procedure and postoperatively at 0, 1, 4 and 24 hours. It was assessed using a ten point numeric rating scale by asking the patient to score the pain in a range of zero to ten. Only the complaint of most severe pain on more than one occasion was considered as significant. According to the rating scale, absence of pain was taken as zero, scores less than five were considered as mild pain and moderate to severe pain was scored as >5. Oral paracetamol was used to alleviate the moderate-to-severe postoperative pain and oral diclofenac was administered if the pain was still persistent. The other factors assessed included the time to attain akinesia, patient's comfort and satisfaction score with regards to the administration of anesthesia. Patient comfort score was assessed as: 0- complete absence of sensation in the operated eye, 1- presence of sensation of the eye (slight pressure) but with no discomfort, 2- mild discomfort, but with the patient

declining further analgesia or with no obvious clinical need for such further intervention, 3-patient expresses wish for additional analgesia or exhibits an obvious clinical need for such intervention such as a state of distress related to pain on further questioning or requested for pain relief.

Intraoperative Positive Pressure (PP) was graded as: 0 – No PP 1 – Mild – not requiring intervention, 2 – Moderate – settled with intraoperative maneuvers and 3 – Severe – requiring intravenous mannitol.

Amount of Subconjunctival Hemorrhage (SCH) was graded as 0 – no hemorrhage, 1 – mild (<90 degrees/ 1 quadrant), 2 – moderate (> 90 degrees/ 2 quadrants) and 3 – severe (> 180 degrees/ > 2 quadrants). Amount of Chemosis was graded as 0 – no chemosis, 1 – mild (<90 degrees/ 1 quadrant), 2 – moderate (> 90 degrees/2 quadrants) and 3 – severe (> 180 degrees/ > 2 quadrants) – causing obstruction in vision. The presence of pain intraoperatively and postoperatively and its severity were the primary outcome measures. The secondary outcome measures included anesthesia related complications, amount of anesthesia used and the patient satisfaction after the MSICS.

Statistical Analysis

Continuous variables were expressed as mean with standard deviation or median with interquartile range (IQR) and group differences between continuous variables were analyzed using the student t test or the Wilcoxon's ranksum test in cases with nonparametric distribution. The Shapiro Wilk test was used to understand the normalcy of distribution of continuous variables. Categorical variables were expressed as proportions (n, %) and group differences between categorical variables were analyzed using the chi square test or the Fischer's exact test for proportions below 5%. Correlations between some of the continuous variables were assessed using the Pearson's correlation coefficient and expressed graphically using the Locally Weighted Scatterplot Smoothing (LOWESS) curve. The data analysis was done using STATA 12.1 I/c (STATA Corp, Fort Worth, Texas, USA) after entering the data into Microsoft Excel. A p value was considered statistically significant when it was less than 0.05.

Results

Table 1: Demographic data

Gender	Sub-tenon's	Peribulbar
Male	16 (32)	17 (34)
Female	34 (68)	33 (66)
P Value	0.120	
Age in years		
40-50	4 (8)	3 (6)
50-60	17 (34)	11 (22)
60-70	16 (32)	19 (38)

70-80	13 (26)	17 (34)
Mean	62.98	64.36
P Value	0.340	

In subtenon's group out of 50 patients 16 (32%) were males, 34 (68%) were females. In peribulbar group out of 50 patients 17 (34%) were males, 33 (66%) were females. Student T test showed no significant difference in sex distribution of study groups. In our

study, patient's age in subtenon's group was ranging from 40-80 years and in peribulbar group from 42-85 years. Student T test showed no significant difference in age distribution of the study groups. (P value = 0.340).

Table 2: Intra Ocular Pressure pre-op, at 1 min, at 15 min

Mean IOP	Sub-tenon's	Peribulbar	P value
PRE OP	15.65	16.42	0.07
At 1 min	22.24	26.62	0.001
At 5 min	16.14	16.64	0.07

In subtenon's group mean IOP was 15.65 mmHg +/- 1.16 SD. In peribulbar group it was 16.42 mmHg +/- 1.40 SD. Student T test showed no statistical significant difference in the pre operative intraocular pressure between two groups. (P value = 0.07). In subtenon's group mean IOP was 22.24 mmHg +/- 4.32 SD, In peribulbar group it was 26.62 mmHg +/-

6.40 SD. Student T test showed significant difference. (P value = 0.001). In subtenon's group mean IOP was 16.14 mmHg +/- 1.48 SD, In peribulbar group it was 16.64 mmHg +/- 1.48 SD. Student T test showed no significant difference between the two groups. (P value = 0.07).

Table 3: Distribution of Chemosis and Analgesia

Chemosis	Sub-tenon's	Peribulbar
No chemosis	8 (16)	37 (74)
1 Quadrant	20 (40)	7 (14)
2 Quadrant	16 (32)	6 (12)
3-4 Quadrant	6 (12)	0
P Value	0.00	
Pain		
No Sensation	32 (64)	7 (14)
Sensation	15 (30)	16 (32)
Mild Pain	3 (6)	13 (26)
Moderate Pain	0	12 (24)
Severe Pain	0	2 (4)
P Value	0.00	

Out of 50 patients in sub tenon's group 8 (16%) had no chemosis, 20 (40%) had chemosis in one quadrant, 16 (32%) in two quadrants, 6 (12%) in three or more quadrants. In peribulbar group 37 (74%) had no chemosis, 7 (14%) had chemosis in one quadrant, and 6 (12%) in two quadrants. 0 in three or more quadrants. Chi-square test showed significant difference between two groups. In subtenon's group 32 (64%) had no sensation or pain,

15 (30%) experienced sensation, 3 (6%) experienced mild pain, 0-none had moderate pain and 0-none had severe pain. In peribulbar group 7 (14%) had no sensation or pain, 16 (32%) experienced sensation, 13 (26%) experienced mild pain, 12 (24%) had moderate pain and 2 (4%) had severe pain. Chi-square test showed significant difference between two groups.

Table 4: Distribution of SCH and Akinesia 5 Min After Anesthesia

SCH	SUBTENON	PERIBULBAR
NO SCH	11 (22)	42 (84)
1 QUADRANT	22 (44)	8 (16)
2 QUADRANT	10 (20)	0
3-4 QUADRANT	7 (14)	0%
P Value	0.00	
AKINESIA		

NO MOVEMENT	10 (20)	27 (54)
FLUTTER	20 (40)	14 (28)
PARTIAL MOVEMENT	18 (36)	9 (18)
FULL MOVEMENT	2 (4)	0%
P Value	0.01	

Out of 100 patients in sub tenon’s group 11 (22%) had no SCH, 22 (44%) had SCH in one quadrant, 10 (20%) in two quadrants, 7 (14%) in three or more quadrants. In peribulbar group 42 (84%) had no SCH, 8 (16%) had SCH in one quadrant, and 0 in two quadrants. 0 in three or more quadrants. Chi-square test showed a significant difference between

two groups. In subtenon's group 10 (20%) had no movements, 20 (40%) had flutter, 18 (36%) had partial movements, 2 (4%) had full movements. In peribulbar group 27 (54%) had no movements, 14 (28%) had flutter, 9 (18%) had partial movements, 0-none had full movements. Chi-square test showed significant difference between two groups.

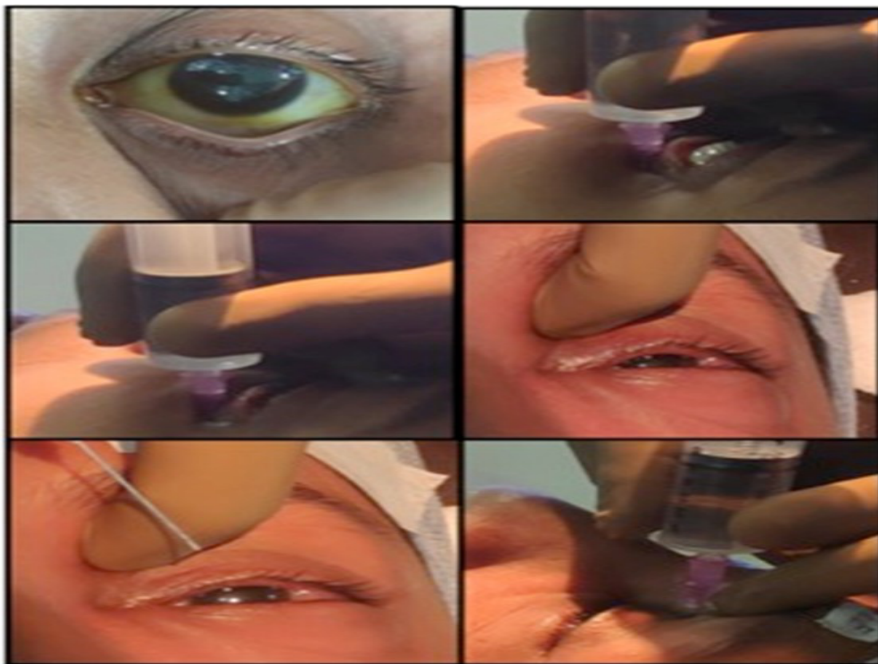

Figure 1: Technique of giving a peribulbar block

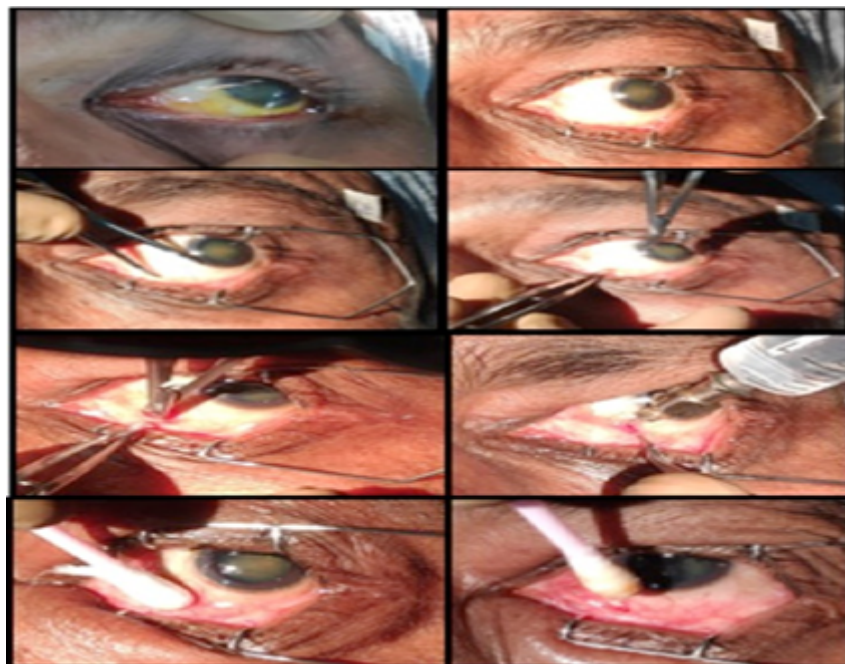


Figure 2: Technique of giving a sub tenon’s block

Discussion

Cataract surgery is the one of the most common surgical procedures with a good safety profile. As cataract surgery has evolved over the years, so has the anaesthesia used in an attempt to reduce the risks and complications. Shorter acting, less invasive methods of anesthesia are being used nowadays for small incision cataract surgery (SICS), which is possible due to the development of better surgical techniques like a self-sealing and smaller wound, availability of better intraocular lens designs and less tissue manipulation with modern instrumentation. [9]

In subtenon's group out of 50 patients 16 (32%) were males, 34 (68%) were females. In peribulbar group out of 50 patients 17 (34%) were males, 33 (66%) were females. Student T test showed no significant difference in sex distribution of study groups. In our study, patient's age in subtenon's group was ranging from 40-80 years and in peribulbar group from 42-85 years. Student T test showed no significant difference in age distribution of the study groups. (P value = 0.340). In sub tenon's group mean IOP was 15.65 mmHg +/- 1.16 SD. In peribulbar group it was 16.42 mmHg +/- 1.40 SD. Student T test showed no statistical significant difference in the pre operative intraocular pressure between two groups. (P value = 0.07). In sub tenon's group mean IOP was 22.24 mmHg +/- 4.32 SD, In peribulbar group it was 26.62 mmHg +/- 6.40 SD. Student T test showed significant difference. (P value = 0.001). In subtenon's group mean IOP was 16.14 mmHg +/- 1.48 SD, In peribulbar group it was 16.64 mmHg +/- 1.48 SD. Student T test showed no significant difference between the two groups. (P value = 0.07). Barak Azmon et al. in their study of 64 patients found a significant difference in the mean IOP between the two groups at 1 min. [11]

Out of 50 patients in sub tenon's group 8 (16%) had no chemosis, 20 (40%) had chemosis in one quadrant, 16 (32%) in two quadrants, 6 (12%) in three or more quadrants. In peribulbar group 37 (74%) had no chemosis, 7 (14%) had chemosis in one quadrant, and 6 (12%) in two quadrants. 0 in three or more quadrants. Chi-square test showed significant difference between two groups. Chi-square test showed significant difference between two groups. Stan J Roman et al [12] reported in their study that 39% had chemosis involving more than 1 quadrant in sub tenon's anesthesia. It takes a little practice to limit chemosis by ensuring that the local anesthetic solution is truly delivered to posterior sub tenon's space and not to anterior subconjunctival space. Chemosis did not interfere in any surgical steps in our study.

In sub tenon's group 32 (64%) had no sensation or pain, 15 (30%) experienced sensation, 3 (6%) experienced mild pain, 0-none had moderate pain

and 0-none had severe pain. In peribulbar group 7 (14%) had no sensation or pain, 16 (32%) experienced sensation, 13 (26%) experienced mild pain, 12 (24%) had moderate pain and 2 (4%) had severe pain. Chi-square test showed significant difference between two groups. Out of 100 patients in sub tenon's group 22 (22%) had no SCH, 45 (45%) had SCH in one quadrant, 20 (20%) in two quadrants, 13 (13%) in three or more quadrants. In peribulbar group 80 (80%) had no SCH, 20 (20%) had SCH in one quadrant, and 0 in two quadrants. 0 in three or more quadrants. Chi-square test showed a significant difference between two groups. Out of 100 patients in sub tenon's group 11 (22%) had no SCH, 22 (44%) had SCH in one quadrant, 10 (20%) in two quadrants, 7 (14%) in three or more quadrants. In peribulbar group 42 (84%) had no SCH, 8 (16%) had SCH in one quadrant, and 0 in two quadrants. 0 in three or more quadrants. Chi-square test showed a significant difference between two groups. In subtenon's group 10 (20%) had no movements, 20 (40%) had flutter, 18 (36%) had partial movements, 2 (4%) had full movements. In peribulbar group 27 (54%) had no movements, 14 (28%) had flutter, 9 (18%) had partial movements, 0-none had full movements. Chi-square test showed significant difference between two groups. The different volumes of anesthetic agents used may account for the variation. However, in another study Al-Yousuf [13] in Bahrain used equal volumes of the same anesthetic mixture in both groups and reported that the sub-Tenon's anesthesia was more effective in achieving globe akinesia compared to peribulbar anesthesia. However, he did not state the time interval for grading the akinesia.

Adekola et al [14] conducted a study to compare peribulbar and sub tenon's anesthesia for MSICS among 462 patients. They reported significantly less pain score in the group ST than the group P, significantly higher chemosis in the group ST (3.2%) than in the group P (0%) and a very small proportion of patients with complete akinesia (only 10 eyes in group P and 1 eye in group ST). After comparing all the above parameters, Adekola et al [14] reported a higher overall patient satisfaction with the sub tenon's technique. There was no significant difference in patient comfort scores in the two groups (p=0.47) in our study. Ashok et al [15] conducted a similar randomized controlled trial (RCT) study with 113 patients. They reported that average time to akinesia with sub tenon's technique was significantly shorter (2.78 ± 0.9 minutes) compared to peribulbar technique (9.96 ± 2.2 minutes). Higher pain score with peribulbar technique (5.12 ± 1.255) as compared to sub tenon's anesthesia (3.77 ± 1.716) at the time of injection. Datti et al [16] conducted a prospective and RCT to compare the two techniques among 500 patients who underwent MSICS with rigid polymethyl

Methacrylate (PMMA) IOL implantation. Similar to our study, they reported that there was a significant difference in the pain scores at the time of administration of anesthetic between the two techniques, being more for the group P.

It is much better in terms of patient comfort, amount of pain and most importantly in terms of safety. Sub tenon's technique, however has none such reported to our knowledge and logically a blunt cannula is far safer than a sharp needle even in the most experienced hand.

Conclusion

Subtenon's anesthesia and peribulbar anesthesia provide adequate analgesia, akinesia during cataract surgery. However there is slight difference between two groups in providing akinesia, Sub tenon's anesthesia has some partial residual movements which can be negotiated with patient cooperation or fixation forceps. The residual partial movements of sub tenon's anesthesia did not hamper any steps in cataract surgery. Sub tenon's anesthesia is less painful during administration compared to peribulbar anesthesia. Intraocular pressure in sub tenon's anesthesia remains within acceptable limits where as it is raised immediately after peribulbar anesthesia. Subconjunctival hemorrhage and chemosis are frequently encountered in sub tenon's anesthesia compared to peribulbar anesthesia, which also do not hamper any steps of cataract surgery. Subtenon's anesthesia is a safe and effective anesthesia compared to peribulbar anesthesia in small incision cataract surgeries.

References

1. Buys YM, Trope GE. Prospective study of sub-Tenon's versus retrobulbar anesthesia for inpatient and day-surgery trabeculectomy. *Ophthalmology*. 1993 Oct 1;100(10):1585-9.
2. Stevens JD. A new local anesthesia technique for cataract extraction by one quadrant sub-Tenon's infiltration. *British journal of ophthalmology*. 1992 Nov 1;76(11):670-4.
3. Ritch R, Liebmann JM. Sub-Tenon's anesthesia for trabeculectomy. *Ophthalmic Surgery, Lasers and Imaging Retina*. 1992 Jul 1;23(7):502-4.
4. Joshi N, Reynolds A, Porter EJ, Rubin AP, Kinnear PE. An assessment of intraocular pressure during fractionated peribulbar anaesthesia. *Eye*. 1996 Sep;10(5):565-8.
5. McLure HA, Rubin AP. Local anaesthesia for ophthalmic surgery. *Current Anaesthesia & Critical Care*. 1999 Feb 1;10(1):40-7.
6. Malik A, Fletcher EC, Chong V, Dasan J. Local anesthesia for cataract surgery. *J Cataract Refract Surg*. 2010 Jan;36(1):133-52.
7. McKibbin M. The pre-operative assessment and investigation of ophthalmic patients. *Eye (Lond)*. 1996;10 (Pt 1):138-40.
8. Nouvellon E, Cuvillon P, Ripart J. Regional anesthesia and eye surgery. *Anesthesiology*. 2010 Nov;113(5):1236-42.
9. Parkar T, Gogate P, Deshpande M, Adenwala A, Maske A, Verappa K. Comparison of subtenon anaesthesia with peribulbar anaesthesia for manual small incision cataract surgery. *Indian Journal of Ophthalmology*. 2010 Oct 1;53(4):255-9.
10. Guise P. Sub-Tenon's anesthesia: an update. *Local and regional anesthesia*. 2012 Jun 21:35-46.
11. Azmon B, Alster Y, Lazar M, Geyer O. Effectiveness of sub-Tenon's versus peribulbar anesthesia in extracapsular cataract surgery. *Journal of Cataract & Refractive Surgery*. 1999 Dec 1;25(12):1646-50.
12. Roman SJ, Sit DA, Boureau CM, Auclin FX, Ullern MM. Sub-Tenon's anaesthesia: an efficient and safe technique. *British journal of ophthalmology*. 1997 Aug 1;81(8):673-6.
13. Al-Yousuf N. Subtenon versus peribulbar anaesthesia for cataract surgery. *Bahrain Med Bull*. 2003 Sep;25:115-8.
14. Adekola OO, Aribaba OT, Musa K, Olatosi JO, Asiyambi GK, Rotimi-Samuel A, Onakoya A, Akinsola FB. Regional anesthesia for small incision cataract surgery: Comparison of subtenon and peribulbar block. *Journal of Clinical Sciences*. 2018 Jan 1;15(1):1-7.
15. Ashok A, Krishnagopal S, Jha KN. Comparison of peribulbar anesthesia with sub-tenon's in manual small incision cataract surgery. *TNOA Journal of Ophthalmic Science and Research*. 2018 Apr 1;56(2):67-70.
16. Datti NP, Krishnappa K, Guruprasad BS, Krishnappa P, Guha J, Bansal A. Efficacy and safety of subtenon's and peribulbar anaesthesia in manual small incision cataract surgery. *J Clin Biomed Sci*. 2013;3(1):20.