

## An Observational Study to Evaluate Mammographic and Sonographic Findings in Breast Cancer Screening at Tertiary Care Centre

Sandeep Kumar<sup>1</sup>, Madhukar Dayal<sup>2</sup>, Rajeev Ranjan<sup>3</sup>

<sup>1</sup>Senior Resident, Department of Radiology, Nalanda Medical College and Hospital, Patna, Bihar, India

<sup>2</sup>Assistant Professor, Department of Radiology, Nalanda Medical College and Hospital, Patna, Bihar, India

<sup>3</sup>Professor, Nalanda Medical College and Hospital, Patna, Bihar, India

Received: 15-10-2023 Revised: 19-12-2023 Accepted: 16-02-2024

Corresponding Author: Dr. Sandeep Kumar

Conflict of interest: Nil

### Abstract

**Aim:** The aim of the present study was to assess the mammographic and sonographic findings in breast cancer screening.

**Methods:** The present study was conducted in the Department of Radiology. Breast lesions were detected by clinical breast examination, mammography and ultrasound. A total of 200 breast lesions were examined by histological methodology.

**Results:** A total of 200 breast lesions were examined by histological method, revealing the presence of 96 invasive cancers, and 104 benign lesions. The mean age of the patient was 58 years, ranging from 31 to 78 years. Most of the patients belonged to 50-59 years. The histological types of cancer in 96 patients were: invasive ductal, invasive lobular, mixed (ductal/lobular) tubular, medullary, mucinous. Mammography was false negative in 44 out of 96 invasive cancers; ultrasound was false negative in 26 out of 96 cancers. Mammography was false negative in 30 out of 104 patients without cancer; ultrasound was false negative in 14 out of 104 patients without cancer.

**Conclusion:** Breast ultrasound is more accurate than mammography in symptomatic women 45 years or younger, mammography has progressive improvement in sensitivity in women 60 years or older. The accuracy of mammograms increased as women's breasts became fatter and less dense. In young women and women with dense breasts, ultrasound appears superior to mammography, and may be an appropriate initial imaging test in those women.

**Keywords:** breast lesions, diagnostic methods, mammography, ultrasound

This is an Open Access article that uses a funding model which does not charge readers or their institutions for access and distributed under the terms of the Creative Commons Attribution License (<http://creativecommons.org/licenses/by/4.0>) and the Budapest Open Access Initiative (<http://www.budapestopenaccessinitiative.org/read>), which permit unrestricted use, distribution, and reproduction in any medium, provided original work is properly credited.

### Introduction

Breast cancer is one of leading cancers among Indian women. Increasing incidence of breast cancer is alarming. India being a conservative society, women hesitate to seek medical attention. There is lack of awareness on breast cancer. Often, ladies visit hospitals at terminal stages, when mortality rates are high. Prevalence estimates in India are just tip of an iceberg. Western literature emphasizes that screening for breast cancer would reduce mortality rates [1].

The three strongest prognostic factors in invasive breast cancer are widely accepted to be lymph node stage, histological grade and the size of histologically invasive cancer. [1-4] Axillary lymph node stage is an important prognostic factor in invasive breast cancer: the prognosis progressively worsens with an increasing number of involved nodes. Although controversial, micro metastatic disease continues to have clinical significance. Most

series have shown that nodal micrometastasis appears to have a more or less adverse effect on disease and overall survival. [5] The three strongest prognostic factors in invasive breast cancer provide more valuable information when taken into account altogether than when any single individual factor is used alone. [6]

The Nottingham Prognostic Index (NPI) uses these three factors and has been externally validated by several studies. [3,7-9] In addition, histological grade, tumour size and oestrogen receptor (ER) status are usually used as significant factors in guiding adjuvant systemic chemotherapy in node-negative patients. [10] Lymphovascular invasion (LVI) shows a clear relationship with nodal status [11-14] and local recurrence. [13,14] LVI is also related to distant metastasis and overall survival in node-negative breast cancer. [15,16]

Lee et al [11] concluded that LVI was an independent prognostic factor in node-negative breast cancer and should be considered when making decisions regarding adjuvant treatment in this group of patients. Gajdos et al [16] carried out a study of 543 non-palpable breast cancers, and demonstrated that lymphatic invasion was more common in cancers presenting as a mass with calcifications.

To find a better imaging screening tool for breast cancer the present study planned with aim to assess the mammographic and sonographic findings in breast cancer screening.

### Materials and Methods

The present study was conducted in the Department of Radiology, Nalanda Medical College and Hospital, Patna, Bihar, India from October 2020 to July 2021. Breast lesions were detected by clinical breast examination, mammography and ultrasound. A total of 200 breast lesions were examined by histological methodology. Final histologic diagnosis was obtained for all patients who underwent surgical biopsy, and all cases were verified by reviewing the histopathology report. Histopathology results revealed the presence of 96 invasive cancers and 104 benign lesions.

#### Anamnesis

To each patient, detailed history was taken including: Age at first childbearing, age at menarche, age at menopause, history of breastfeeding, number of children, history of hormone therapy, a history of pre-menopausal breast cancer for a mother and a sister, a personal history of breast cancer or benign proliferative breast disease, radiation, chemical exposure and smoking. The protocol of diagnosis consisted of clinical breast examination, ultrasound, mammography and histopathological examination.

#### Physical examination

Clinical breast examination of the whole breasts and axillary's regions was performed with the patient in the sitting position with arms both lowered and raised. In an upright position, we visually inspect the breasts, noting asymmetry, nipple discharge, obvious masses, and skin changes, such as dimpling, inflammation, rashes, and unilateral nipple retraction or inversion. With the patient supine and one arm raised, we thoroughly palpate breast tissue, axillary's region and supraclavicular area, assessing the size, texture, and location of any masses. After the patient history is obtained and the clinical breast examination is performed, the next diagnostic step was mammography, ultrasound and biopsy.

#### Mammography

Conventional film-screen mammography was performed with at least two views per breast, medio-lateral oblique and cranio-caudal views. Additional views or spot compression views were obtained where appropriate. Mammograms were obtained with dedicated mammography units (Allenger). Patient younger than 30 years were excluded because mammography was not performed in this age group. Mammograms were interpreted according to the Breast Imaging Reporting and Data system (BI-RADS) diagnostic categories on a five-point scale, with BI-RADS 1 (negative), 2 (benign finding), 3 (probably benign), 4 (suspicious abnormality), and 5 (highly suggestive of malignancy). Breast density grades were also determined according to the BI-RADS on a scale of 1-4, with 4 corresponding to a dense breast, 3 to a heterogeneous breast, 2 to scattered fibro glandular densities and 1 to an almost entirely fat breast (8).

#### Breast Ultrasound

The radiologist who had performed the physical examination and who had interpreted the mammograms of that patient performed breast ultrasound. Ultrasound examinations were performed using a high-resolution unit (Logic P3 GE) with a linear array probe centred at 7, 5 MHz. All ultrasound examinations were performed with the patient in a supine position for the medial parts of the breast and in a contra lateral posterior oblique position with arms raised for the lateral parts of the breast. The whole breasts were scanned. Diagnoses were scored on a five-point scale identical to the mammographic BI-RADS categories. [17]

#### Histopathological examination

#### Therapy

Treatment of patient with breast cancer was based on a multimodality approach combining surgery, radiation therapy hormonal therapy and/or chemotherapy. Treatment is tailored for an individual patient based on tumor size, axillary lymph node involvement, estrogens and progesterone status, histologic tumour type, standardized pathologic grade, and menopausal status. Lumpectomy or wide local excision was performed for patient with benign tumour.

#### Statistical Analysis

$\chi^2$  test, and student t-test were used for statistical data processing. The significance of differences observed was assessed using Pearson's chi-square test, with  $p < 0,01$  considering to be statistically significant.

#### Results

**Table 1: Age distribution**

Age groups in years	Benign	Malignant	Total	%
30-39	10	12	22	11
40-49	24	20	44	22
50-59	26	26	52	26
60-69	22	22	44	22
70-79	22	16	38	19
Total	104	96	200	100

A total of 200 breast lesions were examined by histological method, revealing the presence of 96 invasive cancers, and 104 benign lesions. The mean age of the patient was 58 years, ranging from 31 to 78 years. Most of the patients belonged to 50-59 years.

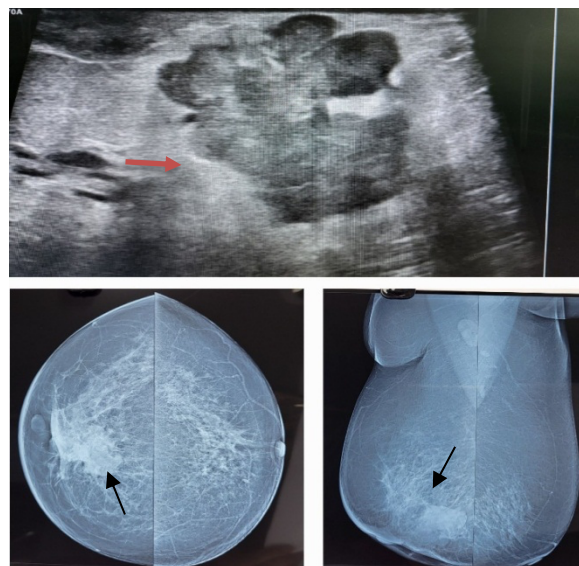
**Table 2: Histological types of cancer**

Histological types of cancer	N
Ductal carcinoma	50
Lobular carcinoma	10
Mixed ductal/lobular Carcinoma	20
Mucinous carcinoma	2
Medullary carcinoma	2
Tubular carcinoma	2
Total	96

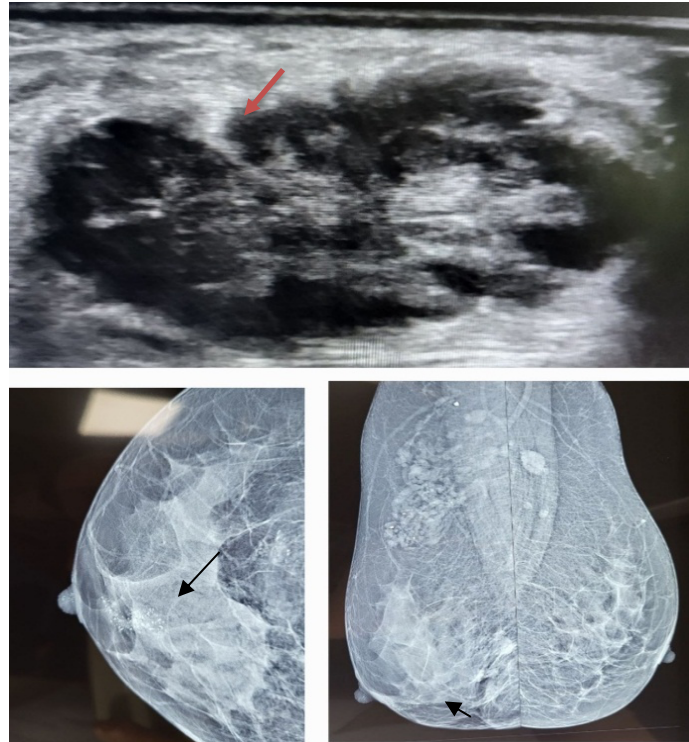
The histological types of cancer in 96 patients were: invasive ductal, invasive lobular, mixed (ductal/lobular) tubular, medullary, mucinous.

**Table 3: Correlation between mammography and ultrasound for malignant and benign lesions**

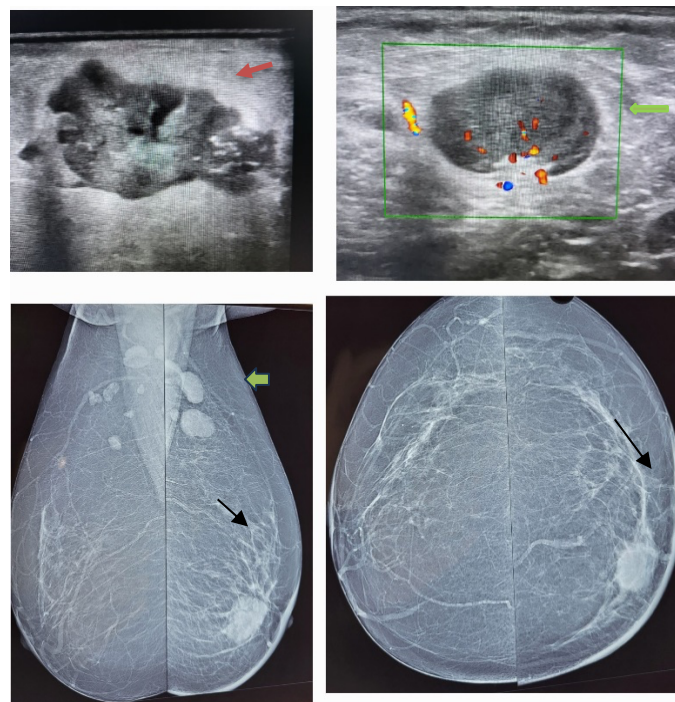
Malignant lesions	Ultrasound		Total
	Positive	Negative	
<b>Mammography</b>			
Positive	44	6	50
Negative	26	20	46
Total	70	26	96
Benign lesions	Ultrasound		Total
	Positive	Negative	
<b>Mammography</b>			
Positive	70	4	74
Negative	20	10	30
Total	90	14	104



**Figure 1:- Breast carcinoma in lower inner quadrant of right breast on mammography and ultrasound**



**Figure 1:- Breast carcinoma with internal microcalcifications in lower inner quadrant of right breast on mammography and ultrasound**



**Figure 2:- Breast carcinoma in left breast with ipsilateral axillary lymph nodal metastasis on mammography and ultrasound**

Mammography was false negative in 44 out of 96 invasive cancers; ultrasound was false negative in 26 out of 96 cancers. Mammography was false negative in 30 out of 104 patients without cancer; ultrasound was false negative in 14 out of 104 patients without cancer.

**Discussion**

Excluding cancers of the skin, breast cancer is the most common type of cancer in women today, accounting for 1 of every 3 cancers diagnosed. A woman’s chance of developing invasive breast cancer at some time in her life is approximately 1 in

8 (12%). It is one of the leading causes of cancer mortality among women (3). Breast cancer is a heterogeneous disease with no single characterized cause. Epidemiological studies have identified many risk factors that increase the chance for a woman to develop breast cancer. Important risk factors for female breast cancer include early age at onset of menarche, late age at onset of menopause, a first full-term pregnancy after the age of 30 years, a history of premenopausal breast cancer for a mother and a sister, and a personal history of breast cancer or benign proliferative breast disease. Obesity, nulliparity, and urban residence have also been associated with an increased risk of breast cancer. Mammography plays a major role in early detection of breast cancers, detecting about 75% of cancers at least a year before they can be felt. There are 2 types of mammography examinations: screening and diagnostic. [18]

Screening mammography is done in asymptomatic women. Early detection of small breast cancers by screening mammography greatly improves a woman's chances for successful treatment. Screening mammography is recommended every 1-2 years for women once they reach 40 years of age and every year once they reach 50 years of age. In some instances, physicians may recommend beginning screening mammography before age 40 if the woman has a strong family history of breast cancer. Studies have shown that regular mammograms may decrease the risk of late-stage breast cancer in women 80 years of age and older. [19,20] A total of 200 breast lesions were examined by histological method, revealing the presence of 96 invasive cancers, and 104 benign lesions. The mean age of the patient was 58 years, ranging from 31 to 78 years. [21,22]

Women who present with breast symptoms or who have palpable findings on clinical examination are usually investigated with breast imaging, which generally consists of mammography or breast ultrasound or both. The choice of primary breast imaging in examining women with symptoms is partly based on age. However, despite the importance of age in clinical practice, little evidence exists as to the appropriate age that delineates the choice of initial diagnostic breast imaging in symptomatic women. In the absence of evidence, experts suggest that women younger than 35 years be examined with ultrasound, and women 35 years and older be examined with mammography, as the primary breast imaging modality. Most of the patients belonged to 50-59 years. The histological types of cancer in 96 patients were: invasive ductal, invasive lobular, mixed (ductal/lobular) tubular, medullary, mucinous. Mammography was false negative in 44 out of 96 invasive cancers; ultrasound was false negative in 26 out of 96 cancers. Mammography was false negative in 30 out of 104

patients without cancer; ultrasound was false negative in 14 out of 104 patients without cancer. Overall, the difference in the sensitivity of the two tests in all subjects is statistically significant. However, in women 45 years or younger, ultrasound has a significantly greater sensitivity than mammography. Our study also shows that there is difference in the specificity of the two imaging tests, ultrasound has a significantly greater specificity than mammography. This fact may explain the different findings in published studies, with some reporting a greater specificity for ultrasound than for mammography. [23-25]

### Conclusion

Breast ultrasound is more accurate than mammography in symptomatic women 45 years or younger, mammography has progressive improvement in sensitivity in women 60 years or older. The accuracy of mammograms increased as women's breasts became fattier and less dense. In young women and women with dense breasts, ultrasound appears superior to mammography, and may be an appropriate initial imaging test in those women.

### References

1. Kumar JU, Sreekanth V, Reddy HR, Sridhar AB, Kodali N, Prabhu AS. Screening Mammography: A Pilot Study on Its Pertinence in Indian Population by Means of a Camp. *J Clin Diagn Res.* 2017 Aug;11(8): TC 29-TC32.
2. Carter CL, Allen C, Henson DE. Relation of tumor size, lymph node status, and survival in 24,740 breast cancer cases. *Cancer.* 1989 Jan 1;63(1):181-7.
3. Sundquist M, Thorstenson S, Brudin L, Nordenskjöld B. Applying the Nottingham Prognostic Index to a Swedish breast cancer population. South East Swedish Breast Cancer Study Group. *Breast Cancer Res Treat.* 1999 Jan;53(1):1-8.
4. Elston CW, Ellis IO. Pathological prognostic factors in breast cancer. I. The value of histological grade in breast cancer: experience from a large study with long-term follow-up. *Histopathology.* 1991 Nov;19(5):403-10.
5. Neville AM, Bettelheim R, Gelber RD, Säv-Söderbergh J, Davis BW, Reed R, Torhorst J, Golouh R, Peterson HF, Price KN, et al. Factors predicting treatment responsiveness and prognosis in node-negative breast cancer. The International (Ludwig) Breast Cancer Study Group. *J Clin Oncol.* 1992 May;10(5):696-705.
6. Nasser IA, Lee AK, Bosari S, Saganich R, Heatley G, Silverman ML. Occult axillary lymph node metastases in "node-negative" breast carcinoma. *Hum Pathol.* 1993 Sep;24(9):950-7.

7. Blamey RW, Ellis IO, Pinder SE, Lee AH, Macmillan RD, Morgan DA, Robertson JF, Mitchell MJ, Ball GR, Haybittle JL, Elston CW. Survival of invasive breast cancer according to the Nottingham Prognostic Index in cases diagnosed in 1990-1999. *Eur J Cancer*. 2007 Jul;43(10):1548-55.
8. Balslev I, Axelsson CK, Zedeler K, Rasmussen BB, Carstensen B, Mouridsen HT. The Nottingham Prognostic Index applied to 9,149 patients from the studies of the Danish Breast Cancer Cooperative Group (DBCG). *Breast Cancer Res Treat*. 1994;32(3):281-90.
9. Volpi A, De Paola F, Nanni O, Granato AM, Bajorko P, Becciolini A, Scarpi E, Riccobon A, Balzi M, Amadori D. Prognostic significance of biologic markers in node-negative breast cancer patients: a prospective study. *Breast Cancer Res Treat*. 2000 Oct;63 (3):181-92.
10. Héry M, Delozier T, Ramaioli A, Julien JP, de Lafontan B, Petit T, de Ghislain C, Weber B, Bonnetterre J, Teissier E. Natural history of node-negative breast cancer: are conventional prognostic factors predictors of time to relapse? *Breast*. 2002 Oct;11(5):442-8.
11. Lauria R, Perrone F, Carlomagno C, De Laurentiis M, Morabito A, Gallo C, Varriale E, Pettinato G, Panico L, Petrella G, et al. The prognostic value of lymphatic and blood vessel invasion in operable breast cancer. *Cancer*. 1995 Nov 15;76(10):1772-8.
12. Lee AH, Pinder SE, Macmillan RD, Mitchell M, Ellis IO, Elston CW, Blamey RW. Prognostic value of lymphovascular invasion in women with lymph node negative invasive breast carcinoma. *Eur J Cancer*. 2006 Feb;42 (3):357-62.
13. Sundquist M, Thorstenson S, Klintonberg C, Brudin L, Nordenskjöld B. Indicators of loco-regional recurrence in breast cancer. The South East Swedish Breast Cancer Group. *Eur J Surg Oncol*. 2000 Jun;26(4):357-62.
14. Voogd AC, Nielsen M, Peterse JL, Blichert-Toft M, Bartelink H, Overgaard M, van Tienhoven G, Andersen KW, Sylvester RJ, van Dongen JA; Danish Breast Cancer Cooperative Group. Breast Cancer Cooperative Group of the European Organization for Research and Treatment of Cancer. Differences in risk factors for local and distant recurrence after breast-conserving therapy or mastectomy for stage I and II breast cancer: pooled results of two large European randomized trials. *J Clin Oncol*. 2001 Mar 15;19(6):1688-97.
15. Rosen PP, Groshen S, Saigo PE, Kinne DW, Hellman S. Pathological prognostic factors in stage I (T1N0M0) and stage II (T1N1M0) breast carcinoma: a study of 644 patients with median follow-up of 18 years. *J Clin Oncol*. 1989 Sep;7(9):1239-51.
16. de Mascarel I, Bonichon F, Durand M, Mauriac L, MacGrogan G, Soubeyran I, Picot V, Avril A, Coindre JM, Trojani M. Obvious peritumoral emboli: an elusive prognostic factor reappraised. Multivariate analysis of 1320 node-negative breast cancers. *Eur J Cancer*. 1998 Jan;34(1):58-65.
17. Gajdos C, Tartter PI, Bleiweiss IJ, Hermann G, de Csepe J, Estabrook A, Rademaker AW. Mammographic appearance of nonpalpable breast cancer reflects pathologic characteristics. *Ann Surg*. 2002 Feb;235(2): 246-51.
18. American College of Radiology. Illustrated Breast Imaging Reporting and Data System (BI-RADS) 3rd ed. Reston, V.A: American College of Radiology; 1998.
19. American Cancer Society. Detailed Guide: Breast Cancer What Are the Key Statistics for Breast Cancer? American Cancer Society Cancer Resource.
20. Schonberg MA, Ramanan RA, McCarthy EP, Marcantonio ER. Decision making and counseling around mammography screening for women aged 80 or older. *J Gen Intern Med*. 2006 Sep;21(9):979-85.
21. Badgwell BD, Giordano SH, Duan ZZ, Fang S, Bedrosian I, Kuerer HM, Singletary SE, Hunt KK, Hortobagyi GN, Babiera G. Mammography before diagnosis among women age 80 years and older with breast cancer. *J Clin Oncol*. 2008 May 20;26(15):2482-8.
22. Dixon J.M, Mansel R.E. In: Symptoms, assessment, and guidelines for referral. ABC of breast diseases. 2nd ed. Dixon J.M, editor. London: BMJ; 2000. pp. 3-7.
23. Zonderland HM. The role of ultrasound in the diagnosis of breast cancer. *Semin Ultrasound CT MR*. Aug. 2000;21(4):317-324.
24. Kaplan S.S. Clinical utility of bilateral whole-breast US in the evaluation of women with dense breast tissue. *Radiology*. 2001
25. Kolb T.M, Lichy J, Newhouse J.H. Comparison of the performance of screening mammography, physical examination, and breast US and evaluation of factors that influence them: an analysis of 27,825 patient evaluations. *Radiology*. 2002;225(1):165-175.