

## A Hospital Based Study to Evaluate the Correlation of Ultrasound with X-Ray for Determining the Amount of Aspirated Effusion and Evaluate Pleural Effusion

Saumitra Barthwal<sup>1</sup>, Isha Saini<sup>2</sup>, Amisha Patel<sup>3</sup>

<sup>1</sup>Senior Resident, Department of Radiodiagnosis, SGRRIMHS and Shri Mahant Indiresht Hospital, Dehradun, India

<sup>2</sup>Senior Resident, Department of Radiodiagnosis, SGRRIMHS and Shri Mahant Indiresht Hospital, Dehradun, India

<sup>3</sup>Assistant Professor, Department of Radiodiagnosis, SGRRIMHS and Shri Mahant Indiresht Hospital, Dehradun, India

---

Received: 10-12-2023 Revised: 15-01-2024. Accepted: 22-02-2024

Corresponding author: Dr Saumitra Barthwal

Conflict of interest: Nil

---

### Abstract

**Aim:** The aim of the present study was to evaluate the correlation of ultrasound with chest radiographs for determining the amount of aspirated effusion and evaluate pleural effusion.

**Methods:** The present study was conducted at SGRRIMHS and Shri Mahant Indiresht Hospital, Dehradun, India from June 2022-Oct 2023. The source of data for this study includes total 50 patients referred to the department of Radio- Diagnosis and Imaging for chest radiography and ultrasonography from OPD/IPD/ED of SGRRIMHS and Shri Mahant Indiresht Hospital, Dehradun, India

**Results:** In this prospective study 50 patients were included, out of which 31 (62%) were male and 19 (38%) were female, the average age of patient were 37.3 years. In this study we included only those patients who underwent both x-ray as well as USG to identify pleural effusion. Results from USG showed 25 (50%) males and 9 (18%) females had pleural effusion in right lung whereas 10 (20%) females and 6 (12%) males had pleural effusion in left lung. In x-ray images 20 (40%) males and 9 (18%) females showed pleural effusion in right lung and 11 (22%) female, 10 (20%) males had effusion in their left lung. For right lung minimum volume of fluid was 36.4 ml and maximum volume was 340 mL whereas the average volume was 93.98 mL. In left lung minimum 36.4 ml of fluid was detected and maximum recorded volume was 220.2 mL and average volume recorded was 60.1 mL. Average volume of effusion in male was 35.50 mL in left lung and 120.40 mL in right lung. In female average effusion in right lung was 102.90 mL and in left lung was 64.36 mL.

**Conclusion:** USG is some distance superior than simple X-Ray in locating of minimal pleural & also for quantification of pleural effusion. Furthermore, interventions like pleural faucet can also done. USG can locate low amount of fluid presence even less than 3 ml, while X- ray fails to help diagnose such low quantity of fluid.

**Keywords:** ultrasonography, pleural effusion, pleural cavity, inflammation

---

This is an Open Access article that uses a funding model which does not charge readers or their institutions for access and distributed under the terms of the Creative Commons Attribution License (<http://creativecommons.org/licenses/by/4.0>) and the Budapest Open Access Initiative (<http://www.budapestopenaccessinitiative.org/read>), which permit unrestricted use, distribution, and reproduction in any medium, provided original work is properly credited.

---

### Introduction

Several medical conditions are responsible for pleural effusion (PLEFF), with volume overload, congestive heart failure, and pleuropulmonary infection representing the most common causes in the intensive care unit (ICU). [1] Fluid accumulation can take place due to an imbalance of hydrostatic and oncotic pressure across the lung capillaries, increased pleural membrane capillary permeability, and lymphatic obstruction. [2] Furthermore, the factors known to promote lung edema formation in the clinical setting (fluid loading, myocardial depression, hypoalbuminemia) usually coexist, and may exceed the normally high absorptive capacity of

the lungs and parietal pleural lymphatics, resulting in exacerbation of PLEFF.

PLEFF occurs frequently in ICU patients with an incidence that varies according to the diagnostic technique used (from 8% following physical examination to more than 60% after routine imaging). [3,4] It is also associated with a high crude mortality rate. [5] Indeed, PLEFF can worsen gas exchange, hemodynamic stability, and respiratory dynamics. Drainage can improve oxygenation, respiratory mechanics, and compliance by enhancing the ventilation: perfusion ratio and by re-

expanding areas of collapsed parenchymal lung. [6,7] Although percutaneous pleural drain insertion is frequently carried out in the ICU, inaccurate insertion of the tube can have tragic consequences. [8,9] Complications with the insertion of chest drains have been reported in up to 20–30% of cases; some of these complications can be potentially fatal (i.e., perforation of the lung, heart, liver, esophagus, spleen, and inferior vena cava). [10]

Compared to radiography, ultrasonography has the advantage of being non-invasive, cost-effective, readily available, and repeatable. It is also radiation-free. Furthermore, chest ultrasonography shows better sensitivity and reliability than radiography. [11,12] While a minimum of 150 mL is required to detect effusion by radiography in the erect position [13], effusions as small as 5 mL can be detected ultrasonographically with 100% sensitivity. [14] Pleural effusion is frequently managed by thoracentesis. Sometimes, the actual amount of effusion is at variance with the clinical presentation, and it is doubtful whether to drain. The ideal ultrasonographic formula for pleural effusion volume estimation should be simple, accurate, and rapidly/easily performed.

The aim of the present study was to evaluate the correlation of ultrasound with X-Ray for determining the amount of aspirated effusion and evaluate pleural effusion.

**Materials and Methods**

The present study was conducted at SGRRIMHS and Shri Mahant Indires Hospital, Dehradun, India from June 2022-Oct 2023. The source of data for this study includes total 50 patients referred to department of Radio- Diagnosis Imaging for chest radiography and ultrasonography from OPD/IPD/ED of SGRR Medical College, Dehradun, India.

**Inclusion Criteria**

- All the Patient with post-diagnosed of pleural effusion, All the patient IPD & OPD, both male & female patient were included, No age limitation

**Exclusion Criteria**

- Pregnancy, those patients who were not diagnosed with pleural effusion

After performing X Ray chest, in case of any doubt of Pleural effusion, the USG Chest was performed and vice versa.

**Statistical Analysis**

The data were analyzed using SPSS ver. 20 for Windows (IBM Corp., Armonk, NY, USA). Pearson correlation analysis was performed to determine the extent of correlation between ultrasonographically estimated effusion volumes and the actual volume drained.

**Results**

**Table 1: Demographic details**

Gender	N%
Male	31 (62)
Female	19 (38)
<b>Pleural effusion USG Findings</b>	
<b>Male</b>	
Right Lung	25 (50)
Left Lung	6 (12)
<b>Female</b>	
Right Lung	9 (18)
Left Lung	10 (20)
<b>X Ray USG Findings</b>	
<b>Male</b>	
Right Lung	20 (40)
Left Lung	11 (22)
<b>Female</b>	
Right Lung	9 (18)
Left Lung	10 (20)

In this prospective study 50 patients were included, out of which 31 (62%) were male and 19 (38%) were female, the average age of patient were 37.3 years. In this study we included only those patients who

underwent both x-ray as well as USG of chest to identify pleural effusion. Results from USG showed 25 (50%) males and 9 (18%) females had pleural effusion in right lung whereas 10 (20%) females and

6 (12%) males had pleural effusion in left lung. In x-ray images 20 (40%) males and 9 (18%) females showed pleural effusion in right lung and 11 (22%)

female, 10 (20%) males had effusion in their left lung.

**Table 2: Comparison pleural effusion between male and female**

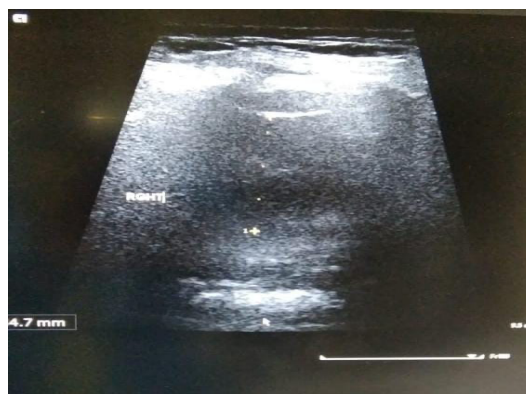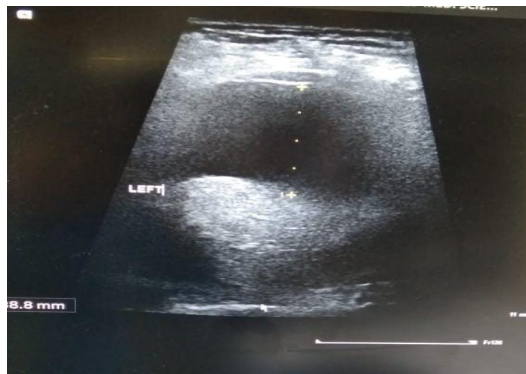Male		Female	
Right Lung	Left Lung	Right Lung	Left Lung
46	0	0	36.4
102	60	0	183.7
0	43.7	0	210
340	0	220	0
105.5	220.2	0	186
160	0	175	0
0	55.7	46.4	108.2
350	0		
36.4	46		
0	43		
180	0		
100	0		
112.8	0		

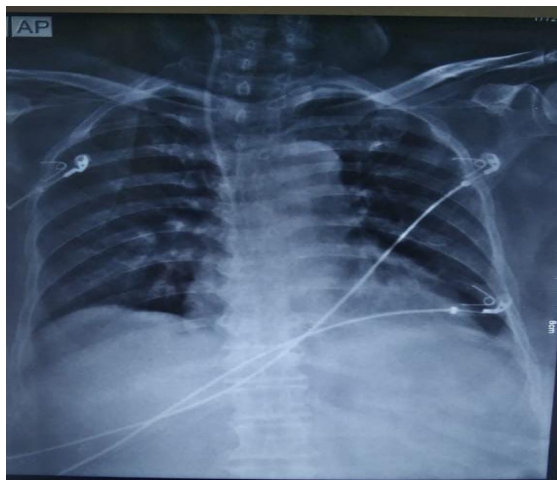
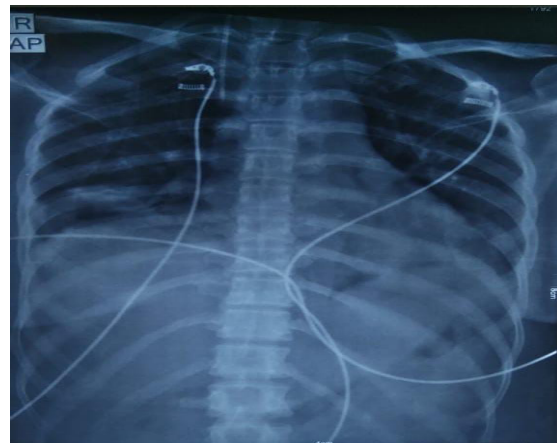
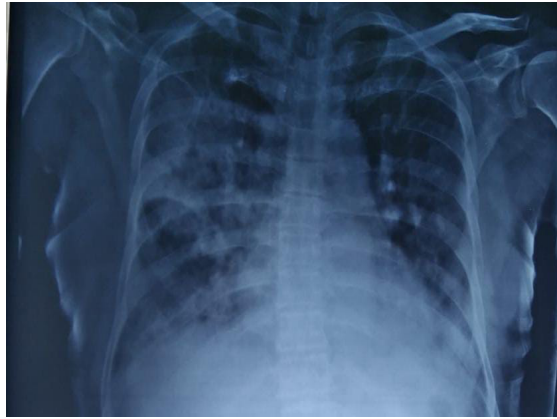For right lung minimum volume of fluid level was 36.4 ml and maximum volume was 340 mL, the average volume was 93.98 mL. In left lung minimum 36.4 ml of fluid was detected and maximum recorded was 220.2 mL with average volume recorded 60.1 mL.

**Table 3: Average of Plueral Effusion between male and female**

Gender	Right Lung	Left Lung
Male	120.40	35.50
Female	64.36	102.90

Average volume of effusion in male was 35.50 in left lung and in right lung were 120.40. In female average effusion in right lung were 102.90 and in left was 64.36 mL.





### Discussion

Pleural effusions are most commonly associated with heart failure, pneumonia, cancer, pulmonary embolism, viral disease, coronary artery bypass surgery, and cirrhosis with ascites. The most common symptoms related to pleural effusion are nonspecific and often indistinguishable from those of the underlying disease process, including cough, dyspnea, and pleuritic chest pain. [15] Chest radiography has traditionally been used to diagnose pleural effusions. Free-flowing pleural fluid collects in the most dependent portions of the thorax, initially in the subpulmonic space followed by the

costophrenic recesses. Pleural fluid is detectable in the costophrenic recesses on lateral upright chest radiograph after 50 mL has accumulated. In this prospective study 50 patients were included, out of which 31 (62%) were male and 19 (38%) were female, the average age of patient were 37.3 years. In this study we included only those patients who undergo for both scan x-ray as well as USG for identify the pleural effusion. Results from USG showed 25 (50%) male and 9 (18%) females had pleural effusion in right lung whereas 10 (20%) female and 6 (12%) males had pleural effusion in left lung. In x-ray images 20 (40%) males and 9 (18%) females showed pleural effusion in right lung and 11

(22%) female, 10 (20%) males had effusion in their left lung. On standard posterior-anterior chest radiograph, blunting of the costophrenic recesses and obliteration of the hemidiaphragm are seen when >200 mL and >500 mL of pleural fluid have accumulated, respectively. [16] However, upright chest radiographs can miss a considerable number of effusions, including as many as 10% of parapneumonic effusions large enough to indicate need for drainage. [17] Supine anterior-posterior chest radiographs can miss a significant proportion of large effusions seen on chest CT, [18] ultrasound, [19] and lateral decubitus radiographs. [20] Pleural effusions are frequently mistaken for parenchymal opacities on portable anterior-posterior chest radiographs. [18]

For right lung minimum volume of fluid level 36.4 ml and 340 mL was maximum volume and the average volume was 93.98 mL. In left lung minimum 36.4 ml of fluid was detected and maximum recorded was 220.2 mL and average volume recorded is 60.1 mL. The effective management of pleural effusion requires early recognition, some form of volume estimation, and identification of the underlying etiology. [21] The clinical diagnosis is often difficult when the amount of effusion is relatively small or when there is underlying lung consolidation, making it expedient to obtain radiological evidence. Eibenberger et al. [22] reported a significant and high correlation ( $r=0.80$ ) between the actual volume drained and the ultrasonographic estimates they derived using the supine 1 formula. Contrary to their findings, that formula yielded  $r=0.62$  in this study. Mathis [22] observed that the deviations of the estimated volume from the real volume could be considerable with this formula (supine 1). Its limitations include the fact that the same volume of pleural fluid in individuals with different-sized thoracic/pleural cavities tends to be underestimated in the larger thoracic cavities and vice versa. Similarly, diaphragmatic elevation affects the estimated effusion volume. [22] The other recognized limitation of the supine 1 formula is the effect of the lung parenchymal status on the shape of the pleural fluid. A poorly aerated/collapsed lower lobe will likely displace underlying pleural fluid, thus yielding an estimated volume smaller than the actual volume. [22]

Average volume of effusion in male was 35.50 in left lung and in right lung were 120.40. In female average effusion in right lung were 102.90 and in left was 64.36 mL. A transudate pleural effusion as a result of imbalanced hydrostatic or oncotic strain. He most common causes are: coronary heart failure, cease stage kidney sickness, peritoneal dialysis and myxoedema. An exudate pleural effusion occurs when there may be an inflammation which purpose endothelium to grow to be leakier and allow free passage of lymphatic fluid. The most commonplace

reasons are: bacterial pneumonia, viral contamination, pulmonary embolism and T.B. [23]

Because fluid is reliant and accumulates posteriorly, a chest radiograph taken in the supine position can detect a large amount of fluid with few imaging changes. Because a veil-like increased density of the hemithorax may be seen, identifying similar-sized bilateral effusion is difficult because the densities of the lungs will be similar. USG can detect a little quantity of fluid (3-5 ml) that would be missed by a radiograph. Radiography's sensitivity is defined as the ability to detect a minimum of 50 mL of fluid. The USG examination of a patient in a sitting posture is preferable because it allows for more exact pleural effusion quantification. The free fluid is collected in the dependent space in this position, whereas it is located in a posterior region with the patient in a supine position. The difference between Loculated pleural fluid and Thickened pleura may be easily distinguished using ultrasound. It enables for the recognition of nearby structures such as the chest wall, hemidiaphragm, and visceral pleural surface. Pleural fluid is generally hypo echoic (darker) when compared to the isochoric reference of the liver and spleen, while air-filled lung is hyper echoic (brighter). Ultrasound is clearly more sensitive than a lateral Decubitus chest radiograph for detecting pleural effusions, and when compared to chest X-ray, Ultrasound of the chest has been reported to have "95 percent sensitivity for detecting pleural lesions in Patients with a white out" on chest Radiography. Loculated Pleural Fluid and Thickened Pleura are easily distinguished using ultrasound. Even with little fluid collections, it is effective in guiding thoracentesis. [24]

### Conclusion

USG is some distance superior than simple X-Ray in locating of minimal pleural & also for quantification of pleural effusion. Furthermore, intervention like pleural faucet can also be done. USG can locate low amount of fluid presence even less than 3 ml, while X-ray fails to help diagnose such low quantity of fluid.

### References

1. aslove DM, Chen BT, Wang H, Kushner WG. The diagnosis and management of pleural effusions in the ICU. *J Intensive Care Med.* 2013;28(1):24–36.
2. Graf J. Pleural effusion in the mechanically ventilated patient. *Curr Opin Crit Care.* 2009;15(1):10–7.
3. Mattison LE, Coppage L, Alderman DF, Herlong JO, Sahn SA. Pleural effusions in the medical ICU: prevalence, causes, and clinical implications. *Chest.* 1997;111(4):1018–23.
4. Fartoukh M, Azoulay E, Galliot R, Le Gall JR, Baud F, Chevret S, Schlemmer B. Clinically documented pleural effusions in medical ICU

- patients: how useful is routine thoracentesis? *Chest*. 2002;121(1):178–84.
5. Azoulay E. Pleural effusions in the intensive care unit. *Curr Opin Pulm Med*. 2003; 9(4):291–7.
  6. Goligher EC, Leis JA, Fowler RA, Pinto R, Adhikari NK, Ferguson ND. Utility and safety of draining pleural effusions in mechanically ventilated patients: a systematic review and meta-analysis. *Crit Care (London, England)*. 2011;15(1):R46.
  7. Cartaxo AM, Vargas FS, Salge JM, Marcondes BF, Genofre EH, Antonangelo L, Marchi E, Teixeira LR. Improvements in the 6-min walk test and spirometry following thoracentesis for symptomatic pleural effusions. *Chest*. 2011; 139(6):1424–9.
  8. Kopec SE, Conlan AA, Irwin RS. Perforation of the right ventricle: a complication of blind placement of a chest tube into the postpneumectomy space. *Chest*. 1998;114(4):1213–5.
  9. Bozzani A, Arici V, Bellinzona G, Pirrelli S, Forni E, Odero A. Iatrogenic pulmonary artery rupture due to chest-tube insertion. *Tex Heart Inst J*. 2010;37(6):732–3.
  10. Harris A, O'Driscoll BR, Turkington PM. Survey of major complications of intercostal chest drain insertion in the UK. *Postgrad Med J*. 2010;86(1012):68–72. Blackmore CC, Black WC, Dallas RV, Crow HC. Pleural fluid volume estimation: a chest radiograph prediction rule. *Acad Radiol*. 1996; 3(2):103–109.
  11. Eibenberger KL, Dock WI, Ammann ME, Dorffner R, Hörmann MF, Grabenwöger F. Quantification of pleural effusions: sonography versus radiography. *Radiology*. 1994 Jun;191(3):681–4.
  12. Azoulay E. Pleural effusions in the intensive care unit. *Curr Opin Pulm Med* 2003;9:291–297.
  13. Collins JD, Burwell D, Furmanski S, Lorber P, Steckel RJ. Minimal detectable pleural effusions: a roentgen pathology model. *Radiology*. 1972 Oct;105(1):51–3.
  14. Qureshi NR, Rahman NM, Gleeson FV. Thoracic ultrasound in the diagnosis of malignant pleural effusion. *Thorax*. 2009 Feb 1;64(2):139–43.
  15. Light RW. *Pleural diseases*. 6th ed. Philadelphia, PA: Lippincott Williams & Wilkins, 2013.
  16. Brixey AG, Luo Y, Skouras V, Awdankiewicz A, Light RW. The efficacy of chest radiographs in detecting parapneumonic effusions. *Respirology*. 2011;16(6):1000–1004.
  17. Kitazono MT, Lau CT, Parada AN, Renjen P, Miller WT Jr. Differentiation of pleural effusions from parenchymal opacities: accuracy of bedside chest radiography. *AJR Am J Roentgenol*. 2010;194(2):407–412.
  18. Emamian SA, Kaasbol MA, Olsen JF, Pedersen JF. Accuracy of the diagnosis of pleural effusion on supine chest X-ray. *Eur Radiol*. 1997; 7(1):57–60.
  19. Ruskin JA, Gurney JW, Thorsen MK, Goodman LR. Detection of pleural effusions on supine chest radiographs. *AJR Am J Roentgenol*. 1987;148(4):681–683.
  20. Oguntoyinbo AE, Adeoye PO, Rahman GA, Abdulkadir AY. Radiological And Clinical Pattern Of Pleural Effusion In Ilorin. *Chest*. 2008;4:5.
  21. Eibenberger KL, Dock WI, Ammann ME, Dorffner R, Hörmann MF, Grabenwöger F. Quantification of pleural effusions: sonography versus radiography. *Radiology*. 1994 Jun;191(3):681–4.
  22. Mathis G. Pleura. In: Mathis G, ed. *Chest sonography*. 3rd ed. Heidelberg: Springer-Verlag, 2011;30–32.
  23. D'Agostino HP, Edens MA. Physiology, pleural fluid. In: StatPearls [Internet]. 2021 Sep 1. StatPearls Publishing.
  24. McLoud TC, Flower CD. "Imaging the pleura: sonography, CT, and MR imaging." *AJR. American journal of roentgenology*, 1991;156(6):1145–1153.