

A Morphometric Assessment of Renal Vein to Observe the Variations in Renal Vein

Archana Kumari¹, Shishir Kumar², Kumari Suman³, Birendra Kumar Sinha⁴

¹Tutor, Department of Anatomy, Patna Medical College, Patna, Bihar, India

²Professor, Department of Community Medicine, ESIC Medical College, Bihta, Patna, Bihar, India

³Tutor, Department of Anatomy, Patna Medical College, Patna, Bihar, India

⁴Professor and HOD, Department of Anatomy, Patna Medical College, Patna, Bihar, India

Received: 14-03-2024 / Revised: 12-04-2024 / Accepted: 20-05-2024

Corresponding Author: Dr. Shishir Kumar

Conflict Of Interest: Nil

Abstract

Aim: The aim of the present study was to study the variability in morphology of the renal vein and to measure length of renal vein and to observe the variations in renal vein.

Methods: The dissection was done in 30 embalmed cadavers in the Department of Anatomy, Patna Medical College, Patna, Bihar, India for seven months. They included 20 male and 10 female cadavers. They were collected from the dissection hall of department of Human Anatomy of various medical colleges.

Results: Tributaries that emerge from the kidney and join to form renal vein are called primary tributaries. These were present in 9 in right and 12 in left specimens. Statistically significant association was not found between presence of primary tributary of renal vein and side. Statistically significant difference found between length of renal vein of right and left side. Average length was more on left side (62.44 mm) than that of right side (26.98 mm).

Conclusion: Detailed knowledge of variations of these vessels will definitely improve outcome of various urological, renal transplantation and laparoscopic surgeries. This knowledge will be of immense help to radiologists and oncologists who are dealing with this region. Also, a detailed knowledge and understanding of major congenital anomalies of the renal veins variations will provides safety guidelines for endovascular procedures.

Keywords: Renal vein, Tributaries, Retro aortic left renal vein

This is an Open Access article that uses a funding model which does not charge readers or their institutions for access and distributed under the terms of the Creative Commons Attribution License (<http://creativecommons.org/licenses/by/4.0>) and the Budapest Open Access Initiative (<http://www.budapestopenaccessinitiative.org/read>), which permit unrestricted use, distribution, and reproduction in any medium, provided original work is properly credited.

Introduction

Renal arteries are a pair of branches arising from the lateral aspect of abdominal aorta. They arise just below the origin of superior mesenteric artery at the level of intervertebral disc between L1 & L2 vertebrae. The renal arteries from embryonic lateral splanchnic arteries. [1] Accessory renal arteries represent persistence of embryonic vessels that normally disappear when the definitive renal arteries are formed. Accessory renal veins usually be noticed during surgery or during dissection of cadaver.

Developmentally, bilateral cardinal venous system and associated venous channels becomes unilateral right sided Inferior vena cava around 8Th week of development. Primarily two renal veins present on both sides as ventral and dorsal plane, later union of both tributaries results in the single vessel formation where as its persistence leads to the existence of accessory renal veins. [2] Normally left renal vein passes anterior to aorta on the way to its termination.

Whereas Accessory left renal vein or retro aortic left renal vein is due to persistence of vein posterior to aorta. This appearance is also known as persistence of renal collar or circum aortic renal vein collar. The information about the anatomical variations of renal vessels has major surgical implications. Accessory renal arteries anastomoses with other arteries in kidney were described as early as sixteenth century by Eustachi. [3] Due to complex embryology involved in the development of kidney, there can be a wide range of variations in renal vasculature especially with respect to origin of accessory renal artery. [4]

The renal veins on both sides of the body connect the hila of both kidneys to the inferior vena cava (IVC). The vein on the right side drains only the right kidney, while the vein on the left side drains the left kidney, left gonads, and left suprarenal gland. [5] Similarly, variations in the anatomy of

renal vein is very common due to the complex development of Inferior vena cava & its tributaries. Many a times renal vein variations is a common incidental finding during venography, operation or autopsy. [6] Length of the right renal vein (2.5cm) is three times shorter than left renal vein (7.5cm). [7] Variations in left renal vein is significant in renal transplants, since left kidney is preferred to be transplanted mostly due to the fact that left renal vein is longer than right. [8]

A study by Baptista-Silva et al. [9] found variations in the left renal vein (LRV) and double and triple right renal veins (RRVs). Senecail et al. [10] suggested variations of the LRV may be problematic for clinicians interpreting abdominal imaging scans. Left kidney & left renal artery/ vein is the preferred and favored side for donor nephrectomies to the renal transplant surgeons.. In the present situation, of increasing number of operating procedures like renal transplants, vascular surgery, aneurysm myography, retroperitoneal surgery & other diagnostic interventions, the pre-operative knowledge of renal vascular variations play a very significant role. Similarly, variations in the anatomy of renal vein are very common due to the complex development of Inferior vena cava & its tributaries. Many times renal vein variations are common incidental finding during venography, operation or autopsy. [11] Variations in left renal vein is significant in renal transplants, since left kidney is preferred to be transplanted mostly due to the fact that left renal vein is longer than right. [12]

The aim of the present study was to study the variability in morphology of the renal vein and to measure length of renal vein and to observe the variations in renal vein.

Materials and Methods

The dissection was done in 30 embalmed cadavers in the Department of Anatomy, Patna Medical College, Patna, Bihar, India for seven months. They included 20 male and 10 female cadavers. They were collected from the dissection hall of department of Human Anatomy of various medical colleges.

Each cadaver was kept in supine position. Cadavers were dissected according to guidelines of 'Cunningham's Manual of Practical Anatomy. [13]

1. A midline skin incision from the xiphi sternum to the pubic symphysis, encircling the umbilicus was made. The incision from xiphoid process along costal margin to point on the mid axillary line was made. A skin incision from pubic symphysis to anterior superior iliac spine was made. This was extended posteriorly to a point on the mid axillary line.
2. The skin was reflected from the medial to the lateral aspect in four quadrants towards mid axillary line. Anterior abdominal wall was dissected sequentially. Muscles of the anterior abdominal wall were incised and reflected laterally.
3. Peritoneal cavity was opened and various organs of the abdomen were removed and simultaneously renal vessels and their tributaries and branches were identified. Search was made for any variation. The renal vessels were studied by using simple blunt dissection.
4. All measurements were obtained using a Vernier caliper. Photographed records were made. With the dissection, we liberated the kidney from the fat shell and separated the blood vessels from it towards the large blood vessels.
5. Presence of primary tributaries was noted. These tributaries emerged from kidney and join renal vein. [14]
6. Length of renal vein was measured using Vernier caliper between:
 - a) Point at renal hilum or when extra hilar primary tributaries were present, the point where it joined with renal vein
 - b) Point of entry of renal vein into the inferior vena cava
7. Also any variation in relation to renal vein was looked upon.

Statistical analysis

The collected data regarding length was entered into the Microsoft excel sheet and analyzed statistically by Epo info 7.2.5. Values were reported as in percentage, mean and standard deviation. Statistical analysis of right and left side specimen was carried out by using Fisher Exact Test, T Test, P Value.

Results

Table 1: Number of renal veins having extra hilar primary tributaries

Primary tributaries	Right renal vein N (%)	Left renal vein N (%)	P Value
Present	9 (30)	12 (40)	0.2252
Absent	21 (70)	18 (60)	

Tributaries that emerge from the kidney and join to form renal vein are called primary tributaries. These were present in 9 in right and 12 in left specimens. Statistically significant association was not found between presence of primary tributary of renal vein and side.

Table 2: Measurement of length of renal vein in millimeter

Renal Vein	Maximum Length	Minimum Length	Mean Length	S.D.	P value
Right	46.02	11.17	26.98	2.18	<0.001
Left	76.66	42.16	62.44	2.44	

Statistically significant difference found between length of renal vein of right and left side.

Table 3: Average measurement of range of length of renal vein in millimeter

Average length of right renal vein	26.98
Average length of left renal vein	62.44
Average obsolete difference between two	35.46

Average length was more on left side (62.44 mm) than that of right side (26.98 mm).




Figure 1: An anterior view of an abdomen illustrating measurement of the right renal vein using a vernier caliper (RK- right kidney), RRV- right renal vein, RGV- right gonadal vein, IVC- inferior vena cava, LSRV- left suprarenal vein, LRV- left renal vein)

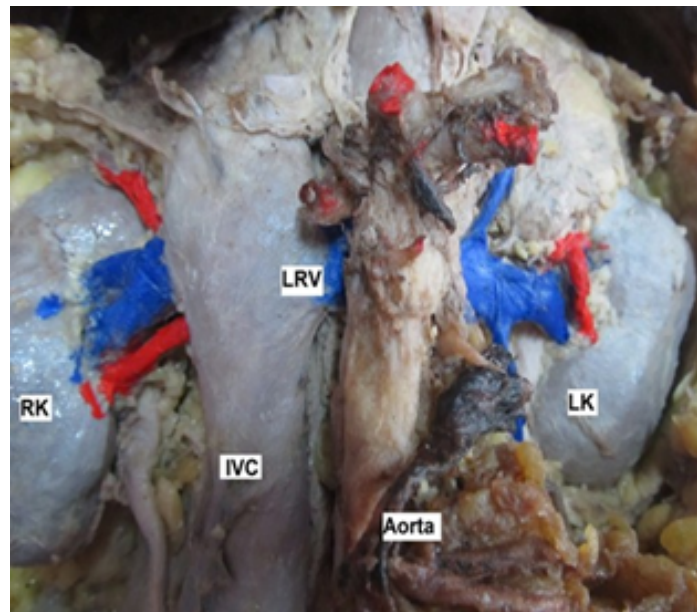


Fig. 2: Anterior view of abdomen showing retro aortic left renal vein (Aorta: abdominal aorta; LRV: left renal vein; RK: right kidney; IVC: inferior vena cava; LK: left kidney)

Discussion

Length of the right renal vein (2.5cm) is three times shorter than left renal vein (7.5cm). [7] The left side anomalies of the renal vein may represent problems

in the interpretation of CT scan, magnetic resonance of abdomen, stated by Senecail et al. [15] Blood supply to kidney is characterised by the presence of variations, both in renal artery and renal vein, which

are significantly predominant in most of the studies. So, a detailed knowledge of the anatomy and variational pattern in the blood supply of kidney is more important in an era of renal transplantations and conservative renal surgeries. The renal arteries are paired arteries which arise from the lateral side of the abdominal aorta. [16] The venous drainage occurs through the paired renal veins which drain into the inferior vena cava. Both these vessels enter through the hilum of the kidney. However, accessory renal vessels if present, may enter the kidney either through the hilum or through the surface of kidney. They may enter either through upper pole or lower pole as polar arteries. [17]

Variations in renal arteries accounts for about 30% of its existence. [16] These variations are classified as accessory or aberrant renal arteries. Accessory renal arteries are additional arteries which pass along with normal renal arteries through the hilum. Aberrant arteries are those which enter the kidney by piercing the substance of the kidney, either through upper pole or lower pole as polar arteries. All these variations can be explained on embryological basis. Tributaries that emerge from the kidney and join to form renal vein are called primary tributaries. These were present in 9 in right and 12 in left specimens. 66% specimens didn't have extra hilar primary tributaries. Statistically significant association was not found between presence of primary tributary of renal vein and side. Statistically significant difference found between length of renal vein of right and left side. Average length was more on left side (62.44 mm) than that of right side (26.98 mm). The common anatomical variations of the renal veins like circum-aortic left renal vein, additional renal veins, retro- aortic, and plexiform left renal vein were observed. The presence of additional renal veins was most common finding. The wide discrepancies of incidence of variations of renal veins were seen in previous studies. Additional veins are observed less commonly on left side than on right side. [18]

Singla et al (2010) stated that the retro aortic left renal vein may be compressed between the lumbar spine and the aorta leading to left renal venous hypertension. [19] The surgical significance of such variants may affect use the long left renal vein for venous reconstruction in hepatic pancreatic surgery and mobilization procedures gets restricted. [20] The accessory or aberrant renal arteries may be important for the clinicians, since they have a vital role to play in causation of hydronephrosis, renal transplantations and in micro vascular surgeries. Variations in renal veins are usually discovered during venography or any operative procedures. Renal arterial variations are more frequently observed than renal veins, which account for about 18% of the cases. [21] Anupama et al., reported various congenital variations of renal veins, in which

the study described about supernumerary renal vein, in which presence of an additional vein arising from the hilum of kidney and draining into inferior vena cava. Out of 30 cadavers which were studied, they described a right side supernumerary renal vein in 10 cases and in only one case, they described a bilateral renal vein variation. [22]

Conclusion

Detailed knowledge of variations of these vessels will definitely improve outcome of various urological, renal transplantation and laparoscopic surgeries. This knowledge will be of immense help to radiologists and oncologists who are dealing with this region. Also, a detailed knowledge and understanding of major congenital anomalies of the renal veins variations will provides safety guidelines for endovascular procedures.

References

1. Susan standing, Neil R Borley and Jeremiah C Healy; Abdomen and pelvis, Abdominal aorta. Gray's Anatomy – The Anatomical Basis of Clinical Practice. 40th Ed. Churchill Livingstone Elsevier; 2008: 1231.
2. Anupama Doddappaiah Panagar, .Lakshmi Prabh Subhash, and D.N.Nagaraj. Circum aortic Left Renal Vein: A Rare Case Report. J Clin Diagn Res. 2014 Mar, 8(3):111-112.
3. Gulas E, Wysiadecki G, Szymański J, Majos A, Stefańczyk L, Topol M, Polguy M. Morphological and clinical aspects of the occurrence of accessory (multiple) renal arteries. Archives of Medical Science. 2018 Mar 1;14(2):442-53.
4. Mohamed A. Bakheit, Mohamed A. Motabagani. Anomalies of the renal, phrenic, suprarenal arteries. Saudi Med J 2004; 25 (3): 376- 378.
5. Petru B, Elena Ş, Dan I, Constantin D. The morphology and the surgical importance of the gonadal arteries originating from the renal artery. Surgical and Radiologic Anatomy. 2007 Jun;29(5):367-71.
6. Sreekanth C, Thyagaraju K, Devi VS. Corresponding Address: Dr. C. Sreekanth, Department of Anatomy, Sri Padmavathi Medical College for women, Tirupati, Andhra Pradesh.
7. Standing S, Harold E, Jeremiah H, Collin P, Wigley C. Gray's anatomy the anatomical basis of clinical practice. 39th ed. India: Churchill Livingstone Elsevier Ltd; 2004.
8. R. Haładaj et al. Circumaortic left renal vein (circumaortic renal collar) associated with the presence of vascular anomalies: a case series and review of literature. Folia Morphol., 2019, Vol. 78, No. 2
9. Baptista-Silva JC, Veríssimo MJ, Castro MJ, Câmara AL, Pestana JO. Anatomical study of

- the renal veins observed during 342 living-donor nephrectomies. Sao Paulo Medical Journal. 1997;115:1456-9.
10. Petru B, Elena Ş, Dan I, Constantin D. The morphology and the surgical importance of the gonadal arteries originating from the renal artery. Surgical and Radiologic Anatomy. 2007 Jun;29(5):367-71.
 11. Sreekanth C, Thyagaraju K, Devi VS. Corresponding Address: Dr. C. Sreekanth, Department of Anatomy, Sri Padmavathi Medical College for women, Tirupati, Andhra Pradesh.
 12. Nayak.B.S. Multiple variations of the right renal vessels. Case Report. Singapore Med J 2008; 49(6): e153C
 13. Romanes GJ. The abdominal cavity. Cunningham's Manual of Practical Anatomy. Thorax and Abdomen.
 14. Satyapal KS, Rambiritch V, Pillai G. Additional renal veins: incidence and morphometry. Clinical Anatomy: The Official Journal of the American Association of Clinical Anatomists and the British Association of Clinical Anatomists. 1995;8(1):51-5.
 15. Senecail B, Bobeuf J, Forlodou P, Nonent M. Two rare anomalies of the left renal vein. Surg Radiol Anat. 2003;25(5-6):465-7.
 16. Rao TR. Aberrant renal arteries and its clinical significance: a case report. International journal of anatomical variations. 2011 Jan 1;4 :37-9.
 17. Saldarriaga B, Pérez AF, Ballesteros LE. A direct anatomical study of additional renal arteries in a Colombian mestizo population. Folia morphologica. 2008;67(2):129-34.
 18. Satyapal KS. Classification of the drainage patterns of the renal veins. Journal of anatomy. 1995 Apr;186(Pt 2):329.
 19. Singla RK, Sharma T, Gupta R. Retro-aortic left renal vein with left suprarenal vein draining into inferior vena cava. IJAV. 2010; 3:134-7.
 20. Loveday BP, Dib MJ, Sequeira S, Alotaiby N, Visser R, Barbas AS, Wei AC, Cleary SP, Moulton CA, Gallinger S, Greig PD. Renal outcomes following left renal vein harvest for venous reconstruction during pancreas and liver surgery. HPB. 2019 Jan 1;21(1):114-20.
 21. FavaroWJ, Santos TD, Cagnon VHA. Venous communication between right and left kidneys. A rare anatomical variation. case report. Int. J. Morphol. 2009; 27(1):117-20.
 22. Anupma Gupta, Raman Gupta, Rikki Singal. Congenital variations of renal veins: Embryological background and clinical implications. Journal of Clinical and Diagnostic Research. 2011; 6:1140-43.