

**Study of Analgesic Efficacy of Bilateral Superficial Cervical Plexus Block Administered Before Thyroid Surgery under General Anesthesia**Joga Sree Durga Naga Sai Hyma<sup>1</sup>, Mallikharjuna Payyavula<sup>2</sup>, Joga Aparna<sup>3</sup><sup>1</sup>Assistant Professor, Department of Anesthesiology, GSL Medical College, Raja nagaram, Rajahmandry, Andhra Pradesh-533296.<sup>2</sup>Associate Professor, Department of Anesthesiology, GSL Medical College, Raja nagaram, Rajahmandry, Andhra Pradesh-533296.<sup>3</sup>Assistant Professor, Department of Anesthesiology, GSL Medical College, Raja nagaram, Rajahmandry, Andhra Pradesh-533296.

Received: 01-09-2025 / Revised: 15-10-2025 / Accepted: 21-11-2025

Corresponding author: Dr. Mallikharjuna Payyavula

Conflict of interest: Nil

**Abstract****Background:** The bilateral superficial cervical plexus block technique is widely used for managing pain after surgery, but the ideal dosage of anesthetic agents has to be administered to control the severity of post-thyroid surgical pain.**Method:** 120 (one hundred twenty) patients were selected for BSCP and divided into three groups and each group consists of 40 patients. Patients in group P received normal saline, group R received Ropivacaine 0.5%; group RC received Ropivacaine 0.5% and clonidine 0.5 mcg/kg. Sufentanil was given during the intraoperative period for a 20% increase in arterial mean pressure or heart rate in patients with a bispectral index between 40 and 60. All patients received 2 gm of acetaminophen during the first 24 hours after surgery. The pain score was checked every 4 hours, and Inj Ketorolac 30 mg (IV) was given to reduce pain scores >4 on a numeric pain scale.**Results:** The comparison of the mean values of demographic characteristics, age, height, and duration of surgery (minutes) remains insignificant ( $p > 0.001$ ) indicates all groups have similar parameters. In the comparison of SBP at the end of resection, incision, and extubation, there was a significant difference among the groups ( $p < 0.001$ ). Regarding rescue analgesic (sufentanil) usage intraoperatively and pain score in PACU - significantly lower values were observed in group RC ( $p < 0.001$ ) which indicates better intra and post-operative analgesia.**Conclusion:** It is proved that group RC (ropivacaine + clonidine) was significantly effective in achieving pain reduction and ideal as anesthetic agents to maintain hemodynamic status.**Keywords:** Visual Analog Scale, Thyroidectomy, Clonidine, Ropivacaine, Post-Anesthesia Care Unit (PACU).This is an Open Access article that uses a funding model which does not charge readers or their institutions for access and distributed under the terms of the Creative Commons Attribution License (<http://creativecommons.org/licenses/by/4.0>) and the Budapest Open Access Initiative (<http://www.budapestopenaccessinitiative.org/read>), which permit unrestricted use, distribution, and reproduction in any medium, provided original work is properly credited.**Introduction**

Thyroid disease is one of the major public health problems in India. Hence, thyroid surgery is one of the most frequently performed surgical procedures. It is also leading endocrine surgery globally [1].

Intra operative and post-operative pain is significant during thyroid surgeries and bilateral superficial cervical plexus block for thyroid is a method to provide perioperative analgesia. It is strongly suggested that pain severity and perception have significant differences among the patients [2].

Acute pain is one of the commonest complaints in the postoperative period, which has serious adverse cardiovascular, pulmonary, metabolic, and psychological outcomes [3]. Pain after thyroid surgery is significant for hours. Bilateral superficial

cervical plexus block is widely used in managing pain after thyroid surgery. It is reported that the block reduces anesthetic requirements and provides prolonged postoperative analgesia [4]. It also decreases rescue analgesic requirement. In contrast, some studies denied the effectiveness of bilateral superficial cervical plexus block (BSCP). The block had failed to demonstrate the reduction in pain scores and opioid consumption. Hence, this study was done to confirm and assess the efficacy of bilateral superficial cervical plexus block for thyroid surgery.

**Material and Method**

120 (one hundred twenty) adult patients admitted to GSL Medical College, Raja nagaram,

Rajahmandry, Andhra Pradesh-533296 were studied.

The duration of the study was one year i.e from August 2024 to July 2025

**Inclusive Criteria:** ASA physical status I-II patients undergoing elective thyroid surgery under general anesthesia who gave their consent in writing were selected for study.

**Exclusion Criteria:** Patients with allergies to opioid or non-opioid analgesics, corticosteroids or non-steroidal anti-inflammatory drugs, coagulation disorders, pregnancy, age below 18 years, and refusal for general anesthesia were excluded from the study.

**Method:** Out of 120 (one hundred twenty) patients, they were classified into three groups by the lottery system: group P received isotonic sodium chloride, and group R received 0.5% ropivacaine & group RC received ropivacaine 0.5% plus clonidine 0.5 mcg/ kg. Sufentanil was given during the intraoperative period for a 20% increase in arterial mean pressure or heart rate in patients with a bispectral index between 40 and 60. All patients received 2 gm of acetaminophen during the first 24 hours after the operation. The pain score was checked every 4 hours, and Inj Ketorolac 30mg (IV) was given for a pain score >4 on the numerical pain scale.

Anesthesia was standardized. All the patients enrolled for the study were kept fasting for 6 hours for solids and 2 hours for clear fluids & were premedicated with tab Ranitidine (150 mg) on the night before surgery & tab Ranitidine (150mg) and metoclopramide (10 mg) on the morning of surgery. General anesthesia was induced by using propofol (2–3 mg/kg) and sufentanil (0.3 mcg/kg). Tracheal intubation was facilitated by the administration of atracurium 0.5 mg/kg. General anesthesia was maintained with sevoflurane (0.5-1.8%) in an oxygen/nitrous oxide mixture (60/40%). The sevoflurane was adjusted to maintain a bispectral index (BIS: Aspect Medical Systems, Newton, MA, USA) between 40 and 60. Additional doses of sufentanil (0.15 mcg/kg) were administered for variations of systolic blood pressure (SBP) and heart rate (HR) of more than 20% when compared with the values measured before operation.

SBC PB (bilateral superficial cervical plexus block) was performed under general anesthesia before skin incision using a three-point injection technique. 10 ml of the prepared mixture were injected into each side using the same puncture orifice. A 23-gauge SC short beveled needle was inserted 2 cm above the clavicle along the posterior border of the clavicular head of the sternocleidomastoid muscle. After an aspiration

test, an S.C. injection of 6 ml of the prepared mixture was performed in the cephalic direction. Then the needle was reoriented in the medial direction above the sternocleidomastoid muscle, and 3 ml of the prepared mixture was injected.

These first two injections allow anesthesia of the greater auricular and transverse cervical nerves. Finally, 1 ml of the mixture was injected S.C. at the point of puncture to block supraclavicular nerves. The depth of the mixture injection was not greater than 5 mm. In order to prevent blockage of the phrenic nerve or recurrent laryngeal nerve, a postoperative laryngoscope was performed to evaluate laryngeal palsy before the transfer to PACU.

Intraoperatively, SBP and HR were recorded at the time of induction, incision, the end of resection, and extubation. The duration of surgery and sufentanil requirements were also recorded. The postoperative pain score in PACU and the number of patients who had a pain score >6 were also recorded.

**Statistical analysis:** mean value of characteristics of patients from different groups and comparison of SBP in different groups Intraoperative and postoperative pain scores were compared with an ANOVA test, and significant values were noted. The statistical analysis was carried out in SPSS software. The ratio of males and females was 1:2.

## Observation and Results

**Table 1:** Comparison of mean value of demographic characteristics of patients

- Age (year): 46 ( $\pm$  1.06) in group p, 48 ( $\pm$  9.8) in group R, 48 ( $\pm$  8.5) in group RC, F value 0.560 and  $p > 0.573$  (p value is insignificant).
- Height (cms): 164.0 ( $\pm$  8.4) in group P, 165.5 ( $\pm$  8.4) in group R, 167.8 ( $\pm$  8.3) in group RC, F value 1.27 and  $p > 0.124$  (p value is insignificant).
- Duration of Surgery (minutes): 183.4 ( $\pm$  11.3) in group P, 184.5 ( $\pm$  8.4) in group R, 183.9 ( $\pm$  7.6) in group RC, F value 0.142 and  $p > 0.868$  (p value is insignificant).

**Table 2:** Comparative study of systolic Blood pressure (SBP) mm/Hg (median range) recorded at induction, incision, end of resection and extubation

- Induction: 158 ( $\pm$  12) in group P, 150 ( $\pm$  8) in group R, 152 ( $\pm$  9) in group RC, F value 7.19 and  $p < 0.001$  (p value is highly significant).
- Incision: 119 ( $\pm$  8) in group P, 119 ( $\pm$  5) in group R, 113 ( $\pm$  8) in group RC, F value 11.5 and  $p < 0.001$  (p value is highly significant).
- End of resection: 145 ( $\pm$  8) in group P, 138 ( $\pm$  9) in group R, 123 ( $\pm$  10) in group RC, F value 61.8 and  $p < 0.001$  (p value is highly significant).

➤ Extubation: 164 (± 12) in group P, 152 (± 9) in group R, 142 (± 7) in group RC, F value 51.1 and p<0.001 (p value is highly significant).

0.08) in group R, 0.326 (± 0.07) in group RC, F value 198.3 and p<0.001 (p value is highly significant).

**Table 3:** Comparative study of Intra-operative and post-operative analgesic requirement and pain scores

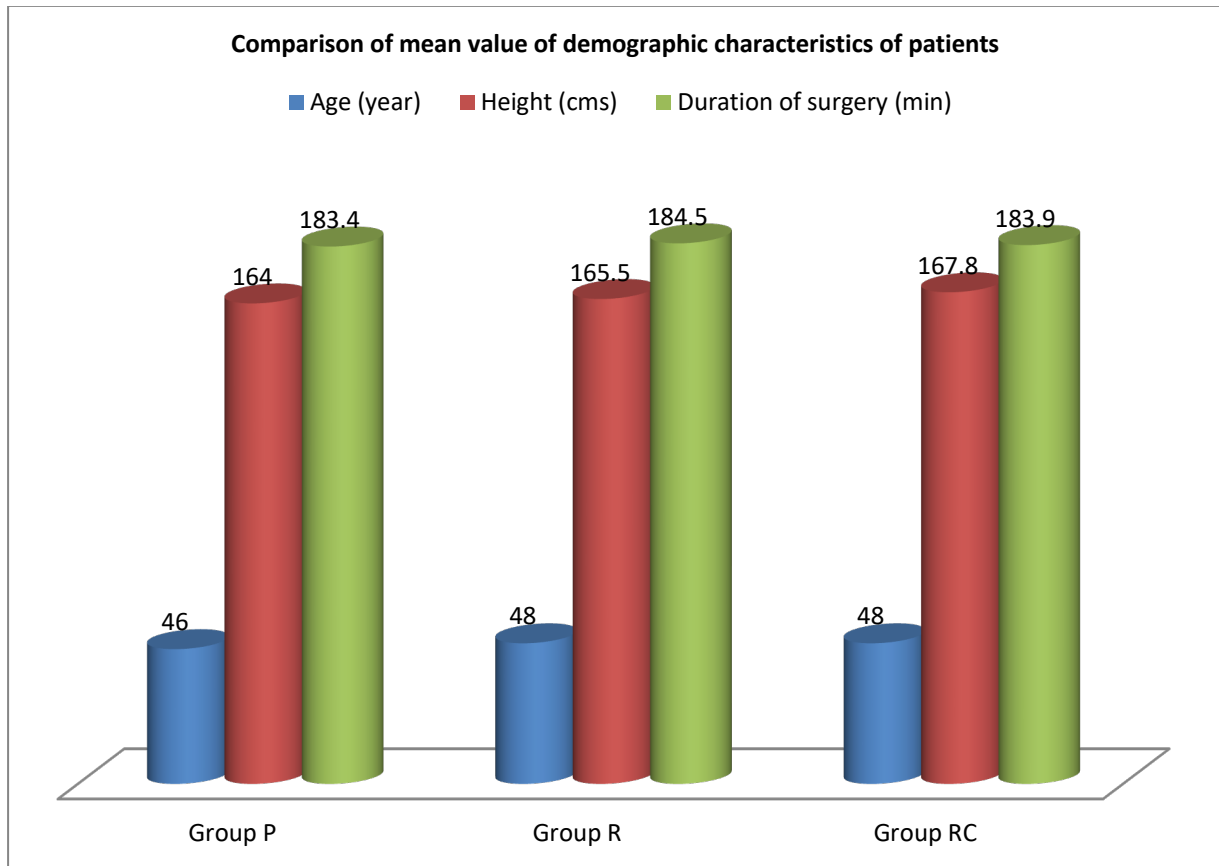
➤ Mean Pain score in PACU: 5 in group P, 3 in group R, 3 in group RC.

➤ Intra-operative supplementary sufentanil (µg/kg<sup>1</sup>): 0.618 (±0.04) in group P, 0.475 (±

➤ Number of patients who had pain score >6 = 9 (22.5%) in group P, 6 (15%) in group R, 4 (10%) in group RC

**Table 1: Comparison of mean value of demographic characteristics of patients (Total No of patient: 120)**

Characteristics	Group P (40)	Group R (40)	Group RC (40)	F value	P value
Age (year)	46 (±10.6)	48 (±9.8)	48 (±8.8)	0.560	p>0.573
Height (cms)	164.0 (± 8.4)	165.5 (±8.2)	167.8 (±8.3)	2.127	p>0.124
Duration of surgery (min)	183.4 (±11.3)	184.5 (±8.4)	183.9 (± 7.6)	0.142	p>0.868



**Figure 1: Comparison of mean value of demographic characteristics of patients**

**Table 2: Comparative study of systolic Blood pressure (SBP) mm / Hg (median range) recorded at induction, incision, end of resection and extubation (Total No of patient: 120)**

Details	Group P (40)	Group R (40)	Group RC (40)	F value	p value
Induction	158 (±12)	150 (±8)	152 (±9)	7.19	P<0.001
Incision	119 (±6)	119 (±5)	113 (±8)	11.5	P<0.001
End of resection	145 (±8)	138 (±9)	123 (±10)	61.8	P<0.001
Extubation	164 (±12)	152 (±9)	142 (±7)	53.1	P<0.001

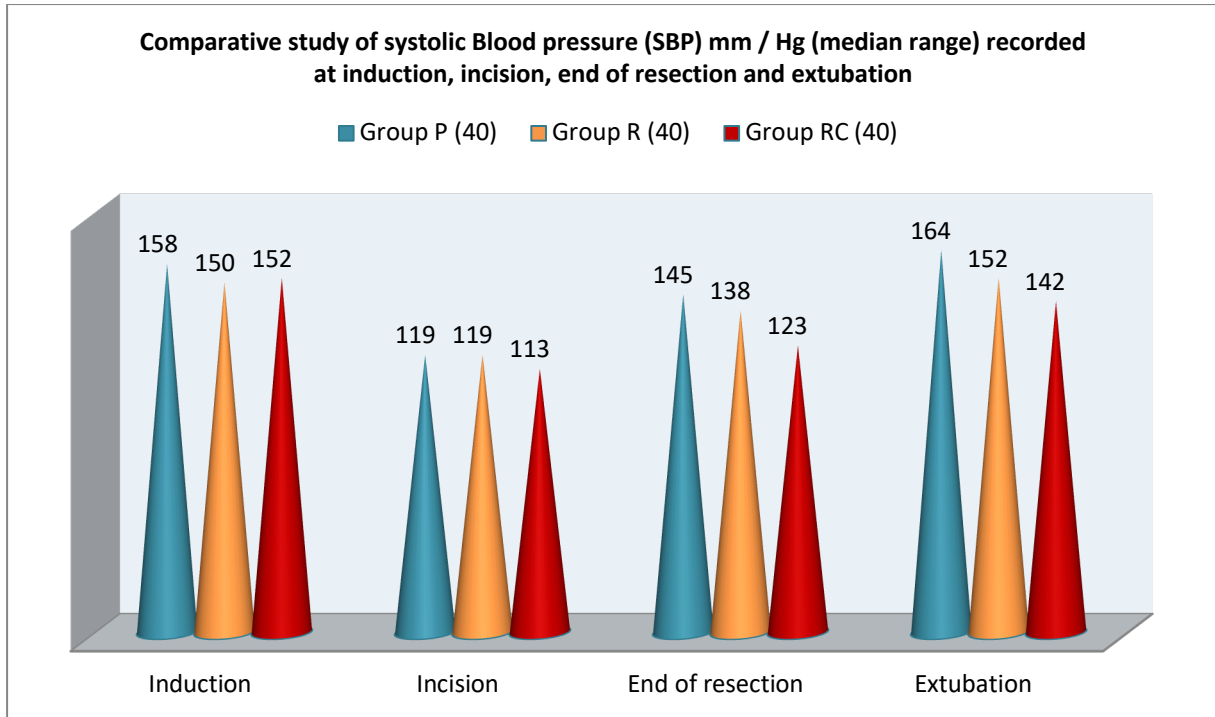


Figure 2: Comparative study of systolic Blood pressure (SBP) mm / Hg (median range) recorded at induction, incision, end of resection and extubation

Table 3: Comparative study of Intra operative and post-operative requirement and pain scores8 (Total No of patient: 120)

Details	Group P (40)	Group R (40)	Group RC (40)	F value	p value
Intra-operative supplementary sufentanil ( $\mu\text{ kg}^{-1}$ )	0.618 ( $\pm 0.04$ )	0.475 ( $\pm 0.08$ )	0.326 ( $\pm 0.07$ )	198.3	$P < 0.001$
Mean Pain score in the PACU	5	3	3	--	--
Number of patients who had pain score >6	9 (22.5%)	6 (15%)	4 (10%)		

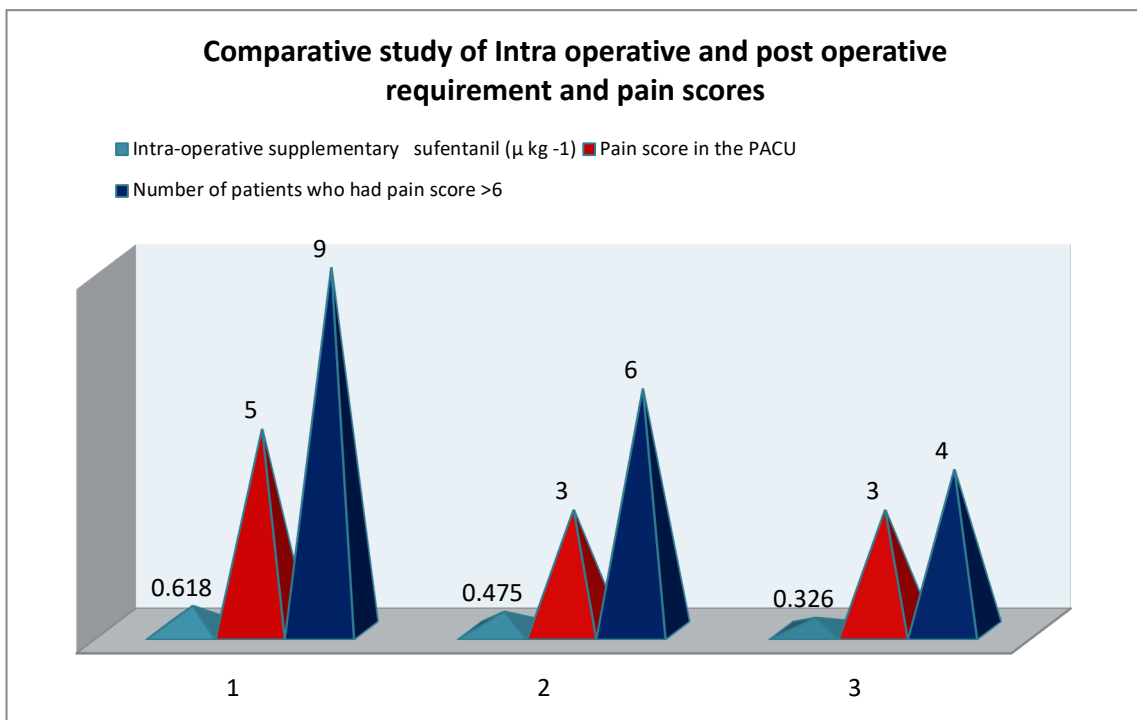


Figure 3: Comparative study of Intra operative and post operative requirement and pain scores

## Discussion

Present study is to confirm the analgesic efficacy of bilateral superficial cervical plexus administered before thyroid surgeries under general anesthesia. In a comparative study of mean values of demographic characters of patients of different groups, there was no significant difference (Table 1). In a comparative study of systolic blood pressure (SBP) mm/Hg (median, range) at the time of incision, end of resection, and extubation in three groups, there was a significant p-value ( $p < 0.001$ ) (Table 2).

Need for Intraoperative supplementary sufentanil, was significantly less in group RC ( $p < 0.001$ ), the pain score was 6 group P, 3 in group R, and 3 in group RC. The number of patients who had a pain score  $> 6$  was 9 (22.5%) in group P, 6 (15%) in group R, and 4 (10%) in group RC (Table 3).

These results indicate better intraoperative and post-operative pain control in group RC. These findings are more or less in agreement with previous studies [5,6,7].

This study confirmed that BSCP with general anesthesia reduced postoperative pain and analgesic consumption in patients who underwent thyroid surgery compared to those who received only general anesthesia (8). VAS was considerably reduced in BSC PB patients during intra & postoperative periods. The efficacy of post-thyroidectomy BSC PB in opioid consumption is a matter of debate. This study also found the block group required less sufentanil than the general anesthetic group [9,11]

Severe postoperative pain control increases the level of stress hormones and the rate of perioperative complications; hence, additional doses of analgesics are required to manage the postoperative pain.

It is also reported that PSCP significantly reduces nausea and vomiting in the postoperative period (10). Hence, in the present study, not a single case of nausea and vomiting is reported.

For the successful blockage, injecting superficially on the superior brachial plexus is recommended in previous studies (12), as in the present, a three-point blockade was performed to get satisfactory results intra operatively and postoperatively to manage the pain score.

## Summary and Conclusion

Present study confirmed the analgesic efficacy of BSC PB under general anesthesia. The patients administered ropivacaine and clonidine had improved intraoperative analgesia. These combinations were quite efficient in managing the VAS score by reducing the analgesic requirement

after thyroid surgery. The present study demands that such clinical trials has to be conducted on a larger number of patients to confirm the analgesic efficacy and adverse effects.

**Limitation of study:** Number of patients enrolled for this study is small which is a limiting factor that led to limited findings and results

This research work was approved by the Ethical Committee of GSL Medical College, Raja nagaram, Rajahmandry, Andhra Pradesh-533296.

## References

1. Karthikeyan VS, Sistla SC: Randomized controlled trial on efficacy of bilateral superficial cervical plexus block in thyroidectomy path pract 2013, 13 (7); 539–46.
2. Shih ML, Duh QY: Bilateral superficial cervical plexus block combined with general anesthesia administered in the thyroid surgery world J. Surg. 2010, 34 (10); 2338–43.
3. Stefen T, Warsch Kow R: Randomized controlled trial of bilateral superficial block versus placebo in thyroid surgery Br. J. Surg. 2010, 97 (7); 1000–6.
4. Cal HD, Lin CZ: Bilateral superficial cervical block reduces postoperative nausea and vomiting and early postoperative pain in thyroidectomy. Turkey klinikleri J. Med. Res. 2012, 40; 1390–8.
5. Suren M, Okan I: Factors associated with the pain catastrophizing scale and validation in a sample of the Turkish population. Turk. J. Med. Science 2014; 14 (1); 104-8.
6. Alkan Karkish, Hakan Tapor: Peri-operative analgesic efficacy of bilateral superficial cervical plexus block in patients undergoing thyroidectomy Rev. Bros. Anaesthesiol 2019, 69 (5); 455–40
7. Kesisoglou T, Papavramids TS: Superficial selective cervical plexus block following total thyroidectomy Head and Neck 2010, 32; 984-6.
8. Kang KH, Kim BS: The benefits of permissive ropivacaine infiltration for redesign postoperative pain after robotic bilateral axillo-breast approach thyrodecotmy Ann. Surg. 2005, 89; 325–9.
9. Ballantyne J, Cousins M: Managing acute pain in the developing world, Int. Assoc. Study Pain 2011, 19 (3); 1-6.
10. Canker E: Effect of bilateral superficial cervical block in postoperative analgesia in thyroid gland surgery performed under general anesthesia Ege. J. Med. 2015, 54 (4); 182–6.
11. Mayhow D, Sahgal N: Analgesic efficacy of bilateral superficial cervical plexus block for thyroid surgery Br. J. Anesthesia 2018, 120 (2); 241–5.

12. Sardar K, Rahman S: The analgesic requirement after thyroid surgery under general anesthesia with bilateral superficial cervical block mymensingh Med. J. 2013, 22 (1); 49–52.