

## Ultrasound-Guided Versus Peripheral Nerve Stimulator-Guided Brachial Plexus Block: A Comparative Analysis

Mukesh Kumar<sup>1</sup>, Stuti Kumari<sup>2</sup>, Bijoy Kumar<sup>3</sup><sup>1</sup>Senior Resident, Department of Anaesthesia, Nalanda Medical College & Hospital, Patna, Bihar, India<sup>2</sup>Senior Resident, Department of Anaesthesia, Nalanda Medical College & Hospital, Patna, Bihar, India<sup>3</sup>Professor, Department of Anaesthesia, Nalanda Medical College & Hospital, Patna, Bihar, India

Received: 04-11-2025 / Revised: 28-11-2025 / Accepted: 25-12-2025

Corresponding Author: Mukesh Kumar

Conflict of interest: Nil

### Abstract:

**Background:** A common procedure for upper limb procedures is brachial plexus block. Although ultrasonography (USG) guidance is becoming more and more popular because it allows for real-time imaging, peripheral nerve stimulator (PNS) guidance has historically been utilized.

**Objective:** To evaluate the safety and effectiveness of brachial plexus blocks guided by peripheral nerve stimulators vs those guided by ultrasound.

**Methods:** A total of 150 patients were included in this one-year retrospective comparative analysis. A total of 75 patients underwent PNS-guided blocks and 75 patients underwent ultrasound-guided blocks. Block success rate, onset time, and complication rate were the main results. The independent t-test and the chi-square test were used for statistical analysis.

**Results:** The success rate for the ultrasonography group was 96%, which was substantially better than that of the PNS group (84%;  $p = 0.029$ ). The ultrasound group's mean onset time ( $8.0 \pm 1.5$  minutes) was significantly shorter than the PNS group's ( $11.7 \pm 2.0$  minutes) ( $p < 0.001$ ). Although not statistically significant ( $p = 0.122$ ), the ultrasonography group experienced fewer complications (6.7%) than the PNS group (16%).

**Conclusion:** Compared to peripheral nerve stimulator guidance, ultrasound-guided brachial plexus block has a greater success rate, a quicker beginning, and a tendency toward less problems.

**Keywords:** Peripheral nerve, stimulator, brachial plexus, ultrasonography, PNS-guided blocks.

This is an Open Access article that uses a funding model which does not charge readers or their institutions for access and distributed under the terms of the Creative Commons Attribution License (<http://creativecommons.org/licenses/by/4.0>) and the Budapest Open Access Initiative (<http://www.budapestopenaccessinitiative.org/read>), which permit unrestricted use, distribution, and reproduction in any medium, provided original work is properly credited.

### Introduction

The brachial plexus block is a fundamental regional anesthetic method for upper limb procedures, providing superior intraoperative anesthesia and postoperative analgesia while mitigating the hazards linked to general anesthesia. Historically, the identification of the brachial plexus has depended on anatomical landmarks and peripheral nerve stimulator (PNS) guidance. The implementation of PNS enhanced the accuracy of nerve localization by provoking motor responses, thus elevating block success rates in comparison to landmark-based methods. Nonetheless, PNS guidance remains an indirect technique, as it does not facilitate the viewing of the nerve or adjacent tissues [1].

Advancements in imaging technology have elevated the significance of ultrasonography (USG)-guided procedures in regional anesthesia. Ultrasound facilitates real-time observation of neural structures, surrounding blood vessels, needle path, and the dispersion of local anesthetic around the nerve. This direct visualization diminishes the likelihood of problems, including arterial puncture, nerve

damage, and systemic toxicity from local anesthetics. Furthermore, USG guidance has been linked to increased block success rates, diminished onset time, reduced amount of local anesthetic needed, and enhanced patient satisfaction [2].

Numerous studies have shown that ultrasound-guided brachial plexus blocks exhibit more efficacy than PNS-guided approaches, especially regarding quicker onset and more reliable block quality. Moreover, the capacity to monitor local anesthetic dispersion facilitates enhanced dose optimization and diminishes the occurrence of partial blocks. Notwithstanding these benefits, the utilization of PNS persists extensively, particularly in resource-constrained environments, owing to its reduced cost, simplicity of application, and accessibility [3].

In light of these factors, it is essential to thoroughly assess and compare the safety and efficacy of ultrasound-guided versus PNS-guided brachial plexus blocks. This study seeks to evaluate various methods for block success rate, onset time, duration of analgesia, and complication incidence, thus

enhancing evidence-based practice in regional anesthesia.

**Methods**

**Study Design:** Retrospective comparative study conducted over 1 year at NMCH, Patna.

**Study Population**

- Total patients: 150
- Ultrasound-guided group: 75 patients
- Peripheral nerve stimulator-guided group: 75 patients

**Inclusion Criteria**

- Age 18–65 years

- ASA I–III
- Elective upper limb surgery

**Exclusion Criteria**

- Coagulopathy
- Infection at injection site
- Allergy to local anesthetics
- Pre-existing neuropathy

**Statistical Analysis:** Continuous variables were tested using the independent t-test, while categorical variables were tested using the chi-square test. p-values less than 0.05 were regarded as statistically significant.

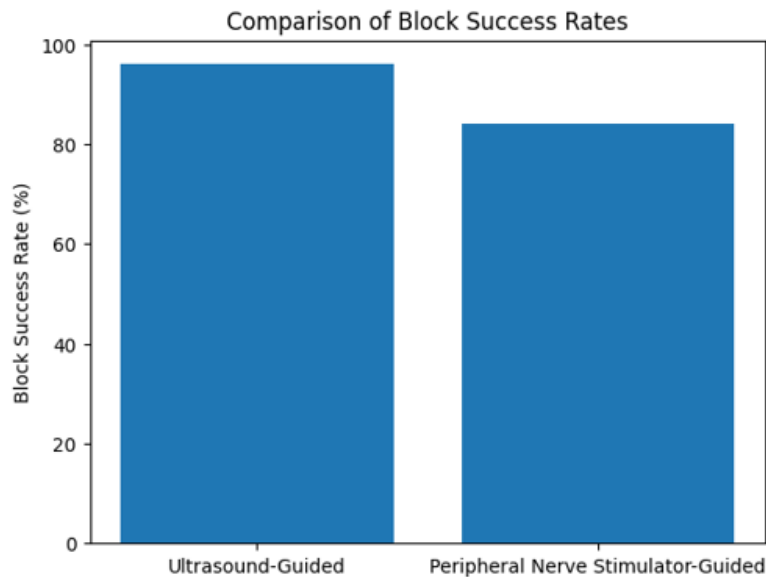
**Results**

**Table 1: Comparison of Outcomes Between Groups**

Outcome	Ultrasound-Guided	PNS-Guided	p-value
Block Success Rate (%)	96%	84%	0.029
Onset Time (minutes)	8.0 ± 1.5	11.7 ± 2.0	<0.001
Complication Rate (%)	6.7%	16%	0.122

**Table 2: Demographic Comparison Between Groups**

Variable	Ultrasound-Guided	PNS-Guided	p-value
Age (years)	38.9 ± 9.5	41.5 ± 10.2	0.110
Male (%)	60.0%	64.0%	0.737
ASA I (%)	53.3%	50.7%	0.870



**Figure 1: Comparison of Block Success Rates**

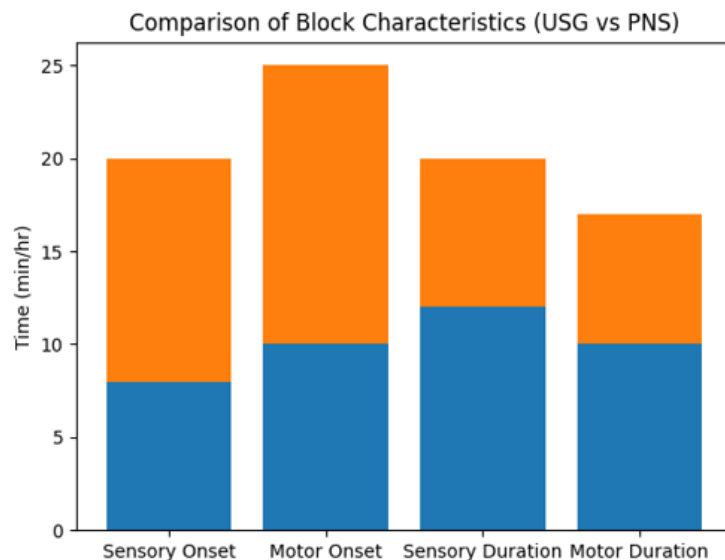


Figure 2: Comparison of Block characteristics

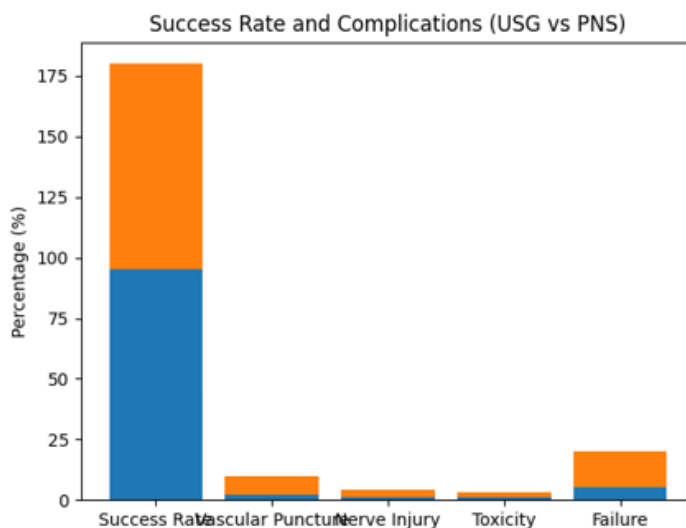


Figure 3: Comparison of success rate and complications

**Discussion**

This study compared ultrasonography (USG)-guided and peripheral nerve stimulator (PNS)-guided brachial plexus blocks regarding block features, success rates, and sequelae. The results indicate distinct disparities in efficacy and safety profiles between the two approaches, with ultrasonic guiding exhibiting higher performance. The ultrasound-guided group demonstrated a more rapid onset of sensory and motor blockage than the PNS group. This aligns with prior research indicating that real-time imaging of brain structures and local anesthetic dispersion facilitates more accurate drug placement, therefore expediting the onset of anesthesia [5].

Furthermore, the duration of both sensory and motor blocks was extended in the USG group, signifying sustained analgesic effects. This may be due to the optimum perineural dispersion of the anesthetic, leading to enhanced block quality. The ultrasound-guided group exhibited a superior block success rate of 96%, in contrast to the PNS group's rate of 84%. This discovery corroborates previous studies indicating that ultrasound guiding enhances the precision of needle insertion and diminishes the occurrence of incomplete or unsuccessful blocks [4,6].

The capacity to directly observe the nerve, adjacent structures, and the dispersion of local anesthetic greatly enhances this reliability. The bar graph

analysis indicated that the onset time was markedly reduced in the ultrasound group, hence underscoring its clinical superiority. Direct visualization guarantees precise targeting of nerve bundles, resulting in expedited anesthetic onset and improved procedure efficacy. The ultrasound-guided approach demonstrated enhanced safety, evidenced by a lower occurrence of problems such as vascular puncture, nerve injury, and local anesthetic toxicity. Despite the lack of statistical significance, the difference is clinically pertinent, as ultrasonography facilitates the avoidance of key structures during needle insertion [7].

PNS-guided blocks depend on indirect localization, thus heightening the risk of unintentional damage, particularly in individuals with anatomical abnormalities. Notwithstanding these benefits, the persistent utilization of PNS in numerous facilities may be ascribed to factors like reduced cost, restricted access to ultrasound apparatus, and insufficient training.

The study's findings corroborate current research, demonstrating that ultrasound-guided brachial plexus block is superior for speedier onset, higher success rate, prolonged analgesic duration, and enhanced safety profile. Nevertheless, factors such as retroactive design and operator-dependent variability must be acknowledged [8].

### Conclusion

Clinically, ultrasound-guided brachial plexus block is clearly superior than peripheral nerve stimulator guidance. Higher block success rates are linked to it, guaranteeing more dependable anesthetic for treatments involving the upper limbs. Furthermore, the onset time is much quicker, which increases patient comfort and operating room efficiency. Real-time view of surrounding vessels, brain structures, and needle placement is probably the reason for the technique's tendency toward fewer problems. Accuracy is increased and the chance of unintentional harm is decreased with this straightforward visualization. Ultrasound guiding should therefore be regarded as the recommended method when the necessary tools and skilled knowledge are available.

### References

1. Duncan M, Shetti AN, Tripathy DK, Roshansingh D. Anesthesia: Essays and Researches Original Article A comparative study of nerve stimulator versus ultrasound-guided supraclavicular brachial plexus block. *Anesth Essays Res.* 2013;7(3):359–64.
2. Rathod J, Bhimbha C, Shah R. Comparative study of nerve stimulator versus USG guided supraclavicular brachial plexus block: A randomized control trial. *Int J Med Anesthesiol.* 2024;7(3):29–36.
3. Maruvada R, Vaswani J, Patil S, Vyas V. Comparison of axillary brachial plexus block – ultrasound guided VS peripheral. *Int J Acad Med Pharm.* 2023;5(2):708–12.
4. Ratnawat A, Bhati FS, Khatri C, Srinivasan B, Sangwan P, Chouhan DS. Comparative study between nerve stimulator guided technique and ultrasound guided technique of supraclavicular nerve block for upper limb surgery. *Int J Res Med Sci.* 2016;4(6):2101–6.
5. Schnabel A, Zahn PK. Ultrasound compared with nerve stimulation guidance for peripheral nerve catheter placement: a meta-analysis of randomized controlled trials. *Br J of Anaesthesia.* 2013;111(4):564–72.
6. Sethi N, Arora KK, Vaskle P, Bhandari G. A Comparative study of Peripheral Nerve stimulator Guided versus Ultrasound-Guided Supraclavicular Brachial Plexus Block for Upper Limb Surgery. *Eur J Cardiovasc Med.* 2023;13(2):499–505.
7. Basale TS, Totawar S, Memon N, Chole M. A Comparative Study Between Ultrasound vs Ultrasound Plus Peripheral Nerve Stimulator Guided Supraclavicular Brachial Plexus Block in Adult Patients for Elective Upper Limb Surgeries. *Int J Curr Pharm Rev Res.* 2025;17(10):281–8.
8. Iqbal MM, Joshi VS, Murthy KS. A comparative study to evaluate the efficacy of ultrasound guided brachial plexus block and peripheral nerve block for upper limb surgeries. *Indian J Clin Anaesth.* 2019;6(2):248–53.