e-ISSN: 0976-822X, p-ISSN:2961-6042

Available online on http://www.ijcpr.com/

International Journal of Current Pharmaceutical Review and Research 2025; 17(5); 1413-1421

Original Research Article

Comparative Outcomes of Chemical Cauterisation versus Fat-Plug Myringoplasty for Closure of Small Central Tympanic Membrane Perforations: A Prospective Interventional Study

Jay Narendra Suratwala[1], Nutan Bala[2]

[1]Associate Professor, Department of Otorhinolaryngology (ENT), Lord Buddha Koshi Medical College & Hospital, Saharsa, Bihar, India

[2]Assistant Professor, Department of Physiology, Shree Narayan Medical Institute & Hospital, Saharsa, Bihar, India

Received: 07-03-2025 / Revised: 30-04-2025 / Accepted: 23-05-2025

Corresponding Author: Dr. Nutan Bala

Conflict of interest: Nil

Abstract

Background: Small central tympanic membrane perforations may persist despite resolution of middle-ear infection and can result in recurrent otorrhoea and conductive hearing loss. Minimally invasive techniques such as chemical cauterisation and fat plug myringoplasty are commonly used for closure of small, dry perforations.

Aim: To compare the effectiveness of chemical cauterisation and fat plug myringoplasty for closure of small central tympanic membrane perforations and to assess their anatomical, audiological, and complication outcomes.

Material and Methods: This prospective interventional study included 110 patients aged ≥16 years with dry, central tympanic membrane perforations measuring ≤5 mm and persisting for at least two months. Patients were divided equally into chemical cauterisation (n=55) and fat plug myringoplasty (n=55) groups. Perforation closure, time to healing, repeat intervention, pure-tone average (PTA), air–bone gap (ABG), recurrence, and complications were evaluated. Data were analysed using IBM SPSS Statistics version 25.0, with $p<0.05$ considered statistically significant.

Results: Complete perforation closure was achieved in 41 (74.55%) patients after chemical cauterisation and 50 (90.91%) after fat plug myringoplasty (p=0.023). Mean closure time was 5.31 ± 1.47 versus 4.18 ± 1.21 weeks, respectively (p<0.001). Repeat intervention was required in 20.00% and 5.45% of patients, respectively (p=0.042). Mean PTA improved by 6.18 ± 3.15 dB in the chemical cauterisation group and 7.80 ± 3.28 dB in the fat plug group (p=0.009). Mean ABG closure was 7.24 ± 3.02 and 9.21 ± 3.18 dB, respectively (p=0.001). Overall complication rates were comparable between the groups (21.82% vs 23.64%; p=0.820).

Conclusion: Fat plug myringoplasty provided a higher closure rate, faster healing, greater hearing improvement, and lower need for repeat intervention than chemical cauterisation, with comparable overall complication rates.

Keywords: Tympanic Membrane Perforation; Chemical Cauterisation; Fat Plug Myringoplasty; Air–Bone Gap; Hearing Improvement.

This is an Open Access article that uses a funding model which does not charge readers or their institutions for access and distributed under the terms of the Creative Commons Attribution License (http://creativecommons.org/licenses/by/4.0) and the Budapest Open Access Initiative (http://www.budapestopenaccessinitiative.org/read), which permit unrestricted use, distribution, and reproduction in any medium, provided original work is properly credited.

Introduction

The tympanic membrane is a thin, trilaminar structure that separates the external auditory canal from the middle-ear cavity and plays a fundamental role in sound transmission. Its integrity is essential for effective coupling of sound energy from the external environment to the ossicular chain. Tympanic membrane perforation is a common otological condition resulting from chronic or recurrent middle-ear infection, trauma, instrumentation, barotrauma, previous ventilation tube insertion, or residual defects following otological surgery. Although recently occurring perforations may heal spontaneously through epithelial migration and regeneration of the fibrous layer, persistent defects can remain when the normal healing process is interrupted by infection, repeated inflammation, poor Eustachian tube function, or epithelialization of the perforation margin.[1] Persistent tympanic membrane perforations may predispose patients to recurrent otorrhoea, conductive hearing impairment, discomfort during water exposure, and repeated middle-ear infections. The functional consequences depend on the size and location of the perforation, the condition of the middle-ear mucosa, and the integrity of the ossicular chain. Small central perforations are particularly suitable for minimally invasive repair because they do not involve the tympanic annulus and generally permit adequate visualization of the middle ear. The principal objectives of treatment are to obtain stable

anatomical closure, prevent recurrent infection, restore the protective function of the tympanic membrane, and improve conductive hearing. These objectives have encouraged the development of techniques that avoid extensive tympanomeatal flap elevation and minimize tissue trauma.[2] Conventional myringoplasty and type I tympanoplasty using temporalis fascia, perichondrium, or cartilage remain established techniques for persistent tympanic membrane defects. However, formal tympanoplasty may require greater operative exposure, longer procedural time, and more extensive manipulation than is necessary for a small uncomplicated central perforation. Consequently, simpler transcanal and office-based procedures have attracted considerable interest. These approaches include paper patching, chemical cauterisation, fat grafting, collagen patches, cartilage inlay techniques, and other biologically active or autologous materials. Careful patient selection is important because the condition of the perforation margins, middle-ear mucosa, Eustachian tube function, and absence of active infection influence the healing process.[3] Chemical cauterisation is one of the least invasive approaches to closure of a small central perforation. The technique involves controlled cauterisation of the epithelialized perforation margin, producing a fresh raw surface that can initiate reparative epithelial and connective-tissue activity. A supporting patch may additionally provide a scaffold for centripetal epithelial migration. Chemical cauterisation can usually be performed under local anaesthesia without elevation of a tympanomeatal flap or harvesting of autologous graft material. Its simplicity, low tissue manipulation, and suitability for an outpatient setting make it attractive for appropriately selected dry central perforations. Nevertheless, closure may sometimes require repeated applications, and persistent perforations may remain when adequate regeneration across the defect does not occur.[4] Fat plug myringoplasty represents another minimally invasive technique intended particularly for small, dry tympanic membrane perforations. In this procedure, autologous fat, most commonly harvested from the ear lobule, is positioned within the perforation after freshening its margins. The graft is generally placed in an hourglass or dumbbell configuration, with portions extending on both sides of the tympanic membrane. The fat acts as a mechanical bridge across the defect and provides a temporary biological scaffold that supports epithelial and mucosal migration. Ear-lobule fat is readily accessible, can be harvested through a small incision, and allows repair without extensive manipulation of the external auditory canal or middle-ear structures.[5]

The biological characteristics of adipose tissue provide further rationale for its use in tympanic membrane repair. Adipose tissue contains connective-tissue components, microvascular elements, and cellular mediators capable of supporting tissue repair and revascularization. Contemporary approaches have also investigated biological adjuncts such as platelet-rich plasma in combination with fat grafts to enhance tissue regeneration. However, for uncomplicated small perforations, the use of autologous fat alone remains particularly appealing because of its accessibility, biocompatibility, absence of graft-related immunogenicity, and straightforward surgical technique. Preservation of normal middle-ear anatomy and minimal operative trauma are additional considerations supporting minimally invasive fat graft procedures.[6]

Aim and Objectives

Aim: To compare the anatomical closure, healing time, audiological outcomes, treatment requirements, and postoperative complications of chemical cauterisation versus fat-plug myringoplasty for small, dry, central tympanic membrane perforations.

Objectives

- To compare the complete tympanic membrane closure rate between chemical cauterisation and fat-plug myringoplasty.
- To compare the time required for complete perforation closure between the two treatment groups.
- To evaluate and compare pre- and post-intervention hearing outcomes, including pure-tone average (PTA) and air–bone gap (ABG).
- To compare the proportion of patients achieving ABG closure ≥10 dB between the two groups.
- To compare treatment failure, residual or recurrent perforation, and requirement for repeat intervention between the treatment groups.
- To compare the frequency and pattern of post-intervention complications associated with both techniques.
- To assess the overall comparative effectiveness and safety of chemical cauterisation and fat-plug myringoplasty in patients with small central tympanic membrane perforations.

Materials & Methods

Study Design: A prospective, interventional, comparative study was conducted to evaluate and compare the efficacy and hearing outcomes of chemical cauterisation and fat-plug myringoplasty for closure of small, dry, central tympanic membrane perforations. A total of 110 eligible patients were enrolled and allocated equally into two intervention groups (55 patients each).

Study Population: The study population comprised patients aged ≥16 years presenting with small, dry, central tympanic membrane perforations measuring ≤5 mm in maximum diameter and persisting for at least 2 months. Group A consisted of patients treated with chemical cauterisation, whereas Group B underwent fat-plug myringoplasty.

Study Place: The study was conducted in the Department of Otorhinolaryngology (ENT), Lord Buddha Koshi Medical College & Hospital, Saharsa, Bihar, India in collaboration with Department of Physiology, Shree Narayan Medical Institute & Hospital, Saharsa, Bihar, India, with clinical, otoscopic, microscopic, and audiological assessments performed according to a standardized institutional protocol.

Study Period: The study was conducted over the period of 12 months from March 2024 to February 2025, including patient recruitment, intervention, postoperative follow-up, and final audiological assessment.

Ethical Considerations: The study protocol was approved by the Institutional Ethics Committee before commencement. Written informed consent was obtained from all participants after explaining the study procedures, potential benefits, and possible risks. Patient confidentiality was maintained throughout the study, and participation was voluntary.

Inclusion Criteria: Patients were eligible for inclusion if they were ≥16 years of age and had a dry, central tympanic membrane perforation ≤5 mm in maximum diameter, persisting for ≥2 months, with a dry middle ear and no active otorrhoea.
Patients with clinically intact and mobile ossicles, adequately visualized perforation margins on microscopy, and willingness to undergo intervention and complete scheduled follow-up were included.

Exclusion Criteria: Patients were excluded if they had active otorrhoea, marginal or attic perforation, cholesteatoma, significant tympanosclerosis involving the perforation margin, suspected or confirmed ossicular chain abnormality, severe sensorineural or mixed hearing loss, previous ear surgery, uncontrolled systemic disease, or inability to comply with the follow-up protocol.

Methodology: A detailed history was recorded regarding demographic characteristics, affected ear, duration and probable aetiology of perforation, previous episodes of ear discharge, hearing impairment, tinnitus, otalgia, and previous treatment. Otoscopic and microscopic examinations were performed to document the site, shape, and maximum diameter of the perforation, condition of the tympanic membrane margins, middle-ear mucosa, and contralateral ear. The maximum perforation diameter was measured under microscopic visualization and recorded in millimetres. Baseline pure-tone audiometry (PTA) was performed, and air- and bone-conduction thresholds were recorded at 0.5, 1, 2, and 4 kHz. Pure-tone average and air–bone gap (ABG) were calculated for each participant before intervention.

Interventional Procedures

Group A – Chemical Cauterisation: Under microscopic visualization, the external auditory canal was cleaned and the epithelialized perforation margins were gently freshened. Following application of local anaesthesia when required, the perforation margins were treated with a chemical cauterising agent using controlled application to stimulate healing while avoiding injury to the surrounding tympanic membrane and middle-ear mucosa. A small sterile supporting patch was applied when clinically indicated. Patients were instructed to maintain strict water precautions and avoid ear manipulation.

Group B – Fat-Plug Myringoplasty: After microscopic visualization and local anaesthesia, the perforation margins were circumferentially freshened. Autologous fat was harvested, preferably from the ear lobule, under aseptic precautions. The harvested tissue was fashioned into a plug slightly larger than the perforation and introduced through the perforation in a dumbbell/hourglass configuration, allowing adequate contact with both the medial and lateral aspects of the tympanic membrane. The graft position was confirmed microscopically, and the donor site was appropriately closed.

Post-intervention Care and Follow-up: All patients received standardized postoperative instructions, including strict water precautions and avoidance of nose blowing, excessive straining, and manipulation of the operated ear. Follow-up examinations were performed according to the institutional schedule. Otoscopic or microscopic assessment was undertaken to document epithelialization, complete closure, residual or recurrent perforation, otorrhoea, infection, granulation tissue, retraction, or other complications.
Complete closure was defined as intact, completely epithelialized tympanic membrane without residual perforation at the final clinical assessment.

Investigations: Baseline and follow-up audiological evaluation included pure-tone air- and bone-conduction thresholds at 0.5, 1, 2, and 4 kHz. PTA and ABG were calculated before intervention and after adequate tympanic membrane healing. Clinical and microscopic examinations were used to assess anatomical healing and postoperative complications.

Outcome Measures: The primary outcome was the proportion of patients achieving complete tympanic membrane closure.

Secondary outcomes included:

- Time to complete perforation closure.
- Residual or recurrent perforation.
- Change in PTA following treatment.
- Change in ABG.
- Proportion achieving clinically meaningful ABG improvement.
- Post-intervention otorrhoea, otalgia, infection, granulation tissue, and other complications.
- Requirement for repeat intervention.
- Donor-site complications in the fat-plug group.
- Overall treatment failure.
- Association of treatment success with age, sex, perforation size, site, duration, affected ear, and baseline hearing status.

Statistical Analysis: Data were entered into Microsoft Excel and analysed using IBM SPSS Statistics version 27.0 (IBM Corp., Armonk, NY, USA). Continuous variables were summarized as mean ± standard deviation (SD) for normally distributed data and as median with interquartile range (IQR) for non-normally distributed data. Categorical variables were expressed as frequency (n) and percentage (%).

Normality of continuous variables was assessed using the Shapiro–Wilk test. Between-group comparisons of normally distributed continuous variables were performed using the independent-samples t-test, whereas the Mann–Whitney U test was used for non-normally distributed variables.

Pre- and post-intervention continuous variables were compared using the paired t-test for normally distributed data or the Wilcoxon signed-rank test for non-normally distributed data.

Categorical variables, including complete perforation closure and postoperative complications, were compared using the Pearson chi-square test or Fisher's exact test, as appropriate. Associations between treatment success and relevant demographic or clinical variables were assessed using univariate logistic regression, followed by multivariable logistic regression where appropriate. Effect estimates were reported as odds ratios (ORs) with corresponding 95% confidence intervals (CIs).

All statistical tests were two-tailed, and a p-value <0.05 was considered statistically significant.

Results

A total of 110 patients with small central tympanic membrane perforations were included in the study. Of these, 55 patients underwent chemical cauterisation (Group A), while 55 patients underwent fat plug myringoplasty (Group B).

Table 1: Comparison of Baseline Demographic Characteristics Between the Study Groups

Characteristics	Variable	Chemical cauterisation (n=55)	Fat-plug myringoplasty (n=55)	p-value
Mean Age (years)	Mean ± SD	33.76 ± 10.94	34.58 ± 11.21	0.699
Age group, n (%)	16–25 years	15 (27.27)	14 (25.45)	0.985
	26–35 years	17 (30.91)	18 (32.73)	
	36–45 years	14 (25.45)	13 (23.64)	
	>45 years	9 (16.36)	10 (18.18)	
Sex, n (%)	Male	31 (56.36)	29 (52.73)	0.702
	Female	24 (43.64)	26 (47.27)	
Affected ear, n (%)	Right	30 (54.55)	28 (50.91)	0.702
	Left	25 (45.45)	27 (49.09)	

SD: Standard deviation.

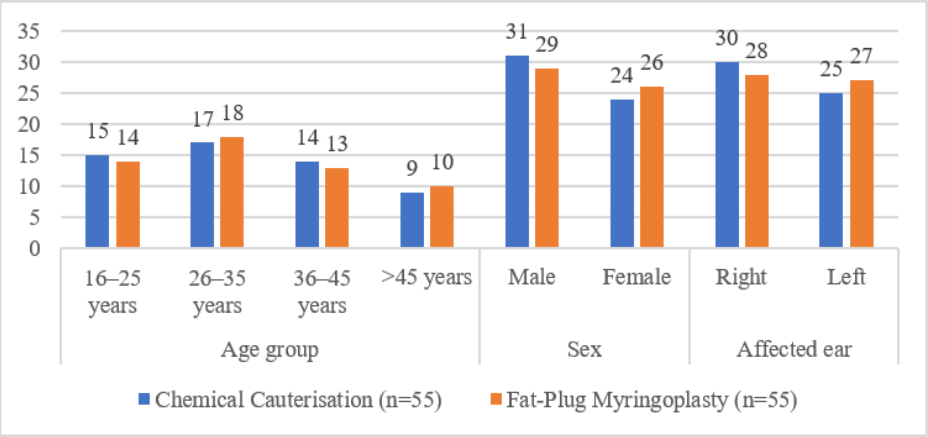

Figure 1: Baseline Demographic of Study Participants

Table 1 and figure I, present the mean age was 33.76 ± 10.94 years in the chemical cauterisation group and 34.58 ± 11.21 years in the fat-plug myringoplasty group, with no statistically significant difference (p=0.699). Similarly, the distribution across age groups was comparable between the groups (p=0.985). Males constituted 56.36% and 52.73% of the chemical cauterisation and fat-plug groups, respectively (p=0.702). The distribution of affected ear was also similar, with right-sided involvement in 54.55% and 50.91% of patients, respectively (p=0.702). Thus, there was no significant baseline demographic imbalance between the two groups.

Table 2: Comparison of Clinical Characteristics of Tympanic Membrane Perforations Between the Study Groups

Clinical characteristic	Variable	Chemical cauterisation (n=55)	Fat-plug myringoplasty (n=55)	p-value
Mean Perforation size (mm)	mean ± SD	3.21 ± 1.01	3.12 ± 0.96	0.633
Perforation size, n (%)	≤2.0 mm	16 (29.09)	18 (32.73)	0.918
	2.1–3.5 mm	21 (38.18)	20 (36.36)	
	3.6–5.0 mm	18 (32.73)	17 (30.91)	
Perforation site, n (%)	Anterior	21 (38.18)	20 (36.36)	0.916
	Posterior	19 (34.55)	18 (32.73)	
	Inferior	15 (27.27)	17 (30.91)	
Probable aetiology, n (%)	Post-infective	31 (56.36)	29 (52.73)	0.922
	Traumatic	17 (30.91)	18 (32.73)	
	Iatrogenic/other	7 (12.73)	8 (14.55)	
Duration of perforation (months)	mean ± SD	7.42 ± 4.12	7.16 ± 3.88	0.734
Duration of perforation, n (%)	2–6 months	34 (61.82)	32 (58.18)	0.697
	>6 months	21 (38.18)	23 (41.82)	

SD: Standard deviation.

Table 2 show that mean perforation size was 3.21 ± 1.01 mm in the chemical cauterisation group and 3.12 ± 0.96 mm in the fat-plug group (p=0.633). The categorical distribution of perforation size was also similar (p=0.918). No significant difference was observed in the site of perforation (p=0.916) or probable aetiology (p=0.922). The mean duration of perforation was 7.42 ± 4.12 months and 7.16 ± 3.88 months, respectively (p=0.734), with comparable duration categories between groups (p=0.697). These findings indicate similar baseline clinical characteristics of the perforations in both groups.

Table 3: Comparison of Tympanic Membrane Closure and Treatment Outcomes Between the Study Groups

Treatment outcome	Chemical cauterisation (n=55)	Fat-plug myringoplasty (n=55)	p-value
Complete perforation closure, n (%)	41 (74.55)	50 (90.91)	0.023*
Residual perforation/treatment failure, n (%)	14 (25.45)	5 (9.09)	0.023*
Time to complete closure (weeks), mean ± SD	5.31 ± 1.47	4.18 ± 1.21	<0.001*
Repeat intervention required, n (%)	11 (20.00)	3 (5.45)	0.042*
Recurrent perforation after initial healing, n (%)	3 (5.45)	1 (1.82)	0.618

*Statistically significant at p<0.05.

Table 3 illustrate a significantly higher proportion of patients achieved complete tympanic membrane closure following fat-plug myringoplasty compared with chemical cauterisation (90.91% vs. 74.55%; p=0.023). Accordingly, residual perforation or treatment failure was significantly lower in the fat-plug group (9.09% vs. 25.45%; p=0.023).

The mean time to complete closure was also significantly shorter with fat-plug myringoplasty (4.18 ± 1.21 vs. 5.31 ± 1.47 weeks; p<0.001). Repeat intervention was required significantly less frequently in the fat-plug group (5.45% vs. 20.00%; p=0.042).

However, recurrent perforation after initial healing did not differ significantly between groups (1.82% vs. 5.45%; p=0.618). Overall, fat-plug myringoplasty demonstrated superior anatomical closure and a faster healing profile.

Table 4: Comparison of Pre- and Post-intervention Audiological Outcomes Between the Study Groups

Audiological parameter	Variable	Chemical cauterisation (n=55)	Fat-plug myringoplasty (n=55)	p-value
Pure-tone average (PTA), dB	Pre-intervention PTA, mean ± SD	28.64 ± 5.83	28.11 ± 5.68	0.630
	Post-intervention PTA, mean ± SD	22.46 ± 4.92	20.31 ± 4.36	0.017*
	Mean improvement in PTA, dB	6.18 ± 3.15	7.80 ± 3.28	0.009*
	Within-group pre–post comparison	<0.001*	<0.001*	—
Air–bone gap (ABG), dB	Pre-intervention ABG, mean ± SD	19.42 ± 4.65	19.08 ± 4.51	0.698
	Post-intervention ABG, mean ± SD	12.18 ± 3.91	9.87 ± 3.36	0.001*
	Mean ABG closure, dB	7.24 ± 3.02	9.21 ± 3.18	0.001*
	ABG closure ≥10 dB, n (%)	20 (36.36)	31 (56.36)	0.035*
	Within-group pre–post comparison	<0.001*	<0.001*	—

PTA: Pure-tone average; ABG: Air–bone gap; SD: Standard deviation. Statistically significant at p<0.05.

Table 4 demonstrate that mean pre-intervention PTA was 28.64 ± 5.83 dB in the chemical cauterisation group and 28.11 ± 5.68 dB in the fat-plug group (p=0.630). Following treatment, PTA improved significantly in both groups (p<0.001 for each), with a significantly greater post-intervention PTA improvement in the fat-plug group (7.80 ± 3.28 vs. 6.18 ± 3.15 dB; p=0.009). Similarly, baseline ABG was comparable between groups (19.42 ± 4.65 vs. 19.08 ± 4.51 dB; p=0.698). Both groups demonstrated significant within-group ABG improvement (p<0.001). However, the post-intervention ABG was significantly lower in the fat-plug group (9.87 ± 3.36 vs. 12.18 ± 3.91 dB; p=0.001), with greater mean ABG closure (9.21 ± 3.18 vs. 7.24 ± 3.02 dB; p=0.001). Moreover, significantly more patients achieved ABG closure of ≥10 dB following fat-plug myringoplasty (56.36% vs. 36.36%; p=0.035). These findings demonstrate significantly better hearing improvement with fat-plug myringoplasty.

Table 5: Comparison of Post-intervention Complications Between the Study Groups

Post-intervention complication	Chemical cauterisation (n=55)	Fat-plug myringoplasty (n=55)	p-value
Post-intervention otalgia, n (%)	5 (9.09)	9 (16.36)	0.392
Otorrhoea, n (%)	6 (10.91)	2 (3.64)	0.271
Local infection, n (%)	4 (7.27)	1 (1.82)	0.363
Granulation tissue, n (%)	3 (5.45)	1 (1.82)	0.618
Donor-site haematoma, n (%)	—	2 (3.64)	—
Donor-site wound infection, n (%)	—	1 (1.82)	—
Any treatment-related complication, n (%)	12 (21.82)	13 (23.64)	0.820

A two-sided p<0.05 was considered statistically significant.

Table 5 show that post-intervention otalgia occurred in 9.09% of patients undergoing chemical cauterisation and 16.36% undergoing fat-plug myringoplasty (p=0.392). Otorrhoea was observed in 10.91% and 3.64%, respectively (p=0.271), while local infection occurred in 7.27% and 1.82% (p=0.363). Granulation tissue was reported in 5.45% and 1.82% of patients, respectively (p=0.618).

Donor-site haematoma and wound infection occurred only in the fat-plug group, affecting 3.64% and 1.82% of patients, respectively. The overall incidence of any treatment-related complication was 21.82% in the chemical cauterisation group and 23.64% in the fat-plug group, with no statistically significant difference (p=0.820). Thus, both techniques demonstrated comparable overall safety profiles.

Discussion

In present study, the mean age was 33.76 ± 10.94 years in the chemical cauterisation group and 34.58 ± 11.21 years in the fat plug myringoplasty group, with no significant difference (p=0.699). Overall, males constituted 54.55% of the study population, with 56.36% males in the chemical cauterisation group and 52.73% in the fat plug group. Mukherjee et al. (2013), in a prospective study of 50 patients undergoing fat graft minimyringoplasty, reported an average age of 27.3 years; 56.00% were males and 44.00% were females.[7] The male predominance reported by Mukherjee et al. was therefore almost identical to the overall male proportion of 54.55% observed in the present study.[7]

The mean perforation size in the present study was 3.21 ± 1.01 mm in the chemical cauterisation group and 3.12 ± 0.96 mm in the fat plug myringoplasty group (p=0.633). Anterior perforations accounted for 38.18% and 36.36%, posterior perforations for 34.55% and 32.73%, and inferior perforations for 27.27% and 30.91% of patients, respectively. Han et al. (2021) evaluated 193 patients undergoing fat-

graft myringoplasty and reported that 86.50% perforations involved <20% of the tympanic membrane area; the anteroinferior quadrant was the most frequent location, accounting for 42.10% of cases, while 71.00% of perforations involved the anterior part of the tympanic membrane. They achieved an overall closure rate of 89.60% and found no statistically significant difference in closure according to perforation size.[8]

Post-infective perforation was the predominant etiology in the present study, occurring in 56.36% of patients receiving chemical cauterisation and 52.73% receiving fat plug myringoplasty, whereas traumatic perforations accounted for 30.91% and 32.73%, respectively. The mean duration of perforation was also comparable at 7.42 ± 4.12 and 7.16 ± 3.88 months (p=0.734). Hegazy (2013) prospectively evaluated 60 patients with small tympanic membrane perforations caused by chronic infection, trauma, tympanostomy tube extraction, or residual perforation following myringoplasty. Fat graft myringoplasty produced an overall success rate of 88.20%; etiology-specific success was 90.00% for traumatic perforations and 86.60% for perforations associated with inactive chronic tubotympanic infection.[9]

In the present study, both post-infective and traumatic etiologies were represented in similar proportions in the two treatment groups, thereby allowing comparison of the two interventions without a significant baseline etiological imbalance (p=0.922). Complete tympanic membrane closure in the present study was achieved in 74.55% treated with chemical cauterisation, while residual perforation or treatment failure occurred in 25.45% patients. Santhi et al. (2012) studied 38 patients with dry chronic tympanic membrane perforations treated by 50% silver nitrate cauterisation combined with patching and reported an overall closure success rate of 73.75%. Their success rate was remarkably similar to the 74.55% obtained with chemical cauterisation in the present study. They also reported greater success among traumatic perforations and used up to five applications when necessary.[10]

In contrast, complete closure following fat plug myringoplasty was achieved in 90.91% patients in the present study, significantly higher than the 74.55% closure observed with chemical cauterisation (p=0.023). Treatment failure was correspondingly lower with fat plug myringoplasty at 9.09% compared with 25.45% following cauterisation. Dursun et al. (2008) prospectively compared paper-patch, fat, and perichondrium myringoplasty in 45 patients with chronic perforations smaller than 3 mm and reported closure rates of 66.70%, 86.70%, and 86.70%, respectively. The 90.91% closure rate obtained with fat plug myringoplasty in the present study was slightly higher than their 86.70% fat graft success rate, whereas the 74.55% rate following chemical cauterisation was closer to the less invasive patch-based treatment results reported in their study.[11]

Among successfully healed patients, the mean time to complete closure was 5.31 ± 1.47 weeks following chemical cauterisation compared with 4.18 ± 1.21 weeks following fat plug myringoplasty (p<0.001). Repeat intervention was required in 20.00% of chemical cauterisation patients but in only 5.45% of patients undergoing fat plug myringoplasty (p=0.042). Upreti (2019) evaluated 68 cases treated with trichloroacetic acid cauterisation and paper patching and reported successful closure in 91.20% patients. Patients were reviewed weekly for up to 12 weeks, and between one and three applications were required for closure. 8.80% patients ultimately failed treatment, all of whom had inflammatory perforations.[12] Compared with these findings, the present chemical cauterisation group demonstrated a lower overall closure rate of 74.55% and a 20.00% requirement for repeat intervention, whereas fat plug myringoplasty achieved faster healing with fewer repeat procedures.

Significant audiological improvement occurred in both treatment groups. The mean PTA decreased from 28.64 ± 5.83 to 22.46 ± 4.92 dB after chemical cauterisation and from 28.11 ± 5.68 to 20.31 ± 4.36 dB after fat plug myringoplasty, with mean PTA improvements of 6.18 ± 3.15 and 7.80 ± 3.28 dB, respectively (p=0.009). Similarly, the mean air–bone gap decreased from 19.42 ± 4.65 to 12.18 ± 3.91 dB following chemical cauterisation and from 19.08 ± 4.51 to 9.87 ± 3.36 dB following fat plug myringoplasty. Mean ABG closure was 7.24 ± 3.02 versus 9.21 ± 3.18 dB (p=0.001), while ABG closure ≥10 dB occurred in 36.36% and 56.36% of patients, respectively. Hagemann et al. (2003) performed adipose-tissue myringoplasty in 44 patients and achieved permanent tympanic membrane healing in 91.00% patients; hearing improvement of 5–10 dB was documented in 47.72% patients.[13] The 7.80-dB mean PTA improvement observed after fat plug myringoplasty in the present study falls within this previously reported 5–10-dB range, while the greater ABG closure in the fat plug group corresponded with its better postoperative hearing thresholds.

Overall treatment-related complications occurred in 21.82% patients following chemical cauterisation and 23.64% patients following fat plug myringoplasty (p=0.820). Otalgia occurred in 9.09% versus 16.36%, otorrhoea in 10.91% versus 3.64%, local infection in 7.27% versus 1.82%, and granulation tissue in 5.45% versus 1.82%, respectively. In the fat plug group, donor-site hematoma and wound infection occurred in 3.64% and 1.82% of patients. Recurrent perforation after initial healing was uncommon, occurring in 5.45%

of the chemical cauterisation group and 1.82% of the fat plug group (p=0.618). Landsberg et al. (2006) reported successful fat graft closure in 31 of 38 perforations (81.60%) over a mean follow-up of 40.6 ± 8.3 months and observed no recurrence among perforations that had initially healed successfully. They also reported significant improvement in speech reception threshold from 23.5 ± 8.0 to 18.5 ± 7.7 dB (p=0.043), without significant sensorineural hearing loss.[14] In the present study, the similarly low recurrence rate of 1.82% after fat plug myringoplasty was accompanied by significant hearing improvement and no significant difference in overall complication frequency compared with chemical cauterisation.

Limitations of the Study: The study has several limitations. First, the sample size was relatively small, with 110 patients, which may limit the statistical power and generalisability of the findings. Second, the study was conducted at a single tertiary-care centre, potentially limiting external validity. Third, the follow-up period may not have been sufficient to determine long-term recurrence of tympanic membrane perforation. Fourth, the study included only small, dry, central perforations ≤5 mm, and therefore the findings may not be applicable to larger, marginal, attic, or actively discharging perforations. Finally, although baseline demographic and clinical characteristics were comparable between groups, residual confounding cannot be completely excluded in a non-blinded interventional study.

Conclusion

Authors found that, fat-plug myringoplasty demonstrated significantly higher tympanic membrane closure rates, faster healing, greater improvement in PTA and ABG, and a higher proportion of patients achieving ABG closure ≥10 dB compared with chemical cauterisation. The requirement for repeat intervention was also significantly lower following fat-plug myringoplasty. However, recurrent perforation and individual postoperative complications did not differ significantly between the groups, and the overall complication rates were comparable. Therefore, for appropriately selected patients with small, dry, central tympanic membrane perforations, fat-plug myringoplasty may provide superior anatomical and functional outcomes compared with chemical cauterisation, while maintaining a comparable overall safety profile. Larger, multicentre studies with longer follow-up are warranted to confirm these findings and evaluate their long-term clinical applicability.

Acknowledgement: The authors sincerely acknowledge the support and cooperation provided by the Department of Otorhinolaryngology (ENT), Lord Buddha Koshi Medical College & Hospital, Saharsa, Bihar, and the Department of Physiology, Shree Narayan Medical Institute & Hospital, Saharsa, Bihar, India. The authors are grateful to the clinical, nursing, and supporting staff for their valuable assistance and to all study participants for their cooperation and participation.

Author contributions: Dr. Jay Narendra Suratwala contributed to study design, surgical procedures, and data collection. Dr. Nutan Bala contributed to data analysis, interpretation, and manuscript preparation. Both authors critically reviewed and approved the final manuscript.

Conflict of interest: The authors declare that there is no conflict of interest.

References

1. Cayir S, Mutlu H. Traumatic tympanic membrane perforation in children in the emergency department: comparison of spontaneous closure and paper patch. Cureus. 2020;12(4):e7697. doi:10.7759/cureus.7697.
2. Ersözlü T, Gultekin E. A comparison of the autologous platelet-rich plasma gel fat graft myringoplasty and the fat graft myringoplasty for the closure of different sizes of tympanic membrane perforations. Ear Nose Throat J. 2020;99(5):331-336. doi:10.1177/0145561319900388.
3. Khafagy AG, El-Begermy M, El-Begermy MM, Afifi PO. Comparative study between fat plug and inlay butterfly cartilage grafts for myringoplasty in adults. Egypt J Otolaryngol. 2021;37:13. doi:10.1186/s43163-021-00076-y.
4. Ajaiy M, Sankaranarayanan G, Jayaprakash A, Deva Sooria N. A comparative study of using collagen patch or fat plug in myringoplasty for small tympanic membrane perforations. Indian J Otolaryngol Head Neck Surg. 2022;74(Suppl 3):4081-4086. doi:10.1007/s12070-021-02839-8.
5. Mandal MM, Kapadia PB, Panchal AJ, Kumar R. Fat myringoplasty for small central perforation of tympanic membrane: a prospective study. Indian J Otolaryngol Head Neck Surg. 2022;74(Suppl 3):4388-4392. doi:10.1007/s12070-021-03055-0.
6. Tewari V, Tabrez M, Gautam HK, Zehra A, Singh P. Fat graft myringoplasty versus chemical cauterization in small tympanic membrane perforation: a comparative study. Bengal J Otolaryngol Head Neck Surg. 2024;32(1):15-21. doi:10.47210/bjohns.2024.v32i1.62.
7. Mukherjee M, Paul R. Minimyringoplasty: repair of small central perforation of tympanic membrane by fat graft: a prospective study. Indian J Otolaryngol Head Neck Surg. 2013;65(4):302-304. doi:10.1007/s12070-011-0379-3.

8. Han JS, Han JJ, Park JM, Seo JH, Park KH. The long-term stability of fat-graft myringoplasty in the closure of tympanic membrane perforations and hearing restoration. ORL J Otorhinolaryngol Relat Spec. 2021;83(2):85-92. doi:10.1159/000512084.
9. Hegazy HM. Fat graft myringoplasty: a prospective clinical study. Egypt J Ear Nose Throat Allied Sci. 2013;14(2):91-95. doi:10.1016/j.ejenta.2012.11.006.
10. Santhi T, Rajan KV. A study of closure of tympanic membrane perforations by chemical cauterisation. Indian J Otolaryngol Head Neck Surg.2012;64(4):389-392. doi:10.1007/s12070-011-0425-1.
11. Dursun E, Dogru S, Gungor A, Cincik H, Poyrazoglu E, Ozdemir T. Comparison of paper-patch, fat, and perichondrium myringoplasty in repair of small tympanic membrane perforations. Otolaryngol Head Neck Surg. 2008;138(3):353-356. doi:10.1016/j.otohns.2008.01.003.
12. Upreti G. Office myringoplasty by chemical cauterization and paper patching: a prospective study. Int J Otorhinolaryngol Head Neck Surg. 2019;5(1):55-59. doi:10.18203/issn.2454-5929.ijohns20184677.
13. Hagemann M, Häusler R. [Tympanoplasty with adipose tissue]. Laryngorhinootologie. 2003;82(6):393-396. doi:10.1055/s-2003-40537.
14. Landsberg R, Fishman G, DeRowe A, Berco E, Berger G. Fat graft myringoplasty: results of a long-term follow-up. J Otolaryngol. 2006;35(1):44-47. doi:10.2310/7070.2005.4124.