

Plate-Related Complications after Mandibular Reconstruction: An Observational Study of Osteotomy

Ritesh Vatsa¹, Sweta², Neelam Singh³

¹Assistant Professor and HOD, Department of Oral and Maxillofacial Surgery, Government Dental College and Hospital, Nalanda, Bihar, India

²Assistant Professor, Department of Dentistry, Narayan Medical College and Hospital, Jamuhar, Sasaram, Rohtas, Bihar, India

³Senior Resident, Department of Dentistry, Sri Krishna Medical College and Hospital, Muzaffarpur, Bihar, India

Received: 10-03-2025 / Revised: 15-04-2025 / Accepted: 21-05-2025

Corresponding author: Dr. Neelam Singh

Conflict of interest: Nil

Abstract

Background: For oral and mandibular tumors, mandibular reconstruction after bony resection is essential. Certain risk factors may lead to complications following these reconstructive procedures, such as infection, plate exposure, or plate fracture. The aims of this study were to report some of the postoperative complications of reconstruction plates, and to analyze the risk factors associated with those complications.

Methods: This observational study was conducted at Department of Oral and Maxillofacial Surgery, Government Dental College and Hospital, Nalanda, Bihar from September 2024 to February 2025. Total 19 patients analyzed clinical and radiological data who required mandibular reconstructive surgery. The complications related to plates were recorded and used as an objective measure of outcome.

Results: Plate-related complications developed in 8/19 patients. The complications involved screw loosening (n=2), plate fracture (n=2), plate exposure (n=3), and heat sensitivity (n=1). No significant differences were found in plate survival rate in relation to age or sex. Moreover, complications associated with plates developed in 73.68% of the patients with defect in the mandibular body crossing the midline of the mandible. Radiotherapy decreased the survival rate of the plates, as 60% of the irradiated patients had a higher risk of plate-related complications. and angle area and 100% of the patients who had defect crossing the midline of the mandible. Radiotherapy decreased the survival rate of the plates, as 60% of the irradiated patients had a higher risk of plate-related complications.

Conclusion: The survival rate of mandibular reconstruction plate relies on mechanical and biological risk factors in terms of site of mandibular defects and radiation therapy, respectively.

Keywords: mandible reconstruction, survival rate of reconstruction plates, risk factors.

This is an Open Access article that uses a funding model which does not charge readers or their institutions for access and distributed under the terms of the Creative Commons Attribution License (<http://creativecommons.org/licenses/by/4.0>) and the Budapest Open Access Initiative (<http://www.budapestopenaccessinitiative.org/read>), which permit unrestricted use, distribution, and reproduction in any medium, provided original work is properly credited.

Introduction

In order to restore functioning and aesthetic restoration of the lower face following surgical resection of mandibular tumors, postresective mandibular reconstruction is sometimes necessary [1]. Although several techniques for mandibular reconstruction have been presented, such as soft tissue free flaps, reconstruction plates, and bone grafts, bone reconstruction is often the preferred method [2].

However, when the donor bone cannot be harvested or the lesion's prognosis is poor, bone reconstruction may not be possible [3,4]. In such cases, reconstruction plates can be used to restore the patient's jaw integrity, which in turn improves the patient's self-perception and self-confidence

[5]. The first generation of clinically available reconstruction plates was presented in the mid-1970s. Since the early 1980s, the standard treatment for a mandibular discontinuity defect has been the use of a rigid reconstruction plate with simultaneous or subsequent osseous reconstruction [6]. Recently, the efficacy of osteosynthesis has improved with the use of titanium reconstruction plates, which provide better biocompatibility, and locking screws for biomechanical enhancement.

With these improvements, modern reconstruction plates can provide excellent anchorage and rigid fixation [7,8]. Nevertheless, complications such as infection, plate exposure, fracture, or loosening of the fixation still occur occasionally [9]. Decreasing

the risk of complications can be challenging, but optimizing the design and fabrication of reconstruction plates and improving surgical techniques may help reduce those risks [10].

Therefore, this study focused on some of the postoperative complications of reconstruction plates and aimed to analyze the risk factors linked with those complications.

Material and Methods

The study included 19 patients (11 male and eight female) suffering from lesions that necessitated mandibular bony resection. They attended the Department of Oral and Maxillofacial Surgery, Government Dental College and Hospital, Nalanda, Bihar from September 2024 to February 2025. Diagnosis was confirmed by incisional biopsies before surgical resection and planned reconstructions. Twelve cases had ameloblastoma

and the rest of the cases were as follows: odontogenic keratocyst (one case), Pindborg tumor (one case), and squamous cell carcinoma of the mandible (five cases). Informed consents for undergoing the surgical operation were obtained from participants according to the policy of our institution.

The surgical procedures were performed while the patients were under general anesthesia. The resultant defects were classified using HCL (Jewer’s) classification [11]. In this system, H represents a lateral segment of any length containing a condyle and not significantly crossing the midline, L represents the same defect but without a condyle, and C represents the anterior segment between the two incisive foramina. Data for each patient including age, sex, HCL classification, and diagnosis are shown in Table 1.

Table 1: Patient’s demographic data, site, and diagnosis of the lesions

| Patient number | Age | Sex | Area | | | | | Pathological diagnosis |
|----------------|-----|--------|------|---|---|----|----|-------------------------|
| | | | H | C | L | HC | LC | |
| 01 | 24 | Male | | | √ | | | Ameloblastoma |
| 02 | 34 | Female | | | √ | | | Ameloblastoma |
| 03 | 23 | Male | | | √ | | | Ameloblastoma |
| 04 | 26 | Female | | | √ | | | Ameloblastoma |
| 05 | 30 | Male | √ | | | | | Ameloblastoma |
| 06 | 24 | Female | | | √ | | | Ameloblastoma |
| 07 | 19 | Female | | | √ | | | Odontogenic keratocyst |
| 08 | 19 | Female | | | | | √ | Pindborg tumor |
| 09 | 58 | Male | | | | | √ | Squamous cell carcinoma |
| 10 | 21 | Female | | | √ | | | Ameloblastoma |
| 11 | 64 | Male | | | | | √ | Squamous cell carcinoma |
| 12 | 62 | Male | | | √ | | | Squamous cell carcinoma |
| 13 | 41 | Male | | | √ | | | Ameloblastoma |
| 14 | 36 | Female | | | √ | | | Ameloblastoma |
| 15 | 26 | Male | | | √ | | | Ameloblastoma |
| 16 | 67 | Male | | | √ | | | Squamous cell carcinoma |
| 17 | 25 | Female | | | | | √ | Ameloblastoma |
| 18 | 55 | Male | | | √ | | | Ameloblastoma |
| 19 | 70 | Male | | | √ | | | Squamous cell carcinoma |

HC: discontinuity involves the condyle, body and extends beyond the midline; LC: discontinuity involves the ramus and body and extends beyond the midline.

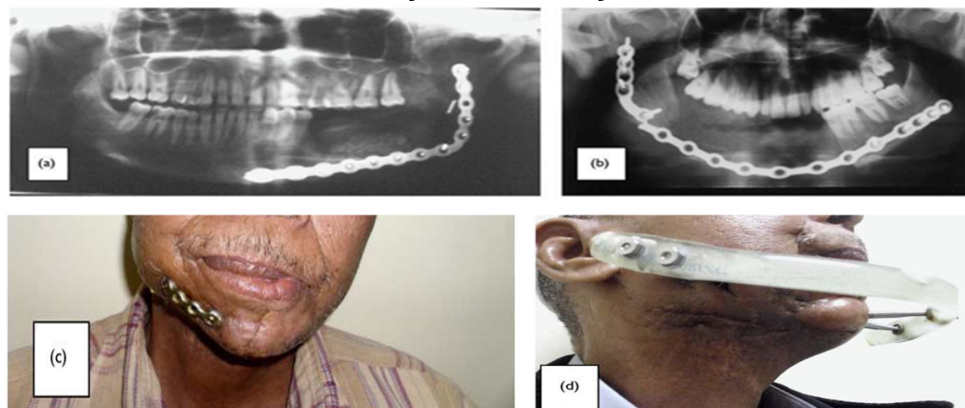


Figure 1:

Fig. 1: Plate-related complications: (a) screw loosening, (b) plate fracture, (c) orocutaneous fistula and plate exposure, (d) application of external pin fixation after plate removal.

The complications related to plates and plate failure were recorded and used as an objective measure of outcome (Fig. 1a–c). Complications were defined as postoperative infection, screws loosening, heat sensitivity, wound dehiscence and plate exposure, or plate fracture that required plate removal.

The survival rate of the reconstruction plates was analyzed according to age, sex, site of defect, and whether postoperative radiation therapy (RT) was a

risk factor. The statistical analysis for significance was tested by Pearson’s χ^2 -test and P value of less than 0.05 was accepted as the level of statistical significance.

Results

The mean age of the patients was 38.26 years and the mean follow-up period was 19 ± 3 months. The patients had a number of different diagnoses, including malignant tumors, benign tumors, and large cyst. Malignant tumors accounted for five (26.31%) cases, benign odontogenic tumors for 13 (68.42%) cases, and large odontogenic cyst for one (5.26%) case (Table 2).

Table 2: Disease processes underlying mandibular discontinuity defect cases

| Pathological diagnosis | No. of Cases | Percentage |
|------------------------|--------------|------------|
| Malignant tumor | 5 | 26.31% |
| Benign tumor | 13 | 68.42% |
| Odontogenic cyst | 1 | 5.26% |

Regarding the site of the lesions, the HCL classification showed that 14 (73.68%) lesions occurred in the mandibular body and angle. Four (21.05%) lesions crossed the midline of the mandible, and one (5.26%) lesion extended from the mandibular body to the ipsilateral condyle (Table 3).

Table 3: Extension of the lesions based on HCL classification

| Site of the lesions | No. of Cases | Percentage |
|--|--------------|------------|
| Mandibular body and angle | 14 | 73.68 |
| Lesions crossed the midline | 4 | 21.052 |
| Lesions extended from the mandibular body to the ipsilateral condyle | 1 | 5.26 |

The overall postoperative plate-related complications and affecting factors are summarized in Table 4. Postoperative plate-related complications occurred in 42.1% (n=8) as follows: screw loosening occurred in 10.52% (n=2) of the

patients. Plate fracture occurred in 10.52% (n=2) of the patients, 15.78% (n=3) of the patients suffered from orocutaneous fistula associated with infection and plate exposure, and finally 5.26% (n=1) suffered from heat sensitivity (Fig. 2).

Table 4: Overall postoperative plate-related complications

| Variables | Assessments | | | | | | | |
|--------------------|----------------|------------------|----------------|----------------|-----------------|----------------|----------------|-----------------|
| | n2 | n8 | n9 | n11 | n13 | n15 | n17 | n19 |
| Age (years) | 34 | 19 | 58 | 64 | 41 | 26 | 25 | 70 |
| Sex | Female | Female | Male | Male | Male | Male | Female | Male |
| Diagnosis | BT | BT | MT | MT | BT | BT | BT | MT |
| HCL classification | L | LC | LC | C | L | L | LC | L |
| Postoperative RT | × | × | √ | √ | × | × | × | √ |
| Complication | Plate fracture | Heat sensitivity | Plate exposure | Plate exposure | Screw loosening | Plate fracture | Plate exposure | Screw loosening |
| Plate removal | √ | × | √ | √ | × | √ | √ | × |

BT: benign tumor; L: lateral segment of any length not containing a condyle; LC: lateral segment of any length crossing the midline; MT: malignant tumor; RT: radiation therapy.

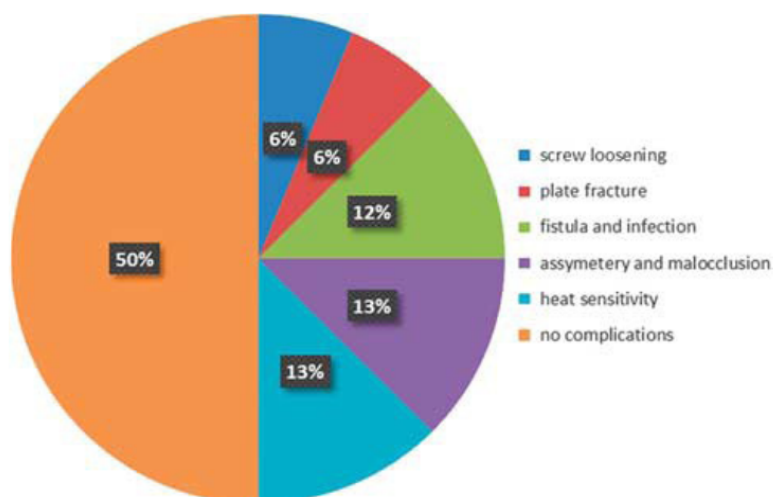


Figure 2: Pie chart showing the percentage of postoperative plate-related complications.

Exposed reconstruction plates associated with orocutaneous fistula and infection was removed, and the patients were treated by external pin fixation (Fig. 1d). Those who experienced plate fracture were treated by replacing the current plate with another plate that was 2.7mm in thickness. Patients with contour defect and those with screw loosening refused the plate removal surgery. Regarding the patient who suffered heat sensitivity, she adapted the complication 3 months later.

χ^2 -Test revealed that the survival rate of the reconstruction plate was not significantly related to the patient's age ($P \geq 0.1$) or sex ($P \geq 0.1$). Complications associated with the reconstruction plate developed in 62.5% of the patients with a discontinuous defect in the mandibular body and angle area. Additionally, 100% of the patients who had discontinuous defect crossing the midline of the mandible suffered plate-related complications. Radiotherapy decreased the survival rate of the plates, as 60% of the irradiated patients had a higher risk of platerelated complications.

Discussion

The success rate of mandibular reconstruction has increased because of improvements in plate designing and materials. However, plate-related complications still develop frequently and can sometimes cause serious problems to patients [12].

Our findings suggest that mechanical risk factors, such as plate strain and fatigue, and biological risk factors, such as RT, affect the reconstruction plate's survival rate. Shibahara [13] reported that bite force upsurges the mechanical stresses on reconstruction plates. These stresses in association with the forces caused by contracture of the masticatory muscles during mastication causes strain, metal fatigue, and eventually plate fracture, which jeopardizes survival rate of the reconstruction plate and accordingly the success of reconstructive surgery [14]. This mechanical risk

factor could justify plate fracture that happened to two of our patients (n2, n15) who encountered resection of the mandibular angle. Besides, our findings ascertained that plate fractures are significantly related to mandibular angle defects.

Furthermore, Arias-Gallo [15] reported that most hardware exposure occurs at sites exposed to higher moment and shear forces. These factors are even exaggerated by the excessive intraoperative bending of titanium reconstruction plates [16]. In the current study, one of our patients (n17) experienced plate exposure at the premolar region owing to plate over-bending.

Radiotherapy is a biological risk factor that leads to plate-related complications. Our findings that RT is significantly associated with plate exposure are consistent with the reports of Ryu [17]. He explained that ionizing radiation causes damage to the small vessels and progressively occlusion and fibrosis of the vessels. This decreases the local tissue vascularity and alteration of the bone-to-metal interface. The poor soft tissue bed causes infection and fistula formation that leads to plate exposure.

In the light of the previous explanation, two patients (n9, n11) developed orocutaneous fistulas and plate exposure. These patients were treated for squamous cell carcinoma and received postoperative radiotherapy. The condition necessitated plate removal and application of external pin fixation together with culture and sensitivity tests to control the infection. The treatment with external pin fixation decreased the tension over the soft tissue by avoiding the bulky hardware underneath the mucosa and thus enhanced the healing.

In addition, Ryu [17] stated that radiotherapy causes back-scatter effect against the titanium plates that increases the risk of local overdoses around the plate and contribute to screw loosening.

This explains why screw loosening occurred in case n19 who was receiving ionizing radiation. On the other hand, loosening of the screws occurred in case n13 who was not receiving RT. Our explanation is consistent with that of Kimura et al. [18], who explained this as a result of the masticatory forces that leads to vertical stress on the plate leading to bone resorption around the screws.

Another complication was heat sensitivity, which was encountered in one patient (n8) owing to the extension of the reconstruction plate anteriorly crossing the midline.

Our results are in agreement with Cavusoglu et al. [19], who reported that some patients might experience cold or heat sensation especially at the anterior region where the mucosa is thin, but the condition soon resolved after about 3 months as the patient can put up to the complication.

Conclusion

The mandibular reconstruction plate's survival rate is significantly related to mechanical and biological risk factors in terms of location of mandibular defects and RT, respectively, and was not significantly related to the age or sex of the patients.

The mandibular reconstruction plate survival rate is significantly related to biological risk factors, such as location of mandibular defects, RT, and mechanical risk factors.

References

- Schmeizeisen R, Schön R. Microvascular reanastomosed allogeneous iliac crest transplants for the reconstruction of bony defects of the mandible in miniature pigs. *Int J Oral Maxillofac Surg* 2008; 27:377–385.
- Anthony J. Donor leg morbidity and function after fibula free flap mandible reconstruction. *Plast Reconstr Surg* 2015; 96:146–152.
- Boyd J. Use of reconstruction plates in conjunction with soft-tissue free flaps for oromandibular reconstruction. *Clin Plast Surg* 2024; 21:69–77.
- Urken M. Oromandibular reconstruction using microvascular composite flaps: report of 210 cases. *Arch Otolaryngol Head Neck Surg* 2018; 124:46–55.
- Maurer P, Eckert AW, Kriwalsky MS, Schubert J. Scope and limitations of methods of mandibular reconstruction: a long-term follow-up. *Br J Oral Maxillofac Surg* 2010; 48:100–104.
- Peacock ZS, Afshar S, Lukas SJ, Kaban LB. Customized repair of fractured mandibular reconstruction plates. *J Oral Maxillofac Surg* 2012; 70: e563–e573.
- Knott P. Evaluation of hardware-related complications in vascularized bone grafts with locking mandibular reconstruction plate fixation. *Arch Otolaryngol Head Neck Surg* 2017; 133:1302–1306.
- Szypryt P. The use and abuse of locking plates. *Orthop Trauma* 2009; 23:281–290.
- Probst FA, Mast G, Ermer M, Gutwald R, Schmelzeisen R, Pautke C, et al. Matrix Mandible preformed reconstruction plates – a two-year two institution experience in 71 patients. *J Oral Maxillofac Surg* 2012; 70: e657– e666.
- Cohen A, Laviv A, Berman P, Nashef R, Abu-Tair J. Mandibular reconstruction using stereolithographic 3-dimensional printing modeling technology. *Oral Surg Oral Med Oral Pathol Oral Radiol Endod* 2009; 108:661–666.
- Jewer D. Orofacial and mandibular reconstruction with the iliac crest free flap: a review of 60 cases and a new method of classification. *Plast Reconstr Surg* 1989; 84:391–403.
- Seol G-J. Reconstruction plates used in the surgery for mandibular discontinuity defect. *J Korean Assoc Oral Maxillofac Surg* 2014; 40:266–271.
- Shibahara T. Fracture of mandibular reconstruction plates used after tumor resection. *J Oral Maxillofac Surg* 2002; 60:182–185.
- Nagasao T, Miyamoto J, Tamaki T, Kawana H. A comparison of stresses in implantation for grafted and plate-and-screw mandible reconstruction. *Oral Surg Oral Med Oral Pathol Oral Radiol Endod* 2010; 109:346–356.
- Arias-Gallo J. Long term results of reconstruction plates in lateral mandibular defects. Revision of nine cases. *Auris Nasus Larynx* 2004; 31:57–63.
- Knoll W-D. Analysis of mechanical stress in reconstruction plates for bridging mandibular angle defects. *J Craniomaxillofac Surg* 2006; 34: 201–209.
- Ryu J. Mandibular reconstruction using a titanium plate: the impact of radiation therapy on plate preservation. *Int J Radiat Oncol Biol Phys* 1995; 32:627–634.
- Kimura A, Nagasao T, Kaneko T, Tamaki T, Miyamoto J, Nakajima T. Adequate fixation of plates for stability during mandibular reconstruction. *J Craniomaxillofac Surg* 2006; 34:193–200.
- Cavusoglu T. Resorbable plate-screw systems: clinical applications. *Ulus Travma Acil Cerrahi Derg* 2005; 11:43–48.