

Utility of Cytology Along with Ziehl Neelsen Stain and Cartridge Based Nucleic Acid Amplification Test for Rapid Diagnosis of Tubercular Lymphadenitis in High Burden Setting

Moumita Chatterjee¹, Nikhilesh Dewasi², Ankita Chakraborty³, Soumik Dandapat⁴, Sourav Das⁵, Rupam Karmakar⁶

¹Senior Resident, Department of Pathology Bolpur Sub-divisional Hospital, Birbhum

²Assistant Professor, Department of Pathology, Burdwan Medical College and Hospital

³Senior Resident, Department of Pathology, Chhatna Multi/Super Speciality Hospital, Bankura

⁴Senior Resident, Department of Community Medicine, Burdwan Medical College and Hospital

⁵RMO/Clinical Tutor, Department of Anesthesiology, Calcutta National Medical College & Hospital

⁶Professor and Head, Department of Pathology, Burdwan Medical College and Hospital

Received: 01-05-2025 / Revised: 15-06-2025 / Accepted: 21-07-2025

Corresponding author: Dr. Nikhilesh Dewasi

Conflict of interest: Nil

Abstract

Introduction: TB lymphadenitis is the commonest form of EPTB, but its diagnosis remains a challenge. FNAC is widely used, though it lacks specificity. ZN staining provides confirmation, but sensitivity is low. CBNAAT has emerged as rapid and reliable diagnostic tool in this context.

Aim: To evaluate the utility of FNAC with ZN stain in comparison to CBNAAT for rapid diagnosis of tuberculous lymphadenitis in a tertiary care center in Eastern India.

Materials and Methods: This cross-sectional study was conducted at Burdwan Medical College and Hospital, from June'23-May'24. Sixty clinically suspected cases of TB lymphadenitis were evaluated. FNAC smears were examined for cytomorphology and stained with ZN stain. Remaining aspirated material was tested using CBNAAT. Diagnostic performance parameters were calculated.

Results: Mean age of participants was 37.77 ± 19.52 years, with majority being male (68.33%) and belonged to 31–50 years group. Cervical lymph node was most commonly involved site (86.67%). FNAC findings were reactive lymphoid hyperplasia (30.00%), epithelioid granuloma without necrosis (21.67%), suppurative lesions (21.67%), epithelioid granuloma with necrosis (13.33%), and caseous necrosis without epithelioid cells (11.67%). CBNAAT positivity was 36.67%, double that of ZN stain (18.33%). Epithelioid granuloma with necrosis showed the highest positivity (87.50% CBNAAT, 87.50% ZN stain). All suppurative aspirates were ZN stain negative but 30.77% CBNAAT positive. Compared with CBNAAT, ZN stain showed sensitivity of 45.45%, specificity 97.37%, PPV 90.91%, NPV 75.51%, diagnostic accuracy 78.33%, and a weak agreement ($\kappa = 0.48$).

Conclusions: FNAC is a good first test for TB lymphadenitis, ZN stain is specific but often misses cases, while CBNAAT detects more, even in ZN-negative samples. Using all three together gives faster, more accurate diagnosis in high-burden, low-resource settings.

Keywords: Cartridge Based Nucleic Acid Amplification Test (CBNAAT), Fine Needle Aspiration Cytology (FNAC), Tuberculous lymphadenitis, Ziehl–Neelsen (ZN) stain.

This is an Open Access article that uses a funding model which does not charge readers or their institutions for access and distributed under the terms of the Creative Commons Attribution License (<http://creativecommons.org/licenses/by/4.0>) and the Budapest Open Access Initiative (<http://www.budapestopenaccessinitiative.org/read>), which permit unrestricted use, distribution, and reproduction in any medium, provided original work is properly credited.

Introduction

Tuberculosis (TB) is an infectious disease caused by organisms belonging to the *Mycobacterium tuberculosis* complex. Among these, *M. tuberculosis* is the most widespread and clinically significant species affecting humans [1]. World Health Organization (WHO) 2022 report revealed the global burden of tuberculosis (TB) rose from 10.1 million cases and 1.5 million deaths in 2020 to 10.6 million cases and 1.6 million deaths in 2021.

There was a significant increase in the incidence rate (3.6%) [2]. TB continues to be a major public health problem, particularly in low- and middle-income countries, where it creates significant challenges to disease control and adds burden to the overall health system [3]. India bears the heaviest TB burden, contributing to nearly one-fifth (about 21%) of all TB cases reported globally [4]. Pulmonary TB is the most common form of

tuberculosis, but it can actually affect almost every organ or system in the body. According to the WHO classification, Extrapulmonary Tuberculosis (EPTB) refers to infection caused by *M. tuberculosis* that occurs in sites other than the lung parenchyma. [5] EPTB most commonly involves lymph nodes, genitourinary tract, bones and joints, and the central nervous system, while peritoneum and other abdominal organs being affected less frequently. TB lymphadenitis is the leading cause of cervical lymph node enlargement in countries where TB is endemic, attributing 30% to 80% of all EPTB cases [6]. TB lymphadenitis is often neglected in global TB control programs as it plays only a minor role in disease transmission [7]. But, it still holds significance for the future of TB control as this form of TB can reactivate later, often involves less obvious areas of the body, usually carries a small number of bacteria, and is often detected at an advanced stage usually with complications [8]. In this scenario, accurate and timely diagnosis of TB lymphadenitis is essential, as this ensures effective treatment and also helps to prevent further complications.

Fine Needle Aspiration Cytology (FNAC) is a rapid and simple method for diagnosis of TB lesions, but it lacks specificity [9]. Conventional smears with Acid Fast Bacilli (AFB) stain prepared from aspirated material of FNAC lacks sensitivity because of its paucibacillary nature [10]. So, both the techniques have limitations, and they do not provide any information regarding neither specific species nor drug resistance. Culture and drug susceptibility testing can address these limitations; but, in resource-poor settings they are often not readily available, and even when available, the results may take 4 to 8 weeks or even longer [11]. In line with these limitations more rapid and reliable methods were needed. In December 2010, WHO proposed Cartridge Based Nucleic Acid Amplification Test (CBNAAT)/GeneXpert MTB/RIF1 (Cepheid, USA) for use in TB laboratories [12]. CBNAAT was first adopted in India under RNTCP in 2012 and was started as a pilot project in Maharashtra [13].

The CBNAAT is a cartridge-based assay that runs within a completely closed system and uses real-time PCR technology. It can detect tuberculosis as well as rifampicin resistance in less than two hours [14]. CBNAAT was initially developed and validated for sputum samples, particularly for HIV associated TB and multidrug-resistant TB diagnosis. Currently WHO [15] as well as Government of India [16] strongly recommends its widespread use for all TB patients. Several studies have also demonstrated the usefulness of CBNAAT on non-respiratory specimens in the diagnosis of EPTB [4].

In this context, the present study was undertaken to evaluate the utility of FNAC along with ZN Stain in comparison to CBNAAT for rapid diagnosis of suspected Tubercular lymphadenitis in a high burden settings.

Aims and Objective: This study was done to assess the efficacy of FNAC along with ZN stain positivity in comparison to CBNAAT for the diagnosis of TB among suspected patients of TB lymphadenitis attending in a tertiary care center in Eastern India.

Materials and Methods

Study area, design and duration: This hospital-based cross-sectional prospective study was conducted among the patients suspected of having TB lymphadenitis in the department of pathology, Burdwan Medical College and Hospital (BMCH) from June 2023 to May 2024 (12 months).

Sample size and sampling technique: According to the Global TB Report 2020, EPTB constituted 19% of reported TB cases in Southeast Asia [17]. Taking this prevalence, with 95% level of confidence and considering an absolute precision of 10% the minimum required sample size was found to be 60. All new clinically suspected patients of tuberculous lymphadenitis, referred from the Outpatient Department to the Pathology Department of BMCH, with adequate purulent or serous material from FNA, were consecutively enrolled in this study after obtaining informed consent until the required sample size was reached. Known patients of TB receiving anti-tubercular therapy, and recurrent or follow-up patients were excluded.

Sample collection and processing: For the diagnosis of Tubercular lymphadenitis, the ZN staining technique and CBNAAT were used. In the absence of culture, CBNAAT was considered the reference standard to which ZN staining was compared. In a newly suspected Tubercular lymphadenitis case, FNAC was done using 22-gauge needle attached to a 10 ml syringe, and the material was obtained by applying suction with repeated back-and-forth movements to ensure adequacy of sample. Three conventional cytology smears were prepared following standard procedures for Papanicolaou [18], Leishman [19] and ZN staining [20]. The remaining material was sent in a presterilized Falcon tube for CBNAAT. The final outcome of the procedure was reported as positive/negative (anyone).

Cytological diagnosis: The air-dried FNAC smears were stained with Papanicolaou [18], Leishman [19] stain according to the SOPs and examined microscopically by experienced pathologists. In tuberculosis, common cytological

findings include epithelioid granulomas, granulomas containing multinucleated giant cells, areas of necrosis, and degenerated inflammatory cells. [21]

Ziehl-Neelsen (ZN) staining: ZN staining was performed according to the SOP [20], and the stained smears were examined under the oil-immersion objective (100x) of a light microscope. At least 100 fields were examined before reporting a slide as negative.

CBNAAT: The specimens were processed for detection of TB using CB-NAAT according to the Gene Xpert system operator manual given by Central TB division, Government of India [22], using Xpert MTB/RIF assay, made by Cepheid-Sunnyvale-USA. As per the standard operating procedure, the sample was mixed with assay sample reagent (a mixture of NaOH and isopropanol) in a 1:2 ratio and kept at room temperature for 15 minutes with intermittent shaking. Three ml of this treated sample was then transferred to the cartridge and the cartridge was inserted into the module of CB-NAAT instrument where 4 cartridges containing 4 samples were processed at each run, remaining assay steps were completed by an automatic process within 1 hour and 50 minutes and the result was displayed on the monitor as positive or negative. [23,24]

Analysis: The data were analyzed using JAMOV version 2.4.11.0. The collected data were compiled and analysed, and the results were presented in tabular and graphical formats, expressed in terms of frequency and percentage. Sensitivity, specificity, PPV, NPV, likelihood ratios and Kappa coefficient were determined. The agreement between the tests

and the reference method were evaluated using the Kappa value. The kappa values were categorized as follows: 0–0.20 indicating no agreement, 0.21–0.39 minimal agreement, 0.40–0.59 weak agreement, 0.60–0.79 moderate agreement, 0.80–0.90 strong agreement, and above 0.90 representing almost perfect agreement [25]. P-value of less than 0.05 was considered statistically significant.

Ethical clearance: The study was approved by the Institutional Review Board of Burdwan Medical College (Memo no: BMC/I.E.C./522). Participants were made aware of the study's purpose and procedures before their involvement. Data were collected after written informed consent and/or assent was obtained from the study participants or the parents/ guardians. Strict confidentiality was maintained throughout the study.

Results

In this study, cytological findings of FNAC sample along with ZN stain from 60 suspected TB lymphadenitis patients were compared with the corresponding CBNAAT findings. Mean age of the study participants were 37.77 years (SD \pm 19.52). Majority of the participants were male (68.33%). Cervical lymph node was the most commonly involved site overall (86.67%), followed by axillary (8.33%) and inguinal nodes (5.00%). Similar pattern was seen in male and female participants with cervical lymph node involvement was higher (90.24% and 78.95% respectively) and it was consistent across all age groups. Although, axillary (15.79% vs 4.88%) and inguinal (5.26% vs 4.88%) node involvement were relatively higher in female than in males. [Table 1, Figure 1]

Table 1: Distribution of study participants according to their gender and site of FNAC. (n=60)

Gender	Site [Frequency (%)]			Test statistics
	Axillary lymph node	Cervical lymph node	Inguinal lymph node	
Male (N ₁ =41)	2 (4.88)	37 (90.24)	2 (4.88)	P=0.399*
Female (N ₂ =19)	3 (15.79)	15 (78.95)	1 (5.26)	
Total (n=60)	5 (8.33)	52 (86.67)	3 (5.00)	

*Fischer exact test

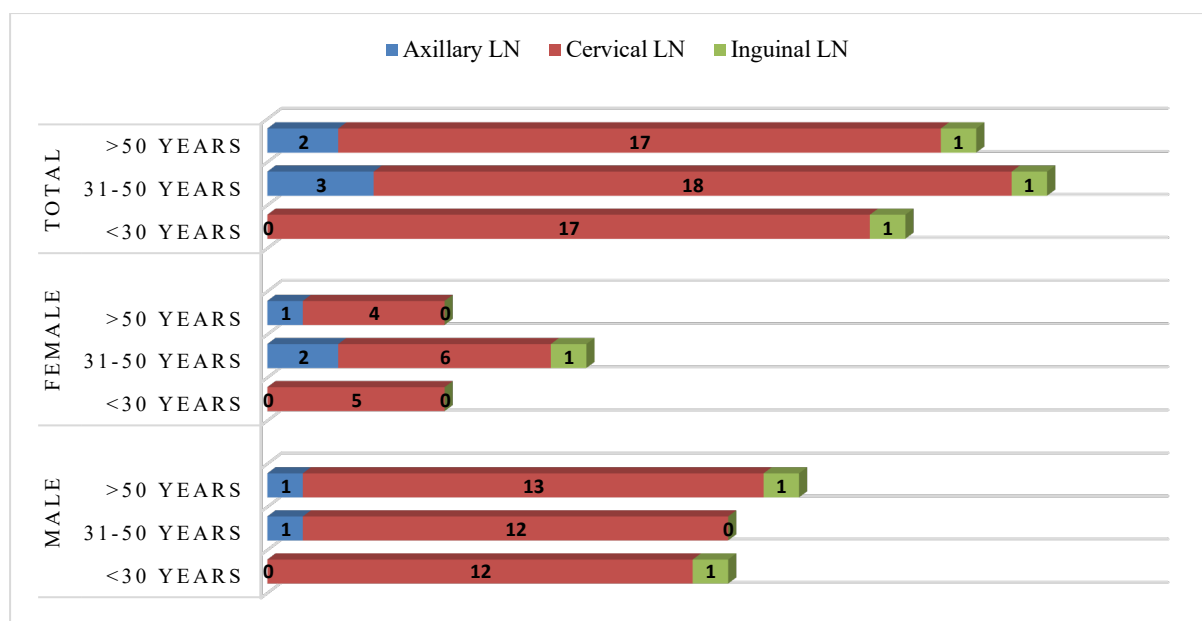


Figure 1: Clustered stacked bar diagram showing distribution of study participants according to their age, gender and site of FNAC. (n=60)

The most frequent cytological diagnosis was reactive lymph node hyperplasia (30.00%), followed by epithelioid granuloma without necrosis (21.67%), suppurative lesions (21.67%), epithelioid granuloma with necrosis (13.33%), and caseous necrosis without epithelioid cells (11.67%). Only one case of lymphoma was observed. CBNAAT was positive in 36.67% of cases, nearly double that of ZN staining (18.33%). Cases with cytological finding of epithelioid granuloma with necrosis had the highest positivity for both CBNAAT and ZN

stain (87.50% each), while cases having caseous necrosis without epithelioid cells showed high CBNAAT (85.71%) but lower ZN stain positivity (42.86%). Aspirate with epithelioid granulomas without necrosis had lower positivity in both CBNAAT (38.46%) and ZN stain (7.69%). All of the suppurative lesions were ZN stain negative but showed CBNAAT positivity in 30.77% of cases. Both CBNAAT and ZN stain were negative in all reactive lymphoid hyperplasia and lymphoma. [Table 2]

Table 2: Distribution of study participants according to their FNAC finding with CBNAAT and ZN stain outcome. (n=60)

FNAC finding	ZN stain [Frequency (%)]		CBNAAT [Frequency (%)]		Total
	Positive	Negative	Positive	Negative	
Caseous necrosis without epithelioid cell	3(42.86)	4(57.14)	6(85.71)	1(14.29)	7(100.00)
Epithelioid granuloma with necrosis	7(87.50)	1(12.50)	7(87.50)	1(12.50)	8(100.00)
Epithelioid granuloma without necrosis	1(7.69)	12(92.31)	5(38.46)	8(61.54)	13(100.00)
Lymphoma	0(0.00)	1(100.00)	0(0.00)	1(100.00)	1(100.00)
Reactive lymph node hyperplasia	0(0.00)	18(100.00)	0(0.00)	18(100.00)	18(100.00)
Suppurative lesion	0(0.00)	13(100.00)	4(30.77)	9(69.23)	13(100.00)
Total	11(18.33)	49(81.67)	22(36.67)	38(63.33)	60(100.00)

Table 3 shows the diagnostic performance of Ziehl–Neelsen (ZN) staining against CBNAAT as the reference standard in tuberculosis lymphadenitis (n = 60). The overall agreement between the two tests was 78%, with $\kappa = 0.48$, $p < 0.001$ (weak agreement). ZN staining demonstrated a sensitivity of 45.45 % (95% CI: 24.39-67.79) and a specificity of 97.37 % (95% CI: 86.19-99.93). The diagnostic accuracy was 78.33% (95% CI: 65.80–87.93). The positive predictive value was

relatively higher (90.91 %), whereas the negative predictive value was 75.51 %, indicating that a positive ZN result reliably confirmed tuberculosis. ZN staining yielded a positive likelihood ratio of 17.27 and a negative likelihood ratio of 0.56. Using Fagan's nomogram with a pre-test probability of 19% (study prevalence), the post-test probability increased to 80% following a positive ZN result, whereas it decreased to 12% after a negative test result. This demonstrates that ZN staining is more

useful in confirming tuberculosis lymphadenitis than ruling out. [Figure 2]

Table 3: Diagnostic performance of Ziehl-Neelsen staining technique compared to the CBNAAT reference standard in the diagnosis of tuberculosis lymphadenitis. (n=60)

CBNAAT	ZN stain		Total	Agreement 78% Kappa 0.4786 Z 4.131 p-value< .001
	Positive	Negative		
Positive	10	12	22	
Negative	1	37	38	
Total	11	49	60	
Decision Statistics			Estimate	95% Confidence Interval
Test sensitivity			45.45 %	24.39-67.79
Test specificity			97.37 %	86.19-99.93
Diagnostic accuracy			78.33 %	65.80-87.93
Positive predictive value			90.91 %	58.72-99.77
Negative predictive value			75.51 %	61.13-86.66
Likelihood ratio of a positive test			17.27	2.37-126.04
Likelihood ratio of a negative test			0.56	0.38-0.82

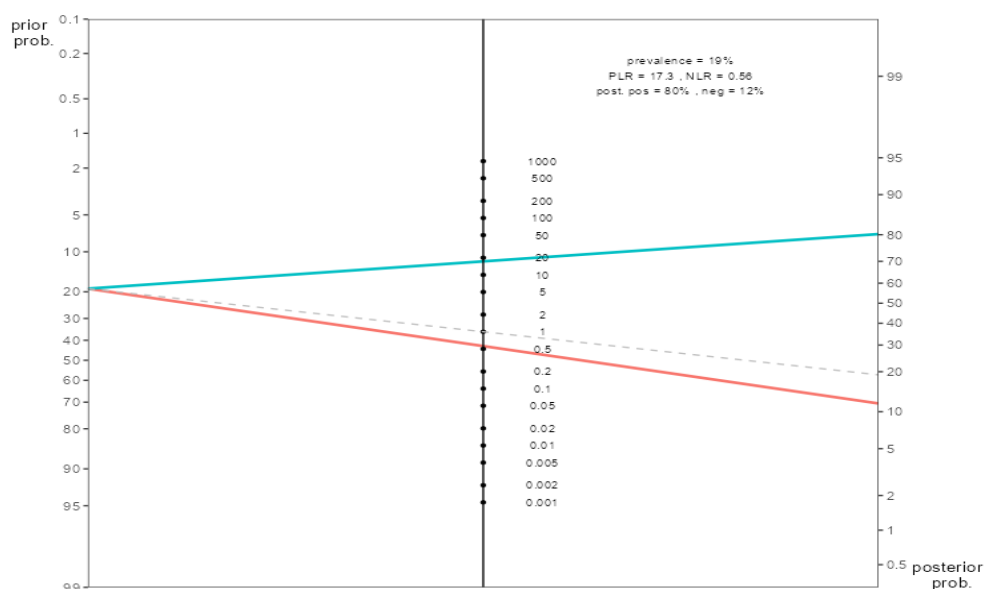


Figure 2: Fagan's Nomogram depicting pre and post-test probabilities of TB lymphadenitis using ZN staining.

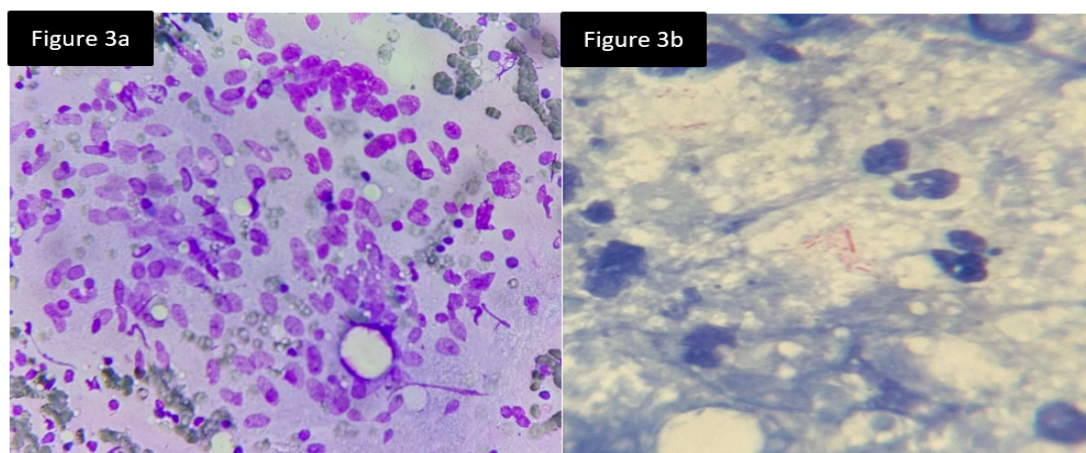


Figure 3a: Smear shows granuloma composed of epithelioid cells, lymphocytes in a necrotic background (Leishman stain, 40x). Figure 3b: Smear shows slender, beaded, acid fast bacilli scattered among inflammatory cells (Z-N stain, 100x).

Discussion

TB lymphadenitis is the most common type of EPTB, and its early diagnosis is crucial for cure as well as for preventing community transmission. WHO has set the ambitious goal of ending TB by 2030 [26], but achieving this requires emphasis on simple, reliable, and timely diagnostic approaches for EPTB, which is often neglected. Because of the low bacterial load, developing a reliable diagnostic modality is often difficult. FNAC is widely used since it is easy to perform, safe, reliable, and affordable. Although presence of granulomas, giant cells, and caseous necrosis often supports a diagnosis of TB lymphadenitis, but these features are not specific and may also be seen in other conditions such as fungal infection and other inflammatory lesions. Tests like ZN staining can confirm AFB when present, but their sensitivity is low. Culture is the gold standard, but it is rarely feasible in resource-poor settings due to technical and safety requirements. In such contexts, CBNAAT has emerged as a rapid and more dependable alternative.

In high-resource countries, culture and molecular assays are standard. But in developing regions, including parts of Africa and Asia, cost-effective tools such as FNAC and ZN staining continue to play a crucial role in diagnosing TB.

In the current study, mean age of the suspected TB lymphadenitis patients was 37.77 years (SD ± 19.52), with the majority belonging to 31–50 years age group. Most of the patients were male (68.33%). This finding is consistent with Shilpa G. et al. [27], reported a mean age of 34 years and a male-to-female ratio of 1.26:1. Siddegowda M.S. et al. [28] observed equal male and female involvement, most of whom were in the 16–30 years group. Although Patil S.B. et al. [29] found a female predominance (59.2%) with the highest frequency in 21–30 years, while Komanapalli S.K. et al. [4] reported that young adults were most commonly affected, with females comprising of 51% of cases. Similarly, Arpitha K. et al. [30] reported majority of patients were young adults, with females comprising 57.14%. These variations highlight that while male predominance is often seen, several large studies demonstrate majority female involvement, suggesting gender distribution may vary due to geographical, socio-cultural and referral patterns.

Cervical lymph nodes were the most commonly involved site in our study (86.67%), followed by axillary (8.33%) and inguinal nodes (5.00%). This strong cervical involvement is a consistent feature across published literatures. Shilpa G. et al. [27] described cervical involvement in 91% of cases, Arpitha K. et al. [30] in 64.7% cases, and

Siddegowda M.S. et al. [28] also recorded 84.1% cervical lymph node involvement. Axillary and inguinal nodes were much less frequently affected across studies, though Patil et al. [29] noted a slightly higher extra-cervical node involvement in females.

In the present study, the most frequent FNAC pattern was reactive lymphoid hyperplasia (30.00%), followed by epithelioid granuloma without necrosis (21.67%), suppurative lesions (21.67%), epithelioid granuloma with necrosis (13.33%), and caseous necrosis without epithelioid cells (11.67%). CBNAAT positivity was 36.67%, nearly twice that of ZN staining (18.33%) positivity. Epithelioid granuloma with necrosis was positive in 87.50% cases by both CBNAAT and ZN stain, and caseous necrosis without epithelioid cells in 85.71% by CBNAAT but only 42.86% by ZN stain. While epithelioid granuloma without necrosis showed lower detection (38.46% CBNAAT, 7.69% ZN stain), and suppurative aspirates were entirely ZN stain negative but 30.77% CBNAAT positive. These findings are similar with Arpitha K. et al. [30], who reported CBNAAT positivity of 65.0% in granulomatous, 42.85% in necrotising, and 64.28% in suppurative aspirates, with ZN stain negativity in all suppurative cases. Shilpa G. et al. [27] also found highest positivity in only necrotic smears (83% AFB, 66% CBNAAT) and lower in granuloma with necrosis (7% AFB, 21.4% CBNAAT). Similarly, Siddegowda M.S. et al. [28] found that among CBNAAT-positive cases, 36.7% showed epithelioid granuloma with caseous necrosis, 33.3% caseous necrosis without epithelioid cells. Patil S.B. et al. [29] also found higher CBNAAT positivity (33.2%) compared to ZN stain (21.4%). These results suggest that necrotising cytology strongly predicts CBNAAT positivity, while suppurative lesions should not be overlooked despite of negative AFB result.

In this study, the sensitivity and specificity of ZN stain was 45.45% and 97.37% respectively when compared to CBNAAT as the reference standard, with an diagnostic accuracy of 78.33%. The positive predictive value (PPV) was high (90.91%), while the negative predictive value (NPV) was lower (75.51%). The likelihood ratio of a positive test was 17.27, whereas the likelihood ratio of a negative test was 0.56. Patil S.B. et al. [29] found ZN stain sensitivity of 46.35% and specificity of 97.97% against cytology, very similar to our findings. Kumbi et al. [7] in Ethiopia found ZN sensitivity of 73.2% and specificity of 97.4% against GeneXpert, with PPV 96.2% and NPV 80.1%, but reported poor agreement ($\kappa = -0.253$), again showing high specificity but inconsistent sensitivity of ZN stain. In our study, ZN stain

showed a lower sensitivity compared to the findings from India by Lavanya G. et al. [31] (83.3%) and Singh K. et al. [3] (91%), while it was higher than that reported from Bangladesh by Nur T. et al. [32] (17.6%) and Ethiopia by Derese Y. et al. [33] (22.9%). The specificity of ZN stain in this study was found to be lower compared to the findings reported from Bangladesh by Nur T. et al. [32] (98.4%), while it was higher than in Ethiopia by Derese Y. et al. [33] (92.4%), India Lavanya G. et al. [31] (88.9%), India by Singh K. et al. [3] (90%), and South Africa by Ligthelm LJ. et al. [34] (88.9%).

These findings suggest that while ZN staining retains value as a rapid, inexpensive confirmatory test due to its high specificity and strong PPV, its modest sensitivity and low NPV implied that a negative result cannot reliably exclude TB lymphadenitis. CBNAAT consistently demonstrates higher case detection and should be used to complement ZN stain, especially in cytological patterns such as suppurative or necrotising aspirates.

Conclusions

FNAC still remains a useful first-line investigation in suspected cases of TB lymphadenitis, with necrotizing cytological patterns showing the strongest association with microbiological confirmation. While ZN stain has high specificity, but its sensitivity remains low. CBNAAT demonstrates better diagnostic yield, especially in paucibacillary disease. Therefore, adopting a stepwise strategy that combines FNAC, ZN stain, and CBNAAT can provide a faster, more reliable, and accurate diagnosis, particularly in resource-constrained, high-burden settings.

Acknowledgement: The authors are thankful to the technicians and staffs of the Pathology department of Burdwan Medical College and Hospital for their kind co-operation.

References

1. Delogu G, Sali M, Fadda G. The biology of mycobacterium tuberculosis infection. *Mediterr J Hematol Infect Dis*. 2013; 5(1):e2013070.
2. Bagcchi S. WHO's global tuberculosis report 2022. *Lancet Microbe*. 2023 Jan; 4(1):e20.
3. Singh KG, Tandon S, Nagdeote S, Sharma K, Kumar A. Role of CB-NAAT in diagnosing Mycobacterial tuberculosis and rifampicin resistance in tubercular peripheral lymphadenopathy. *Int J Med Res Rev*. 2017; 5(3):242-6.
4. Komanapalli SK, Prasad U, Atla B, Nammi V, Yendluri D. Role of CB-NAAT in diagnosing extra pulmonary tuberculosis in correlation with FNA in a tertiary care center. *International Journal of Research in Medical Sciences*. 2018 Nov 26; 6(12):4039-45.
5. Ramirez-Lapausa M, Menendez-Saldana A, Noguerado-Asensio A. Extrapulmonary tuberculosis: an overview. *Rev Esp Sanid Penit*. 2015; 17(1):3-11.
6. Jayakumar P, Kaushal M, Duggal N. Comparison of CBNAAT and AFB screening using Ziehl Neelsen stain and fluorescent stain on FNAC sample for rapid diagnosis of tubercular lymphadenitis. *Indian Journal of Pathology and Oncology*. 2025 Jul 26; 10(3):249-58.
7. Kumbi H, Ali MM, Abate A. Performance of fine needle aspiration cytology and Ziehl-Neelsen staining technique in the diagnosis of tuberculosis lymphadenitis. *BMC Infectious Diseases*. 2024 Jun 25; 24(1):633.
8. Sharma SK, Mohan A, Kohli M. Extrapulmonary tuberculosis. *Expert Rev Respir Med*. 2021; 15(7):931-48.
9. Bekedam HJ, Boeree M, Kamenya A, Liomba G, Ngwira B, Subramanyam VR, Harries AD. Tuberculous lymphadenitis: a diagnostic problem in areas of high prevalence of HIV and tuberculosis. *Trans R Soc Trop Med Hyg*. 1997 May-Jun; 91(3):294-7.
10. Annam V, Karigoudar MH, Yelikar BR. Improved microscopical detection of acid-fast bacilli by the modified bleach method in lymph node aspirates. *Indian J Pathol Microbiol*. 2009; 52(3):349-52.
11. Gholoobi A, Masoudi-Kazemabad A, Meshkat M, Meshkat Z. Comparison of culture and PCR methods for diagnosis of Mycobacterium tuberculosis in different clinical specimens. *Jundishapur J Microbiol*. 2014; 7(2):e8939.
12. Kashyap B, Sarkar K, LNU S, Banik D, Hyanki P. Evaluating diagnostic performance of extrapulmonary tuberculosis using cartridge-based nucleic acid amplification test assay: a retrospective cross-sectional study at a tertiary health care setup in India. *EMJ*. 2024; 9(4):89-96.
13. Dewan R, Anuradha S, Khanna A, Garg S, Singla S, Ish P, Agarwal S. Role of cartridge-based nucleic acid amplification test (CBNAAT) for early diagnosis of pulmonary tuberculosis in HIV. *J Indian Acad Clin Med*. 2015; 16(2):114-7.
14. Lawn SD, Nicol MP. Xpert MTB/RIF assay: development, evaluation and implementation of a new rapid molecular diagnostic for tuberculosis and rifampicin resistance. *Future Microbiol*. 2011; 6(9):1067-82.
15. World Health Organization. Automated real-time nucleic acid amplification technology for rapid and simultaneous detection of

- tuberculosis and rifampicin resistance: Xpert MTB/RIF assay for the diagnosis of pulmonary and extrapulmonary TB in adults and children: policy update. Geneva: World Health Organization; 2013.
16. Pai M, Swaminathan S. India is well placed to scale innovations in tuberculosis diagnostics. *Indian J Med Res.* 2023; 157(2&3):114-7.
 17. Ministry of Health and Family Welfare, Government of India. India TB report 2023 [Internet]. New Delhi: Ministry of Health and Family Welfare, Government of India; 2023 [cited 2023 Apr 27]. Available from: <https://tbcindia.mohfw.gov.in/2023/06/06/indiatb-report-2023/>.
 18. Thakur M, Guttikonda VR. Modified ultrafast Papanicolaou staining technique: A comparative study. *J Cytol.* 2017; 34(3):149-53.
 19. Bain BJ, Lewis SM. Preparation and staining methods for blood and bone marrow films. In: Dacie and Lewis Practical Haematology. 10th ed. Philadelphia: Churchill Livingstone Elsevier; 2006. p. 59-77.
 20. Prakoeswa F, Rumondor B, Prakoeswa C. Acid-Fast Staining Revisited, a Dated but Versatile Means of Diagnosis. *Open Microbiol J.* 2022; 16: e187428582206081.
 21. Fantahun M, Kebede A, Yenew B, Gemechu T, Mamuye Y, Tadesse M, et al. Diagnostic accuracy of Xpert MTB/RIF assay and non-molecular methods for the diagnosis of tuberculosis lymphadenitis. *PLoS One.* 2019; 14(9):e0222402.
 22. Central TB Division, Directorate General of Health Services, Ministry of Health & Family Welfare. Index-TB Guidelines: Guidelines on extra-pulmonary tuberculosis for India. New Delhi: Ministry of Health & Family Welfare; 2016. Standard operating procedure for CBNAAT (Xpert MTB/RIF). p. 148-51.
 23. Central TB Division, Directorate General of Health Services. Guidance document for use of cartridge based-nucleic acid amplification test (CB-NAAT) under Revised National TB Control Programme (RNTCP). New Delhi: Ministry of Health and Family Welfare, Government of India; 2013.
 24. Ministry of Health and Family Welfare. Guidelines for programmatic management of drug resistant TB in India. New Delhi: Ministry of Health and Family Welfare; 2021.
 25. McHugh ML. Interrater reliability: the kappa statistic. *Biochem Med (Zagreb).* 2012; 22(3):276-82.
 26. Martini M, Barberis I, Gazzaniga V, Icardi G. The fight to end tuberculosis: a global challenge in strong partnership. *J Prev Med Hyg.* 2020; 61(1 Suppl 1):E1-2.
 27. R SA, A MH, E CB, Francis R, G S. Role of fine needle aspiration cytology as a diagnostic tool in lymphadenopathy with utility of CBNAAT in tuberculous lymphadenopathy. *IP Archives of Cytology and Histopathology Research.* 2025 Jul 28; 4(1):61-4.
 28. Siddegowda MS, S S, U MM. Comparative study of fine needle Aspiration Cytology, Acid Fast Bacilli staining and Cartridge Based Nucleic Acid Amplification test in the diagnosis of extrapulmonary tuberculosis. *IP Journal of Diagnostic Pathology and Oncology.* 2025 Jul 19; 5(2):151-6.
 29. Patil SB, Dhage SM, Umap PS, Ghorpade SV, Patharwat S. Cartridge based nucleic acid amplification test: a sensitive diagnostic tool for tuberculosis on fine needle aspirates samples. *International Journal Of Community Medicine And Public Health.* 2020 Mar 26; 7(4):1511-5.
 30. Arpitha K, Kumar MR, Sirasagi AK, Pattar PM. Comparison of fine needle aspiration cytology, Ziehl-Neelsen staining and GeneXpert methods in suspected cases of tubercular lymphadenopathy. *Natl J Lab Med.* 2021 Jul; 10(3):26-9.
 31. Lavanya G, Sujatha C, Faheem K, Anuradha B. Comparison of GeneXpert with ZN staining in FNA samples of suspected extrapulmonary tuberculosis. *IOSR J Dent Med Sci.* 2019; 18:25-30.
 32. Nur T, Akther S, Kamal M, Shomik M, Mondal D, Raza M. Diagnosis of tuberculous lymphadenitis using fine needle aspiration cytology: a comparison between cytomorphology and GeneXpert Mycobacterium tuberculosis resistant to rifampicin (MTB/RIF) test. *Clin Infect Immun.* 2019; 1(1):4.
 33. Derese Y, Hailu E, Assefa T, Bekele Y, Mihret A, Aseffa A, et al. Comparison of PCR with standard culture of fine needle aspiration samples in the diagnosis of tuberculosis lymphadenitis. *J Infect Dev Ctries.* 2012; 6(1):53-7.
 34. Ligthelm LJ, Nicol MP, Hoek KG, Jacobson R, Van Helden PD, Marais BJ, et al. Xpert MTB/RIF for rapid diagnosis of tuberculous lymphadenitis from fine-needle aspiration biopsy specimens. *J Clin Microbiol.* 2011; 49(11):3967-70.