

Dermatoglyphic Assessment of atd Angle Alterations in Vitiligo: A Case–Control StudyAbhijit Bhakta¹, Jayashree Konar²¹Professor, Department of Anatomy, NRS Medical College & Hospital, Kolkata, West Bengal, India²Associate Professor, Department of Microbiology, College of Medicine & Sagore Dutta Hospital, West Bengal, India

Received: 01-10-2025 / Revised: 15-11-2025 / Accepted: 21-12-2025

Corresponding author: Dr. Jayashree Konar

Conflict of interest: Nil

Abstract

Background: Dermatoglyphics reflects genetically determined epidermal ridge patterns established during early fetal life and remains unaltered thereafter. Vitiligo, a depigmenting disorder characterized by selective melanocyte loss, is believed to have a multifactorial etiology with a significant genetic component. The atd angle, formed by the digital triradii 'a' and 'd' and the axial triradius 't', serves as an important quantitative palmar parameter indicative of developmental variations.

Objective: To evaluate alterations in the atd angle in individuals with vitiligo and to compare these findings with age- and sex-matched healthy controls.

Methods: A case–control study was conducted involving clinically diagnosed vitiligo patients and healthy controls from the same institution. Palmar dermatoglyphic prints were obtained using the standardized ink method described by Cummins and Midlo. The atd angle was measured bilaterally using established anatomical landmarks. Statistical analysis was performed to compare mean values between cases and controls.

Results: The mean atd angle was found to be increased in both male and female vitiligo patients on the right and left palms compared with controls, although the differences did not reach statistical significance in all parameters.

Conclusion: The observed tendency toward increased atd angles in vitiligo supports the hypothesis of an underlying developmental and genetic predisposition. Dermatoglyphic assessment of the atd angle represents a simple, noninvasive, and cost-effective adjunct tool for studying genetic susceptibility in vitiligo.

Keywords: Dermatoglyphics; atd angle; Vitiligo; Palmar triradius.

DOI: 10.25258/ijcpr.18.1.149

This is an Open Access article that uses a funding model which does not charge readers or their institutions for access and distributed under the terms of the Creative Commons Attribution License (<http://creativecommons.org/licenses/by/4.0>) and the Budapest Open Access Initiative (<http://www.budapestopenaccessinitiative.org/read>), which permit unrestricted use, distribution, and reproduction in any medium, provided original work is properly credited.

Introduction

Dermatoglyphics is the scientific study of epidermal ridge patterns present on the volar surfaces of the hands, fingers, feet, and toes. These ridge patterns are formed during early fetal development and remain unchanged throughout life, making them reliable markers of genetic constitution and intrauterine developmental events. Owing to this stability, dermatoglyphic analysis has been widely applied in medical genetics to identify associations with chromosomal abnormalities and inherited disorders, such as Down's syndrome, where characteristic dermatoglyphic deviations have been well documented.[1]

Vitiligo is an acquired depigmentary disorder characterized by complete or partial loss of functional melanocytes from the skin and, occasionally, hair follicles. Although its exact etiopathogenesis is not fully understood, vitiligo is

believed to result from a complex interplay of genetic susceptibility, autoimmune mechanisms, and environmental factors. Familial clustering and association with other genetically influenced conditions support the presence of a strong hereditary component in its pathogenesis. [2]

The atd angle is an important quantitative parameter in palmar dermatoglyphics. It is formed by drawing straight lines connecting the digital triradius 'a' located at the base of the index finger, the axial triradius 't' situated near the center of the palm, and the digital triradius 'd' at the base of the little finger. The magnitude of the atd angle reflects the degree of distal displacement of the axial triradius, with larger angles indicating a more distal position. In cases where multiple axial triradii are present, the angle formed from the most distal triradius is considered for analysis. [4]

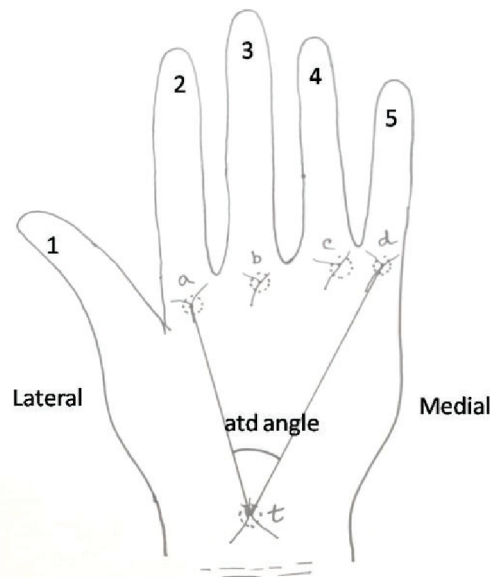


Figure 1: Schematic diagram of palm showing the position of axial triradii and atd angle.

atd angle: How it's measured and what it means:

- Triradii: These are points where three ridge systems (papillary ridges) meet, forming a Y-shape.
 - 'a': Digital triradius at the base of the index finger.
 - 'd': Digital triradius at the base of the little finger.
 - 't': Axial triradius, located in the palm's center.
- Angle formation: Two lines are drawn: one from 'a' to 't', and another from 't' to 'd'. The angle between these lines is the ATD angle.
- Interpretation: A larger ATD angle means the axial triradius ('t') is more distally (further down) located on the palm, indicating a greater displacement.
- Significance: It's a genetically determined trait used to study developmental anomalies, potentially indicating risks for conditions like diabetes or skeletal issues [5].

Key characteristics

- **Normal range:** Around 48° for typical individuals, but can vary.
- **Associated conditions:** Higher angles are seen in Down Syndrome (averaging around 81°) and hypertension, while lower angles might be linked to other conditions [6].

Detection of the changing pattern of atd angle is an easy to perform and cost effective novel tool to document the dermatoglyphic changes related to vitiligo.

Variations in the atd angle have been reported in several genetically and developmentally influenced conditions, including Down's syndrome,

hypertension, and other systemic disorders, highlighting its value as a marker of disturbed embryological growth. [3-6] However, studies evaluating atd angle patterns in vitiligo patients have yielded inconsistent results, with no universally accepted dermatoglyphic pattern established to date [3,7-9]

In view of the presumed genetic basis of vitiligo and the non-invasive nature of dermatoglyphic assessment, the present study was undertaken to evaluate changes in the atd angle among individuals with vitiligo and to compare these findings with age- and sex-matched healthy controls.

Objective: The present study aimed to evaluate atd angle in digito palmar dermatoglyphic features in individuals with vitiligo and to compare these parameters with those of age and sex matched healthy controls.

Materials & Methods

Vitiligo patients attending dermatology OPD at Nil Ratan Sircar medical college and Hospital were enrolled as cases in the study. Controls were hospital staff & medical students from the same institute. The study population consisted of all clinically diagnosed 112 cases of vitiligo. The controls 112 in number were students and staff members from the same institution. Controls were screened to rule out vitiligo and other hereditary disorders. Dermatoglyphic prints were taken by the 'ink method' of Cummins and Midlo (1961) [7,8].

Inclusion criteria:

- Confirmed diagnosis of vitiligo
- Age above 10 years
- Absence of congenital anomalies

Exclusion criteria:

- Chromosomal disorders known to affect dermatoglyphics
- Palmar dermatologic conditions or trauma
- History of hand surgery

Informed consent of the cases and controls was obtained. The subjects were asked to clean their hands with soap and water and then to dry them up leaving behind slight moisture. A requisite amount of ink was placed on a glass slab and uniformly smeared by a rubber roller to get a thin and even film. The thin film of ink was applied over the palms by keeping the expanded palms on the ink film on the glass slab and then applying pressure over the dorsum of the hands and digits taking care that hollow of the palms and flexor creases over

palms and fingers will get uniformly inked. Inked hands of the subjects were pressed on the sheet of the paper from proximal to distal end. The palm was then lifted away from the paper in reverse order from distal to proximal end.

The fingers were rolled from radial to ulnar side to obtain a complete impression of the ball of the finger. The prints thus obtained were subjected to detailed digito-palmar dermatoglyphic analysis with the help of magnifying hand lens and ridge counting with the help of a sharp needle. Statistical analysis were done by standard statistical methods.

Results:

The mean value of atd angle was increased in vitiligo males and females on both sides.

Table 1: Comparison of atd angle between vitiligo cases and controls.

Parameter	Sex	Control		Vitiligo		P-value
		Mean (SD)	Range	Mean (SD)	Range	
Right atd angle	Male	41.49 ± 5.2	33–61	43 ± 8.51	33–80	0.22
	Female	41.82 ± 5.8	34–73	44 ± 6.93	32–67	0.12
Left atd angle	Male	41.33 ± 4.9	31–57	42 ± 6.49	23–78	0.81
	Female	41.10 ± 4.1	33–50	43 ± 5.21	35–58	0.08

Discussion:

Vitiligo is a common acquired disease characterized by one or more patches of depigmented skin due to degeneration or disappearance of cutaneous melanocytes [8]. Dermatoglyphics which deals with epidermal ridges can be useful in early diagnosis of Vitiligo. This study was conducted to find whether any specific pattern of atd angle in dermatoglyphics exist for Vitiligo population in the place of study. The present study has revealed that the mean value of atd angle was increased in vitiligo males and females on both sides. Similar findings were recorded by Kar et al. in a study performed in Kolkata [3]. In the contrary, Manjusha K Tabhane et.al found mean value of "atd" angle shows significant decrease in Vitiligo as compared to control groups. But due to non-availability of data this point cannot be discussed [8]. Some other researchers also have reported that, mean "atd" angle in females of vitiligo (37.7°) showed a statistically significant decrease (p value < 0.05) when compared with control females (42.2°) [9].

In conclusion, the expanded dermatoglyphic analysis presented in this study reinforces the concept that vitiligo has a strong developmental and genetic component. The observed alterations in fingertip and palmar ridge patterns reflect disturbances occurring during early fetal life and provide stable phenotypic evidence of underlying susceptibility. Future studies incorporating familial analysis molecular genetics and longitudinal follow up may further clarify the relationship between

dermatoglyphic markers and the pathogenesis of vitiligo.

References:

1. Rajangam S, Janakiram S, Thomas IM. Dermatoglyphics in Down's syndrome. Journal of the Indian Medical Association. 1995 Jan 1;93(1):10-3.
2. Passeron T, Ortonne JP. Physiopathology and genetics of vitiligo. Journal of autoimmunity. 2005 Jan 1;25:63-8.
3. Sumit Kar, Ajay Krishnan, Abhijit Bhakta, Atul Dongre, Digito-palmar dermatoglyphics in vitiligo – A case control study, Journal of the Saudi Society of Dermatology & Dermatologic Surgery, Volume 16, Issue 2, 2012, Pages 61-66. <https://doi.org/10.1016/j.jssdds.2012.04.004><https://www.sciencedirect.com/science/article/pii/S2210836X12000097>
4. Bharat J. Sarvaiya, Jagdish S. Chaudhari, S. M. Patel, S. V. Patel. Study Of Atd Angle And Finger Ridge Count In Leprosy Patient Of Bhavnagar District. Int J Anat Res 2015;3(4): 1515- 1519. DOI: 10.16965/ijar.2015.287
5. Shubhangi Maheshwari et al. Comparison Of Palmar Atd Angle And A-B Ridge Count In Normotensive And Hypertensive Patients. NeuroQuantology| October 2022 | Volume 20 | Issue 13 |Page 4076-4082| doi: 10.48047/nq.2022.20.13.NQ88495
6. Elkwatehy, Wahdan & Sheta, Abdelrazek. (2016). Dermatoglyphics as a Non-Invasive Anatomical Marker in Early Childhood Caries. International Journal of Dentistry and Oral

- Science. 366-371. 10.19070/2377-8075-1600074.
7. Cummins, et al. (1961). *Finger Prints, Palms and Soles: An Introduction to Dermatoglyphics*. Mineola, New York: Dover Publications.
 8. Manjusha K Tabhane et.al. Comparative Study of Palmar Dermatoglyphics in Vitiligo Population of Vidarbha Region of Maharashtra India. *Int J Biol Med Res*. 2013; 4(2): 3107-3114
 9. Kumar P, Gupta A. Dermatoglyphic patterns in psoriasis, vitiligo and alopecia areata. *Indian J Dermatol Venereol Leprol* 2010;76:185-186.