e-ISSN: 0976-822X, p-ISSN:2961-6042

Available online on http://www.ijcpr.com/

International Journal of Current Pharmaceutical Review and Research 2026; 18(1); 1169-1176

Original Research Article

Role of Ultrasonography and Computed Tomography Assessment of Gallbladder mass and its relationship to cytology

Anupriya Mishra[1], Priyanka Kumari[2], Ashok Kumar[3], Madhukar Dayal[4]

[1]Senior Resident, Department of Radiology, Sri Krishna Medical College & Hospital, Muzaffarpur, Bihar.

[2]Senior Resident, Department of Radiology, Nalanda Medical College & Hospital, Patna, Bihar.

[3]Associate Professor and HOD, Department of Radiology, Sri Krishna Medical College & Hospital, Muzaffarpur, Bihar.

[4]Associate Professor, Department of Radiology, Nalanda Medical College & Hospital, Patna, Bihar.

Received: 01-10-2025 / Revised: 15-11-2025 / Accepted: 21-12-2025

Corresponding author: Dr. Priyanka Kumari

Conflict of interest: Nil

Abstract

Background: Ultrasonography is the primary first diagnostic tool for suspected biliary abnormalities, and computed tomography (CT) and ultrasonography (USG) have transformed the diagnosis process. Although the infiltrative nature of certain tumors and the presence of gallstones, inflammation, and debris may make tumor identification impossible, it might be useful for identifying gadolinium-based contrast agents (GBCA). According to reports, CT is a complete imaging and staging tool for GBCA. Aim of this study to evaluate USG and CT assessment of gallbladder (GB) masses and correlate to cytological findings.

Methods: From February 2025 to July 2025, this study was carried out in the Department of Radiology at Sri Krishna Medical College and Hospital in Muzaffarpur, Bihar, in collaboration with the departments of surgery, medicine, and pathology. Our investigation comprised 50 patients with suspected GB masses in total.

Result: Maximum number of patients were in the age group between 41 and 50 year, about 32%, and age group between 51 and 60 years, about 28%. GB masses 33 (66%) were detected in females and 17 (34%) were detected in males. Mass detection as per diffuse wall and mass detection as per heterogeneous echotexture was seen in 35 patients, about 70% in USG, and 36 patients, about 72% in CT. Thickening of GB was seen in 7 patients, about 14% in USG and CT.

Conclusion: In our study, overall detection of GB carcinoma USG could detect 94% of cases and CT could detect 96% of cases same as fine-needle aspiration cytology detection of GB carcinoma showing that CT is more sensitive than USG to detect the GB carcinoma.

Keywords: Computed tomography scan, Ultrasonography, GB carcinoma.

DOI: 10.25258/ijcpr.18.1.197

This is an Open Access article that uses a funding model which does not charge readers or their institutions for access and distributed under the terms of the Creative Commons Attribution License (http://creativecommons.org/licenses/by/4.0) and the Budapest Open Access Initiative (http://www.budapestopenaccessinitiative.org/read), which permit unrestricted use, distribution, and reproduction in any medium, provided original work is properly credited.

Introduction

Ultrasound (US) is the main initial diagnostic tool for suspected biliary lesions. It may be helpful for detecting gadolinium-based contrast agents (GBCA) although the infiltrative morphology of some tumors and the presence of gallstones, inflammation, and debris may preclude tumor detection. CT has been reported as a comprehensive tool for imaging and staging of GBCA. USG in patients of carcinoma GB has certain limitations such as interference by bowel gas, limited depth resolution, and inadequate visualization of parts of the GB in the region of posterior acoustic shadowing in the presence of calculi. CT scan overcomes these drawbacks and provides definite information regarding the invasion of the tumor into the adjacent organs, distant metastasis, delineation of the biliary tree, and portal vein involvement.[1-4] Sonography is currently the most practical and accurate method to diagnose acute cholecystitis. When adjusted for verification bias, sensitivity and specificity of US are approximately 88% and 80%, respectively.[1] CT may be useful for depiction of complications. Sonographic findings include the thickening of the GB wall (>3 mm), distention of the GB lumen (diameter >4 cm), gallstones impacted stone in cystic duct or GB neck, pericholecystic fluid collections, positive sonographic Murphy's sign, hyperemic GB wall on Doppler, and interrogation.[5] The integration of cytological analysis through fine needle aspiration (FNA) or biopsy under imaging guidance enhances the

diagnostic accuracy for gallbladder masses.[6,7] Cytological examination provides definitive histopathological diagnosis, which is essential for the confirmation of malignancy and subsequent treatment planning. The correlation between imaging findings and cytological results is critical in establishing a precise diagnosis and guiding therapeutic decisions. This study aims to evaluate the diagnostic efficacy of USG and CT in identifying and characterizing gallbladder masses and to correlate these imaging findings with cytological results. By comparing the performance of these imaging modalities and their correlation with cytology, this research seeks to establish a comprehensive diagnostic approach for the effective management of gallbladder masses.

Material and Methods

This study was conducted in the Department of Radiology in coordination with the surgery, medicine, and pathology at Sri Krishna Medical College and Hospital, Muzaffarpur, Bihar from February 2025 to July 2025. A total of 50 patients with suspected GB masses were included in our study. Informed written consent of patients was taken before conduction of the study.

Patients who presented with a sign and symptom of GB masses in SKMCH, Muzaffarpur underwent USG, CT scan, and FNAC were included in this study.

Non-cooperative patients and who did not underwent all the three investigations (USG, CT scan and FNAC) were excluded in this study.

Sonographic examinations were carried out after an overnight fast with a real-time gray scale. The GB was examined for wall thickness, irregularity, echotexture, mass lesions, stones, and pericholecystic fluid collections. CT scan was done on 16 slice GE CT scan machine.

Multiplanar reconstructions were created in both coronal and sagittal plane section.

All the cases had a clinical or radiological suspicion of GB malignancy. Hematoxylin and eosin stained cytology smears were examined in all cases.

Results

In our study, age of the GB mass patients was ranged from 30 to 90 years. Maximum number of patients were in the age group between 41 and 50 years, about 32%, and age group between 51 and 60 years, about 28%. Minimum number of patients were in the group between 71–80 years and 81–90 years. The average age of the patients presented was 52 years.

According to Table 2a and b in our study, of 50 patients of the GB masses, 33 (66%) were detected in females and 17 (34%) were detected in males. Female predominance is seen, 6.6 female per 3.4 male. One patient may have more than one complaint. In our study, most common presenting symptom was pain in RUQ which was seen in 94% of cases. 52% (26) of patients were presented with jaundice. About 38% of patients were presented with itching all over the body and 36% of patients were presented with weight loss which were other associated complaints. In our study, GB masses were assessed in terms of size, irregularity, complete or partial replacing lumen, heterogeneous echotexture, gallstone [Figure 1], vascularity on USG, enhancement on CT, dilated common bile duct (CBD), and intrahepatic biliary radicals (IHBR). According to the detection of complete or partial replacing GB lumen masses, USG could detect in 24 patients, about 48% of cases. CT scan could detect in 32 patients, about 64% of cases. In 16% of cases, USG could not detect partial replacing GB lumen masses due to obscured by bowel gas in the abdomen which were detected in CT scan, Figure 2. GB masses were assessed in terms of focal thickening of wall, irregularity, echotexture in USG, and enhancement in CT.

According to detection as per focal wall thickening Figure 3, USG could detect 5 patients, about 10% of the cases. CT scan could detect 9 patients, about 18% of the cases. USG could not detect rest of the 8% of cases obscured by bowel gas, which shows that CT scan is better than USG to detect focal wall thickening masses. Mass detection as per diffuse wall thickening of GB was seen in 7 patients, about 14% in USG and CT. GB masses as per intraluminal mass lesion could be detected in 2 patients, about 4% of cases in USG and CT, which shows that both USG and CT are equally sensitive to detect the diffuse wall thickening. Mass detection as per heterogeneous echotexture seen in 35 patients (70%) in USG and 36 patients (72%) in CT showing CT is more accurate than USG. Mass detection as per presence of calculus seen in 24 patients, 48% seen in USG, and 20 patients, about 40% in CT showing, USG is more sensitive than CT to detect calculus. Dilated CBD, associated sign of GB mass, and USG could detect 17 cases, about 34%, and CT could detect 18 cases, about 36%, showing that CT is more sensitive than USG to detect dilated CBD.

Dilated IHBR, associated sign of GB mass, and USG could detect 29 patients, about 58% cases, and CT could detect 30 patients, about 60% cases, showing that CT is more sensitive than USG for detection of dilated IHBR associated with GB masses. In this study, GB mass could detect as per direct invasion of the liver in 74% of cases almost similar in USG as well as CT. Similarly, 2% of cases of right and left hepatic duct could be detected by USG, and CT could detect 10% of

cases. Duodenum, pylorus, and colon are detected in 2% of cases only by CT, and USG could not detect any distant organ invasion, showing that CT is for better to detect distant organ invasion than USG. In this study, the USG and CT both are equally sensitive to detect the porcelain GB in 4% of cases which represent GB carcinoma. In this study ,GB carcinoma detected by USG in 26 (52%) cases shows vascularity on color Doppler, CT detect 48 (96%) cases showing enhancement on dual phase study represents malignant nature of masses , Figure 4.

This shows that CT is more sensitive to accurate detection of GB carcinoma than USG. In this study, as per detection of nodes, nodes at liver hilum or periportal could be detected by USG in 25, about 50% of cases, and CT could detect 27, about 54% of cases. Peripancreatic nodes could be detected by USG in 20, about 40% of cases, and CT could detect 21, about 42% of cases. Aortocaval lymph node could be detected by USG in 4, about 8% of cases, while CT could detect 8, about 16% of cases. Mesenteric lymph node could be detected by USG in 3, about 6% of cases, while CT could detect 7, about 14% of cases. It shows that CT is more sensitive to detect distant lymphatic spread than USG. In this study, as per detection of metastasis, USG could detect 15, about 30% of cases, and CT could detect 19, about 38% of cases of liver metastasis. While USG could not detect any case of peritoneal metastasis, however, CT could detect 1, about 2% of cases, showing that CT is more sensitive than USG to detect metastasis.

In this study, as per overall detection of GB carcinoma, USG could detect 94% of cases and CT could detect 96% of cases of GB carcinoma, showing that CT is more sensitive than USG to detect the GB carcinoma.

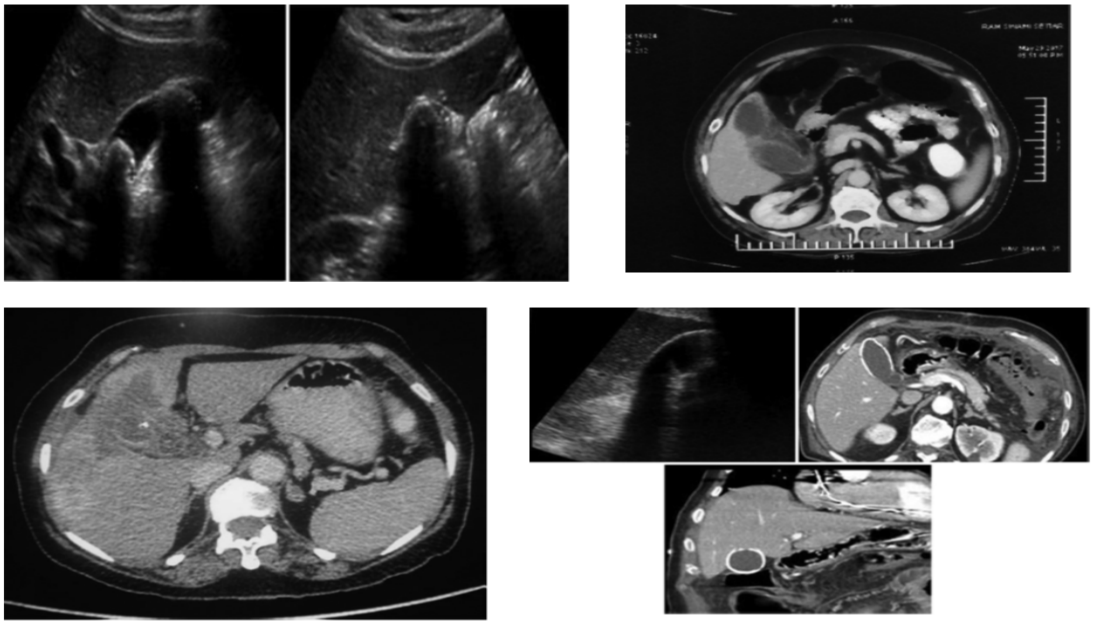

Figure 1-4:

Figure 1: Wes sign. Sagittal and transverse ultrasound images of the gallbladder showing the wall-echo-shadow complex, comprised of an outer echogenic line representing the gallbladder wall, an outer hypoechoic line representing the gallbladder lumen, an inner echogenic line, representing the margin of the gallstone, and then strong posterior acoustic shadow

Figure 2: Wall thickening. There is irregular wall thickening of gallbladder in the body and fundus region, measuring about 5–6 mm with extensive pericholecystic fat stranding.

The gallbladder lumen is filled with iso-to hypo-dense content. The fundus of gallbladder is seen abutting the anteroinferior segment of right hepatic lobe which reveals evidence of heterogeneously enhancing soft tissue density foci

Figure 3: Mass replacing lumen, there is axial contrast-enhanced computed tomography abdominal section showing ill-defined heterogeneous mass replacing gallbladder fossa with direct infiltration of adjacent hepatic segments

Figure 4: Porcelain gallbladder. Transverse right upper quadrant grayscale ultrasound shows strong posterior acoustic shadow, and axial and coronal contrast-enhanced computed tomography images of the upper abdomen each demonstrate thin intramural calcification of the gallbladder wall.

Table 1: Distribution as per age

Age Group in years	No. of cases	Percentage
≥30	4	8%
31–40	7	14%
41–50	16	32%
51–60	14	28%
61–70	7	14%
71–80	1	2%
81–90	1	2%

Table 2a: Distribution as Gender

Gender	No. of cases	Percentage
Female	33	66%
Male	17	34%

Table 2b: Distribution as Gender as per age

Age Group in years	Female	Male
≥30	4	0
31–40	4	3
41–50	13	3
51–60	7	7
61–70	4	3
71–80	0	1
81–90	1	0

Table 3: Distribution as per non-specific clinical symptom

Symptoms	No. of cases	Percentage
Pain in the abdomen (RUQ)	47	94%
Weight Loss	18	36%
Jaundice	26	52%
Fever/Vomiting	12	24%
Itching all over the body	19	38%

Table 4: Distribution as per mass replacing GB lumen

Investigation	No. of cases	Percentage
By Ultrasonography	24	48%
By Computed Tomography	32	64%

Table 5: Distribution as per focal wall thickening

Investigation	No. of cases	Percentage
By Ultrasonography	5	10%
By Computed Tomography	9	18%

Table 6: Distribution as per diffuse wall thickening

Investigation	No. of cases	Percentage
By Ultrasonography	4	8%
By Computed Tomography	7	14%

Table 7: Distribution as per intraluminal mass lesion

Investigation	No. of cases	Percentage
By Ultrasonography	2	4%
By Computed Tomography	2	4%

Table 8: Distribution as per heterogeneous echotexture

Investigation	No. of cases	Percentage
By Ultrasonography	35	70%
By Computed Tomography	36	72%

Table 9: Distribution as per detection of calculus

Investigation	No. of cases	Percentage
By Ultrasonography	24	48%
By Computed Tomography	20	40%

Table 10: Distribution as per CBD dilated

Investigation	No. of cases	Percentage
By Ultrasonography	17	34%
By Computed Tomography	18	36%

Table 11: Distribution as per dilated IHBR

Investigation	No. of cases	Percentage
By Ultrasonography	22	44%
By Computed Tomography	30	60%

Table 12: Distribution as per invasion

Site	USG (%)	CT (%)
Liver	37(74%)	37(74%)
Right and left hepatic duct	1(2%)	5(10%)
Duodenum	0	1(2%)
Pylorus	0	1(2%)
Colon	0	1(2%)

Table 13: Distribution as per porcelain GB

Investigation	No. of cases	Percentage
By Ultrasonography	2	4%
By Computed Tomography	2	4%

Table 14: Distribution as per vascularity and enhancement

Investigation	No. of cases	Percentage
By Ultrasonography	26	52%
By Computed Tomography	48	96%

Table 15: Distribution as per lymph node involvement

Lymph Node	USG (%)	CT (%)
Periportal	25(50%)	27(54%)
Peripancreatic	20(40%)	21(42%)
Aortocaval	4(8%)	8(16%)
Mesenteric	3(6%)	7(14%)

Table 16: Distribution as per mass detection in USG and CT

Investigation	No. of cases	Percentage
By Ultrasonography	47	94%
By Computed Tomography	48	96%
By FNAC	48	96%

Discussion

In our study, age distribution of the patients presenting with GB mass was in range from 30 to 90 years. Maximum patients were in the age group of 41–50 year, which constituted about 32% of cases. The overall mean age of the patients presented was 52 years. Haaga and Herbener[8] and Fong et al[9] in their separate studies showed that most common age group of presentation of GB mass was primarily in the sixth to seventh decade of life which slightly differs from our study sample. In one study by George et al.[10] the peak incidence age group of GB mass was 51–70 years. Memon et al.,[11] in their study, 2005 have shown in their series that the mean age of the patients having GB malignancy was 70.6 years and ranges from 42 to 85 years. Of the 50 patients included in the study, 33 (66%) patients were female and 17 (34%) patients were male. The overall female-to-male ratio was 1.9:1.

The mean age of the presentation was 49.6 years for female and 56.7 years for male. In one study by George et al.,[10] the male: female ratio was 2:5 and the mean age of presentation was 57 years for

females and 52 years for males, which is almost a decade less than the reported mean age in western literature. In our study, the most common presenting symptom was pain in RUQ which was seen in 94% of cases. Pandey et al.[12] in their study showed most common presentation of GB cancer as loss of weight (201 patients, 99%) followed by loss of appetite (197 patients, 97%), pain in the right hypochondrium (143 patients, 70%), a mass in the right hypochondrium (107 patients, 53%), jaundice (79 patients, 39%), and nausea and vomiting (21 patients, 10%).

According to the detection of complete or partial replacing GB lumen mass, USG could detect in 24 patients, about 48% of cases. CT scan could detect in 32 patients, about 64% of cases. In 16% of cases, USG could not detect partial replacing GB lumen masses due to obscured by bowel gas in the abdomen which was detected in the CT scan, showing that CT scan is more sensitive than USG to detect partially replacing GB lumen masses obscured by bowel gases. George et al.[10] most common presentation in their study was of a sub-hepatic mass replacing or obscuring the GB often with invasion of the adjacent liver. This finding was seen in 28 (56%) cases with half of them in an inoperable stage of the disease, Similar features reported in study done by Mandal et al [13] in their study the main patterns on imaging were an infiltrating mass into the liver or adjacent bowel in 28 patients (56%) .

According to detection as per focal or diffuse wall thickening, USG could detect about 10% of the cases of focal wall, while CT scan detected in about 18% of the focal wall cases, diffuse wall thickening of GB seen in 7 patients, about 14% in USG and CT. Pandey et al.[12] in their study in GB wall thickening (>12 mm), inhomogeneous echoes, and ill-defined margins were evident in 26 patients (13%). The GB wall adjacent to the liver was more often thickened than the wall of the rest of the GB. Yun et al.[14] in their study used dual-phase CT to assess thickness as well as enhancement pattern of GB wall seen in GB melanoma as well as chronic cholecystitis in arterial and venous phase. They reported a difference in enhancement patterns of malignancy as compared to chronic cholecystitis using dual-phase CT.

In our study, GB masses as per intraluminal polypoidal mass lesion could be detected in 2 patients, about 4% of cases in USG and CT, showing that both USG and CT are equally sensitive to detect the intraluminal polypoidal mass.

Color Doppler USG has been reported to be useful in the evaluation of malignant lesions. Mandal et al.[13] in their study reported that intraluminal polypoidal masses were detected in 16 patients (32%) of 50 cases. The polyps showed mild-to-moderate enhancement following intravenous contrast administration. Hirooka et al.[15] reported that in cancerous GB polyps, the color signal pattern was diffuse, becoming linear at the base. Velocity and the resistance index were 39.0 ± 12.4 cm/s and 0.62 ± 0.12, respectively, which were significantly different from control measurements from control measurements.

In our study, mass detection as per heterogeneous echotexture was seen in 35 patients, about 70% in USG, and 36 patients, about 72% in CT, showing that CT is more accurate than USG. GB carcinoma typically appears on USG as a mass with inhomogeneous echoes in the GB. Palma et al.[16] suggested that these areas were due to necrosis or residual bile within the GB.

In our study, mass detection as per the presence of calculus was seen in 24 patients, about 48% was seen in USG, and 22 patients, about 44% in CT, showing that USG is more sensitive than CT to detect calculus. The size of the gallstones impacting on the GB wall was a strong indicator for the possible repeated mechanical irritation of the GB mucosa. This chronic GB mucosa irritation by gallstones is a mechanism that has been postulated by Solan and Jackson.[17] Lowenfels et al.[18] in their study of more than 1600 patients with GB disease reported that 40% of patients with GB carcinoma had stones that were >3 cm. Moerman et al.,[15] in their study, well explain the lack of association between gallstone size and GB carcinoma, and there is no relationship between stone size and advent of GB was observed.

In this study d ilated CBD, associated sign of GB mass, USG could detect 17 cases, about 34%, and CT could detect 18 cases, about 36% showing that CT is more sensitive than USG to detect dilated CBD.

In this study dilated IHBR, associated sign of GB mass, USG could detect 29 patients, about 58% of cases, and CT could detect 30 patients, about 60% of cases, showing that CT is more sensitive than USG for detection of CBD with GB mass USG could detect 17 cases (34%). Mandal et al.[13] in their study detected that IHBRs were dilated in 30 patients (60%) of 50 patients ranging from minimal to severe in both lobes of the liver.

In this study, GB mass could detect as per direct invasion of the liver in 74%of cases almost similar in USG as well as CT.

Similarly, 2% of cases of right and left hepatic duct could be detected by USG and CT could detect 10% of cases. Duodenum, pylorus, and colon are detected in 2% of cases only by CT, and USG could not detect any distant organ invasion, showing that CT is far better to detect distant organ

invasion than USG. Oikarinen et al.[20 in their study compared USG and CT in the staging of GB cancers and reported the sensitivity of USG for determining liver invasion to be 68%. In this study, the USG and CT both are equally sensitive to detect the porcelain GB in 4% of cases which representing GB carcinoma. Table 14 presents the distribution as per vascularity and enhancement. In this study USG detected 26(52%) cases shows vascularity on color Doppler represents malignant nature of masses. Similarly, CT could detect 48, about 96% of cases, showing that enhancement on dual phase study represents malignant nature of masses. This shows that CT is more sensitive to accurate detection of GB carcinoma than USG. Our study showed that application of dynamic CT did not improve the diagnostic accuracy. In 9 of our 16 patients, the GB cancers appeared as is attenuated lesions on the arterial phase. In contrast, they were hypo attenuated on the portal phase in.

Kim et al.[21] in their study assessed the enhancement pattern of abnormal GB wall thickening using multidetector computed tomography to differentiate between carcinoma and inflammatory diseases. They concluded that there is a distinct pattern of enhancement of inner wall compared to non-enhancing surface covering.

In this study as per detection of nodes, nodes at liver hilum or periportal could be detected by USG in 25, about 50% of cases, and CT could detect 27, about 54% of cases. Peripancreatic nodes could be detected by USG in 20, about 40% of cases, and CT could detect 21, about 42% of cases. Aortocaval lymph node could be detected by USG in 4, about 8% of cases, while CT could detect 8, about 16% of cases. Mesenteric lymph node could be detected by USG in 3, about 6% of cases, while CT could detect 7, about 14% of cases. It shows that CT is more sensitive to detect distant lymphatic spread than USG. Pandey et al.[12] in their study found that lymph node enlargement was demonstrated in 39 patients (19%). The node groups most often involved were the periportal (33 cases), followed by the pancreaticoduodenal (17 cases), the paraaortic (16 cases), and less often, the pericholedochal (4 cases) nodes. These nodes appeared as round, well-defined hypoechoic masses with sharp margins and few internal echoes. Most of the nodes were larger than 2.0 cm and discrete.

In this study, as per overall detection of GB carcinoma, USG could detect 94% of cases and CT could detect 96% of cases of GB carcinoma, showing that CT is more sensitive than USG to detect the GB carcinoma. Kim et al.[21] have reported an overall accuracy of 71% in staging the T-factor of the tumor node metastasis staging in their study of 100 consecutive cases, with accuracies varying from 79% for T1 and T2, 46% for T3, and 73% for T4. The accuracy was lowest for thickened GB wall at 54% and highest for GB mass at 89%.

Conclusion

The overall mean age of the patients presented was 52 year, and the overall female-to-male ratio was 1.9:1. The most common presenting symptom was pain in RUQ which was seen in 94% of cases. Mass detection according to complete or partial replacing GB lumen, USG could detect in about 48% cases. CT scan could detect in about 64% of cases. Focal wall thickening USG could detect about 10%.

References

1. Tsuchiya Y. Early carcinoma of the gallbladder: Macroscopic features and US findings. Radiology 1991; 179:171-5.
2. Rumack, C. M., Wilson, S. R., & Charboneau, J. W. (2011). Diagnostic Ultrasound. Elsevier.
3. Bhatt, S., & Dogra, V. S. (2008). Introduction to Musculoskeletal Ultrasound: Getting Started. Ultrasound Clinics, 3(1), 1-8.
4. Low, G., & Panu, A., & Millo, N., & Leen, E. (2011). Multimodality Imaging of Neoplastic and Non-neoplastic Solid Lesions of the Gallbladder. Clinical Radiology, 66(4), 391-400.
5. Kim, S. J., Lee, J. M., & Lee, J. Y. (2008). Analysis of Enhancement Pattern of Gallbladder Diseases with Multi-detector Row CT. Clinical Imaging, 32(4), 240-248.
6. Kochhar, R., & Goenka, M. K., & Nagi, B. (2001). Role of Percutaneous Transhepatic Aspiration Cytology in the Diagnosis of Malignant Lesions of the Gallbladder. Journal of Gastroenterology and Hepatology, 16(1), 40-43.
7. Lim, J. H. (2003). Fine Needle Aspiration Cytology of Gallbladder Lesions: A 3-year Study. Diagnostic Cytopathology, 29(1), 28-31.
8. Haaga JR, Herbener EH. The gallbladder and biliary tract. In: Haaga JR, Lanzieri CF, Gilkeson RC, editors. CT and MR Imaging of the Whole Body. 4th ed. St Louis: Mosby; 2003. p. 1357-60.
9. Fong Y, Jarnagin W, Blumgart LH. Gallbladder cancer: Comparison of patients presenting initially for definitive operation with those presenting after prior noncurative intervention. Ann Surg 2000; 232:557-69.
10. George RA, Godara SC, Dhagat P, Som PP. Computed tomographic findings in 50 cases of gall bladder carcinoma. Med J Armed Forces India 2007; 63:215-9.
11. Memon MA, Anwar S. Shiwani MH, Gallbladder carcinoma: A retrospective analysis of twenty-two-year experience of a

single teaching hospital. Int Sem Surg Oncol 2005; 6:79-81.
12. Pandey M. Environmental pollutants in gallbladder carcinogenesis. J Surg Oncol 2006; 93:640-3.
13. Mandal AK, Sithanthaseelan M, Thakur V. Gall bladder carcinoma: Computed tomographic findings in 50 cases. JMSCR. Imperial J Interdiscip Res 2017; 3:106-108.
14. Yun EJ, Cho SG, Park S, Park SW, Kim WH, Kim HJ, et al. Gallbladder carcinoma and chronic cholecystitis: Differentiation with two-phase spiral CT. Abdom Imaging 2004;29:102-8.
15. Hirooka Y, Naitoh Y, Goto H, Furukawa T, Ito A, Hayakawa T, et al. Differential diagnosis of gall-bladder masses using colour Doppler ultrasonography. J Gastroenterol Hepatol 1996; 11:840-6.
16. Palma LD, Rizzatto G, Pozzi-Mucelli RS, Bazzocchi M. Grey scale ultrasonography in the evaluation of carcinoma of the gallbladder. Br J Radiol 1980; 53:662.
17. Solan MJ, Jackson BT. Carcinoma of the gallbladder. Br J Surg 1971; 58:593-7.
18. Lowenfels AB, Walker AM, Althaus DP, Townsend G, Domellof L. Gallstone growth, size, and risk of gallbladder cancer: An interracial study. Int J Epidemiol 1989; 18:50-4.
19. Moerman CJ, Lagerwaard FJ, Bueno de Mesquita HB, van Dalen A, van Leeuwen MS, Schrover PA. Gallstone size and the risk of gallbladder cancer. Scand J Gastroenterol 1993; 28:482-6.
20. Oikarinen H, Päivänsalo M, Lähde S, Tikkakoski T, Suramo I. Radiological findings in cases of gallbladder carcinoma. Eur Radiol 1993; 17:179.
21. Kim SJ, Lee JM, Lee JY, Kim SH, Han JK, Choi BI, et al. Analysis of enhancement pattern of flat gallbladder wall thickening on MDCT to differentiate gallbladder cancer from cholecystitis. AJR Am J Roentgenol 2008; 191:765-71.