e-ISSN: 0976-822X, p-ISSN:2961-6042

Available online on http://www.ijcpr.com/

International Journal of Current Pharmaceutical Review and Research 2026; 18(11); 18-25

Case Series

Spectrum of Metastatic Clear Cell Tumours Mimicking Usual Malignancies: A Single Centre Study

Harani Brahma[1], Muktanjalee Deka[2], Jagannath Dev Sharma[3], Barasha Sharma Bharadwaj[4]

[1]Fellow, Department of Oncopathology, State Cancer Institute, Guwahati, 781032, Assam, India
[2]Professor and Head of the Department of Oncopathology, State Cancer Institute, Guwahati, 781032, Assam, India
[3]Professor and Consultant, Department of Oncopathology, State Cancer Institute, Guwahati, 781032, Assam, India
[4]Associate professor, Department of Oncopathology, State Cancer Institute, Guwahati, 781032, Assam, India

Received: 01-08-2026/Revised: 15-09-2026 / Accepted: 21-10-2026
Corresponding author: Dr. Harani Brahma, email: hbrahma20@gmail.com
Conflict of interest: Nil

Abstract

Clear cell morphology is encountered in a diverse group of neoplasms arising from various organs like Head and neck, kidney, Müllerian tract, adrenal cortex, liver, melanocytic and some soft tissue tumours. When present in metastatic lesions, these tumours often mimic common primary malignancies at the metastatic site, posing significant diagnostic challenges. Accurate identification of the primary tumour is essential for appropriate management and relies on a combination of histomorphology, clinical correlation, and immunohistochemistry. This study evaluates the spectrum of metastatic clear cell tumours and highlights common diagnostic pitfalls encountered in routine oncopathology practice.

Keywords: Clear Cell Tumours, Metastatic Site, Liver, Bone, Breast, Ovary, Axilla, Clear Cell Carcinoma Mimics.

DOI: 10.25258/ijcpr.18.11.4

This is an Open Access article that uses a funding model which does not charge readers or their institutions for access and distributed under the terms of the Creative Commons Attribution License (http://creativecommons.org/licenses/by/4.0) and the Budapest Open Access Initiative (http://www.budapestopenaccessinitiative.org/read), which permit unrestricted use, distribution, and reproduction in any medium, provided original work is properly credited.

Introduction

Clear cell tumours represent a heterogeneous group of neoplasms characterized histologically by tumour cells with abundant clear or optically empty cytoplasm on routine haematoxylin and eosin (H&E) staining. The clear appearance may result from the accumulation of glycogen, lipids, mucin, or other intracellular substances, as well as from cytoplasmic vacuolation and degenerative changes.

These substances or structural changes can produce an optically clear appearance after routine tissue processing[1,2]. Clear cell morphology is a descriptive histopathological feature rather than a distinct diagnostic entity and may be encountered in a wide spectrum of neoplasms, including carcinomas, sarcomas and melanocytic tumours. Examples include clear cell renal cell carcinoma (ccRCC), clear cell carcinoma of the ovary and clear cell sarcoma (CCS) of soft tissue[3,4].These tumours create major diagnostic challenges when presented in metastatic sites, especially when the metastatic deposit is the initial manifestation. Several neoplasms may exhibit overlapping morphological features mimicking clear cell carcinoma at metastatic sites, making distinction difficult on routine H & E section, especially in small biopsies. Although these tumours share a similar cytomorphological appearance, they differ considerably in their histogenesis, molecular alterations, biological behaviour, prognosis and therapeutic implications[5].

The present study aims to describe different types of tumours with clear cell morphology that can present at metastatic sites from various organs with emphasis on their clinicopathological features, immunohistochemical (IHC) profile and diagnostic challenges.

Case series: 1. A 45 years old male presented with right upper abdomen pain and imaging revealed a heterogeneous hepatic mass with areas of necrosis measuring 4.2 x 3 x 2.5 cm. USG guided core needle biopsy was taken and sent for histopathological examination (HPE).

Microscopy: Sections showed linear cores of hepatic tissue with neoplasm arranged in nests and trabecular pattern. These cells were polygonal, had abundant clear cytoplasm, round irregular hyperchromatic nuclei and inconspicuous nucleoli (Figure 1a-c). Morphologically differentials were clear cell hepatocellular carcinoma(HCC) and metastatic carcinoma like clear cell renal cell carcinoma (ccRCC), melanoma and squamous cell carcinoma (SCC). IHC revealed diffuse strong nuclear positivity for p40 (Figure 1d). It was negative for Glypican3, Arginase and HMB45. Thus, the final diagnosis of Metastatic squamous cell carcinoma (SCC) was made.

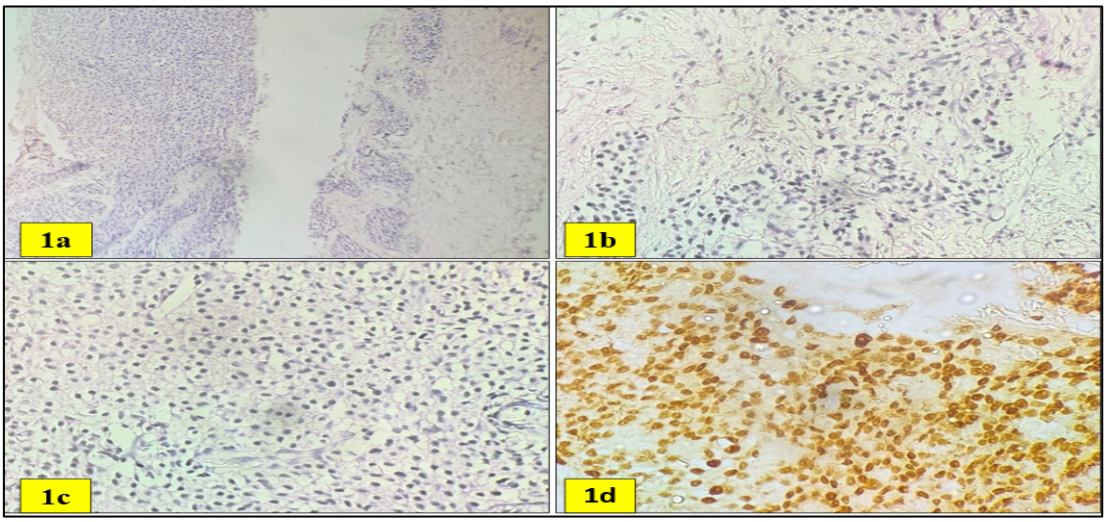

Figure 1(a-c): H and E stain showing metastatic SCC at ×40, (d) IHC showing diffuse p40 expression at ×40.

2.A 24 years old female presented with painless right breast lump measuring 4 x 3 x 3 cm. Tru-cut core needle biopsy was taken and sent for HPE.

Microscopy: Sections showed linear cores of breast tissue with invasive neoplasm arranged in nests.

These cells were ovoid to polygonal, had abundant clear cytoplasm, central round irregular hyperchromatic nuclei and inconspicuous nucleoli (Figure 2a-b). Morphologically differentials were invasive breast carcinoma, melanoma, lymphoma and metastatic clear cell carcinoma from kidney or ovary.

IHC revealed diffuse membranous positivity for CD45 (Figure 2c) and CD20. It was negative for PanCK (Figure 2d), HMB45and CD3. Further IHC markers revealed positivity for CD10, BCL6, MUM, BCL2 and c-MYC(Figure 2e and f). Thus, the final diagnosis of High-grade B-cell lymphoma (HGBCL) with MYC/BCL2 with BCL6 double expressor was made.

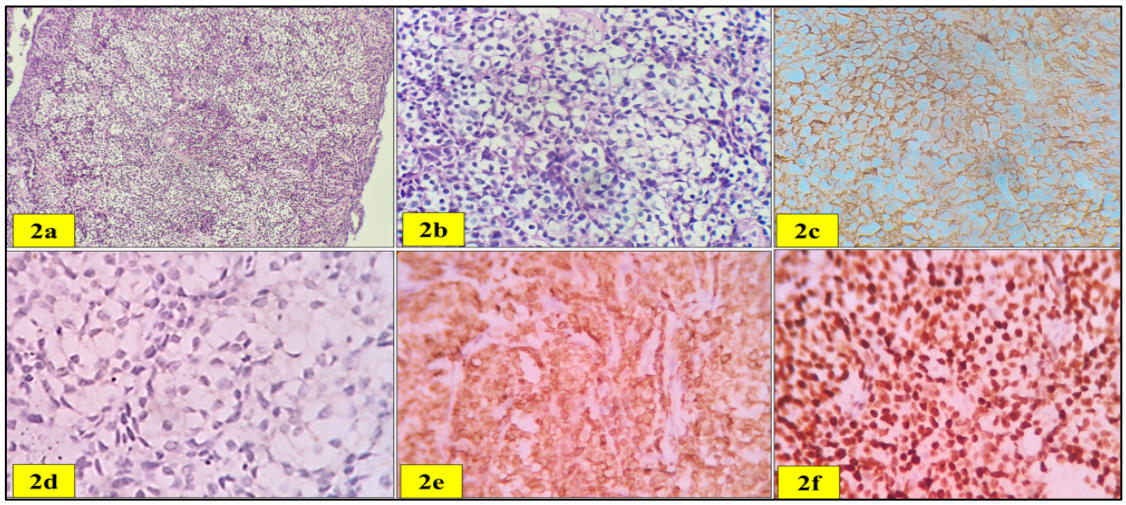

Figure 2(a and b): H and E stain showing high-grade B-cell lymphoma (HGBCL)at ×40, (c) IHC showing diffuse CD45 positivity at ×40,(d) negative for PanCK at ×40, (e and F) BCL2 and c-MYC positivity, respectively at ×40.

3.A 55 years old female presented with expansile lytic lesion in manubrium sterni measuring approx. 7 x 4 x 4 cm. USG-guided biopsy was taken and sent for HPE.

Microscopy: Sections showed linear cores of neoplastic tissue arranged in nests surrounded by delicate capillaries with lymphocytic infiltrates. These cells were polygonal, had abundant clear cytoplasm, central round irregular hyperchromatic nuclei and inconspicuous nucleoli (Figure 3a-b).

Morphologically the differentials were metastatic clear cellcarcinoma from kidney, ovary, lung, breast and metastatic SCC.

IHC revealed positivity for PanCK, PAX8 and CD10(Figure 3c and d). It was negative for CK7 and p40. So final diagnosis of Metastatic clear cell renal cell carcinoma was made.

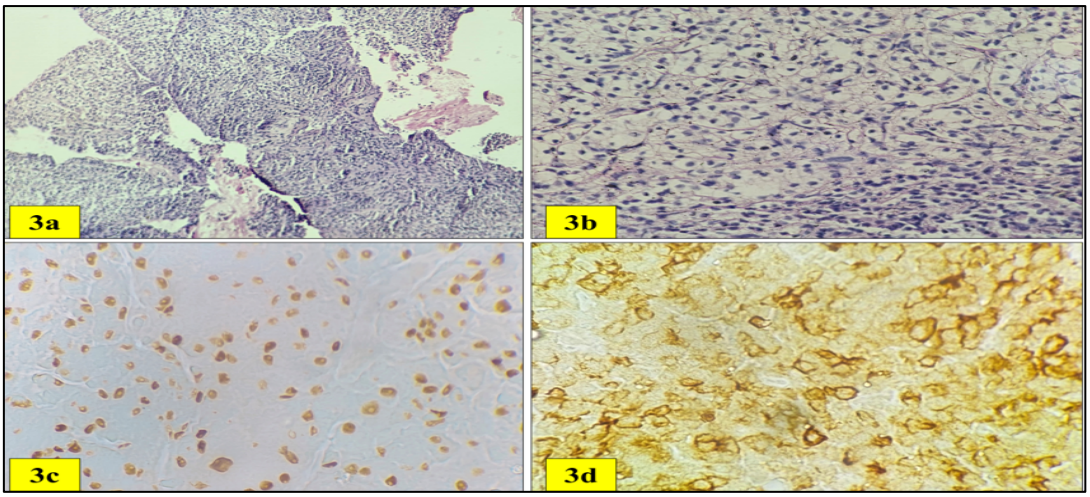

Figure 3(a and b): H and E stain showing metastatic clear cell renal cell carcinoma at ×40, (c and d) IHC showing PAX8and CD10 positivity, respectively at ×40.

4.A 68 years old male presented with multiple liver space occupying lesions. USG guided core biopsy was taken and sent for HPE.

Microscopy: Sections showed linear cores of hepatic tissue with neoplasm arranged in nests, cords and acinar patterns. These cells were ovoid to polygonal, had abundant clear cytoplasm, central round nuclei with dispersed chromatin and few cells showed conspicuous nucleoli. Few cells showed granular brown pigments in cytoplasm (Figure 4a-b). Morphologically diagnostic differentials were HCC, melanoma, metastatic adenocarcinoma and lymphoma. IHC revealed diffuse positivity for S100 and HMB45 (Figure 4c and d). It was negative for PanCK and Glypican3. So final diagnosis of Metastatic melanoma was made.

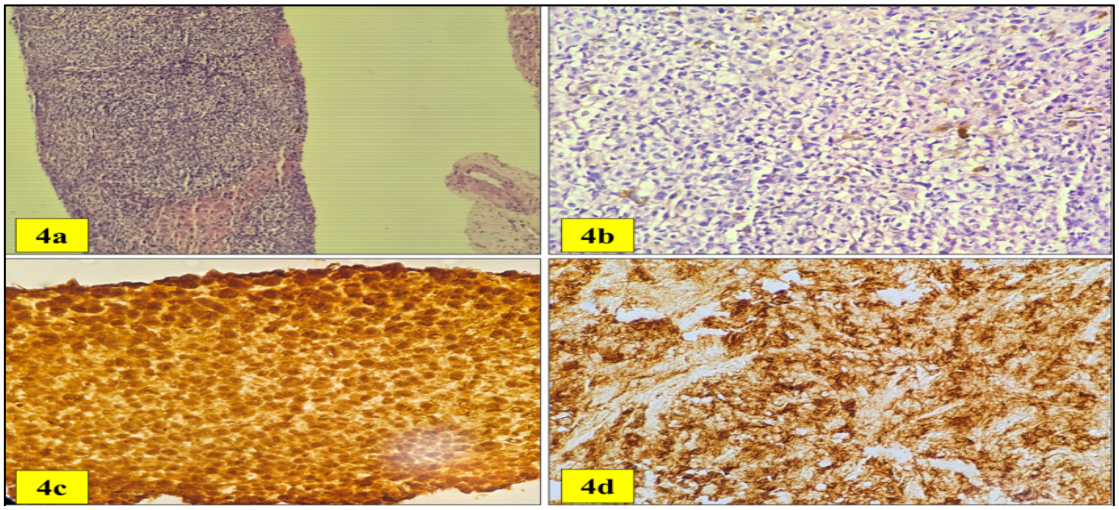

Figure 4(a and b): H and E stain showing metastatic melanoma at ×40, (c and d) IHC showing S100 and HMB 45 positivity, respectively at ×40.

5.A 57 years old female a known case of clear cell sarcoma abdominal wall, presented with left axillary swelling measuring 3 x 3 x 2.2 cm. USG guided core needle biopsy was taken and sent for HPE.

Microscopy: Sections showed linear core of neoplastic tissue arranged in nests separated by delicate fibrovascular septae. These cells were ovoid to epithelioid, had abundant clear cytoplasm, round irregular nuclei with dispersed chromatin and small conspicuous nucleoli (Figure 5a-b). Morphologically diagnostic differentials were metastatic breast carcinoma, lymphoma, melanoma and sarcoma. IHC revealed diffuse positivity for HMB45 and vimentin(Figure 5c and d). It was negative for PanCK, CD45, Desmin and SMA. So final diagnosis of Metastatic Clear cell sarcoma (CCS)in a known case was made.

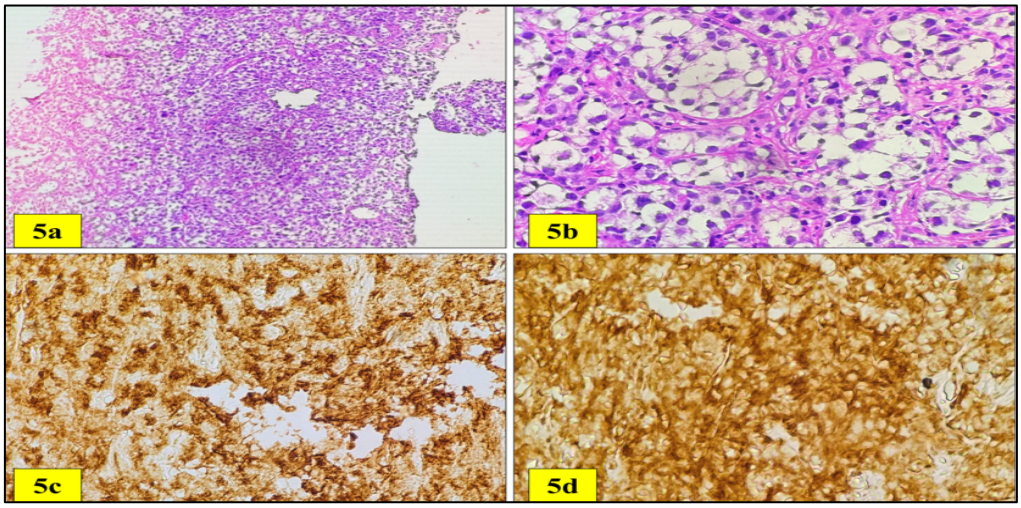

Figure 5(a and b): H and E stain showing metastatic clear cell sarcoma at ×40, (c and d) IHC showing HMB45 and vimentin positivity, respectively at ×40.

6.A 44 years old male presented with growth in stomach. UGI endoscopic guided biopsy was taken and sent for HPE.

Microscopy: Sections showed gastric mucosa with neoplasm arranged in sheets. These cells were ovoid to cuboidal, had abundant clear cytoplasm, central round irregular hyperchromatic nuclei and inconspicuous nucleoli (Figure 6a-b). Morphologically diagnostic differentials were poorly differentiated adenocarcinoma and lymphoma. IHC revealed diffuse positivity for panCK (Figure 6c) and negative for CD45 (Figure 6d). So final diagnosis of poorly differentiated adenocarcinoma was made.

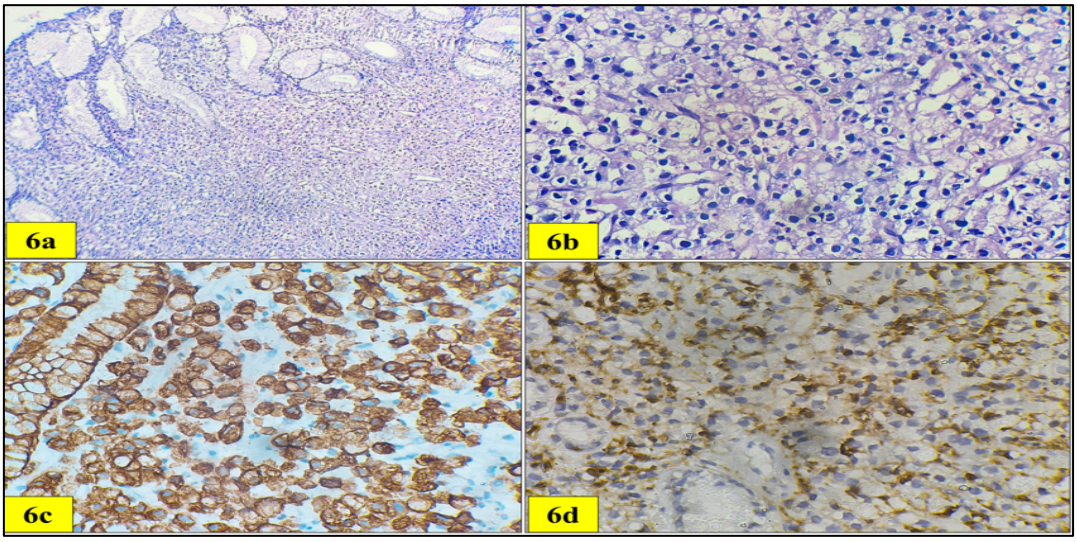

Figure 6(a and b): H and E stain showing poorly differentiated adenocarcinoma at ×40, (c) IHC showing PanCK positivity at ×40 and (d) negative CD45 in neoplastic cells at ×40.

7. A 31 years old female presented with pain in lower abdomen and left adnexal mass with dimensions of 7.3 × 6.1 x 5 cm. USG guided biopsy was taken and sent for HPE.

Microscopy: Sections showed linear cores of neoplastic tissue arranged in nodular pattern separated by loose fibrous band.

These cells were ovoid to polygonal, had abundant clear cytoplasm, central round irregular hyperchromatic nuclei and inconspicuous nucleoli. Few lymphocytes infiltrate was seen in fibrous band (Figure 7a-b). Morphologically diagnostic differentials were dysgerminoma, neuroendocrine tumour (NET), lymphoma and clear cell carcinoma. IHC revealed diffuse membranous positivity for CD45 (Figure 7c), CD20, BCL6, MUM1and BCL2 (Figure d and e).

It was negative for OCT3/4, CD117, INSM1, PanCK, CD10, c-MYC and CD3 (Figure 7f). Thus, the final diagnosis of diffuse large B-cell lymphoma (DLBCL), NOS, non-germinal centre phenotype was made.

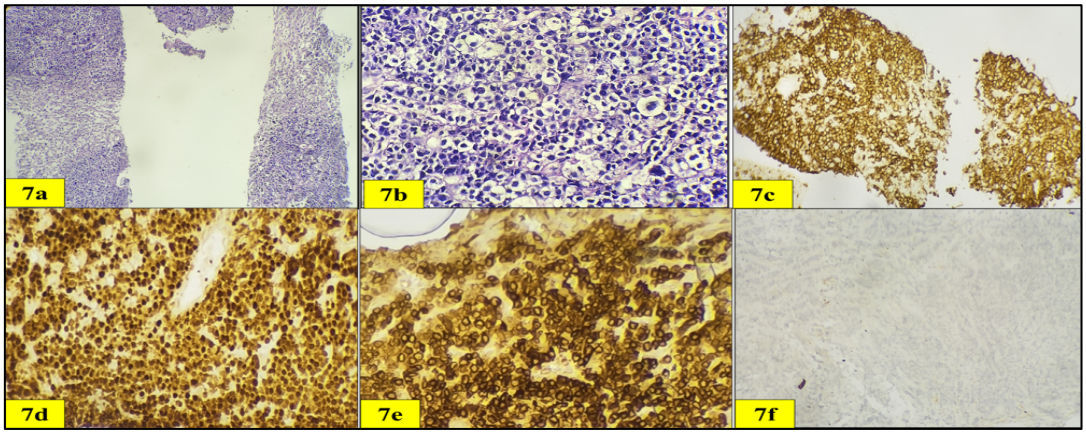

Figure 7(a and b): H and E stain showing DLBCL at ×40, (c, d and e) IHC showing diffuse positivity for CD45, MUM1 and BCL2respectively at ×40, (f) negative for OCT3/4 at ×40.

8.A 63 years old male presented with large hepatic mass measuring 6 x 5 x 3.3 cm. USG guided biopsy was taken and sent for HPE.

Microscopy: Sections showed linear cores of neoplastic tissue arranged in nests and trabecular pattern.

These cells were large epithelioid, had abundant clear to eosinophilic cytoplasm, pleomorphic hyperchromatic nuclei and inconspicuous nucleoli (Figure 8a-b). Morphologically diagnostic differentials were HCC, metastatic SCC and neuroendocrine neoplasm.

IHC revealed diffuse positivity for PanCK and INSM1 (Figure 8c-d). It was negative for Glypican3, p40 and PAX8. Ki 67 index was 80%. So final diagnosis of neuroendocrine carcinoma was made.

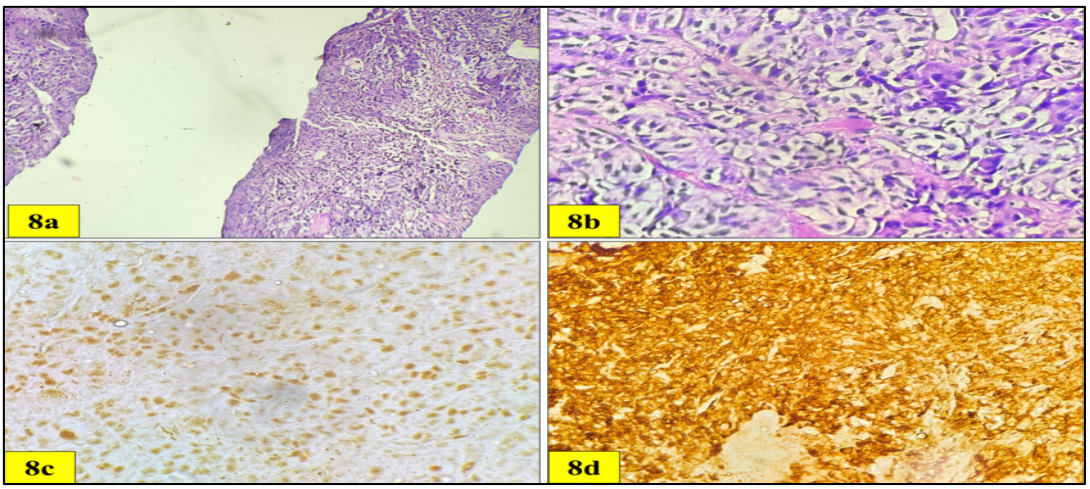

Figure 8(a and b): H and E stain showing neuroendocrine carcinoma at ×40, (cand d) IHC showing diffuse positivity for INSM1 and PanCK respectively at ×40.

9.A 38 years old male presented with cerebellopontine angle mass. Excision biopsy was taken and sent for HPE.

Microscopy: Sections showed neoplastic tissue arranged in nests separated by capillaries. These cells had abundant clear cytoplasm with indistinct cell borders, round irregular hyperchromatic nuclei and inconspicuous nucleoli (Figure 9a-b). Diagnostic differentials considered were hemangioblastoma, clear cell meningioma and metastatic ccRCC.

IHC revealed positivity for α-inhibin; negative for PanCK and EMA (Figure 9c-d). Thus, final diagnosis of Hemangioblastoma was made.

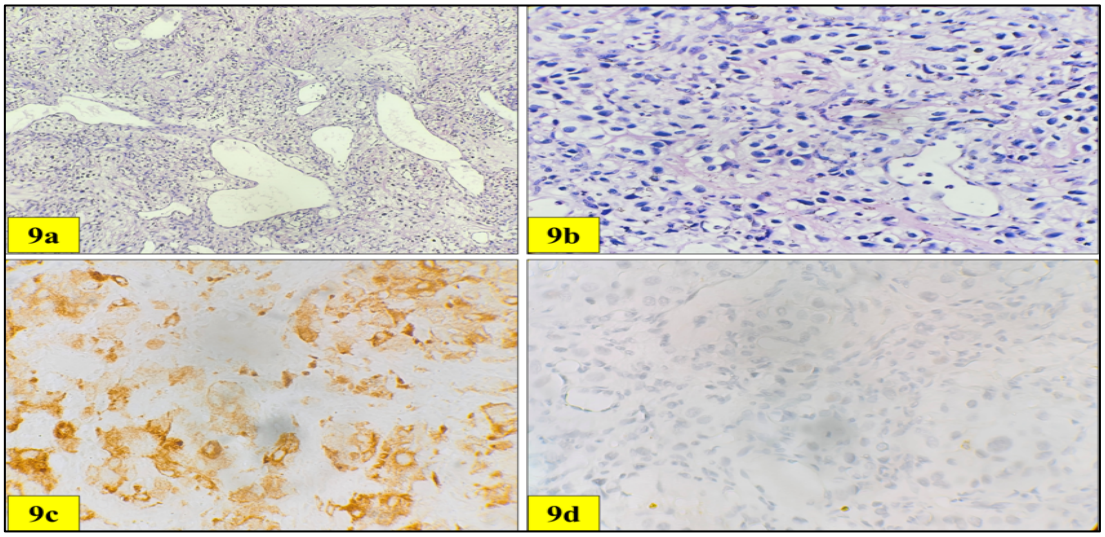

Figure 9(a and b): H and E stain showing hemangioblastoma at ×40, (c) IHC showing α-inhibin positivity at ×40 and (d) negative for PanCK at ×40.

Discussion:

Clear-cell morphology is a nonspecific histological feature encountered in neoplasms of diverse histogenetic origins. The presence of abundant clear cytoplasm, nested or trabecular architecture, and prominent vascularity may lead to considerable diagnostic overlap, particularly in small biopsy specimens. Although ccRCC is an important consideration, several other malignancies may mimic its morphology, necessitating careful clinicopathological correlation and targeted IHC[6,7].

In our study, all nine cases had similar looking morphology with each having individual diagnosis. Out of nine cases, three were from liver mass (Case-1,4, and 8), showing clear cytoplasm; but each having different diagnosis of metastatic SCC, metastatic melanoma and neuroendocrine carcinoma, respectively. In all three cases common differentials were HCC, metastatic clear cell carcinoma from organs like kidney and lung. Also, when brown pigments are seen in tumour cells in liver, it could possibly be melanin, lipofuscin, bile or hemosiderin pigments. Use of IHC markers PanCK, p40, HMB45 and INSM1 helped in arriving the diagnosis.

Two cases (Case 2 and 7) of lymphoma (HGBCL and DLBCL) diagnosed were from mass in breast and ovary respectively in our study. These sites are unusual and uncommon for lymphomas to arise. Primary breast and ovarian lymphoma accounts <1% and 0.5% of all cases of non-Hodgkin lymphoma, respectively[8,9]. Since lymphomas are rare in those sites, diagnosis may be missed in small biopsy, if appropriate IHC is not utilized. Clear cell morphology in breast tumours may be mistaken with invasive lobular carcinoma and melanoma commonly; while in ovary the clear cytoplasm may be mistaken for dysgerminoma or clear cell carcinoma. Utilization of lineage IHC markers (PanCK, CD45, SALL, HMB45) helps reach the diagnosis and avoid unnecessary surgical resection, since lymphoma is treated with systemic chemotherapy and surgery has little or no role. In our case we used PanCK, CD45, HMB45 and OCT3/4 as initial panel to reach the diagnosis.

One interesting case (Case 5) in our study was metastatic CCS in left axilla which is usually not a common differential diagnosis in routine practice. This tumour has close resemblance to melanoma especially immunophenotypically. They express all melanoma markers (S100, SOX10, HMB45, melanA, MITF)[10]. CCS is an aggressive malignancy with high rate of recurrence (40%) and metastasis (30-50%) to lung and lymph nodes[11]. CCS harbours EWSR1::ATF1 or EWSR1::CREB1 gene fusion, which is absent in melanoma. Another IHC marker PRAME (preferentially expressed antigen in melanoma) is a member of the

cancer/testis antigen family, which is nuclear transcription factor and particularly overexpressed in melanoma[12]. PRAME expression is not seen in CCS and it is useful in differentiating from melanoma. In our study, since it was known case of CCS of abdominal wall, further IHC marker PRAME was not advised.

Gastrointestinal tract malignancies like adenocarcinoma can sometime show clear cell morphology, creating diagnostic confusion especially when the carcinoma is in solid pattern. In our case gastric poorly differentiated adenocarcinoma (Case 6) with clear cytoplasm and relatively uniform cells mimicked lymphoma. Usually lymphoma cells are present subepithelially, infiltrating stroma and entrapping the glands. In such cases use of PanCK and CD45 immunomarkers are useful, whenever there is confusion.

Many tumours commonly metastasize to bone and sometime it might be the initial presentation (occult primary). Metastases to bone may be lytic (lung, breast, thyroid, kidney), sclerotic due to excess osteoblastic activity (prostate, neuroendocrine tumour/carcinoma), or mixed (breast, lung, gastrointestinal tract). In our study, the sternal lytic lesion with immunoreactivity to PAX8 and CD10 with negative CK7, proves metastatic ccRCC (Case 3).

Hemangioblastoma is a slow growing low grade CNS WHO grade1 tumour, that has excellent prognosis on complete excision[13]. It is a common manifestation of Von Hippel-Lindau (VHL) disease. It most commonly occurs in cerebellum. Here, the neoplastic component is the stromal cells that are present admixed with reactive vascular cells. Neoplastic cells express α-inhibin, D2-40 and brachyury. These are negative for cytokeratin and vascular markers (CD34, ERG, and CD31)[14].

When clear cells are seen in CNS tumour, it is important to rule out metastasis along with primary tumours like clear cell meningioma, gliomas with clear cell changes, hemangioblastoma etc. Besides CNS it can also occur in other sites like liver, lung, pancreas, kidney, intestines, skin, bone and soft tissue[15]. When presented in non-CNS sites, it is important keep hemangioblastoma in one of the differentials with other metastatic malignancies. In our case the location was typical and with inhibin positivity diagnosis of hemangioblastoma was made (Case 9).

Conclusion

Clear-cell morphology may be encountered in diverse neoplasms and can lead to significant diagnostic overlap between metastatic malignancies and primary tumours. This nine-case series highlights the importance of considering a broad differential diagnosis rather than attributing clear-cell morphology exclusively to ccRCC. A systematic approach integrating histomorphology, targeted immunohistochemistry, clinical history, and radiological findings is essential for accurate tumour classification. While considering IHC it is always preferable to use a lineage marker panel consisting of PanCK, CD45, S100, SALL4, and Vimentin for tumours showing poorly differentiated morphology and then proceed with further IHC marker of that line of differentiation. Molecular testing may be necessary in selected cases to resolve diagnostic uncertainty. Recognition of these morphological mimics can help minimise misclassification and support appropriate clinical management.

Ethical consideration: Ethical clearance for the above-mentioned study was obtained from the Institutional Ethics Committee of State Cancer Institute, Guwahati before commencement of the study.

Declaration of patient consent: Informed consent was taken from all participants and confidentiality of patient information was strictly maintained throughout the research.

Acknowledgement: We thank our institution, Head of various departments including oncopathology, Surgical and Head and neck oncology for providing us with the patient demographic details and submitting the specimens for our study. We are also thankful to the lab technicians for their hard work and effort on optimum tissue sectioning and staining for better visualisation under microscope.

Financial support and sponsorship: Nil.

References:

1. Kwon TJ, Ro JY, Mackay B. Clear-cell carcinoma: an ultrastructural study of 57 tumors from various sites. UltrastructPathol. 1996;20(6):519–27. doi:10.3109/01913129609016356 PubMed PMID: 8940759.
2. Khan T, Sullivan MA, Gunter JH, Kryza T, Lyons N, He Y, et al. Revisiting Glycogen in Cancer: A Conspicuous and Targetable Enabler of Malignant Transformation. Front Oncol. 2020;10:592455. doi:10.3389/fonc.2020.592455 PubMed PMID: 33224887; PubMed Central PMCID: PMC7667517.
3. Hashmi MF, Limaiem F. Renal Clear Cell Cancer. In: StatPearls [Internet] [Internet]. StatPearls Publishing; 2023 [cited 2026 Oct 14]. Available from: https://www.ncbi.nlm.nih.gov/sites/books/NBK563230/ PubMed PMID: 33085377.
4. Ibrahim RM, Steenstrup Jensen S, Juel J. Clear cell sarcoma-A review. J Orthop. 2018

Dec;15(4):963–6. doi:10.1016/j.jor.2018.08.039 PubMed PMID: 30210202; PubMed Central PMCID: PMC6134154.
5. Segal NH, Pavlidis P, Noble WS, Antonescu CR, Viale A, Wesley UV, et al. Classification of clear-cell sarcoma as a subtype of melanoma by genomic profiling. J Clin Oncol. 2003 May 1;21(9):1775–81. doi:10.1200/JCO.2003.10.108 PubMed PMID: 12721254.
6. Reuter VE, Tickoo SK. Differential diagnosis of renal tumours with clear cell histology. Pathology. 2010 Jun;42(4):374–83. doi:10.3109/00313021003785746 PubMed PMID: 20438412.
7. Auerbach A, Cassarino DS. Clear Cell Tumors of Soft Tissue. SurgPathol Clin. 2011 Sep;4(3):783–98. doi:10.1016/j.path.2011.08.005 PubMed PMID: 26837648.
8. Moura C, Leite MI, Parreira R, Medeiros A. Primary breast lymphoma. J Surg Case Rep. 2020 Jan 20;2020(1):rjz405. doi:10.1093/jscr/rjz405 PubMed PMID: 31976067; PubMed Central PMCID: PMC6970344.
9. Kumar N, Kumar R, Bera A, Srinivasan R, Sharma SC. Primary ovarian lymphoma: a case report and review of literature. J ObstetGynaecol India. 2014 Feb;64(1):65–7. doi:10.1007/s13224-012-0200-6 PubMed PMID: 24587611; PubMed Central PMCID: PMC3931906.
10. Obiorah IE, Ozdemirli M. Clear cell sarcoma in unusual sites mimicking metastatic melanoma. World J Clin Oncol. 2019 May 24;10(5):213–21. doi:10.5306/wjco.v10.i5.213 PubMed PMID: 31205866; PubMed Central PMCID: PMC6556591.
11. Gonzaga MI, Grant L, Curtin C, Gootee J, Silberstein P, Voth E. The epidemiology and survivorship of clear cell sarcoma: a National Cancer Database (NCDB) review. J Cancer Res Clin Oncol. 2018 Sep;144(9):1711–6. doi:10.1007/s00432-018-2693-6 PubMed PMID: 29961184; PubMed Central PMCID: PMC11813523.
12. Cassalia F, Danese A, Tudurachi I, Federico S, Zambello A, Guidotti A, et al. PRAME Updated: Diagnostic, Prognostic, and Therapeutic Role in Skin Cancer. Int J Mol Sci. 2024 Jan 27;25(3):1582. doi:10.3390/ijms25031582 PubMed PMID: 38338862; PubMed Central PMCID: PMC10855739.
13. Yin X, Duan H, Yi Z, Li C, Lu R, Li L. Incidence, Prognostic Factors and Survival for Hemangioblastoma of the Central Nervous System: Analysis Based on the Surveillance, Epidemiology, and End Results Database. Front Oncol. 2020;10:570103. doi:10.3389/fonc.2020.570103 PubMed PMID: 33014882; PubMed Central PMCID: PMC7509109.
14. Hoang MP, Amirkhan RH. Inhibin alpha distinguishes hemangioblastoma from clear cell renal cell carcinoma. Am J SurgPathol. 2003 Aug;27(8):1152–6. doi:10.1097/00000478-200308000-00014 PubMed PMID: 12883249.
15. Muscarella LA, Bisceglia M, Galliani CA, Zidar N, Ben-Dor DJ, Pasquinelli G, et al. Extraneuraxial hemangioblastoma: A clinicopathologic study of 10 cases with molecular analysis of the VHL gene. Pathol Res Pract. 2018 Aug;214(8):1156–65. doi:10.1016/j.prp.2018.05.007 PubMed PMID: 29941223.
16. Painter JT, Clayton NP, Herbert RA. Useful Immunohistochemical Markers of Tumor Differentiation. ToxicolPathol. 2010 Jan;38(1):131–41. doi:10.1177/0192623309356449 PubMed PMID: 20028992; PubMed Central PMCID: PMC3439132.