e-ISSN: 0976-822X, p-ISSN:2961-6042

Available online on http://www.ijcpr.com/

International Journal of Current Pharmaceutical Review and Research 2026; 18(11); 26-32

Case Series

Primary Retroperitoneal Tumours: Exploring the Histopathological Diversity and Diagnostic Challenges

Dharitri Rabha[1], Muktanjalee Deka[2], Jagannath Dev Sharma[3], Barasha Sharma Bharadwaj[4]

[1]Fellow, Department of Oncopathology, State Cancer Institute, Guwahati, 781032, Assam, India
[2]Professor and Head of the Department of Oncopathology, State Cancer Institute, Guwahati, 781032, Assam, India
[3]Professor and Consultant, Department of Oncopathology, State Cancer Institute, Guwahati, 781032, Assam, India
[4]Associate professor, Department of Oncopathology, State Cancer Institute, Guwahati, 781032, Assam, India

Received: 01-08-2026 / Revised: 15-09-2026 / Accepted: 21-10-2026
Corresponding author: Dr. Dharitri Rabha, email : dharitrirabha@gmail.com
Conflict of interest: Nil

Abstract

The retroperitoneum is a complex anatomical space located posterior to the parietal peritoneum and contains vital organs, major blood vessels, lymphatics, nerves, and connective tissue. Primary retroperitoneal tumours are uncommon neoplasms arising from mesenchymal, neural, lymphoid, or embryonal tissues of the retroperitoneal space, excluding tumours originating from retroperitoneal organs.

Primary retroperitoneal tumours account for less than 1% of all neoplasms and only 0.1- 0.2% of all malignancies. Due to their deep location, these tumours often attain a large size before becoming clinically apparent. Moreover, tumours originating in the retroperitoneum are heterogenous and therefore their definite diagnosis is challenging. Histopathology remains the gold standard technique for diagnosis with immunohistochemistry as a confirmatory tool.

This study analyses the frequencies of various retroperitoneal masses, both benign and malignant and also highlights the various diagnostic difficulties encountered with these lesions

Keywords: Primary Retroperitoneal Tumours, Retroperitoneal Angiosarcoma, Extragonadal Germ Cell Tumour, Retroperitoneal Sarcomas.

DOI: 10.25258/ijcpr.18.11.5

This is an Open Access article that uses a funding model which does not charge readers or their institutions for access and distributed under the terms of the Creative Commons Attribution License (http://creativecommons.org/licenses/by/4.0) and the Budapest Open Access Initiative (http://www.budapestopenaccessinitiative.org/read), which permit unrestricted use, distribution, and reproduction in any medium, provided original work is properly credited.

Introduction

The retroperitoneum is a complex anatomical space extending fromdiaphragm to the pelvis. It is bounded posteriorly by the transverse fascia and anteriorly by the posterior parietal peritoneum. It contains the blood vessels(abdominal aorta, inferior vena cava), extensive lymphatic networks, sympathetic chains, and organs like kidneys, adrenal glands, pancreas, ureters, and portions of the colon and duodenum[1].

Primary retroperitoneal tumours are uncommon neoplasms arising from mesenchymal, neural, lymphoid, or embryonal tissues of the retroperitoneal space, excluding tumours originating from retroperitoneal organs.

Primary retroperitoneal tumours account for less than 1% of all neoplasms and only 0.1- 0.2% of all malignancies[2]. Malignant tumours are more common in the retroperitoneum unlike in other parts of the body where benign neoplasms predominate. Soft tissue (mesenchymal) tumours of retroperitoneum are less common, but constitute 15% of all primary sarcomas[3].The retroperitoneum, consisting of loose connective tissue, often permits significant growth of masses before detection[4]. They are either detected as palpable masses or due to pressure symptoms. While radiology is critical for diagnosis, histopathological confirmation remains indispensable for distinguishing overlapping imaging characteristics. Thus, histopathological examination is the gold standard technique with ancillary tests like immunohistochemistry aiding in definite diagnosis of such lesions.

This study investigates the spectrum of various retroperitoneal tumours and therefore brings

forward the importance of identifying the uncommon or rarer lesions of the retroperitoneum.

Aim and Objectives:

- To determine the type and frequency of various primary retroperitoneal masses.
- To analyse the age and sex distribution of patients with retroperitoneal masses.
- To evaluate the benign and malignant nature of retroperitoneal tumours.
- To assess the role of immunohistochemistry in the diagnosis of the tumours

Materials and Methods

All patients diagnosed with primary retroperitoneal masses and subjected to biopsy or surgical excision during the study period are included in the study. Relevant clinical and radiological data were collected from medical records. Paraffin blocks and hematoxylin and eosin-stained sections were systematically examined. IHC correlation was done wherever necessary. The study is a Retrospective Observational Study conducted in the department of Oncopathology of a Tertiary Cancer care Institute in North-East India over a period of two years (August 2024 to July 2026)

Inclusion criteria:

- Patients with primary retroperitoneal masses.
- Biopsy and resection specimens received for histopathological examination.
- Adequate clinical and radiological information available.

Exclusion criteria:

- Tumors arising from retroperitoneal organs such as kidney, pancreas, adrenal gland, and ureter.
- Inadequate or poorly preserved specimens.
- Previously treated cases

Results

A total number of 36 cases of retroperitoneal mass were encountered in our department during the study period. Out of 36 cases, 20 were males and 16 were females with the male to female ratio 1.25:1. Youngest patient was 12years whereas the oldest was 86 years.

Table 1: shows age distribution of the tumours.

Age	Number of Patients
0-20 years	3
21-40 years	8
41-60 years	16
>60 years	9

Table 2: shows the various histological types of the tumours.

Histological type	Frequency
Well differentiated Liposarcoma	**7**
Dedifferentiated liposarcoma	**7**
Leiomyosarcoma	**6**
Lymphoma	**3**
Extragonadal germ cell tumour	**3**
Peripheral nerve sheath tumour	**2**
Metastatic carcinoma	**2**
Desmoid fibromatosis	**1**
lipoleiomyoma	**1**
Angiosarcoma	**1**
Lymphangioma	**1**
Serous cystadenoma	**1**
Solid pseudopapillary neoplasm	**1**

As can be seen, 29 cases were malignant and 6 cases were benign. 1 case of solid pseudopapillary neoplasm, had lymph nodal metastasis therefore it was not considered as benign. Apart from the more common lesions like liposarcomas and leiomyosarcomas, certain rare entities that we encountered are described as follows:

Case 1:

A 38 years male presented with abdominal pain, vomiting and fever. He also complained of weight loss and loss of appetite. USG revealed a well-defined mass in the retroperitoneum measuring 8 x 7.2 x 7cm without evident infiltration. A core biopsy from the mass was received.

Microscopy: Section showed tissue infiltrated by medium to large atypical lymphoid cells with vesicular chromatin, prominent nucleoli and scant

to moderate amount of eosinophilic to clear cytoplasm. On immunohistochemistry, cells of interest were positive for CD45, CD20, BCL6 and MUM1 while negative for panCK, CD3, CD10 and TdT.

Thus, the diagnosis was confirmed as Diffuse Large B-Cell lymphoma.

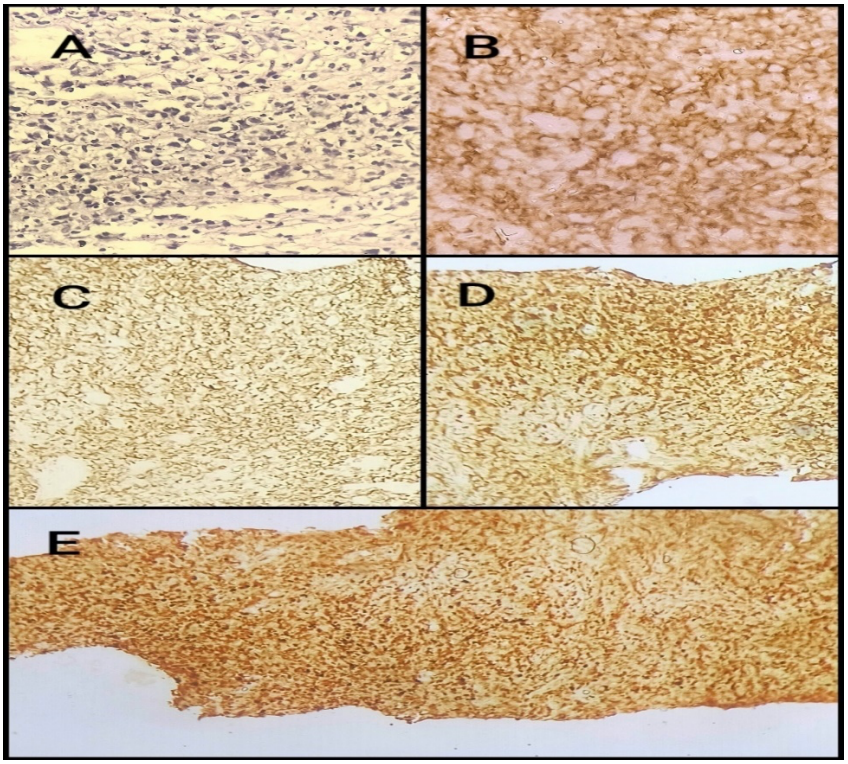

Figure1: (A)H and E stain showing section of retroperitoneal lymphoma biopsy, (B) CD45, (C) CD20, (D)BCL6, (E) MUM1

Case 2:

A 30 years male came with a complain of palpable abdominal mass with urinary incontinence. On USG, a well delineated mass with focal calcification was seen, measuring 12 x 10 x10 cm and compressing the right ureter. A guided biopsy was performed.

Microscopy: Sections showed collagenous tissue infiltrated by sheets and small lobules of tumour cells having round to oval nuclei, small conspicuous nucleoli and clear cytoplasm. Stroma showed scattered inflammatory cells and blood vessels.

On immunohistochemistry, tumour cells were positive for OCT3/4, PLAP and CD117 while negative for CD45, CD99, CD30 and glypican.

The diagnosis was given as Extragonadal Germ Cell Tumour of the retroperitoneum.

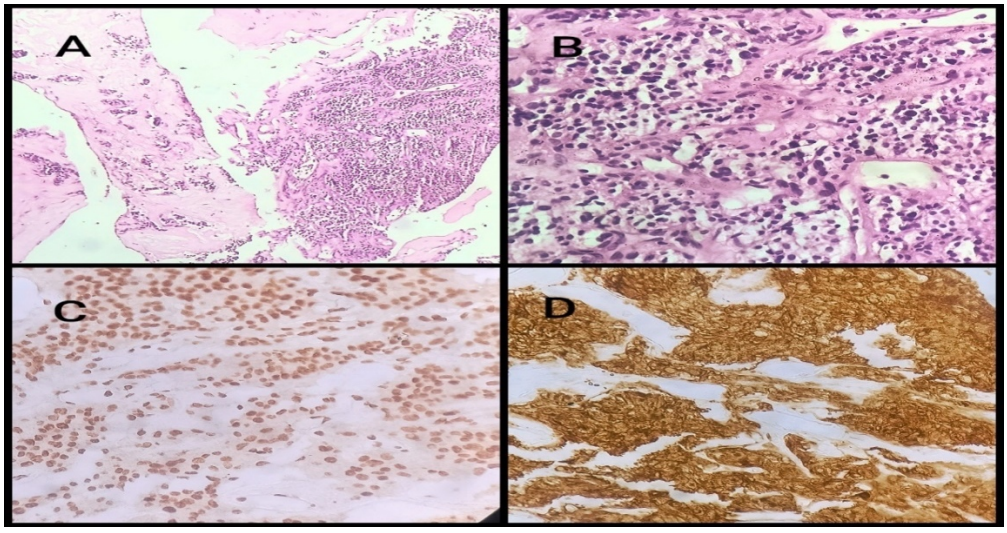

Figure 2: (A,B) H and E stain showing section of Extragonadal Germ Cell Tumour, (C) OCT3/4, (D) PLAP

Case 3:A 39 years female came with complains of waist pain and abdominal distension for the last 2 months. USG revealed an irregular shaped hypoechoic mass measuring 6 x 5.3 x 3.6 cm with non-uniform internal echo. A core biopsy from the mass was received.

Microscopy: Section showed fibrocollagenous tissue infiltrated by irregular shaped, branched spaces lined by round to oval and spindle cells with pleomorphic, hyperchromatic nuclei and scant cytoplasm. Few cells showed prominent nucleoli. On immunohistochemistry, cells were positive for CD34, CD31, ERG and negative for panCK, and desmin.

Therefore, the diagnosis was confirmed as Retroperitoneal Angiosarcoma.

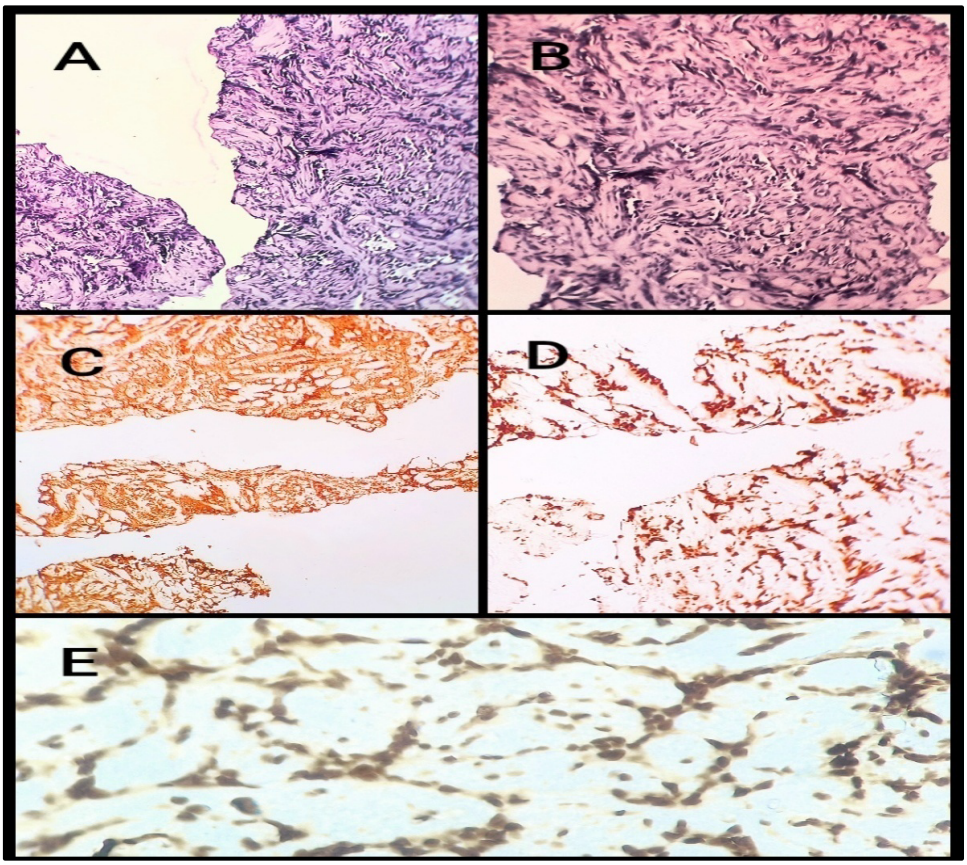

Figure 3: (A,B) H and E stain showing section of core biopsy from retroperitoneal angiosarcoma, (C)CD34, (D)ERG x10, (E) ERG x40

Case 4:

A 12 years female came to the OPD with complains of abdominal distension, pain abdomen and fever.

CT scan revealed a large lobulated mass measuring 20 x 17 x 8cm in the retroperitoneum with extensive internal hemorrhage and necrosis. The mass was seen abutting the uterus and sigmoid colon. Pancreas was normal radiologically but omental nodularities were noted. We received a resected specimen of the mass along with low anterior resection specimen and omental deposits

Microscopy: Sections showed round to polygonal cells arranged in solid sheets and papillaroid pattern.

Cells were predominantly uniform having moderate amount of eosinophilic cytoplasm, fine chromatin and inconspicuous nucleoli. Areas of hemorrhage and necrosis were noted. Pericolorectal lymph nodes showed tumour deposits.

Omentum was involved by tumour. On immunohistochemistry, cells were positive for panCK, cyclinD1, beta catenin and alpha-1-antichymotrypsin and negative for CD56, Pax8, CD99 and desmin. Thus, a diagnosis of Solid Pseudopapillary Neoplasm was confirmed.

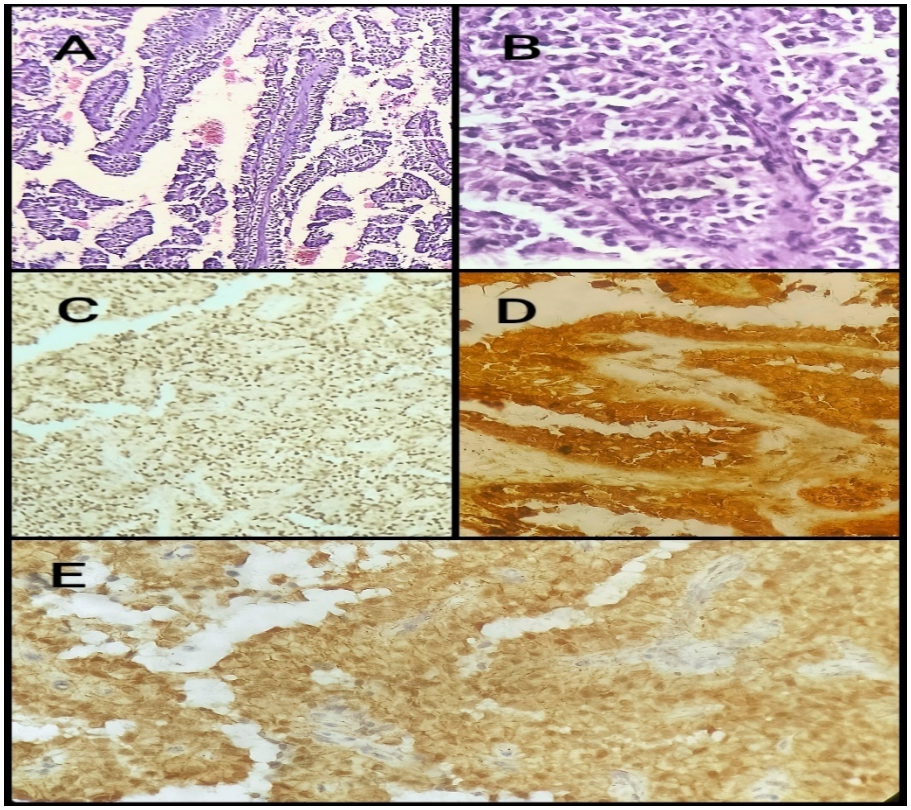

Figure 4: (A, B) H and E stain showing sections from Solid Pseudopapillary Neoplasm, (C)CyclinD1, (D) alpha-1-antichymotrypsin, (E)Beta-catenin

Discussion

Masses in the retroperitoneum are uncommon and usually presents late. Moreover, these tumours are mostly malignant and so, their prompt diagnosis and treatment are of utmost importance. However, the close proximity of these tumours to vital structures and difficulty in taking biopsies from these lesions further points us to cautiously put IHC panels and thus proving that histopathological examination is the gold standard for diagnosis[5].

In our study, we found that the most common tumour belonged to the adipocytic group including well differentiated and De-differentiated Liposarcomas. This is similar to findings in various literatures. Following liposarcomas, the next common tumour was leiomyosarcoma[5]. Apart from the more common neoplasms, we also diagnosed some rare tumours in the retroperitoneum.

Well differentiated liposarcoma is the most common adipocytic malignancy and are usually found in the deeper tissues of lower extremities followed by retroperitoneum. Since, it is composed of variably sized adipocytes, finding atypical nuclear features are sometimes difficult in small biopsies[6][7]. Dedifferentiated liposarcoma shows

an undifferentiated pleomorphic or spindle cells sarcoma component associated with well differentiated areas. Therefore, recognizing a well differentiated area is required morphologically for the diagnosis. Both these lesions are positive for MDM2 and CDK4 [8][9].

Leiomyosarcoma is the second most common sarcoma of the retroperitoneum after liposarcoma. They are usually better defined and may arise from blood vessels. IHC findings show positivity for desmin, SMA and h-Caldesmon [10][11].

Retroperitoneal lymphoma is a rare entity. A variety of Non-Hodgkin's lymphoma can involve the retroperitoneal space mostly diffuse large B-cell lymphomas which accounts for around 25% of all NHL cases. Radiological findings sometimes may cause dilemma in differentiating reactive process from lymphomas. Since, it is an unusual site so, differential diagnosis of all small round cell tumour should be considered [12][13].

Extragonadal malignant germ cell tumour is a rare entity in itself and are located in the midline of the body like mediastinum, retroperitoneum, sacrococcygeal region and even central nervous system. Diagnosing a germ cell tumour in retroperitoneum is difficult in Hand E stain alone and IHC is of great diagnostic value in these cases. Retroperitoneal germ cell tumours with positivity for OCT3/4, PLAP and CD117 are suggestive of seminoma while positivity for CD30, EMA and panCK point towards embryonal carcinoma [14][15].Angiosarcoma is a malignant soft tissue sarcoma of vascular origin. It accounts for approximately1% of all sarcomas. These tumours can occur in any part of the body, mostly skin (50%). Retroperitoneal angiosarcomas accounts for only about 10% of all angiosarcomas. Prognosis is usually bad with 5-year survival rate of only 20% which slightly increase when surgery is supplemented by radiotherapy and chemotherapy [16][17].

Primary retroperitoneal solid pseudopapillary neoplasm are low grade malignant tumour also known as solid papillary epithelial tumour.it is thought to be originating from pluripotent cells with various differentiation potential. Though mostly associated with pancreas, they can be seen in the retroperitoneum without any attachment with the pancreas (radiologically normal). Diagnosing this lesion radiologically is extremely difficult and therefore biopsy has become an important tool. Malignant potential is seen in tumours of >5cm size, discontinuous capsule, lymphovascular invasion and lymph nodal involvement. IHC is helpful in diagnosis where cells are positive for cyclin D1, alpha-1-antichymotrypsin, beta-catenin and CD56. Loss of E-cadherin can also be seen [18][19].

We also identified other tumours like desmoid fibromatosis, lymphangioma, serous cyst adenoma, and neurofibromas which are benign but relatively rare in such a location.

Conclusion

Retroperitoneum is an unusual site for tumours to occur. However, due to its various soft tissue contents, tumours of this site show a wide variety. Clinical and radiological findings are often overlapping and non-specific and therefore diagnosing these lesions by histopathology with ancillary IHC tests are almost always essential[20]. A systemic approach including clinical data, biochemical investigations, radiological findings and finally histopathological examination is required to establish a definite diagnosis.

Common lesions like liposarcomas and leiomyosarcomas should be kept in mind but rarer entities under soft tissue sarcomas should not be disregarded as well. Though malignant lesions are more common, benign tumours and even reactive processes should also be considered in the differential diagnosis before finalizing a histopathological report so as to avoid overdiagnosis and thus overtreatment.

Ethical consideration: Ethical clearance for the above-mentioned study was obtained from the Institutional Ethics Committee of State Cancer Institute, Guwahati before commencement of the study.

Declaration of patient consent: Informed consent was taken from all participants and confidentiality of patient information was strictly maintained throughout the study.

Acknowledgement: We thank our institution, Head of the Departments including Oncopathology, Surgical Oncology and Head and neck oncology for providing us with the patient details and submitting the specimens for our study. We are also thankful to the lab technicians for their hard work and effort. Last but not the least, we are thankful to our participants for their support and cooperation.

Financial support and sponsorship: Nil.

References:

1. Jaiswal S, Agrawal UK, Singh D. Retroperitoneal Masses Decoded: A Practical Multidisciplinary Diagnostic and Surgical Strategy Integrating Radiology and Pathology. Cureus. 2026 Mar 5;18(3):e104707.
2. Sassa, N. (2020), retroperitoneal tumors: Review of diagnosis and management. Int. J. Urol., 27: 1058-1070.

3. Goldblum, Folpe, Weiss, Enzinger & Weiss Soft Tissue Tumours, seventh edition, chapter 2:15-28
4. Das R, Purkayastha P, Das R, Unveiling the Enigma: Case Series Of Retroperitoneal Tumours And Literature Review. Trop J Pathol Microbiol. 2025; 11(1):5-16
5. Strauss DC, Hayes AJ, Thomas JM. Retroperitoneal tumours: review of management. Ann R CollSurg Engl. 2011 May;93(4):275-80.
6. Matthyssens LE, Creytens D and Ceelen WP (2015) Retroperitoneal Liposarcoma: Current Insights in Diagnosis and Treatment. Front. Surg. 2:4.
7. Siew C, Apte S, Baia M, Retroperitoneal and Mesenteric Liposarcomas, Surgical Oncology Clinics, 31, 399-417
8. Carina A Dehner, Ian S Hagemann, John S A Chrisinger, Retroperitoneal Dedifferentiated Liposarcoma: The Presence of the Dedifferentiated Component at the Resection Margin Is Associated With Shorter Recurrence-Free Survival, American Journal of Clinical Pathology, Volume 156, Issue 5, November 2021, Pages 920–925
9. Luo P, Cai W, Yang L, Wu Z, Chen Y, Zhang R, Yan W, Shi Y, Wang C. Retroperitoneal dedifferentiated liposarcoma: Analysis of 61 cases from a large institution. J Cancer. 2018 Oct 5;9(21):3831-3838. doi: 10.7150/jca.25715. PMID: 30410585; PMCID: PMC6218781
10. Øines MN, Smith HG, Preisler L and Penninga L (2024) Leiomyosarcoma of the abdomen and retroperitoneum; a systematic review. Front. Surg. 11:1375483.
11. Choi JH, Ro JY. Retroperitoneal Sarcomas: An Update on the Diagnostic Pathology Approach. Diagnostics (Basel). 2020 Aug 27;10(9):642.
12. Choi JH, Ro JY. Retroperitoneal Sarcomas: An Update on the Diagnostic Pathology Approach. Diagnostics (Basel). 2020 Aug 27;10(9):642.
13. Y. Ayari, T. Taktak, H. Boussaffa, Z. Ghorbel, A. Zehani, A. Sellami, S. Ben Rhouma, Y. Nouira, Retroperitoneal extra-adrenal non-Hodgkin lymphoma: An uncommon presentation, Urology Case Reports, Volume 23,2019, Pages 34-36
14. Singh, S., Mohanty, P., Das, P., Mohapatra, D., & Sahoo, P. K. (2023). Retroperitoneal germ cell tumor, primary or secondary: A diagnostic conundrum. MGM Journal of Medical Sciences, 10(2), 359–362.
15. Gao, Yuping & Jiang, Jiyao& Liu, Qiang. (2015). Extragonadal malignant germ cell tumors: A clinicopathological and immunohistochemical analysis of 48 cases at a single Chinese institution. International journal of clinical and experimental pathology. 8. 5650-7.
16. Chen, Bin-Qiong& Luo, Wei-Wen & Lin, Wen-Jie & Zhuang, Wei & Li, Shi-Lin. (2023). Primary retroperitoneal angiosarcoma: A case report. Open Life Sciences. 18. 10.1515/biol-2022-0546.
17. Liu, H., Miao, C. (2018). Retroperitoneal Angiosarcoma. In: Luo, CH. (eds) Retroperitoneal Tumors. Springer, Dordrecht
18. Chen L, Yuan M, Wang M, Luo C, Gao M, Huang Q, Li Z, Zhou Z. Case report: Retroperitoneal solid pseudopapillary neoplasm associated with multiple hepatic metastases. Front Oncol. 2024 Jan 30;14:1335930.
19. Ishii T, Terasaka T, Nishida K, Wada J. Retroperitoneal Solid Pseudopapillary Tumor Mimicking Adrenal Malignant Tumor in a 67-Year-Old Man. JCEM Case Rep. 2023 Aug 14;1(4):luad090.
20. Korant C, Singh I, Ratanpara K, Vaghela K, and Retroperitoneal Tumours: a case series and literature review. MGM J Med Sci 2024; 11:581-9.