e-ISSN: 0976-822X, p-ISSN:2961-6042

Available online on http://www.ijcpr.com/

International Journal of Current Pharmaceutical Review and Research 2026; 18(2); 1585-1587

Original Research Article

Evaluation of Involvement of Different Sites in Oesophageal Malignancy by Conventional Barium Swallow and CT-Scan

Ruchit Shah[1], Dhaval Modi[2]

[1]Assistant Professor, Department of Radiodiagnosis, ACPM Medical College, Sakri, Dhule, Maharashtra, India

[2]Assistant Professor, Department of Radiodiagnosis, ACPM Medical College, Sakri, Dhule, Maharashtra, India

Received: 01-11-2025 /Revised: 15-12-2025 / Accepted: 21-01-2026

Corresponding author: Dr. Ruchit Shah

Conflict of interest: Nil

Abstract

Oesophageal malignancy is the eighth most common malignancy in the world with an annual incidence of 456,000 new cases. In India, it is the fourth most common cause of malignancy-related deaths. The aim is to evaluate involvement of different sites in oesophageal malignancy by conventional barium swallow and CT scan. This study used data evaluating involvement of different site of in oesophageal malignancy among 57 patients which were diagnosed at radiology department of ACPM Medical College & hospital, Dhule, Maharashtra. Out of 57 patients with detected oesophageal malignancy most common site involved was middle one third of oesophagus followed by mid- lower oesophageal junction. CT scan is excellent in diagnosis of various site involved, distant metastasis and lymphadenopathy in oesophageal malignancy.

Keywords: Oesophageal malignancy, CT scan, various sites.

DOI: 10.25258/ijcpr.18.2.263

This is an Open Access article that uses a funding model which does not charge readers or their institutions for access and distributed under the terms of the Creative Commons Attribution License (http://creativecommons.org/licenses/by/4.0) and the Budapest Open Access Initiative (http://www.budapestopenaccessinitiative.org/read), which permit unrestricted use, distribution, and reproduction in any medium, provided original work is properly credited.

Introduction

Oesophageal malignancy is the eighth most common malignancy in the world with an annual incidence of 456,000 new cases. In India, it is the fourth most common cause of malignancy-related deaths. In study done by cancer research UK (May 2012) shows the most site was lower oesophagus.

Approximately, 47,000 new cases are reported each year and the reported deaths reach up to 42,000 each year in India. Population-based data suggest that oesophageal malignancy incidence peaks in the sixth decade in most parts of the world1.

The same trend has been reported in India, with the mean age in women slightly earlier than in men. Squamous cell carcinoma is twice as common in men compared to women.

This study is an attempt to evaluate different sites involvement in the oesophageal malignancy. Esophageal cancer still remains one of the most lethal of all cancers.

Aims and Objective: The aim is to evaluate involvement of different sites in oesophageal malignancy by conventional barium swallow and CT scan.

Material and Methods

This study used data of patients presented in radiology department in ACPM Medical College & hospital, Dhule, Maharashtra from June 2025 to December 2025. A 57 patients were diagnosed having esophageal malignancy at various sites using conventional barium swallow and CT scan and using prospective and observational (non interventional) type of study.

Discussion

In my study the most common site for carcinoma oesophagus was middle oesophagus (35%) followed by middle-lower oesophagus junction (17.5%) and lower oesophagus (15.8%).

Least common site was lower oesophagus, gastroesophageal junction and stomach. In study done by cancer research UK (May 2012) shows the most common site was lower oesophagus. Their reports were not similar as to these of mine. The CT scan is excellent modality in case of esophageal malignancy and to look for metastatic lesions; findings are consistent with Talasila P et al. Study-Imaging in Esophageal Cancer: A Comprehensive Review.

Table 1:

Sites	Number of patients	Percentage
Middle	20	35
Middle lower junction	10	17.5
Lower	9	15.8
Lower+Ge Junction	8	14
Upper	7	12.2
Upper middle junction	2	3.5
Lower+Junction+Stomach	1	1.7

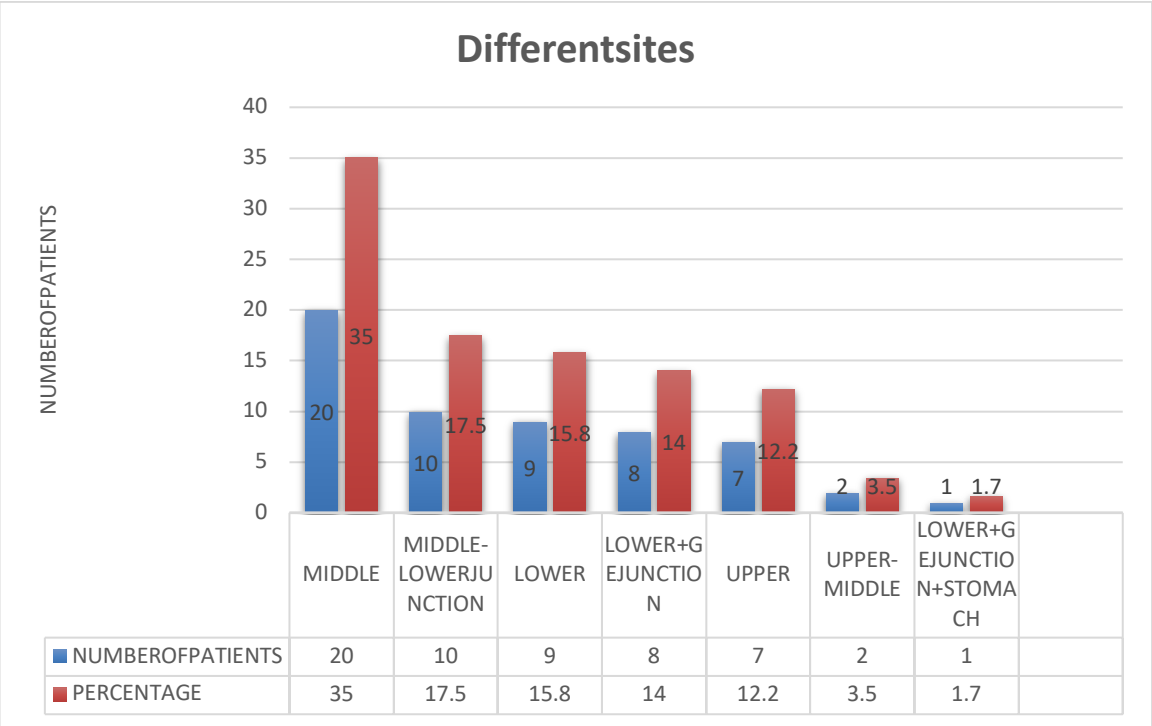

Figure 1: Differentsites

Case no. 1 – Adenocarcinoma of Lower esophagus + GE junction.

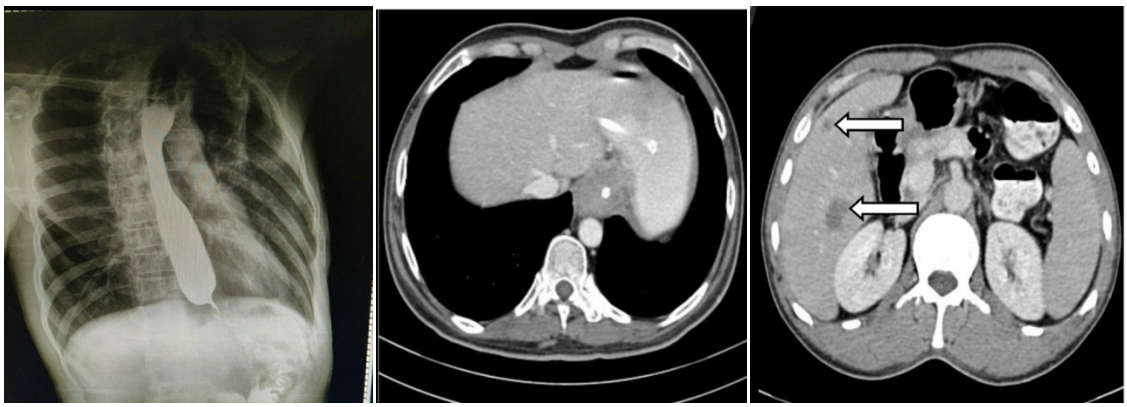

Figure 2:

Barium image shows evidence of short segment partial stricture of lower oesophagus with dilatation of the part of the esophagus proximal to it. On CECT, asymmetrical wall thickening is noted involving lower esophagus and GE junction with liver metastasis (white arrows).

Case no 2 – Squamous cell carcinoma of mid and lower oesophagus.

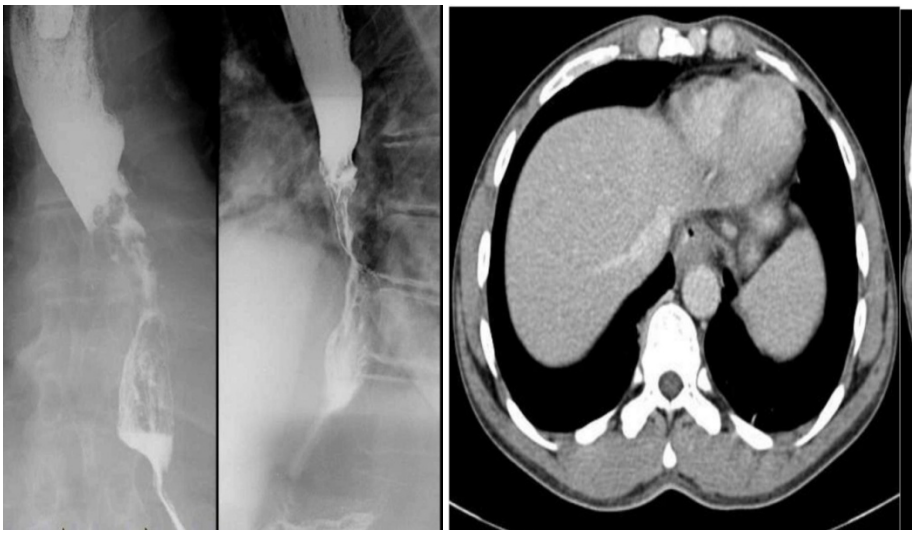

Figure 3:

Barium image shows evidence of long segment partial stricture of middle and lower oesophagus with dilatation of the part of the esophagus proximal to it. On CECT, asymmetrical wall thickening is noted involving mid and lower esophagus.

Conclusion

Carcinoma oesophagus is a fatal malignancy owing to high rate of metastasis at the time of diagnosis of the condition. Any patient presenting with symptoms of progressive dysphagia should undergo investigation.

Barium swallow is the initial investigation of the choice but does not allow staging and biopsy.

Double contrast barium swallow is more accurate in detecting early carcinoma. CT scan is excellent in the diagnosis of distant metastasis and lymphadenopathies. Thus, evaluation of various CT findings and preoperative staging of carcinoma of oesophagus will help to decide management of these patients. Hence, CT plays an important role in detecting and staging carcinoma of oesophagus.

Reference

1. Malkan G, Mohandas KM. Epidemiology of digestive cancers in India. I. General principles and esophageal cancer. Indian J Gastroenterol 1997; 16:98-102.
2. Cancer Research UK ([May 2012]), Oesophageal cancer statistics, Cancer Research UK.
3. Talasila P, Hedge SG, Periasamy K, Nagaraj SS, Singh H, Singh H, Gupta P. Imaging in Esophageal Cancer: A Comprehensive Review. Indian J Radiol Imaging. 2024 May 18;35(1):123-138. doi: 10.1055/s-0044-1786871. PMID: 39697520; PMCID: PMC11651834.
4. Basak Kumbasar, Carcinoma of esophagus: radiologic diagnosis and staging, European Journal of Radiology, Volume 42, Issue 3, 2002, Pages 170-180.