

A Comparative Study of Red Cell Histogram Along with CBC Parameters and Peripheral Blood Smear in Various AnemiasPreeti Sinha¹, Mukesh Prasad Sah²¹Tutor, Department of Pathology, Jawaharlal Nehru Medical College, Bhagalpur, Bihar.²Associate Professor, Department of Pathology, Jawaharlal Nehru Medical College, Bhagalpur, Bihar.

Received: 01-12-2025 / Revised: 15-12-2025 / Accepted: 21-01-2026

Corresponding author: Dr. Mukesh Prasad Sah

Conflict of interest: Nil

Abstract

Background: When it comes to determining the underlying cause of anemia, the importance of microscopic examination of peripheral blood smears (PBSs) cannot be understated. The red blood cell (RBC) parameters produced by cell counters can help with morphological classification of anemia. Therefore, a thorough evaluation of anemia requires both RBC values and microscopic inspection of PBSs. The purpose of this study was to assess and contrast the outcomes of two distinct approaches: automated cell counter-generated parameters and peripheral blood smear (PBS) analysis. Finding any variations or parallels between the diagnostic results generated by each approach was the goal.

Methods: From June 2025 to November 2025, a hospital based, prospective study was conducted at Department of Pathology, JLNMC, Bhagalpur, and Bihar. Total 1000 anemic patients was evaluated and compare the PBS findings and RBC parameters and histograms generated by a cell counter.

Results: In a sample of 1000 cases, we compared the typing of anemia using an automated analyzer and peripheral smear examination. Out of these cases, 690 showed consistent typing results between the two methods, while 310 showed discordant typing. The automated analyzer diagnosed majority of cases 70.1% as microcytic anemia and Normocytic, dimorphic, and macrocytic cases were found in 13.5%, 7.8%, and 4.3% of cases, respectively. Additionally, a normal histogram was observed in 17.6% of cases.

Conclusion: We have concluded that while the automated analyzer is useful in reducing the overall workload through its graphical representation of anemia typing, it should always be confirmed through microscopy. The automated analyzer is a helpful tool, it should not be relied upon solely for accurate anemia typing. Microscopy remains an essential method for confirming the results of automated analysis.

Keywords: Anemia, Peripheral blood smear, automated cell counter, Red blood cell.

DOI: 10.25258/ijcpr.18.2.269

This is an Open Access article that uses a funding model which does not charge readers or their institutions for access and distributed under the terms of the Creative Commons Attribution License (<http://creativecommons.org/licenses/by/4.0>) and the Budapest Open Access Initiative (<http://www.budapestopenaccessinitiative.org/read>), which permit unrestricted use, distribution, and reproduction in any medium, provided original work is properly credited.

Introduction

One of the most prevalent health issues worldwide, especially in India, is anemia. Significant morbidity and mortality have been linked to it. In order to diagnose anemia, platelet disorders, white cell diseases, leukemia, and other related problems, laboratory tests such as a complete blood count (CBC) and differential leukocyte count are essential. Blood cell analysis has greatly improved throughout time, moving from manual processes to automated tools that yield more precise and trustworthy results.[1]

Automated hematological analyzers have become an integral tool in providing accurate and efficient blood cell analysis. These machines not only provide essential information on RBC indices, hematocrit, and RBC distribution width (RDW), but also give a detailed RBC histogram. Such

comprehensive analysis plays a crucial role and managing red cell disorders. In fact, for accurate morphological diagnosis of anemia, the histogram provided by these analyzers is particularly important. Therefore, it is evident that the RBC histogram is a critical component in the laboratory evaluation of blood cells.

The peripheral blood smear has been a primary diagnostic tool for identifying anemia and other hematological disorders. The routine examination of blood films has significantly contributed to the interpretation of various hematological conditions. However, with the advancement in technology, automated hematology analyzers have now replaced the traditional manual methods for analyzing various parameters. These instruments have become the go-to tool for initial screening and

detection of hematological abnormalities in modern clinical diagnostic laboratories. As a result, the use of automated hematology analyzers has streamlined the process and enhanced the accuracy of hematological analysis.

Over the past few years, automated hematology analyzers have become increasingly popular due to their accuracy and reliability, which has significantly reduced subjective errors in diagnosing anemia. However, it is important to note that the microscopic examination of the peripheral blood smear (PBS) by a pathologist remains a critical step in the primary calibration of cell counters.

This examination plays a pivotal role in ruling out other hematological disorders that may go undetected through automated analysis alone. Therefore, despite the remarkable advancements in technology, the role of pathologists in examining the PBS remains invaluable in ensuring accurate and reliable diagnosis.[2]

Material and Methods: The comparative prospective study was conducted in Department of Pathology, Jawaharlal Nehru Medical College,

Bhagalpur, and Bihar from June 2025 to November 2025. Total 1000 newly anemic patients undergoing treatment and follow up. All patients, both male and female with anemia i.e. haemoglobin levels below WHO reference values were included in this study. Patients with normal Hemoglobin levels. (Within the normal range for that particular age) were excluded in this study. For this study, a blood sample of 3 ml will be collected in EDTA and thoroughly mixed. The analysis will be performed using automated hematology analyzers.

A peripheral smear will also be prepared using Giemsa stain as per standard operating procedures. The smear will be evaluated by a pathologist who will not have access to the histogram during reporting. The typing of anemia will be considered concordant if both methods indicate the same morphological type, otherwise, the results will be considered discordant.

Results

Our study included that out of total 1000 cases; males were 473 cases (47.3%), while females were 527 (52.7%). The male to female ratio was 0.95:1.(Table 1)

Table 1: Distribution of study population according to gender

Gender	No. of cases	Percentage
Male	473	47.3%
Female	527	52.7%
Total	1000	100%

Our study included patients spanning a wide age range, from 8 days to 75 years old. Among the study population, the largest proportion of patients (33.1%) fell within the age group of 31-45 years, followed closely by those aged 16-30 years (31.2%). (Table 2).

These findings suggest that anemia is a condition that affects individuals of various ages, and underscore the need for appropriate screening and management strategies across the lifespan. The prevalence and severity of anemia were assessed in

our study, with the majority of cases (51.0%) exhibiting a moderate degree of anemia. Severe anemia was present in 29.7% of cases, while mild anemia was observed in 19.3% of cases. For the purposes of our study, a hemoglobin level above 9.0g/dl was considered indicative of mild anemia.

These findings provide important insights into the prevalence and severity of anemia in our study population, which may have implications for public health interventions aimed at addressing this condition.

Table 2: Distribution of study population according to age

Age groups (years)	No. of cases	Percentage
Up to 1	7	0.7%
1-15	118	11.8%
16-30	312	31.2%
31-45	331	33.1%
46-60	211	21.1%
>61	21	2.1%
Total	1000	100%

In this study 701 cases (70.1%) were diagnosed as microcytic anemia by automated analyzer which constituted major portion of study population. In our study normocytic, dimorphic and macrocytic

cases were found 13.5%, 7.8% and 4.3% respectively by automated analyzer. In our study on peripheral smear examination maximum number of cases (51.6%) belonged to microcytic anemia and

normocytic anemia (30.3%) and 8.1% cases belonged to dimorphic anemia, 3.1% cases belonged to macrocytic anemia and 3.1%

hemolytic anemia and 0.3% Red Cell Agglutinins (cold) and 0.2% cases belonged to Thalassemia . (Table 3)

Table 3: Comparison of cases between automation and PBF

Types of Anemia	No. of cases (%)	
	Histogram & RBC indices	PBF
Normocytic	135(13.5%)	303(30.3%)
Microcytic	701(70.1%)	516(51.6)
Macrocytic	43(4.3%)	31(3.1%)
Dimorphic	78(7.8%)	81(8.1%)
Pancytopenia	39(3.9%)	33(3.3%)
Red Cell Agglutinins (cold)	2 (0.2%)	3 (0.3%)
Hemolytic	0 (0.0%)	31(3.1%)
Thalassemia	2(0.2%)	2 (0.2%)

The results of our study indicate that a normal histogram (bell shape) was observed in only 17.6% of cases, while the majority (81.8%) exhibited a broad base curve, including cases with a left shift, right shift, bimodal, and multiple peaks. Specifically, a left shift was observed in 73% of cases, while a right shift was present in only 4.1% of cases. Bimodal histograms were observed in

2.3% of cases, and multiple peaks were seen in only 1% of cases.(Table 4).

These findings highlight the variability in RBC size and shape observed in our study population and may have important clinical implications for the diagnosis and management of underlying conditions affecting RBC morphology.

Table 4: Distribution of cases asper histogram abnormality

Histogram abnormality	No. of cases	Percentage
Normal curve	176	17.6%
Left shift	730	73%
Right shift	41	4.1%
Broad base	818	81.8%
Bimodal	23	2.3%
Multiple peak	10	1%

On etiologically classifying anemia, the distribution of cases in different groups was as follows. Out of 1000 cases, nutritional deficiency anemia was found in 725 cases (72.5%). Among the 725 cases of nutritional deficiency anemia, iron deficiency was present in 618 cases (85.2%), megaloblastic anemia was found in 26 cases (3.5%), and mixed deficiency anemia was found in 81 cases (11.1%).

Out of the 26 cases of megaloblastic anemia, vitamin B12 deficiency was present in 21 cases, and folic acid deficiency was found in 5 cases.

Out of the total cases of macrocytic anemia on peripheral blood smear examination, 31% were identified. Among these, 26% of the cases had megaloblastic anemia, 2.1% had hypothyroidism, and 2.9% had alcoholic liver disease. Myelodysplastic syndrome (MDS) cases were not found in our study.

Out of the 618 cases of iron deficiency anemia, 25% of the cases had a serum iron level <30 µg/dL, while 62% of the cases had a serum iron level between 30-60 µg/dL, and 13% of the cases had a serum iron level >60 µg/dL. On peripheral blood smear examination, out of 1000 cases, 31 cases

(3.1%) belonged to hemolytic anemia. Among the 31 cases of hemolytic anemia, 3 cases belonged to sickle cell anemia. With the use of automated analyzer and peripheral smear examination we found that out of 1000 cases, 690 cases showed concordant typing of anemia and 310 cases showed discordant typing, which needs to be typed correctly with the help of peripheral smear examination.

Different types of anemia can be characterized by changes in the red blood cell (RBC) indices, namely mean corpuscular volume (MCV), mean corpuscular hemoglobin (MCH), and mean corpuscular hemoglobin concentration (MCHC). MCV, MCH and MCHC in cases of normocytic normochromic anemia were found within the normal limit and in the normocytic hypochromic anemia cases showed MCV within normal limit, MCH was less than normal and MCHC was near normal. In microcytic normochromic anemia, MCV falls below normal levels while MCH and MCHC remain within the normal range. Microcytic hypochromic anemia, on the other hand, is associated with low levels of MCV, MCH, and a near-normal MCHC. In macrocytic normochromic

anemia, there is a marked variation in the size and shape of RBCs, leading to an increase in MCV, MCH, and MCHC. Conversely, macrocytic hypochromic anemia is characterized by increased MCV and decreased MCH and MCHC values below the normal range. These distinct changes in RBC indices aid in the diagnosis and differentiation of various types of anemia. In our study, we found significant correlation between various hematological parameters in different types of anemia. The mean corpuscular volume (MCV) and red cell distribution width (RDW) showed a positive and moderate correlation with each other, not only in the overall sample but also in cases of iron deficiency anemia and megaloblastic anemia. Conversely, we found a mild positive correlation between MCV and RDW in mixed deficiency and anemia of chronic disease. Interestingly, we observed a positive and mild correlation between mean corpuscular hemoglobin (MCH) and RDW across the etiological groups of anemia. On the other hand, hemoglobin (Hb), hematocrit (HCT), red blood cell (RBC) count, and platelet count exhibited negative correlation with RDW, which

were statistically significant. We did not find any significant correlation between RDW and white blood cell (WBC) count or mean corpuscular hemoglobin concentration (MCHC).

The sensitivity of the red blood cell (RBC) histogram against peripheral blood film (PBF) was found to be 69% in our study. Further analysis of the morphological typing of different types of anemia using histogram and RBC indices revealed varying degrees of sensitivity and specificity. Microcytic hypochromic anemia showed the highest sensitivity of 92.7% but lower specificity of 63.3%.

In contrast, normocytic anemia showed high specificity of 96.2% but lower sensitivity of 48.7%. Macrocytic anemia was identified with high specificity of 97.9% and sensitivity of 94.1%. Dimorphic anemia also exhibited high specificity of 94.5% but lower sensitivity of 52%. These results highlight the utility of RBC histogram and indices in the morphological typing of anemia, although their diagnostic accuracy may vary depending on the type of anemia being assessed.

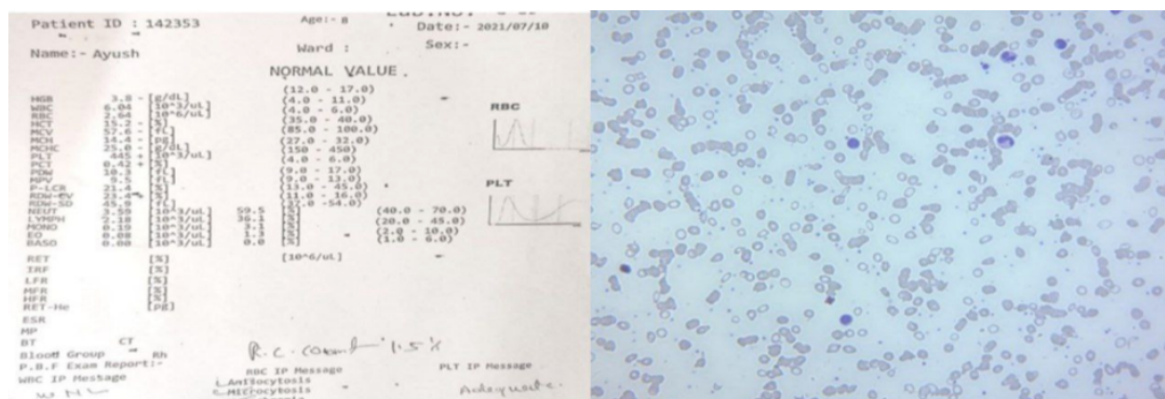


Figure 1: RBC histogram with microcytosis showing shift to left with low MCV value. Broad base indicates that variability in the size of RBC and shows high RDW and Peripheral blood smear shows microcytic hypochromic Anaemia

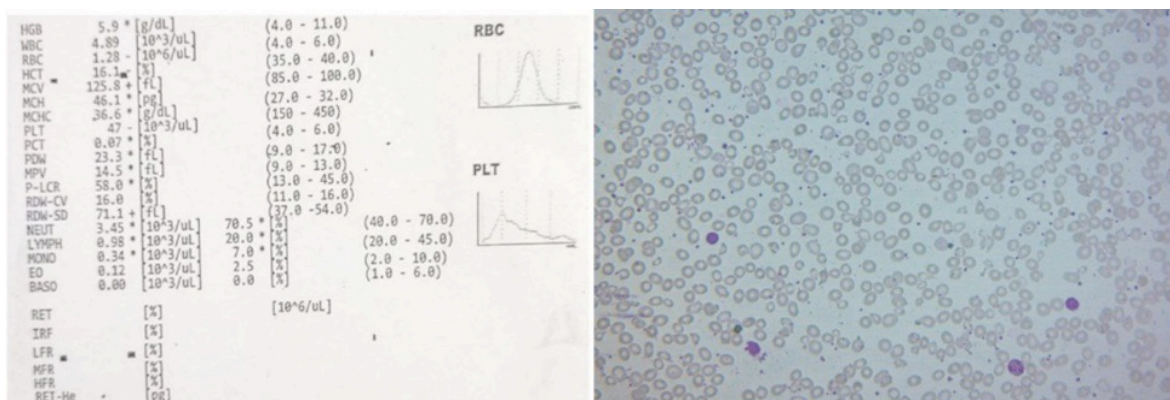


Figure 2: The RBC histogram shows macrocytosis with a shift to the right and a higher mean corpuscular volume (MCV) value. The broad base curve observed on the histogram indicates variability in the size of RBCs (anisocytosis) along with pokilocytosis, as evidenced by a high red cell distribution width (RDW)

value. The peripheral blood smear further confirms the presence of macrocytic RBCs along with macroovalocytes

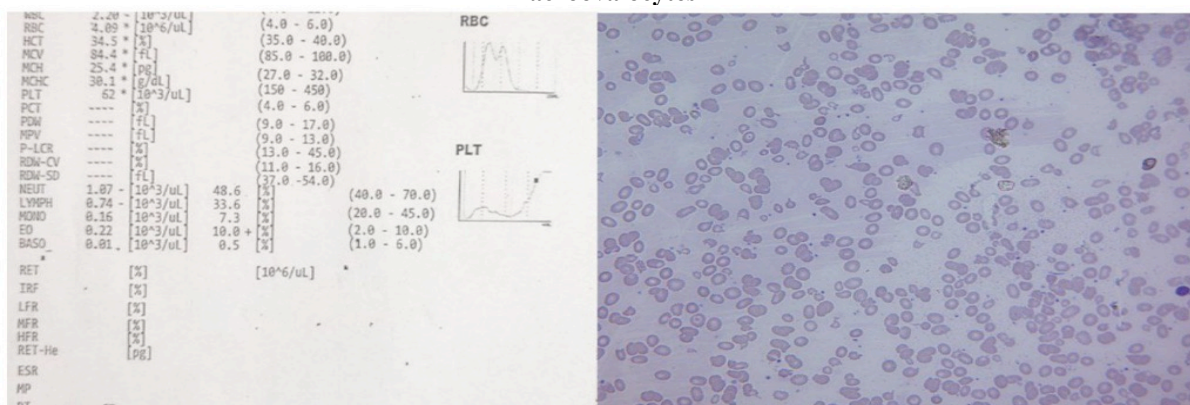


Figure 3: A bimodal peak with a broad base curve observed on the histogram indicates the presence of anisocytosis, which implies variability in RBC size, and pokilocytosis, which indicates variability in RBC shape.

This is further confirmed by a high red cell distribution width (RDW) value. The peripheral blood smear also shows a dimorphic picture, providing further evidence of the coexistence of two distinct populations of RBCs with varying sizes and shapes

Discussion

Visual representations, such as the RBC histogram, have a much more significant impact on clinicians than numbers alone. The newer generation of hematology analyzers generates a range of histograms that offer significant and essential information about a patient's blood profile, even before a peripheral blood smear is examined.[3]

The RBC histogram is generated by the automated hematology analyzer, which uses sophisticated technology to measure the size and number of red blood cells in the blood sample.[4] The normal histogram curve generated by the automated hematology analyzer is typically bell-shaped 156–162 and symmetrical, indicating a Gaussian distribution. This normal curve represents the range of mean corpuscular volume (MCV) between 80–100fl.[5–7]

Symmetry of the histogram curve can be determined by analyzing whether both sides of the curve are mirror images of each other. If the curve displays a similar frequency distribution on both sides, it is considered symmetrical and follows a Gaussian distribution. However, if one side of the curve is more pronounced than the other, it is considered skewed.[8] Under some situations it is altered and shows RBC flags.

The RBC histogram is a useful tool for evaluating the size of a patient's cells in comparison to a normal population. By plotting the number of cells on the Y-axis and the cell size or volume on the X-axis, we can observe any significant shifts in the

histogram curve. If the cell size decreases, the curve will shift towards the left, while an increase in cell size will shift the curve to the right. These directional shifts in the histogram can provide valuable diagnostic insights.[8–10] In a cell counter's RBC histogram, cells with volumes ranging from 36 fl to 250 fl are counted as RBCs.

However, if the RBC histogram begins below 36 fl, it may be indicative of the presence of small particles such as microspherocytes, parasites, platelet clumps, normoblasts, elliptocytes, bacteria, leukocyte fragments, and large platelets etc.[11] The area of the peak is used to calculate the MCV and RDW, i.e 60 fl to 125 fl.[12] The RBC distribution curves can provide valuable insights into various types of anemia. In cases of Iron deficiency anemia and beta thalassemia trait, the curves are shifted towards the left. On the other hand, a histogram with a broad base and a rightshifted curve may indicate macrocytic anemia.

A bimodal distribution curve in the RBC histogram is indicative of the presence of two distinct populations of red blood cells. This can occur in cases where a patient has received a blood transfusion or has a condition such as cold agglutinin disease, hemolytic anemia with schistocytes, or anemias with varying cell sizes. In such cases, interpreting the RBC histogram along with numerical values of RBC count, Hemoglobin, Hct, MCH, MCHC, and RDW can be of significant diagnostic value.

In our study, we provide the pathologist with comprehensive information to accurately diagnose and classify anemia. This includes a detailed clinical history, such as alcohol intake and blood transfusion records, previous medical records, as well as a family history of thalassemia. Additionally, we supply the pathologist with relevant clinical data, such as serum iron levels,

coagulation profile, HPLC data, vitamin B12 and folic acid levels, liver and kidney function test, as well as serum TSH and thyroid hormone levels in suspected cases of anemia.

Out of the 1000 cases of anemia included in our study, we observed a higher prevalence in females, with 52.7% of the cases being female. This finding is consistent with past research conducted by Singhal et al.[13] and Garg et al.,[4] where they reported female predominance with 64.9% and 62.9% cases, respectively. The age range in the study group of anemia was 8 days to 76 years with 331(33.1%) patient being in the age group 31-45 years followed by 312 (31.2%) in age group 16-30 years.

Various previous studies showed similar findings, where the maximum number of cases were in the 16-45 years age group and the majority were women. These results were in concordance with the studies conducted by Kumar et al.,[14] Cook et al [15] and Japheth et al.[16]

This can be due to Adolescence and adult group is an important period of nutritional vulnerability due to increased dietary requirements for growth and development and iron is in high demand as it is present in all body cells and is fundamental for basic physiological processes such as Hemoglobin formation thus, it is extremely important for the adolescent's iron requirements to be met. Women are more affected by iron deficiency anaemia than men because they lose iron during their menstrual periods and need more when pregnant or breast feeding thus women in reproductive age group are at high risk of developing iron deficiency anemia.

MCV and MCH were decreased in microcytic hypochromic anemia but MCHC was normal. RBC with low MCV had shown shift to left.17,18 High RDW and broad base curve was due to anisocytosis. In hypochromic microcytic anemia as there was micocytosis and RDW was increased. On peripheral smear also, hypochromic microcytic anemia showed anisopoikilocytosis.

In our study 701 cases (70.1%) were diagnosed as microcytic anemia which constituted major portion of study population by automated analyzer. In our study normocytic, dimorphic and macrocytic cases were found 13.5%, 7.8% and 4.3% respectively by automated analyzer.

In our study on peripheral smear examination maximum number of cases (51.6%) belonged to microcytic anemia followed by normocytic anemia (30.3%) and 8.1% cases belonged to dimorphic anemia, 3.1% cases belonged to macrocytic anemia and 3.1% hemolytic anemia and 0.3% Red Cell Agglutinins (cold) and 0.2% cases belonged to Thalassemia. On PBF examination in present study, majority of patients (51.6%) were of microcytic

anemia which was comparable to other studies, Singla et al., Rao et al., Chavda et al.[2,5,19] Second most common anemia noted was Normocytic anemia which is also in concordance with above mention studies. Microcytic hypochromic anemia was the most common type in our study and the most common cause of this was iron deficiency anemia. Iron deficiency anemia is the most common type of anemia in the world and there are various reasons for this. Causes may be due to inadequate dietary intake, increased demand mainly in pregnancy and lactation, poor absorption from gut, chronic blood loss, etc.[4]

Shifting of RBC histogram depends on the size of RBC; when the RBC size is microcytic, histogram shifts toward left while the presence of macrocytes causes shift of RBC histogram toward the right. Microcytic hypochromic anemia causes decrease in MCH and MCV which causes left shift of RBC histogram. Few cases of microcytic hypochromic anemia also showed broad-based RBC histogram. Broad-base curve denotes the presence of more anisocytosis with high RDW which can be confirmed by the microscopic examination of peripheral smear. The discrepancy of results in categorizing microcytic anemia in CBC and PBF may be due to various reasons such as the presence of giant platelets, formation of platelet clumps, and presence of fragmented RBCs in hemolytic anemias which are considered microcytic RBC by automated cell counter.[20]

In present study of histogram of 1000 cases, 17.6% showed normal curve, Left shift in 73.0% cases, Broad based in 81.8%, Right shift in 4.1%, Bimodal peak in 2.3% which were in accordance with other studies like Rao et al., Chavda et al.[19] The higher incidence of normal curve in present study is due to inclusion of outpatient anemia patients only which usually have mild anemia.

In our study normal histogram (bell shape) was found in 176 cases (17.6%). Broad base was common which involved cases with normal histogram, left shift, right shift, bimodal and multiple peaks. So this accounted majority of cases (81.8%).

Similarly, left shift contributed 730 cases (73%) of which involved cases were normal curve, broad base, bimodal and multiple peaks. Right shift contributed 41cases (4.1%) of which 16 cases with wide base and 8 cases with narrow base.

23 cases (2.3%) were bimodal in our study. Out of these 19 cases were left shift and wide base, 2 cases with no shift and wide base and only 1 case with no shift and narrow base. Only 10 cases (1%) with multiple peaks were involved in our study. Out of these 5 cases with left shift and wide base, 3 cases with variable peak and wide base and only 2 case

with right shift and wide base. Sandhya et al.[9], Chavda et al [19] and Byna Syam Sundara Rao et al.[5] in their studies also found similar distribution. Out of 1000 cases, 690 (69%) cases showed concordant typing of anemia with automated analyzer and using peripheral smear examination. 310 (31%) cases showed discordant typing, which need to be typed correctly with peripheral smear examination.

Farah E et al[21] studied 350 cases and found that PBF examination provided additional information in 21.7% of the cases. In a similar way Radadiya P et al[22] studied 100 cases found that PBF examination provided additional information in 28%. The present study showed that 33% cases provided additional information by PBF examination which was almost similar with Radadiya P et al.[22]The results of the present study were in contrast with an earlier report by Pierre[23] and Novis et al.[24] who reported that automated haematology analyzer are more accurate in the detection of specimens with morphological abnormality than the traditional eye count method.

Conclusion

When combined with an understanding of the normal curve and CBC measures such as red cell indices and RDW, histograms are a crucial tool for the preliminary morphological study of blood samples. Potential pathology can be found by analyzing the histograms' form, offering clues for situations that call for a thorough peripheral smear test. Furthermore, the histograms' shape and direction of change provide information about RDW, MCV, and RBC count. Hence, by reviewing the histograms, one can anticipate what to expect when evaluating the peripheral blood smear. Although automated analyzers can reduce the overall workload with their advanced graphical representation, it is crucial to confirm the results with microscopy. Based on our study, we concluded that while histograms generated by automated analyzers are useful, they should always be validated by microscopy to ensure accuracy.

References

1. Atlas and Text of Hematology, Singh T. 2018; p. 65; Delhi, India: Avichal Publishing Company, 4th ed.
2. A comparative analysis of anemia cases using peripheral blood smears and cell counter-generated red cell indices was conducted by Singla S, Bedi S, and Joshi K. *Medplus Int Med J.* 4(1):44–8, 2017.
3. Histogram interpretation and its relationship to peripheral smear results (Gupta A, Gupta P, Bhagat VM). 2017; 6(60):4417–20; *J Evol Med Dent Sci.*
4. Garg M, Gitika, Sangwan K. Comparison of automated analyzer generated red blood cell parameters and histogram with peripheral smear in the diagnosis of anaemia. *Int J Contemp Med Res.* 2019;6(8):1–6.
5. Rao BSS, Santhi V, Rao NM, Grandhi B, Reddy VLM, Siresala P. RBC histogram as supplementary diagnostic tool with peripheral smear examination in evaluating anemia. *Ann Pathol Lab Med.* 2017; 4:668–72.
6. Adewoyin AS, Nwogoh B. Peripheral blood film - A review. *Ann Ib Postgrad Med.* 2014;12(2):71–9.
7. Bain BJ. Diagnosis from the blood smear. *N Engl J Med.* 2005;353(5):498–507.
8. Interpretation of red blood cell rbc histograms. Available from: https://www.labce.com/spg579125_interpretationofredbloodcellrbchistograms.aspx
9. Sandhya I, Muhasin T. Study of RBC Histogram in Various Anemia. *J Evol Med Dent Sci.* 2014;3(74):15521–34.
10. Bessman JD, Gilmer PR, Gardner FH. Improved classification of anemias by MCV and RDW. *Am J Clin Pathol.* 1983;80(3):322–6.
11. Ford J. Red blood cell morphology. *Int J Lab Hematol.* 2013;35(3):351–7.
12. Lokwani DP. *The Abc of Cbc Interpretation of Complete Blood Count & Histograms.* Delhi, India: Jaypee Brothers Medical Publishers; 2013.
13. Singhal S, Verma N, Rathi M, Singh N, Singh P, Sharma SP, et al. Can peripheral blood smear examination be totally replaced by automated hematology analyser-with special reference to anemia? *Int J Res Med Sci.* 2016;4(10):4563–6.
14. Kumar A, Kushwaha R, Gupta C, Singh US. An analytical study on peripheral blood smears in anemia and correlation with cell counter generated red cell parameters. *J Appl hematology.* 2013;4(4):137–44.
15. Cook JD, Finch CA, Smith NJ. Evaluation of the Iron Status of a Population. *Blood.* 1976;48(3):449–55.
16. Mukaya JE, Ddungu H, Ssali F, O'Shea T, Crowther MA. Prevalence and morphological types of anaemia and hookworm infestation in the medical emergency ward, Mulago Hospital, Uganda. *S Afr Med J.* 2009;99(12):881–6.
17. Gulati G, Song J, Florea AD, Gong J. Purpose and Criteria for Blood Smear Scan, Blood Smear Examination, and Blood Smear Review. *Ann Lab Med.* 2013;33(1):1–7.
18. Grotto HZW. Why and how validate criteria by manual smear review to improve laboratory

- productivity? . Rev Bras Hematol Hemoter. 2015;37(1):67–8.
19. Chavda J, Goswami P, Goswami A. RBC Histogram as diagnostic tool in anemias. J Dent Med Sci. 2015;14(10):19–22.
 20. Bhargava OP, Kumre M, Thakur J. Comparative study of automated cell counter generated data and peripheral blood smear evaluation in cases of anaemia. Asian J Med Res. 2021;10:1–5.
 21. Farah E, Mehwish A, Nafisa HA. Comparative Study in the Diagnosis of Anemia by SYSMEX KX-21N hematology analyzer with Peripheral Blood Smear. Int J Endorsing Health Sci Res. 2013;1(2):89–92.
 22. Radadiya P, Mehta N, Goswami H, Gonsai RN. Automated red blood cell analysis compared with routine red blood cell morphology by smear review. NHL J Med Sci. 2015;4(1):53–7.
 23. Pierre RV. The demise of the eye count leucocyte differential. Clin Lab Med. 2002;22(1):279–97.
 24. Novis DS, Walsh M, Wilkinson D, Louis MS, Ben-Ezra J. Laboratory productivity and the rate of manual blood smear review: College of American Pathologist Q-Probes Study of 95,141 complete blood count determinations performed in 263 institutions. Arch Pathol Lab Med. 2006;130(5):596–601.