

Prospective Observational Study of Anatomical Correlation between External Jugular Vein and Brachial Plexus at Cricoid and Supraclavicular Levels Using Ultrasonography

Anmol B. Lalwani¹, Vijay Patil², Ketaki Nirkhi³

Associate Professor, Department of Anaesthesia, Rajiv Gandhi Medical College, Kalwa Thane, Maharashtra, India

Professor & HOD, Department of Anaesthesia, Rajiv Gandhi Medical College, Kalwa Thane, Maharashtra, India

Associate Professor, Department of Anaesthesia, Rajiv Gandhi Medical College, Kalwa Thane, Maharashtra, India

Received: 01-11-2025 / Revised: 15-12-2025 / Accepted: 21-01-2026

Corresponding author: Dr. Anmol B. Lalwani

Conflict of interest: Nil

Abstract

Background: Regional anaesthesia is widely used for upper limb surgeries. Although ultrasound guidance is considered the gold standard for brachial plexus blocks, its availability is limited in many developing countries. Reliable surface anatomical landmarks therefore remain clinically important.

Aim: To evaluate the anatomical relationship between the external jugular vein (EJV) and the brachial plexus (BP) at the cricoid and supraclavicular levels using ultrasonography, and to assess the usefulness of EJV as a surface landmark for landmark-guided brachial plexus block.

Methods: This prospective observational study included 270 ASA physical status I and II adults aged 18–60 years. Ultrasound was used to identify the position of the brachial plexus relative to the external jugular vein at the cricoid and supraclavicular levels. Distances from skin to brachial plexus and from EJV to brachial plexus were measured and analysed statistically.

Results: In 90% of patients, the brachial plexus was located medial to the external jugular vein at both levels. At the cricoid level, the EJV-to-brachial plexus distance was less than 1 cm in 92.2% of cases. A strong positive correlation was observed between skin-to-brachial plexus distance at the two levels ($r = 0.75$), while EJV-to-brachial plexus distance showed no significant correlation ($r = -0.02$).

Conclusion: The external jugular vein shows a consistent anatomical relationship with the brachial plexus and may serve as a useful surface landmark for landmark-guided brachial plexus block, particularly in resource-limited settings where ultrasound is unavailable.

Keywords: Brachial plexus, External jugular vein, Regional anaesthesia, Ultrasound, Supraclavicular block.

DOI: 10.25258/ijcpr.18.2.94

This is an Open Access article that uses a funding model which does not charge readers or their institutions for access and distributed under the terms of the Creative Commons Attribution License (<http://creativecommons.org/licenses/by/4.0>) and the Budapest Open Access Initiative (<http://www.budapestopenaccessinitiative.org/read>), which permit unrestricted use, distribution, and reproduction in any medium, provided original work is properly credited.

Introduction

Regional anaesthesia offers several advantages over general anaesthesia for upper limb surgeries, including better postoperative analgesia, reduced morbidity, and cost effectiveness.

Brachial plexus block is a well-established technique that provides complete sensory and motor blockade of the upper limb.

While ultrasound guidance has improved the success and safety of these blocks, its routine use is limited in many developing and resource-constrained settings. Hence, refined landmark-guided techniques continue to have clinical relevance.

Objectives

Primary Objective: To assess the anatomical relationship between the external jugular vein and the brachial plexus at the cricoid and supraclavicular levels using ultrasonography.

Secondary Objectives:

1. To identify inter-individual anatomical variation.
2. To evaluate the clinical applicability of using the external jugular vein as a surface landmark for landmark-guided brachial plexus block.

Materials and Methods

After obtaining Institutional Ethics Committee approval and written informed consent, 270 ASA I and II patients aged 18–60 years were enrolled. Patients with BMI >35 kg/m², prior neck surgery or

trauma, or cervical spine pathology were excluded. Systematic random sampling was used.

Ultrasound examination was performed at the cricoid and supraclavicular levels to locate the brachial plexus and measure distances from the skin and external jugular vein.

Table 1: Distribution of study subjects according to Skin to BP distance and EJV to BP distance at Supraclavicular Level on USG (n = 270)

On USG at Supraclavicular Level	Category	Frequency (n = 270)	Percentage (%)	Mean ± SD
Skin to BP distance	≤ 1	38	14.1	1.34 ± 0.30
	> 1	232	85.9	
EJV to BP distance	≤ 1	35	13	1.95 ± 4.26
	> 1	235	87	

Table 2: Distribution of study subjects according to Skin to BP distance and EJV to BP distance at Cricoid Level on USG (n = 270)

On USG at Cricoid Level	Category	Frequency (n = 270)	Percentage (%)	Mean ± SD
Skin to BP distance	≤ 1	89	33	1.14
	> 1	181	67	
EJV to BP distance	≤ 1	249	92.2	0.29
	> 1	21	7.8	

Table 3: Anatomical Relation

Anatomical Relation	On USG Relation between EJV and BP at Cricoid Level		On USG Relation between EJV and BP at Supraclavicular level	
	Frequency (n=270)	Percentage (%)	Frequency (n=270)	Percentage (%)
BP is lateral to EJV	24	8.9%	17	6.3%
BP is Medial to EJV	246	91.1%	243	90.0%
BP is posterior to EJV	0	0.0%	10	3.7%

Table 4: Relationship Description

Relationship Description	Frequency (n=270)	Percentage (%)
ISG medial to EJV	233	86.3
ISG is posterior to EJV	17	6.3
ISG posterolateral to EJV	20	7.4

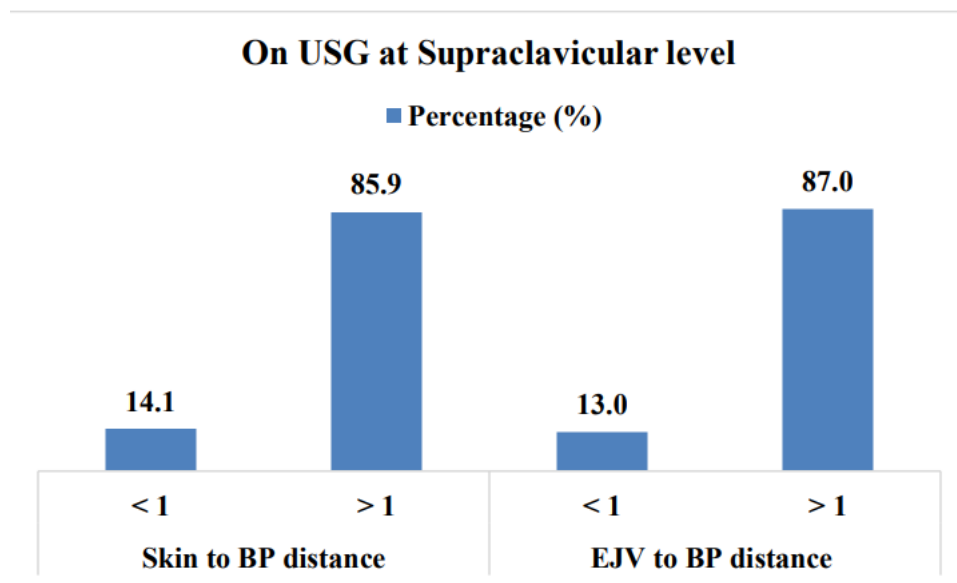


Figure 1: On USG at supraclavicular level

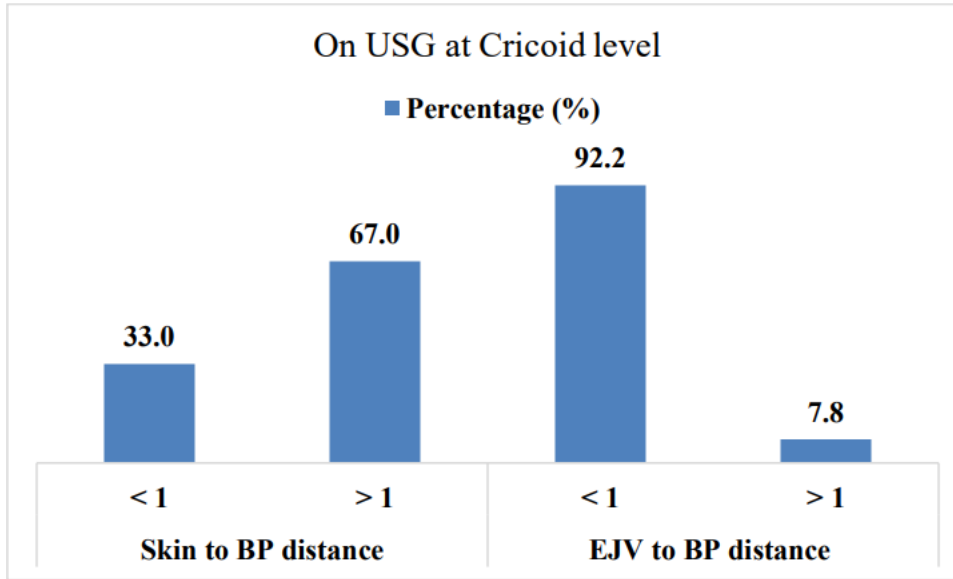


Figure 2: On USG at cricoid level

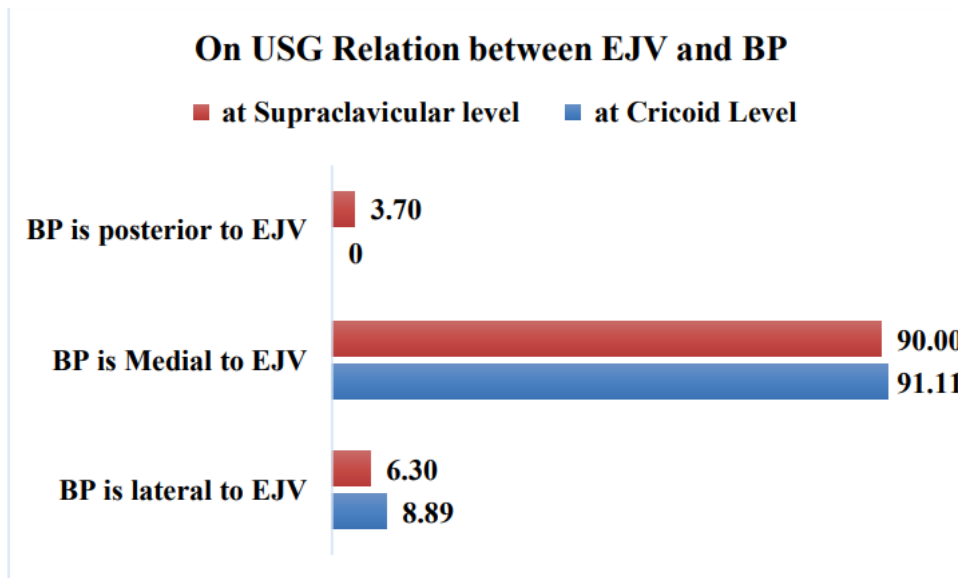


Figure 3: On USG relation between EJV and BP

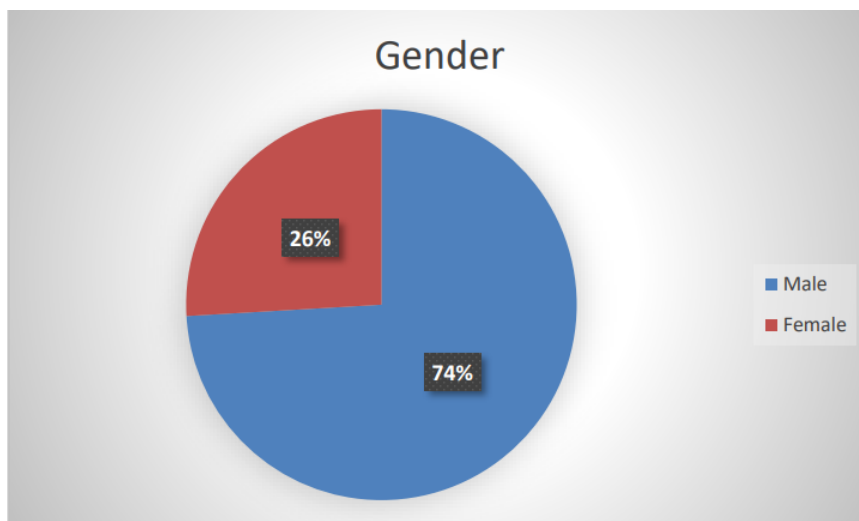


Figure 4: Gender

Results

The mean age of participants was 37.45 ± 13.51 years, with 74% males. In 90% of patients, the brachial plexus was located medial to the external jugular vein at both the cricoid and supraclavicular levels. At the cricoid level, the EJV-to-brachial plexus distance was less than 1 cm in 92.2% of cases. Skin-to-brachial plexus distances at the two levels showed a strong positive correlation ($r = 0.75$), while EJV-to-brachial plexus distances showed no significant correlation.

Discussion

This study illustrates the ultrasound appearance of the brachial plexus in a small group of volunteers. The consistent medial position of the brachial plexus relative to the external jugular vein supports the use of EJV as a reliable surface landmark. These findings are particularly valuable in resource-limited settings where ultrasound guidance is unavailable, reinforcing the importance of sound anatomical knowledge in regional anaesthesia practice.

Conclusion

The study adds important observational data about the anatomical relationship between the brachial plexus and the external jugular vein (EJV) at two commonly accessed levels — the cricoid and supraclavicular levels — using ultrasound. From the observed data, it can be noted that in majority of the patients Brachial plexus lies medial to the External Jugular vein at both cricoid and supra

clavicular level. The external jugular vein maintains a consistent anatomical relationship with the brachial plexus at clinically relevant neck levels. This study supports the continued use of landmark-guided brachial plexus block techniques, especially in developing countries where access to ultrasound is limited.

References

1. Shanthanna H, Rajarathinam M. Regional anesthesia for hand surgeries. *Essentials of Hand Surgery*. InTech; 2018.
2. Brattwall M, Jildenstål P, Stomberg MW, Jakobsson JG. Upper extremity nerve block: an update. *F1000Research*. 2016;5.
3. Koscielniak-Nielsen ZJ. Ultrasound-guided peripheral nerve blocks: benefits and limitations. *Acta Anaesthesiol Scand*. 2008; 52:727–737.
4. Labat G. Brachial plexus block: some details of technique. *Anesth Analg*. 1927; 6:81–82.
5. Benhamou D. Axillary plexus block using multiple nerve stimulation. *Reg Anesth Pain Med*. 2001; 26:495–498.
6. Honnannavar KA, Mudakanagoudar MS. Comparison of conventional and ultrasound-guided supraclavicular brachial plexus block. *Anesth Essays Res*. 2017; 11:467–471.
7. Lewis SR, Price A, Walker KJ, et al. Ultrasound guidance for upper and lower limb blocks. *Cochrane Database Syst Rev*. 2015;9: CD006459.