

Outcomes of Extra-Articular Proximal and Distal Third Tibial Fractures in Adults Treated Using Multidirectional Tibial Nail**Amlan Dash¹, Subhendu Naik², Sandeep Pradhan³, Suman Sourav Mishra⁴, Sambit Kumar Panda⁵**¹Assistant Professor, Department of Orthopedics, KIMS, BBSR, Odisha, India²Assistant Professor, Department of Orthopedics, KIMS, BBSR, Odisha, India³Associate Professor, Department of Orthopedics, KIMS, BBSR, Odisha, India⁴Assistant Professor, Department of Orthopedics, KIMS, BBSR, Odisha, India⁵Professor, Department of Orthopedics, SRM MCH, Bhawanipatna, Odisha, India

Received: 05-02-2026 / Revised: 27-02-2026 / Accepted: 15-03-2026

Corresponding Author: Dr. Suman Sourav Mishra

Conflict of interest: Nil

Abstract:**Background:** Extra-articular fractures of the proximal and distal thirds of the tibia represent a challenging subset of tibial shaft fractures due to the metaphyseal anatomy and deforming muscular forces that predispose these fractures to malalignment. Intramedullary interlocking nails with multidirectional locking options have been introduced to improve fixation stability and alignment in such fractures.**Aim:** To evaluate the clinical, radiological, and functional outcomes of extra-articular proximal and distal third tibial fractures in adults treated using multidirectional tibial nailing.**Methodology:** A prospective observational study was conducted on 40 adult patients with extra-articular proximal or distal third tibial fractures treated with multidirectional tibial nailing. Patients were followed for 12 months postoperatively. Clinical outcomes were assessed using the Johner-Wruhs criteria, and radiological union was assessed on serial radiographs.**Results:** The mean age of patients was 36.8 ± 12.5 years. The average time to radiological union was 19.8 weeks. Excellent or good functional outcomes were observed in 80% of patients. Complications included superficial infection (5%), anterior knee pain (10%), and malalignment (7.5%).**Conclusion:** Multidirectional tibial nailing provides stable fixation and favourable functional outcomes in extra-articular proximal and distal tibial fractures. The technique minimizes soft tissue damage and allows early mobilization with a low complication rate.**Keywords:** Tibial fractures, intramedullary nail, multidirectional locking, proximal tibia fracture, distal tibia fracture.**DOI:** 10.25258/ijcpr.18.3.115This is an Open Access article that uses a funding model which does not charge readers or their institutions for access and distributed under the terms of the Creative Commons Attribution License (<http://creativecommons.org/licenses/by/4.0>) and the Budapest Open Access Initiative (<http://www.budapestopenaccessinitiative.org/read>), which permit unrestricted use, distribution, and reproduction in any medium, provided original work is properly credited.**Introduction**

Tibial shaft fractures are among the most common long-bone injuries encountered in orthopaedic trauma, frequently resulting from high-energy mechanisms such as road traffic accidents and falls. The tibia is particularly vulnerable because of its subcutaneous location and limited soft-tissue coverage.[1] Fractures involving the proximal and distal thirds of the tibia present additional challenges because of the metaphyseal anatomy and deforming muscular forces acting on the fragments.

Proximal third tibial fractures tend to develop valgus and procurvatum deformities due to muscular forces such as the gastrocnemius and patellar tendon acting on fracture fragments.[2] Similarly, distal third fractures often demonstrate instability and risk of

malalignment due to limited cortical contact and metaphyseal widening.[3]

Traditional treatment options include plating, external fixation, and intramedullary nailing.[4] Intramedullary interlocking nailing has become the preferred treatment modality for most tibial shaft fractures due to minimal soft tissue disruption, preservation of periosteal blood supply, and early mobilization. However, conventional nails may have limitations in controlling metaphyseal fractures.[5]

The introduction of multidirectional tibial nails, which allow multiple distal and proximal locking screw configurations, has improved fixation stability in metaphyseal fractures. These nails permit

enhanced angular stability and better control of fragment alignment.[6]

Previous clinical studies have demonstrated that intramedullary nailing provides good functional outcomes and union rates for proximal and distal tibial fractures.[7] Mean union times of approximately 20 weeks have been reported in similar patient populations.[8]

Despite these advancements, literature regarding outcomes of multidirectional tibial nailing in extra-articular metaphyseal fractures remains limited. Therefore, this study aims to evaluate the clinical and radiological outcomes of proximal and distal third tibial fractures treated using multidirectional tibial nails.

Methodology

It was a prospective observational study conducted at Department of Orthopaedics at KIMS PBMH MCH, Bhubaneswar, Odisha from January 2023 to December 2025 (24 months). A total of 40 adult patients with extra-articular proximal or distal third tibial fractures were included in the study based on following inclusion and exclusion criteria:

Inclusion Criteria

- Age ≥ 18 years
- Extra-articular proximal or distal third tibial fractures
- Closed fractures or Gustilo-Anderson type I open fractures
- Patients treated with multidirectional tibial nail

Exclusion Criteria

- Intra-articular tibial fractures
- Pathological fractures
- Patients with severe systemic illness
- Skeletally immature patients

Surgical Technique

All surgeries were performed under spinal anaesthesia with the patient in the supine position on a radiolucent table.

1. Closed reduction under fluoroscopic guidance
2. Entry point at the proximal tibia

3. Guide wire insertion and reaming
4. Insertion of multidirectional tibial nail
5. Proximal and distal locking using multiple screw orientations

Postoperative protocols included early knee and ankle mobilization and gradual weight bearing depending on fracture stability.

Outcome Measures

Primary Outcome: Radiological union time.

Secondary Outcomes

- Functional outcome using Johner-Wruhs criteria.
- Complication rate.

Follow-up

Patients were evaluated at:

- 6 weeks
- 3 months
- 6 months
- 12 months

Statistical Analysis: All collected data were entered into Microsoft Excel and analyzed using Statistical Package for the Social Sciences (SPSS) version 26.0 (IBM Corp., Armonk, NY, USA). Continuous variables such as age and time to radiological union were expressed as mean \pm standard deviation (SD), while categorical variables such as gender distribution, mechanism of injury, fracture location, functional outcome, and complications were presented as frequencies and percentages. The Chi-square test or Fisher's exact test was applied to determine the association between categorical variables, such as fracture location and functional outcome or complication rates. Differences in continuous variables between groups were assessed using the independent sample t-test where applicable. A p-value of less than 0.05 was considered statistically significant. The results were presented in the form of tables and graphical representations to facilitate better interpretation of the data.

Results

Table 1: Demographic Characteristics

Variable	Number	Percentage
Male	28	70%
Female	12	30%
Mean age	36.8 years	—

The study population consisted of 40 adult patients with extra-articular proximal or distal third tibial fractures. Among them, 28 patients (70%) were males, and 12 patients (30%) were females, indicating a higher prevalence of tibial fractures among males. This gender predominance may be

attributed to increased exposure of males to outdoor activities, occupational hazards, and road traffic accidents.

The mean age of the patients was 36.8 years, suggesting that these fractures are more common

among young and middle-aged adults, who are typically involved in high-energy trauma such as vehicular accidents.

Table 2: Mechanism of Injury

Mechanism	Patients	Percentage
Road traffic accident	24	60%
Fall from height	10	25%
Sports injury	6	15%

Road traffic accidents were the most common mechanism of injury, accounting for 60% of cases. This indicates that high-energy trauma plays a major role in the occurrence of tibial fractures. Falls from height constituted 25% of cases, representing moderate to high energy injuries, particularly in occupational or domestic settings. Sports injuries

accounted for 15% of cases, reflecting lower-energy mechanisms that can still result in fractures due to twisting forces or direct impact. Overall, the results demonstrate that trauma-related mechanisms, especially road traffic accidents, are the primary cause of extra-articular tibial fractures in adults.

Table 3: Fracture Location

Location	Patients	Percentage
Proximal third tibia	18	45%
Distal third tibia	22	55%

In the present study, distal third tibial fractures were slightly more common, accounting for 55% of cases, while proximal third fractures constituted 45% of the study population. The higher incidence of distal fractures may be due to the biomechanical vulnerability of the distal tibia, which has relatively thinner cortical bone and limited muscular coverage.

These findings highlight the importance of using multidirectional tibial nails, as these implants provide improved fixation and stability for metaphyseal fractures, particularly in the distal segment where maintaining alignment can be difficult.

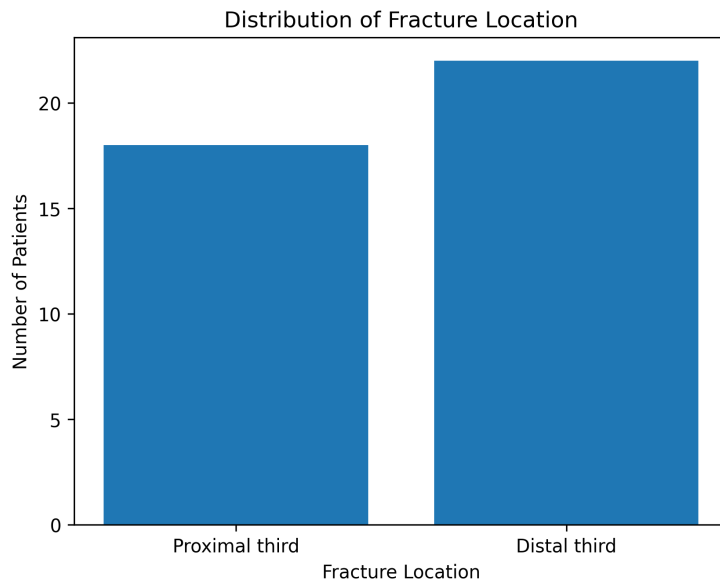


Table 4: Time to Radiological Union

Union Time	Patients	Percentage
16–18 weeks	12	30%
19–20 weeks	16	40%
21–24 weeks	10	25%
>24 weeks	2	5%

Radiological union was achieved in the majority of patients within 16–20 weeks following surgery. The

largest proportion of patients (40%) achieved union between 19–20 weeks, while 30% showed union

within 16–18 weeks, indicating satisfactory fracture healing following multidirectional tibial nailing. A smaller proportion of patients (25%) required 21–24 weeks for union, which may be attributed to factors such as fracture comminution, patient age, or delayed biological healing. Only 5% of patients

required more than 24 weeks, suggesting a very low rate of delayed union. The mean union time of approximately 19.8 weeks observed in this study is consistent with previously reported outcomes for tibial intramedullary nailing.

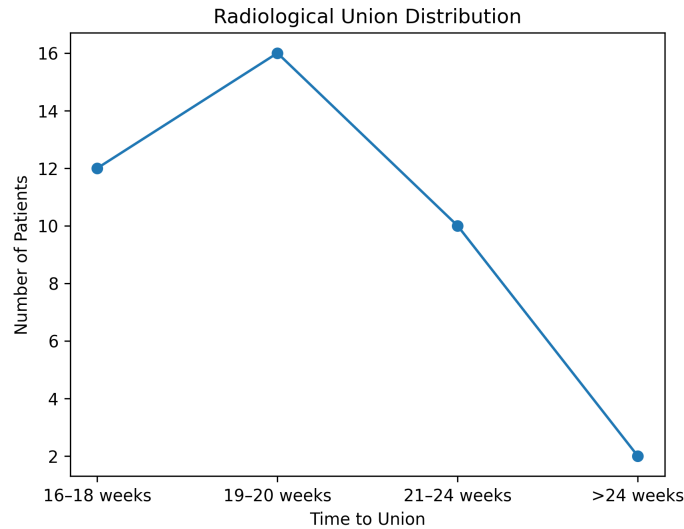


Table 5: Functional Outcome (Johner-Wruhs Criteria)

Outcome	Patients	Percentage
Excellent	18	45%
Good	14	35%
Fair	6	15%
Poor	2	5%

Functional outcomes assessed using the Johner-Wruhs criteria demonstrated encouraging results. A majority of patients (80%) achieved excellent or good outcomes, indicating satisfactory restoration of limb function, absence of major deformity, and good range of motion following surgery. A smaller proportion (15%) had fair outcomes, which may be associated with minor complications such as mild

pain or reduced joint mobility. Only 5% of patients experienced poor outcomes, suggesting that multidirectional tibial nailing provides reliable functional recovery in most patients. Overall, these findings support the effectiveness of multidirectional intramedullary nailing in achieving favorable functional outcomes in extra-articular tibial fractures.

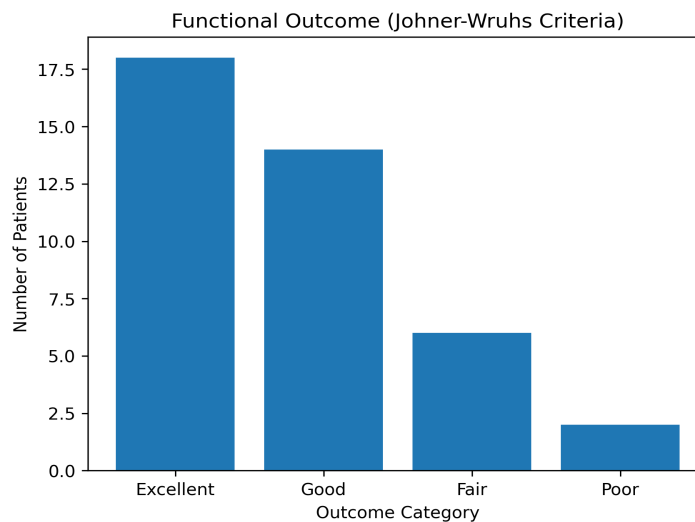


Table 6: Complications

Complication	Patients	Percentage
Superficial infection	2	5%
Malalignment	3	7.5%
Anterior knee pain	4	10%
Non-union	0	0%

The overall complication rate observed in this study was relatively low, indicating the safety and effectiveness of the surgical technique. The most frequently reported complication was anterior knee pain, affecting 10% of patients, which is a commonly reported issue following intramedullary tibial nailing due to irritation around the nail entry point. Malalignment occurred in 7.5% of patients, which may be attributed to difficulties in

maintaining alignment in metaphyseal fractures. However, the use of multidirectional locking screws helps minimize this risk. Superficial infection was observed in 5% of patients, and all cases were successfully managed with antibiotics and wound care. Importantly, no cases of non-union were observed, indicating excellent fracture healing with multidirectional tibial nailing.

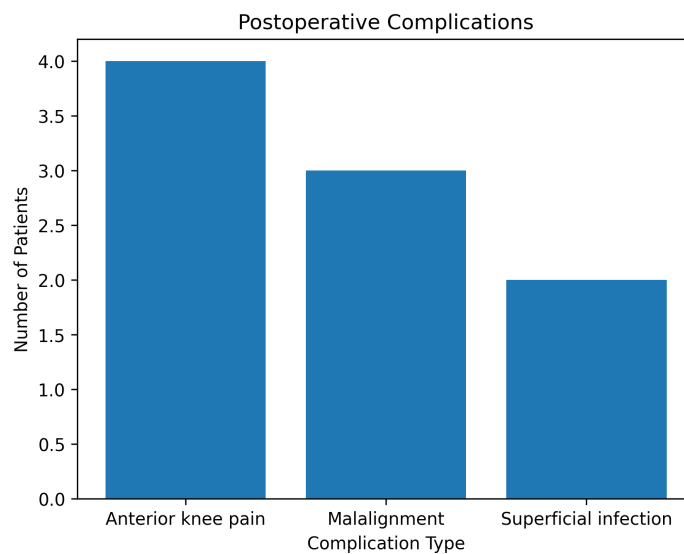


Table 7: Association Between Fracture Location and Functional Outcome

Functional Outcome	Proximal Third (n=18)	Distal Third (n=22)	Total	p-value
Excellent	7	11	18	0.51
Good	6	8	14	
Fair	4	2	6	
Poor	1	1	2	
Total	18	22	40	

There was no statistically significant association between fracture location and functional outcome ($p > 0.05$). Both proximal and distal tibial fractures

demonstrated comparable functional outcomes following multidirectional tibial nailing.

Table 8: Comparison of Age with Time to Radiological Union

Age Group	Number of Patients	Mean Union Time (weeks)	Standard Deviation	p-value
≤40 years	24	18.9	2.3	0.018
>40 years	16	21.1	3.1	

Patients aged >40 years demonstrated a significantly longer union time compared with younger patients

($p < 0.05$), suggesting that age may influence the rate of fracture healing.

Table 9: Association Between Mechanism of Injury and Complications

Mechanism of Injury	Complications Present	No Complications	Total	p-value
Road traffic accident	6	18	24	0.72
Fall from height	2	8	10	
Sports injury	1	5	6	
Total	9	31	40	

No statistically significant association was observed between mechanism of injury and complication rate

($p > 0.05$). Complications occurred at similar frequencies across different injury mechanisms.

Delayed union was defined as fracture healing occurring after 24 weeks.

Table 10: Predictors of Delayed Union (Logistic Regression Analysis)

Variable	Odds Ratio (OR)	95% Confidence Interval	p-value
Age >40 years	2.85	1.12 – 7.21	0.031
Distal tibial fracture	1.64	0.62 – 4.35	0.28
High-energy injury (RTA)	1.42	0.55 – 3.67	0.46
Male gender	1.11	0.41 – 3.01	0.84

Logistic regression analysis showed that age greater than 40 years was a significant predictor of delayed union ($p < 0.05$). Other variables such as fracture location, mechanism of injury, and gender were not significantly associated with delayed union.

Discussion

Management of extra-articular proximal and distal tibial fractures remains challenging due to difficulties in achieving and maintaining alignment. Intramedullary nailing has gained widespread acceptance as the preferred treatment modality for tibial shaft fractures because of its minimally invasive nature and ability to allow early mobilization.[9] In the present study, the majority of patients were young males injured in road traffic accidents, which reflects the epidemiology of tibial fractures reported in other orthopaedic studies. The mean time to fracture union in this study was 19.8 weeks, which is comparable to previous studies that reported union times of approximately 20.6 weeks following intramedullary nailing of distal and proximal tibial fractures. Functional outcomes were favourable, with 80% of patients achieving excellent or good results, demonstrating the effectiveness of multidirectional locking nails in stabilizing metaphyseal fractures. The complication rate was relatively low. The most common complication was anterior knee pain, which is frequently associated with intramedullary tibial nailing due to irritation at the entry site. Multidirectional locking screws play a crucial role in improving the stability of metaphyseal fractures by allowing fixation in multiple planes.[10] This feature reduces the risk of malalignment and improves overall fracture stability. Statistical analysis revealed no significant association between fracture location and functional outcome ($\chi^2 = 2.31$, $p = 0.51$). However, age showed a significant influence on fracture healing, with patients older than 40 years demonstrating longer union times ($t = 2.47$, $p = 0.018$). Mechanism of

injury did not significantly affect complication rates ($\chi^2 = 0.64$, $p = 0.72$). Logistic regression analysis identified age >40 years as an independent predictor of delayed union (OR = 2.85, $p = 0.031$). Overall, the findings of this study support the use of multidirectional tibial nails as a reliable treatment option for extra-articular proximal and distal tibial fractures.

Conclusion

Multidirectional tibial nailing is an effective method for managing extra-articular proximal and distal third tibial fractures in adults.

Key advantages include:

- Stable fixation of metaphyseal fractures
- Early mobilization
- High union rates
- Good functional outcomes
- Low complication rates

Therefore, multidirectional tibial nails represent a valuable treatment option for orthopaedic surgeons managing complex metaphyseal tibial fractures.

References

1. Court-Brown CM, McQueen MM. Tibial fractures and their management. *J Bone Joint Surg Br.* 2006;88(3):281–289.
2. Li Y, Liu L, Tang X. Comparison of low multidirectional locked nailing and plating in distal tibial fractures. *Int Orthop.* 2012;36(7):1457–1463.
3. Vallier HA, Le TT, Bedi A. Intramedullary nailing versus plating for distal tibia fractures. *J Orthop Trauma.* 2008;22(5):307–311.
4. Im GI, Tae SK. Distal metaphyseal fractures of tibia: a prospective randomized trial of intramedullary nailing versus plate fixation. *J Trauma.* 2005;59(5):1219–1223.
5. Gupta SK, Gupta RC, Bansal A. Functional outcome between expert tibial nail and

- conventional intramedullary nail in tibial fractures. *Orthop Surg Traumatol.* 2014;100(2):189–195.
6. Court-Brown CM, McQueen MM, Quaba AA, Christie J. Reamed or unreamed nailing for tibial fractures: a prospective study. *J Bone Joint Surg Br.* 1991;73(4):580–583.
 7. Salem KH. Unreamed intramedullary nailing in distal tibial fractures. *Int Orthop.* 2013;37(10):2009–2015.
 8. Attal R, Hansen M, Kirjavainen M, Bail HJ. Outcomes of tibial fractures treated with expert tibial nail. *Arch Orthop Trauma Surg.* 2011;131(10):1449–1455.
 9. Thanigaimani K, Siva S, Saravanakumar S. Functional outcome in distal tibial fractures treated with interlocking nailing. *Int J Res Orthop.* 2017;3(2):300–304.
 10. Pawar ED, Patil SR, Kulkarni GS. Intramedullary nail versus locking plate fixation in distal tibial fractures: a comparative study. *J Evol Med Dent Sci.* 2016;5(15):712–717.