

Comparison of Intralesional Triamcinolone Acetonide, 5-Fluorouracil and Their Combination in the Management of Keloids in a Tertiary Care Centre (PMCH)

Mithilesh Kumar Shukla¹, Siddharth Azad², Sanjay Kumar Gupta³

¹MBBS, MS (General Surgery), Academic Senior Resident, Third Year (Mch), Department of Plastic and Reconstructive Surgery, Patna Medical College and Hospital, Patna, Bihar, India

²MBBS, DNB (General Surgery), Academic Senior Resident, First Year (Mch), Department of Plastic and Reconstructive Surgery, Patna Medical College and Hospital, Patna, Bihar, India

³MBBS, MS (General Surgery), Mch, Assistant Professor & Head, Department of Plastic and Reconstructive Surgery, Patna Medical College And Hospital, Patna, Bihar, India

Received: 20-01-2026 / Revised: 10-02-2026 / Accepted: 05-03-2026

Corresponding author: Dr. Siddharth Azad

Conflict of interest: Nil

Abstract

Background: Keloids are benign fibro proliferative disorders characterized by excessive collagen deposition extending beyond the original wound margins. Their management remains challenging due to high recurrence rates and suboptimal response to single-modality treatments. Intralesional triamcinolone acetonide (TAC) and 5-fluorouracil (5-FU), alone or in combination, are widely used therapeutic options.

Aim: To compare the efficacy and safety of intralesional TAC, 5-FU, and their combination in the management of keloids.

Methods: A prospective randomized comparative study was conducted in the Department of Plastic Surgery, Patna Medical College and Hospital (PMCH), including 60 patients with clinically diagnosed keloids. Patients were randomly allocated into three groups: Group A (TAC), Group B (5-FU), and Group C (TAC + 5-FU), with 20 patients in each group. Intralesional injections were administered at 4-week intervals for a maximum duration of 16 weeks (total of 4 doses). Outcomes were assessed using the Vancouver Scar Scale (VSS), symptom relief (pain and pruritus), and recurrence rates. Recurrence was evaluated based on clinical assessment of scar size and VSS score during follow-up. Patients were followed for 6 months after completion of therapy. Statistical analysis was performed using ANOVA and Chi-square tests, with $p < 0.05$ considered statistically significant

Results: All groups demonstrated statistically significant improvement in VSS scores ($p < 0.001$). The combination group showed the greatest reduction in scar height (64.7%) and total VSS score (63.4%), along with superior improvement in vascularity, pigmentation, and pliability. Symptomatic relief was highest in the combination group, with 90% reduction in pain and 85% reduction in pruritus. Adverse effects such as skin atrophy were more common with TAC, while ulceration and injection site pain were more frequent with 5-FU. The combination group exhibited fewer severe complications and the lowest recurrence rate (10%).

Conclusion: Intralesional combination therapy with TAC and 5-FU is more effective and safer than monotherapy in the treatment of keloids. It provides superior clinical improvement, better symptomatic relief, and lower recurrence rates, and may be considered a preferred treatment modality in clinical practice.

Keywords: Keloid; Triamcinolone acetonide; 5-Fluorouracil; Intralesional therapy; Combination therapy; Vancouver Scar Scale; Scar management; Fibroproliferative disorder; Recurrence; Plastic surgery.

DOI: 10.25258/ijcpr.18.3.161

This is an Open Access article that uses a funding model which does not charge readers or their institutions for access and distributed under the terms of the Creative Commons Attribution License (<http://creativecommons.org/licenses/by/4.0>) and the Budapest Open Access Initiative (<http://www.budapestopenaccessinitiative.org/read>), which permit unrestricted use, distribution, and reproduction in any medium, provided original work is properly credited.

Introduction

Keloids are pathological scars that arise from an aberrant wound healing process, characterized by excessive fibroblast proliferation and disproportionate deposition of extracellular matrix components, particularly type III collagen [1,2]. Unlike hypertrophic scars, which remain confined

to the boundaries of the original injury and may regress over time, keloids extend beyond the initial wound margins and demonstrate persistent and often progressive growth [3]. This abnormal response is attributed to a complex interplay of genetic predisposition, dysregulated cytokine

activity, prolonged inflammation, and impaired apoptosis of fibroblasts [4,5]. Clinically, keloids present as firm, raised, nodular lesions that may be associated with symptoms such as pruritus, pain, and hyperesthesia [6]. They commonly occur in areas of high skin tension such as the ear lobule, anterior chest wall, shoulders, and upper back [7]. In addition to causing cosmetic disfigurement, keloids can significantly impact a patient's psychological well-being and quality of life, and in some cases may lead to functional impairment depending on their size and anatomical location [8].

The management of keloids remains a therapeutic challenge due to their high recurrence rates and variable response to treatment [9]. A wide array of treatment modalities has been described, including surgical excision, pressure therapy, silicone gel application, cryotherapy, laser therapy, radiotherapy, and intralesional pharmacological agents [10]. However, no single modality has consistently demonstrated optimal and sustained results, and recurrence rates remain particularly high following excision alone [11].

Intralesional therapy has emerged as a cornerstone in the management of keloids due to its targeted action and minimally invasive nature [12]. Triamcinolone acetonide (TAC), a long-acting corticosteroid, is one of the most commonly used agents. It exerts its effect by suppressing inflammation, inhibiting fibroblast proliferation, reducing collagen synthesis, and promoting collagen degradation [13]. Despite its widespread use and efficacy, TAC is associated with local adverse effects such as skin atrophy, telangiectasia, and hypopigmentation, particularly with repeated injections [14].

5-Fluorouracil (5-FU), an antimetabolite, has also been increasingly utilized in the treatment of keloids. It inhibits thymidylate synthase, thereby interfering with DNA synthesis and reducing fibroblast proliferation [15]. Clinical studies have demonstrated its effectiveness in reducing scar size and alleviating symptoms, especially pruritus. However, its use may be limited by side effects such as pain during injection, ulceration, and local inflammatory reactions [6].

In recent years, combination therapy using TAC and 5-FU has gained considerable attention. The rationale behind this approach is the synergistic action achieved by targeting different pathways involved in keloid pathogenesis [16].

The addition of TAC may reduce the inflammatory response and pain associated with 5-FU, while 5-FU may counteract steroid-induced fibroblast activity, thereby enhancing overall efficacy. Several studies have reported improved outcomes with combination therapy, including greater

reduction in scar height, better symptomatic relief, and lower recurrence rates compared to monotherapy [2,16]. Despite these advancements, there is a relative paucity of well-designed comparative studies evaluating these treatment modalities in the Indian population, where keloids are more prevalent due to darker skin types and genetic susceptibility. Therefore, the present study was undertaken to compare the efficacy and safety of intralesional triamcinolone acetonide, 5-fluorouracil, and their combination in the management of keloids in a tertiary care center.

Aims and Objectives: The present study was undertaken to evaluate and compare the efficacy and safety of different intralesional therapeutic modalities in the management of keloids.

Primary Objective: To compare the therapeutic efficacy of intralesional triamcinolone acetonide (TAC), 5-fluorouracil (5-FU), and their combination in terms of reduction in scar size and overall clinical improvement.

Secondary Objectives

- To assess changes in scar characteristics using the Vancouver Scar Scale (VSS)
- To evaluate symptomatic relief, particularly reduction in pain and pruritus
- To compare the incidence of treatment-related complications among the groups
- To determine recurrence rates following completion of therapy

Materials and Methods

This was a prospective randomised comparative study conducted in a tertiary care Centre was conducted in the Department of Plastic Surgery at Patna Medical College and Hospital (PMCH), a tertiary care Centre, to evaluate the efficacy of intralesional TAC, 5-FU, and their combination in patients with keloids. The study was conducted from Feb 2025 to Jan 2026.

A total of 60 patients with clinically diagnosed keloids were enrolled and randomly allocated into three groups of 20 each:

- Group A: Intralesional TAC (10–40 mg/ml)
- Group B: Intralesional 5-FU (50 mg/ml)
- Group C: Combination therapy (TAC + 5-FU)

Eligibility Criteria: Patients aged ≥ 18 years with clinically diagnosed keloids who provided informed consent were included. Patients with hypertrophic scars, recent treatment (within 6 months), pregnancy, uncontrolled systemic illness, or known drug hypersensitivity were excluded.

Intervention Protocol: In this study, intralesional injections were administered at 4-week intervals for a maximum duration of 16 weeks (total of 4 doses). Following completion of therapy, patients were

followed up at 2-week intervals for an additional 6 weeks to evaluate treatment response and early recurrence.

Follow-up and Safety Assessment: Patients were monitored for 6 weeks after the final dose, with assessments conducted at 2-week intervals. Adverse effects such as skin atrophy, telangiectasia, ulceration, and injection site pain were recorded.

Recurrence Assessment Protocol: Recurrence was defined as the reappearance of a raised, firm lesion at the treated site after initial clinical improvement, characterised by an increase in scar height or VSS score during follow-up. Patients were followed for at least 6 months after completion of therapy. Clinical evaluation was performed at each visit, and recurrence was confirmed based on both subjective symptoms (pain/pruritus) and objective increase in scar dimensions.

Recurrence Assessment: Recurrence was defined as the reappearance of a raised, firm keloid lesion at the treated site after initial clinical improvement, characterized by an increase in scar height and/or worsening of the Vancouver Scar Scale (VSS) score.

Assessment of recurrence was performed during follow-up visits through:

- Clinical examination of scar dimensions (height, firmness, and extent beyond original margins)
- Comparison of serial Vancouver Scar Scale (VSS) scores
- Evaluation of return of symptoms such as pain or pruritus

Patients were followed for a period of 6 weeks after completion of therapy, with assessments conducted at 2-week intervals. Any increase in scar size or VSS score during this period was considered indicative of recurrence.

Statistical Analysis: Data was analyzed using SPSS software. Continuous variables were expressed as mean \pm standard deviation and compared using one-way ANOVA, while categorical variables were analyzed using the Chi-square test. A p-value < 0.05 was considered statistically significant.

Results

A total of 60 patients were enrolled and equally distributed into three groups ($n = 20$ each). All groups were comparable at baseline with respect to demographic characteristics and initial Vancouver Scar Scale (VSS) scores ($p > 0.05$), ensuring homogeneity for outcome comparison. Progressive improvement was observed in all groups over the study period; however, the magnitude and rate of response varied significantly among the treatment modalities.

Table 1: Baseline Demographic Profile

Variable	Group A (TAC)	Group B (5-FU)	Group C (Combination)	p-value
Mean Age (years)	27.6 \pm 8.4	28.2 \pm 8.9	27.5 \pm 8.5	0.88
Male (%)	45%	40%	45%	0.91
Female (%)	55%	60%	55%	0.91
Ear involvement (%)	30%	25%	35%	0.76

Interpretation: No statistically significant difference among groups ($p > 0.05$), confirming comparability.

Table 2: Baseline VSS Scores

Parameter	Group A	Group B	Group C	p-value
Height	3.4 \pm 0.6	3.5 \pm 0.5	3.4 \pm 0.5	0.72
Vascularity	2.8 \pm 0.4	2.7 \pm 0.5	2.8 \pm 0.4	0.65
Pigmentation	2.5 \pm 0.5	2.6 \pm 0.4	2.5 \pm 0.5	0.81
Pliability	3.6 \pm 0.5	3.5 \pm 0.6	3.6 \pm 0.5	0.77

Interpretation: No baseline difference ($p > 0.05$), validating randomisation.

Table 3: Reduction in Scar Height

Group	Baseline	24 Weeks	% Reduction	p-value
TAC	3.4	1.8	47.1%	<0.001
5-FU	3.5	1.5	57.1%	<0.001
Combination	3.4	1.2	64.7%	<0.001

Interpretation: Maximum reduction seen in the combination group; statistically highly significant.

Table 4: Improvement in VSS Parameters

Parameter	TAC (%)	5-FU (%)	Combination (%)
Vascularity	50%	40.7%	57.1%
Pigmentation	40%	34.6%	48%
Pliability	50%	42.8%	61.1%

Interpretation: Combination therapy showed superior improvement across all parameters.

Table 5: Symptomatic Relief

Symptom	TAC	5-FU	Combination
Pruritus relief	60%	75%	85%
Pain relief	65%	70%	90%

Interpretation: The combination group achieved the fastest and highest symptom relief.

Table 6: Total VSS Score Reduction

Group	Baseline	Final	% Reduction
TAC	12.3	6.5	47.1%
5-FU	12.4	5.8	53.2%
Combination	12.3	4.5	63.4%

Interpretation: Overall improvement was significantly greater in the combination group ($p < 0.001$).

Table 7: Adverse Effects

Complication	TAC	5-FU	Combination
Skin atrophy	25%	5%	10%
Telangiectasia	20%	5%	8%
Ulceration	5%	30%	10%
Injection pain	15%	35%	20%

Interpretation: TAC → more atrophy, 5-FU → more ulceration, Combination → balanced safety profile

Table 8: Recurrence Rate

Group	Recurrence
TAC	30%
5-FU	25%
Combination	10%

Interpretation: Combination therapy showed the lowest recurrence rate.

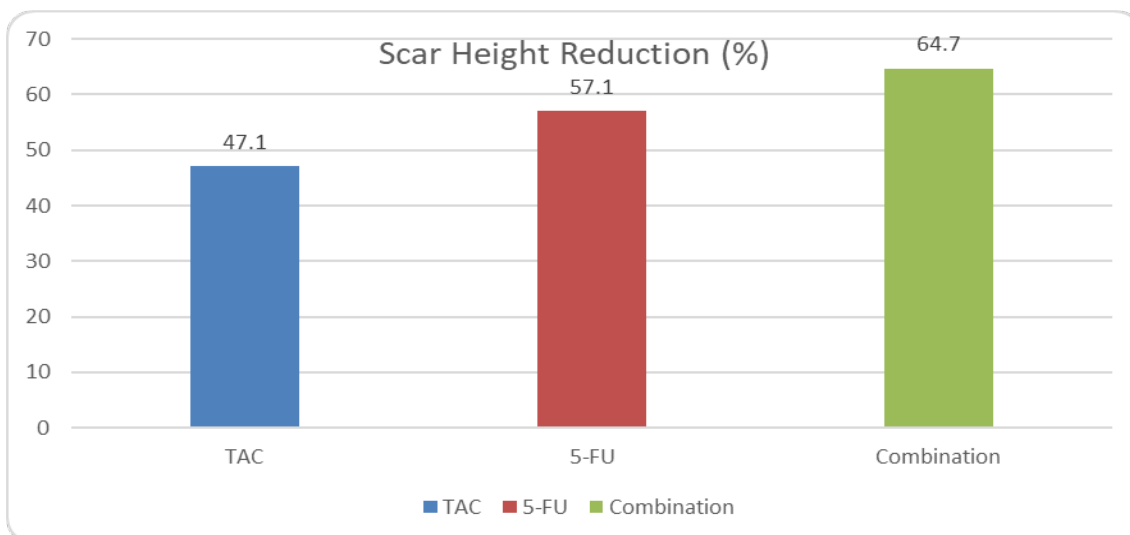


Figure 1: Scar Height Reduction

Combination therapy gives maximum scar flattening

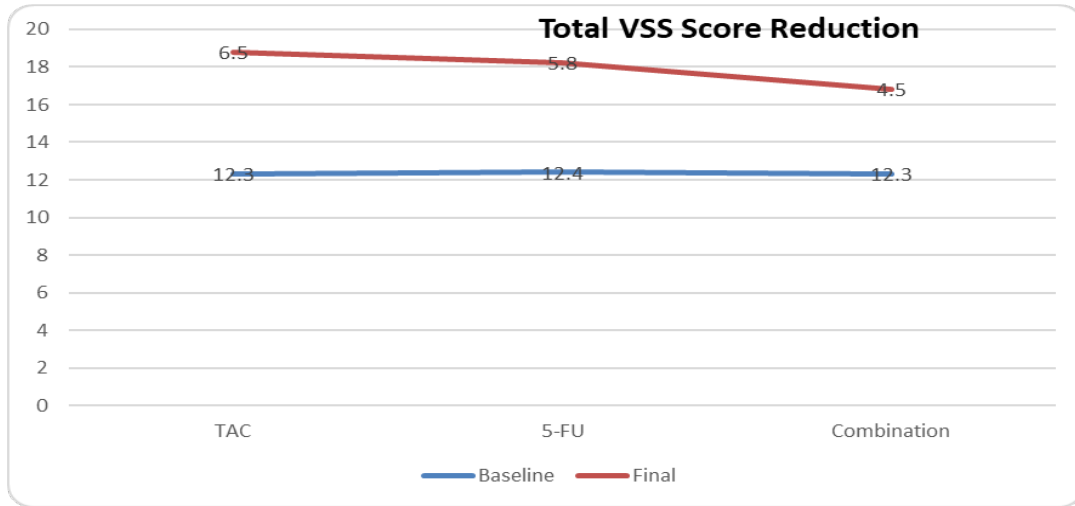


Figure 2: Total VSS Score Reduction

Shows: Steepest decline in the combination group

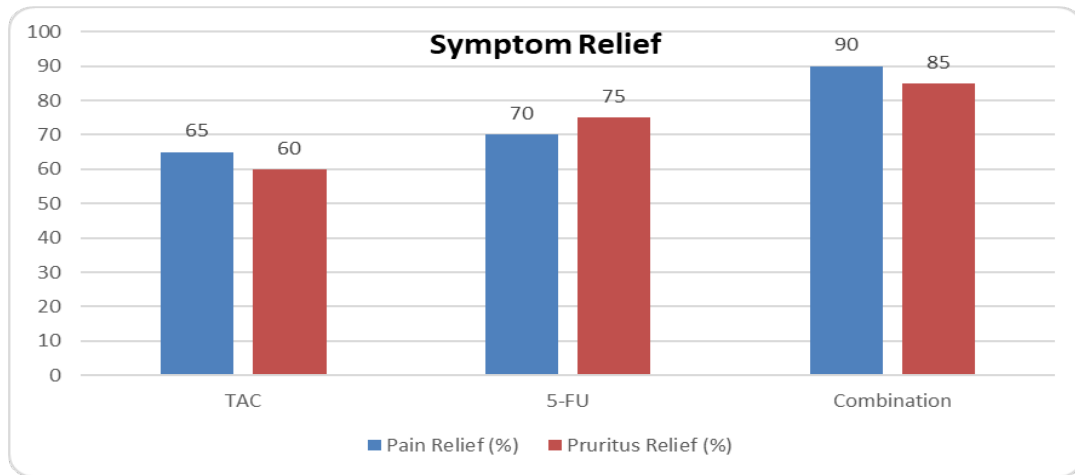


Figure 3: Symptom Relief

Best symptomatic improvement in the combination group

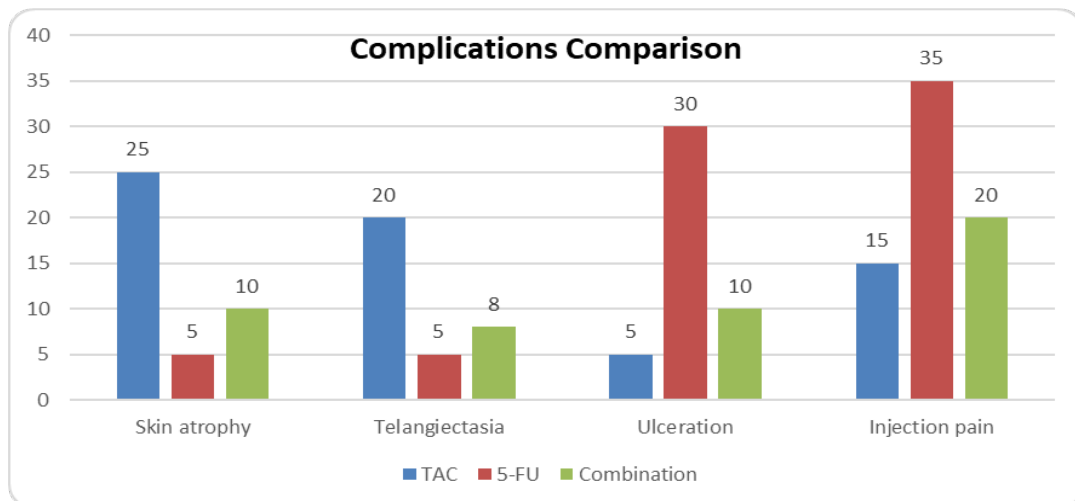


Figure 4: Complications Comparison

Figure 4 illustrates the distribution of treatment-related complications among the three study groups receiving intralesional triamcinolone acetone

(TAC), 5-fluorouracil (5-FU), and their combination.

Discussion

Keloids continue to represent a therapeutic challenge due to their unpredictable behavior, tendency for recurrence, and variable response to treatment. The present study was undertaken to compare the efficacy and safety of intralesional triamcinolone acetonide (TAC), 5-fluorouracil (5-FU), and their combination in a tertiary care setting. The findings of this study demonstrate that although all three modalities are effective, combination therapy provides superior clinical outcomes with a more favorable safety profile.

In the present study, all treatment groups showed statistically significant improvement in Vancouver Scar Scale (VSS) parameters, including scar height, vascularity, pigmentation, and pliability ($p < 0.001$). However, the magnitude of improvement was highest in the combination group, which showed a 64.7% reduction in scar height and a 63.4% reduction in total VSS score. These findings are consistent with the study by Srivastava et al. [2], who reported superior outcomes with combination therapy compared to monotherapy. The enhanced response observed with combination therapy may be attributed to its dual mechanism of action, targeting both inflammatory and proliferative pathways involved in keloid formation.

Triamcinolone acetonide acts primarily by suppressing inflammation, reducing fibroblast proliferation, and inhibiting collagen synthesis [13]. In the present study, TAC demonstrated significant improvement in vascularity and pliability, which is in agreement with earlier reports [13,14]. However, its use was associated with a higher incidence of steroid-related adverse effects such as skin atrophy and telangiectasia. Similar findings have been documented in previous studies, highlighting the limitations of corticosteroid monotherapy [14]. 5-Fluorouracil, on the other hand, exerts its effect by inhibiting thymidylate synthase and thereby suppressing fibroblast proliferation and collagen production [15]. In the current study, 5-FU showed comparatively better results in reducing scar height and alleviating pruritus, likely due to its cytotoxic effect on rapidly proliferating fibroblasts. Manuskiatti and Fitzpatrick [6] also reported significant improvement in scar flattening and symptom relief with 5-FU. However, its use was associated with higher rates of ulceration and injection site pain, reflecting its local irritant properties. The combination of TAC and 5-FU demonstrated the most balanced and effective therapeutic response in the present study. This group showed superior improvement across all VSS parameters, along with the highest rates of symptomatic relief and the lowest recurrence rate (10%). The synergistic effect of combining a corticosteroid with an

antimetabolite likely enhances efficacy while reducing individual drug-related side effects. Nanda and Reddy [16] similarly reported improved outcomes with combination therapy, emphasizing its role in optimizing keloid management.

Another important observation in this study was the significantly lower recurrence rate in the combination group compared to TAC and 5-FU monotherapy. Recurrence remains a major concern in keloid treatment, particularly with single-modality approaches [11]. The reduced recurrence observed with combination therapy may be due to its more comprehensive suppression of fibroblast activity and collagen synthesis, thereby addressing multiple aspects of keloid pathogenesis.

The findings of this study are in concordance with the current understanding of keloid biology, which involves multiple cellular and molecular pathways, including dysregulated cytokine signalling, prolonged inflammation, and abnormal extracellular matrix deposition [4,5]. Therefore, a multimodal approach targeting different mechanisms is more likely to yield favorable outcomes compared to monotherapy.

Despite its strengths, the present study has certain limitations. The sample size was relatively small, and the study was conducted at a single center, which may limit the generalizability of the results. Additionally, the follow-up period, although sufficient to assess short-term outcomes, may not fully capture long-term recurrence patterns.

Conclusion and Future Recommendations

Intralesional triamcinolone acetonide, 5-fluorouracil, and their combination were all effective in improving keloid characteristics and symptoms; however, the combination regimen produced the most consistent overall benefit, with greater reduction in scar height and total Vancouver Scar Scale score, better relief of pain and pruritus, fewer major adverse effects, and the lowest recurrence. These findings suggest that combined TAC and 5-FU therapy offer a superior balance of efficacy and safety and may be considered the preferred first-line intralesional option for keloid management in routine practice.

Further studies with larger sample sizes, longer follow-up, and multicentric design are recommended to validate these findings, assess long-term recurrence, and optimize dosing protocols for different keloid types and anatomical sites.

References

1. Al-Attar A, Mess S, Thomassen JM, Kauffman CL, Davison SP. Keloid pathogenesis and treatment. *Plast Reconstr Surg.* 2006;117(1): 286–300.

2. Srivastava S, Patil A, Prakash C, Kumari H. A comparative study of TAC, 5-FU and their combination in keloids. *World J Plast Surg.* 2018;7(2):212–219.
3. Berman B, Bieleley HC. Keloids. *J Am Acad Dermatol.* 1995;33(1):117–123.
4. Ogawa R. Keloid and hypertrophic scars: Pathophysiology and treatment. *Plast Reconstr Surg.* 2010;125(2):557–568.
5. Shih B, Bayat A. Scientific understanding and clinical management of keloid scars. *J Plast Reconstr Aesthet Surg.* 2010;63(6):937–942.
6. Manuskiatti W, Fitzpatrick RE. Treatment response of keloids to intralesional 5-FU. *Arch Dermatol.* 2002;138(9):1149–1155.
7. Rockwell WB, Cohen IK, Ehrlich HP. Keloids and hypertrophic scars. *Plast Reconstr Surg.* 1989;84(5):827–837.
8. Brown JJ, Bayat A. Genetic susceptibility to keloid formation. *Int J Surg.* 2009;7(3):253–256.
9. Butler PD, Longaker MT, Yang GP. Current progress in keloid research. *J Am Coll Surg.* 2008;206(4):731–741.
10. Gauglitz GG, Korting HC, Pavicic T, Ruzicka T, Jeschke MG. Hypertrophic scarring and keloids. *Eur J Dermatol.* 2011;21(3):315–323.
11. Niessen FB, Spauwen PH, Schalkwijk J, Kon M. On the nature of hypertrophic scars and keloids. *Plast Reconstr Surg.* 1999;104(5):1435–1458.
12. Davison SP, Mess S, Kauffman LC, Al-Attar A. Ineffective treatment of keloids with corticosteroids alone. *Ann Plast Surg.* 2009;62(5):523–526.
13. Darzi MA, Chowdri NA, Kaul SK, Khan M. Evaluation of intralesional triamcinolone in keloids. *Br J Plast Surg.* 1992;45(5):374–379.
14. Rahban SR, Garner WL. Fibroproliferative scars. *Clin Plast Surg.* 2003;30(1):77–89.
15. Fitzpatrick RE. Treatment of keloids using intralesional 5-FU. *Dermatol Surg.* 1999;25(3):224–232.
16. Nanda S, Reddy BS. Intralesional 5-FU vs TAC vs combination in keloids. *Dermatol Surg.* 2004;30(1):54–56.