

**Study on Accuracy of Different Cytoarchitectural Features in the Diagnosis of Papillary Thyroid Carcinoma by Fine Needle Aspiration**Bikash Kumar Singh<sup>1</sup>, Kumar Abi<sup>2</sup>, Jitendra Kumar Sinha<sup>3</sup><sup>1</sup>Associate Professor, Department of Pathology, Lord Buddha Koshi Medical College and Hospital, Saharsa, Bihar, India<sup>2</sup>Senior Resident, Department of Pathology, Lord Buddha Koshi Medical College and Hospital, Saharsa, Bihar, India<sup>3</sup>Assistant Professor, Department of Pathology, Lord Buddha Koshi Medical College and Hospital, Saharsa, Bihar, India

Received: 01-02-2026 / Revised: 15-02-2026 / Accepted: 21-02-2026

Corresponding author: Dr. Kumar Abi

Conflict of interest: Nil

**Abstract****Background:** In a sufficient sample, the diagnostic accuracy of fine needle aspiration (FNA) for papillary thyroid cancer (PTC) is approximately 90%. Reliance on a single or small number of cytologic features can result in a misdiagnosis if the relative importance of each feature is not understood. Our goal was to ascertain the value of both individual and the best combination of cytologic characteristics for PTC diagnosis.**Methods:** The files contained H&E stained FNA smears of fifty cases each of successive histologically confirmed PTC and benign thyroid cases (controls), reported over a three-year period. Blind to the final diagnosis, 31 architectural, cytological, and background characteristics were evaluated and compared between the two groups. Chi-square and odds ratios were used to determine each parameter's statistical significance ( $p < 0.05$ ), and ROC curves were used to evaluate the quality of the combinations.**Results:** Twenty features were found to be statistically significant. Fourteen highly significant ( $p < 0.000$ ) features included flat syncytial sheets, anatomical borders, true papillae, cellular swirls, individually dispersed cells with eosinophilic cytoplasm, anisonucleosis, elongated oval nuclei, powdery chromatin, nuclear outline irregularity, thickened nuclear membranes, crescent shaped nuclei, intranuclear inclusions, histocytoid cells and soap bubble cytoplasmic vacuolation. The six statistically significant features ( $p < 0.05$ ) included micro-acinar structures, cellular crowding, nuclear overlapping, nuclear grooves, squamoid cells and bubble gum colloid. The control group also showed some of these single cytologic features. All the combinations of  $\geq 4$  features had a statistical significance of  $p = 0.000$  and specificity and PPV of 100% with ROC showing excellent results.**Conclusion:** Using correct combination of cytologic features will increase accuracy of FNA diagnosis of PTC.**Keywords:** Fine Needle Aspiration, Papillary Thyroid Carcinoma, Cytologic.**DOI:** 10.25258/ijcpr.18.3.237

This is an Open Access article that uses a funding model which does not charge readers or their institutions for access and distributed under the terms of the Creative Commons Attribution License (<http://creativecommons.org/licenses/by/4.0>) and the Budapest Open Access Initiative (<http://www.budapestopenaccessinitiative.org/read>), which permit unrestricted use, distribution, and reproduction in any medium, provided original work is properly credited.

**Introduction**

Roughly 1% of all cancers are thyroid carcinomas. It is the most prevalent endocrine cancer, with papillary thyroid carcinoma (PTC) accounting for 90% of occurrences in children and 80% of cases in adults [1-3]. The disease has a strong female predilection. In India and neighboring regions, it is significantly more common in females than in males, with a reported ratio typically between 3–4:1. According to recent cancer registry data in India, thyroid cancer is one of the leading sites of cancer for women in the 30–39 age group. [4]

Fine needle aspiration cytology (FNAC) is a reliable first-line diagnostic technique for thyroid

nodules.[5–8] If the sample is sufficient, the diagnosis accuracy of PTC by FNA is over 90%.[8]

True papillary tissue fragments and nuclear characteristics such as dusty pale enlarged nuclei, fine dusty powdery chromatin, chromatic ridge/bar (nuclear single or multiple micro and macronucleoli), and intranuclear cytoplasmic pseudo inclusions with dense stringy "bubble-gum" colloid in the background are the recognized criteria for cytodiagnosis of PTC.[9]

However, none of the previously mentioned architectural, cytomorphological, and background characteristics are specific to or indicative of PTC because they can be found in a number of other

thyroid lesions, both neoplastic and non-neoplastic, including hyperplastic nodules, papillary hyperplasia, thyroiditis, Hurthle cell neoplasm, and hyalinizing trabecular adenoma.[9, 10] Since PTC and lymphocytic thyroiditis share many characteristics, such as nuclear grooves and intranuclear inclusions, it is difficult to differentiate reactive nuclear alterations linked to PTC from lymphocytic thyroiditis.[11]

Unless they coexist and are rather common, none of these characteristics are diagnostic on their own.[8,9]

The cytopathologist's overemphasis on a single cytological characteristic is the most frequent error in PTC diagnosis.[9]

Therefore, untrained cytopathologists may find it challenging to make an unambiguous diagnosis of PTCFNA when only a few diagnostic signs are present or if the symptoms are detected infrequently. Additionally, some PTC variants, such as the follicular variant, may have relatively few nuclear characteristics that are only found in a small number of foci.[12]

Determining which individual cytoarchitectural traits are most trustworthy for PTC diagnosis as well as which feature combination is more helpful for FNA diagnosis of PTC will therefore be beneficial.

### Materials and Methods

This Descriptive cross sectional study with an analytical component. Fine needle aspiration smears from 50 consecutive histologically confirmed PTC cases, reported at the Departments of Pathology, Lord Buddha Koshi Medical College and Hospital, Saharsa, Bihar from August 2025 to January 2026 were retrieved from the archives. FNAs from 50 consecutive histologically confirmed cases of nodular goiter, chronic autoimmune thyroiditis or hyperplastic nodules reported at the same setting during period were also retrieved to be used as controls.

Haematoxylin and eosin (H and E) stained slides of each case were selected consecutively and the slides showing extensive drying artifact and slides which were broken or poorly staining were excluded.

The presence or absence of each cytoarchitectural feature was recorded and entered in a Microsoft excel sheet. The final data was then analyzed by SSPS software (version 23).

The sensitivity, specificity, positive and negative predictive values (PPV and NPV) of the selected parameters were calculated. The histological diagnosis as the gold standard. The chi-square test and odds ratio were used to determine the statistical

significance ( $p < 0.05$ ) of each cytological parameter.

### Results

A total of 100 FNAs were evaluated. In the papillary group 31 cases had been diagnosed as PTC (Thy 5, Bethesda 6) whilst 19 cases had been diagnosed suspicious for PTC (Thy4, Bethesda 5). All FNA cases diagnosed as diagnostic of and suspicious for PTC were confirmed as PTC by histology. In the control group, 2 cases had been diagnosed as follicular proliferation (Thy 3). Rest of the cases were diagnosed as benign (Thy2, Bethesda 2) of which 28 cases had been diagnosed as colloid storing goiter and 20 cases as chronic autoimmune thyroiditis on cytological evaluation.

The two cases diagnosed as follicular proliferation were confirmed as hyperplastic nodules by histology. The remaining 48 cases were confirmed histologically as colloid storing goiter (28 cases) or chronic autoimmune thyroiditis (20 cases).

According to the statistical analysis, the highly statistically significant ( $p = 0.000$ ) cytoarchitectural features are flat syncytial sheets, anatomical borders, true papillae, cellular swirls, individually dispersed cells with eosinophilic cytoplasm, anisonucleosis, elongated oval nuclei, powdery chromatin, nuclear outline irregularity, thickened nuclear membranes, crescent shaped collapsed nuclei, intranuclear inclusions, histocytoid cells and cells with soap bubble cytoplasmic vacuolation. Most of these features also had high sensitivity, specificity, PPV and NPV ( $> 70\%$ ). However, features like true papillae, cellular swirls, histocytoid cells and cells with soap bubble cytoplasmic vacuolation had low sensitivity but very high specificity whereas features like intranuclear inclusions, anisonucleosis and elongated nuclei had high sensitivity but slightly low specificity.

The other architectural, cytological and background features which were found to be statistically significant ( $p < 0.05$ ) were microacinar structures away from the sheets, cellular crowding with nuclear overlapping, nuclear grooves, squamoid cells and bubble gum colloid. All these features except the latter two had high sensitivity and low specificity.

Squamoid cells and bubble gum colloid were more specific (100% and 78% respectively) than sensitive (12% and 48% respectively). Presence of plasma cells admixed with cell clusters also showed statistical significance ( $p < 0.05$ ) in this study with a sensitivity of 72% and a specificity of 50%. Rest of the features (cellularity, marginated and non-marginated nucleoli, mitosis, multinucleated giant cells, hurtheloid cells, cyst macrophages, lymphocytes and neutrophils within

the aspirate) were statistically insignificant ( $p > 0.05$ ). Although psammoma bodies which are generally considered to be significant, failed to prove so in our study. The statistical studies could not be applied on two features; individually dispersed bare nuclei and columnar cells, as two of the four values were less than five. It was not possible to analyze individual cytoarchitectural parameters by ROC since the variables were categorical and not continuous.

All the combinations of more than two features were found to be statistically highly significant in differentiating between PTC and other thyroid pathologies with a statistical significance of  $p = 0.000$  with specificity and PPV of 100% in all five combinations. Combination 3 which included flat syncytial sheets, true papillae, individually dispersed cells with eosinophilic cytoplasm, nuclear outline irregularity, thickened nuclear membranes and showed 100% sensitivity and specificity.

Our study also showed that all the combinations of more than two features to be in the first category of 0.9-1 so the test quality indicated as being excellent. All the five combinations are more or less similar with the highest area under the curve to be for combination 2 which is 0.936.

The ROC for combinations of only two features completely failed the test thus highlighting the

importance of having more than two cytological features for the combinations to be significant. Although the single cytological parameters could not be compared to the combination parameters in the ROC, it was shown that certain statistically significant single cytological parameters were present in some proportion in the non-papillary group as well. However, when more than two statistically significant cytoarchitectural features were combined, all had 100% specificity and none were present in the non-papillary group as a total. This signifies the use of combination of cytoarchitectural features in the diagnosis of PTC on FNA.

As indicated in Table 5, many individual cytological features with 100% specificity and 100% PPV {except for individually dispersed cells with eosinophilic cytoplasm (72%) and true papillae (56%)} had sensitivity of 50% or less. This highlights the problem in cytological diagnosis of PTC, where individual cytological features with a high specificity and positive predictive value may not always be reliable due to low sensitivity. Nuclear outline irregularity in the category of 90% specificity and 90% PPV also had a high sensitivity (88%). In the category of 80-90% specificity and 80% PPV, most of the features had a high sensitivity except for the mitoses (12%).

**Table 1: Calculating sensitivity, specificity, PPV, NPV and significance of combinations of statistically important selected cytoarchitectural features**

Characteristic	Papillary (=50)	Non- papillary (=50)	Sensitivity %	Specificit y%	PPV %	NPV %	Significance
<b>Combination 1</b>							
Present	20	0	40%	100%	100%	62.5%	Fisher's exact test $p = 0.000$
Absent	30	50	44%	100%	100%	64%	
<b>Combination 2</b>							
Present	22	0	100%	100%	100%	66.6%	Fisher's exact test $p = 0.000$
Absent	28	50	80%	100%	100%	83.3%	
<b>Combination 3</b>							
Present	25	0	18%	100%	100%	54.9%	Fisher's exact test $p = 0.000$
Absent	25	50	40%	100%	100%	62.5%	
<b>Combination 4</b>							
Present	40	0	44%	100%	100%	64%	Fisher's exact test $p = 0.000$
Absent	10	50	100%	100%	100%	66.6%	
<b>Combination 5</b>							
Present	41	0	80%	100%	100%	83.3%	Fisher's exact test $p = 0.000$
Absent	09	50	18%	100%	100%	54.9%	

**Table 2: ROC of the combinations: area under the curve**

Combination	Area	Standard error <sup>a</sup>	Asymptotic significance <sup>b</sup>	Asymptotic 95% Lower bound	Confidence interval Upper bound
1	0.924	0.032	0.000	0.862	0.987
2	0.936	0.028	0.000	0.861	0.990
3	0.932	0.033	0.000	0.869	0.996
4	0.933	0.031	0.000	0.873	0.993
5	0.917	0.033	0.000	0.853	0.982
6	0.182	–	–	–	–
7	0.188	–	–	–	–
8	0.268	–	–	–	–
9	0.165	–	–	–	–
10	0.301	–	–	–	–

The test result variable (s): Total 2 has at least one tie between the positive actual state group and the negative actual state group. Statistics may be biased. <sup>a</sup>Under the nonparametric assumption, <sup>b</sup>Null hypothesis: true area = 0.5

**Table 3: Categorization of cytologic features according to the specificity and the PPV**

100% Specificity and 100% PPV Characteristics	Sensitivity%
Individually dispersed cells with eosinophilic cytoplasm	72
True Papillae	56
Histiocytoid cells	50
Cells with septate vacuoles in the cytoplasm	28
Meta plastic squamous cells	12
Psammoma bodies	10
Columnar cells	6
90% Specificity and 90% PPV Characteristics	Sensitivity%
Nuclear outline Irregularity	88
80-90% Specificity and 80% PPV Characteristics	Sensitivity%
Fine powdery chromatin	94
Thickened nuclear membranes	90
Anatomical borders	74
Cellular swirls	58

### Discussion

Our study's primary goal was to ascertain the utility of individual cytoarchitectural features in FNA smears for the diagnosis of PTC and its variations. Additionally, we sought to identify the most beneficial cytoarchitectural features as well as the most dependable combination of cytoarchitectural features for the diagnosis of PTC in cytology smears.

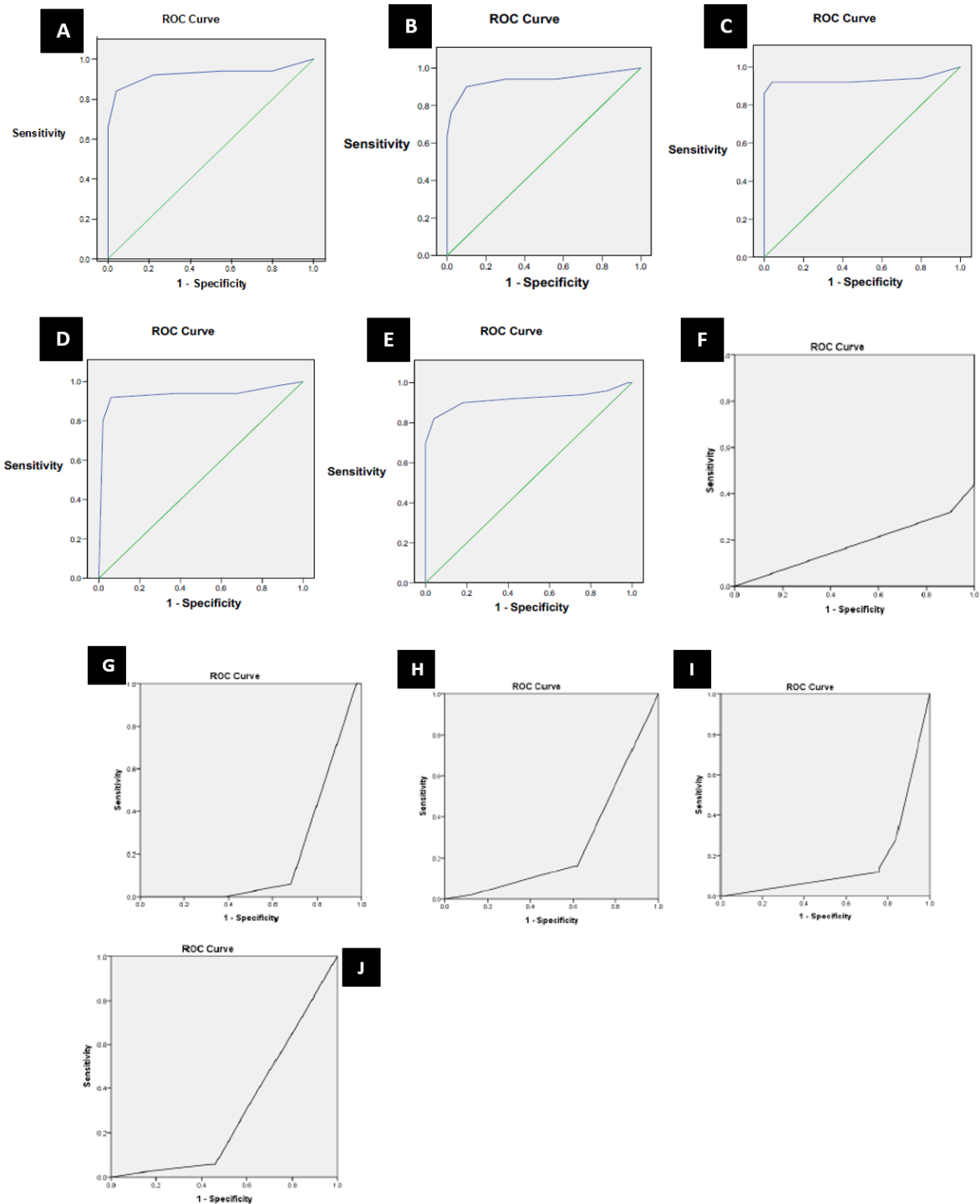
This was justified by the fact that, despite the well-defined cytological characteristics reported in multiple studies, PTC diagnosis on cytology is frequently fairly challenging, and there is currently no international standard for the cytological diagnosis of PTC.

When compared to the control group, twenty of the thirty-one cytological markers examined in our study were found to be statistically significant in the diagnosis of PTC. Six traits had a significance of  $p < 0.05$ , while 14 features had a significance of  $p = 0.000$ .

Flat syncytial sheets, anatomical borders, true papillae, cellular swirls, individual cells with eosinophilic cytoplasm, anisonucleosis, elongated oval nuclei, fine powdery chromatin, irregular nuclear outline, thickened nuclear membranes, crescent-shaped collapsed nuclei with or without nuclear molding, INCI, histiocytoid cells, and cells with septate vacuolation were among the fourteen characteristics.

The aforementioned cytological results and the histologic diagnosis of PTC were significantly correlated.

Nevertheless, all five combinations of more than four features had 100% specificity when the statistically relevant cytoarchitectural features were pooled, and none of the traits were present in the non-papillary group. Combining more than four cytological traits was more important than combining two features, according to the ROC.



**Fig. 1: ROC curves of the combination; A-J: Combination 1-10**

**Conclusion**

This study highlights how crucial it is to diagnose PTC on FNA by combining a greater number of cytoarchitectural markers. In order to create a score system that may be used to categorize the FNA as diagnostic for PTC, it is also advised to involve a bigger study group.

**References**

1. Yuan S, Maoxin WU, Burstein DE, Szporn AH. A novel diagnostic standard for papillary thyroid cancer is cellular swirls in fine needle aspirates. 2006; 19(11):1470–3. Mod Pathol.
2. Jain A, Alam K, Maheshwari V, Rabindranath D, Khan AA, Khan R. Cytological characteristics in the early detection of thyroid

- papillary carcinoma in instances that are not clinically obvious. 2015 *Ann Pathol Lab Med*. 2(3):94–7.
3. Fine needle aspiration cytology by Sidaway MK, Ali SZ. First edition, pp. 37–70, Philadelphia: Elsevier, 2007.
  4. The peak incidence in adults is between 35-40 years and is commoner in females in the ratio of 3-4:1. India. *Int J Sci Study*. 2015;3(2):95-100.
  5. Rajesh SP, Rashmi KP, Andola SK, Viral L, Mallikarjun B. Efficacy of fine needle aspiration cytology in diagnosis of lesions of thyroid and histopathological correlation. *J Pub Health Med res*. 2013;1(1):18–23.
  6. Tabaqchali MA, Hanson JW, Johnson SJ, Wadehra V, Lennard TWJ, Proud G. Thyroid aspiration cytology in Newcastle: a six-year cytology/histology correlation study. *Ann R CollSurg Engl*. 2000;82(3):149–55.
  7. Hisham ETS, Abdelelah ME. The diagnostic value of fine needle aspiration cytology of thyroid nodules. *Kasr EL Aini J Surg*. 2006;7(1):69–77.
  8. Mittal A, Ahmad F, Dutta S, Nizammudin S, Awasthi S, Kumar A. Use and accuracy of fine needle aspiration cytology in thyroid lesion: Our Experience in a tertiary teaching hospital in North India. *Int J Sci Study*. 2015;3(2):95–100.
  9. Pandey P, Dixit A, Mahajan NC. Fine needle aspiration of the thyroid: A cytohistologic correlation with critical evaluation of discordant cases. *Thyroid Res Pract*. 2012; 9:32–9.
  10. Das DK, Sharma PN. Diagnosis of papillary thyroid carcinoma in fine needle aspiration smears. *ActaCytologica*. 2009;53(5):497–506.
  11. Baloch ZW, Livolsi VA. Cytologic and architectural mimics of papillary thyroid carcinoma. *Am J Clin Pathol*. 2006;125(suppl 1):135–44.
  12. Renshaw AA. Focal features of papillary carcinoma of the thyroid in fine needle aspiration material are strongly associated with papillary carcinoma at resection. *Am J Clin Pathol*. 2001;118(2):208–10.