

Pterygium Excision with Thin Conjunctivo-Limbal Strip Autograft: A Novel Study

Suman Bhartiya¹, Prachi Shukla², Yashika Sinha³, Shweta Singh⁴

¹Professor & Head, Department of Ophthalmology, Muzaffarnagar Medical College and Hospital Muzaffarnagar, Uttar Pradesh

²Professor, Department of Ophthalmology, Muzaffarnagar Medical College and Hospital Muzaffarnagar, Uttar Pradesh

³Associate Professor, Department of Ophthalmology, Muzaffarnagar Medical College and Hospital Muzaffarnagar, Uttar Pradesh

⁴Assistant Professor, Department of Ophthalmology, Muzaffarnagar Medical College and Hospital Muzaffarnagar, Uttar Pradesh

Received: 06-02-2026 / Revised: 16-03-2026 / Accepted: 10-04-2026

Corresponding Author: Dr. Suman Bhartiya

Conflict of interest: Nil

Abstract

Background: The aim of this study was to assess the efficacy of novel surgical technique of grafting thin conjunctivo-limbal strip autograft with autologous serum without using any glue or sutures after pterygium excision.

Material and Methods: This is a two years prospective hospital-based interventional study conducted in Ophthalmology department of a Medical College situated in western UP. Patients provided informed written consent, and the institute's ethical committee approved the study. Total 268 eyes from 244 patients having primary pterygium of any grade were included in the study.

Result: Results obtained from analysis of 268 eyes having primary pterygium treated with thin conjunctivo-limbal strip autograft using autologous serum as tissues adhesive. The mean age was 47.5 ± 8.5 years (30–70years). The study included 143 males and 101 females. The average duration of follow-up was 6 months. The average operating time was 10 ± 3 minutes. Recurrence was seen in one patient. This technique minimises the overall surgical time and reduces the destruction of conjunctival tissue.

Conclusion: Sutureless, glue free, thin, Conjunctivo-limbal strip autograft (CLSAG) using autologous blood is safe over other alternative procedures showing early healing and minimal destruction of conjunctival tissue. So, this technique may be considered as a viable alternative in pterygium surgery having all the benefits of other methods to prevent recurrence and without any drawback.

DOI: 10.25258/ijcpr.18.4.162

This is an Open Access article that uses a funding model which does not charge readers or their institutions for access and distributed under the terms of the Creative Commons Attribution License (<http://creativecommons.org/licenses/by/4.0>) and the Budapest Open Access Initiative (<http://www.budapestopenaccessinitiative.org/read>), which permit unrestricted use, distribution, and reproduction in any medium, provided original work is properly credited.

Introduction

Pterygium was first described in 1000 BC by Sushruta. Pterygium derives its etymology from the Greek word pteros which means wing. Pterygium is a wing shaped, fibrovascular overgrowth arising from sub-conjunctival tissue extending across the limbus onto the cornea with preference on the nasal side. It destroys Bowman's membrane and superficial layers of the stroma, covered by the conjunctival tissue. In India, the prevalence ranges from 9.5% to 13%, having more predilections for rural areas [1].

Previous studies state that pterygium is associated with multiple factors like viral infections, immunological causes, hereditary factors, aseptic inflammation and environmental irritations. Recently increased levels of transcription factors

cAMP response, element binding protein, cytochrome P450 1A1 protein, phospholipase D and aquaporin-1 and 3 have been discovered as risk factors for pterygium development [2]. Various aetiologies have been attributed to its cause, but mainly the exposure to ultra-violet rays based on epidemiological evidence is the common and important cause for the occurrence of pterygium [3]. Matrix Metalloproteinase and MMP tissue inhibitors at the advancing edge of pterygium may also be responsible for inflammation, tissue remodelling, and Bowman's layer destruction [4].

Indications for surgery include foreign body sensation, congestion, cosmetic problems or visual defects ranging from irregular astigmatism to total obstruction of the visual axis. Earlier used bare

sclera pterygium surgery is often compromised by post-operative recurrences, which is the leading cause of surgical failure in significant number of cases [5]. Although recurrence could occur even after many years, most recurrences happen in the first 3–6 months postoperatively [6]. Various adjuvants like mitomycin C, 5 fluorouracil, beta irradiation, anti-vascular endothelial growth factor (anti-VEGF) and covering the bare sclera using conjunctival autograft, amniotic membrane placement, conjunctival transpositional flap have been proposed to reduce postoperative pterygium recurrence [7]. Conjunctival autograft after pterygium excision is considered as the gold standard in the treatment of primary pterygium [8]. Conjunctival autograft transplantation is an effective method for preventing recurrence as it replenishes the limbal stem cells and frames a barrier for regrowth. Harvesting superior bulbar conjunctiva is not recommended in patients who had previously undergone trabeculectomy or tube shunt surgery or who may require such surgery in the future. Large size CAG is required for eyes having very bulky or double-head pterygium [9]. Retrieving a large conjunctival graft to cover two bare scleral areas in bulky double head pterygium may cause larger conjunctival deprived area affecting the surface milieu, redness and discomfort [10]. In this study, we have evaluated the result of grafting a thin strip of conjunctivo-limbal autograft (CLSAG) harvested from superior or supero-temporal quadrant and secured with autologous serum on bare sclera after the pterygium excision. Long-term outcomes were documented. The purpose of this technique was to make the procedure cost effective, minimize the overall surgical time, reduce the destruction of conjunctival tissue at donor site, and promote early healing and finally to minimise the recurrence rate.

Material and Methods

This is a two years hospital-based prospective interventional study, conducted in ophthalmology department of tertiary care Medical College of north India. Informed written consent was taken from all the patients and the ethical committee of institution approved the study. Total 268 eyes from 244 patients having primary pterygium of any grade were included in the study. Pre-operative data like age, sex, visual acuity, IOP, Slit lamp examination to document the grade, thickening and vascularity of pterygium was done. Grading was done according to the corneal involvement as:

- Grade 1: crossing the limbus
- Grade 2: midway between the limbus and pupil
- Grade 3: reaching up to the pupillary margin
- Grade 4: crossing the pupillary margin

Both males and females between the age group of 30-70 years having primary pterygium of any grade

were included in the study. Patients having recurrent pterygium, any other ocular surface disorder and those not willing to give consent for regular follow up were excluded from the study. Written and informed consent was taken from all the patients prior to participating in the study. All the surgeries were performed by the same surgeon. Post-operatively visual acuity was done and detailed slit lamp examination was performed to assess the cornea, graft adherence, condition of the harvested site. Photographs were taken for record. Any complication if seen was recorded at each follow up.

Surgical Technique: All the patients were operated under peri-bulbar anaesthesia. After painting and draping, a wire speculum was placed to widen the palpebral aperture. The head of the pterygium was gently avulsed from the corneal surface using Lim's forceps. Thickened portion i.e. the body of the pterygium along with the tenon's capsule was excised using corneal scissors to leave the clean bare sclera. No cautery was used; instead any obvious bleeding if seen, was stopped by direct tamponade using merocel sponge. The corneal and limbal area was scraped to clean of the residual tissue and to smoothen the corneal surface with the help of a crescent knife.

For harvesting the graft, minimal amount of ringer lactate was injected sub-conjunctively with 30-G needle into the superior or supero-temporal quadrant to separate the conjunctiva from the deeper tissues. Vernier caliper was used to mark the required length of conjunctiva to be dissected. About 2 to 3 millimetre wide strip of conjunctiva was separated from the sclera including 0.2 mm of the limbal part too. Careful and meticulous dissection was done to prevent button holing of the graft. The graft when separated from the nasal side was flipped over the cornea and the Tenon's adhesions were stripped off. After wiping off the adherent sub-conjunctival fibers as maximum as possible, the strip was dissected from the limbal side.

The graft was then placed at the bare sclera adjacent to limbus, ensuring that the epithelial surface of the graft remains superficial and the limbal part of the strip directs towards the limbal side. The graft was adhered with the native conjunctiva at its edges by manual compression using lims forceps on both the sides. Oozing blood/serum over bare sclera was used as tissue adhesive to secure the graft at its base. The remaining bare sclera nasal to the conjunctivo-limbal strip graft at the pterygium excision site was left bare. The strip of 2-3 mm bare area of sclera at the donor site was easily covered by pulling and cauterizing at the ends, using wet field cautery and eye was patched after instilling moxifloxacin-

ketorolac combination eye drop. Post-operatively, all the patients were advised topical 0.5% fluorometholone and tobramycin 0.3% combination eye drop 3-4 times/day, which was tapered in a duration of 4 weeks. A preservative-free tear substitute (0.5% carboxymethylcellulose) 4 times/day was also prescribed and continued for 6 weeks. Patients were seen on post-operative day 1,

1 week, 1 month, 3 months and 6 months. At the follow up visits, visual acuity, IOP and ocular examination was done on slit lamp to examine the donor and recipient site. The graft was observed for its in-situ placement, healing and any complications. Photographs were taken as a record and also for comparison on subsequent visits. (figure1)

Conjunctivo-limbal strip autograft (CLSAG)

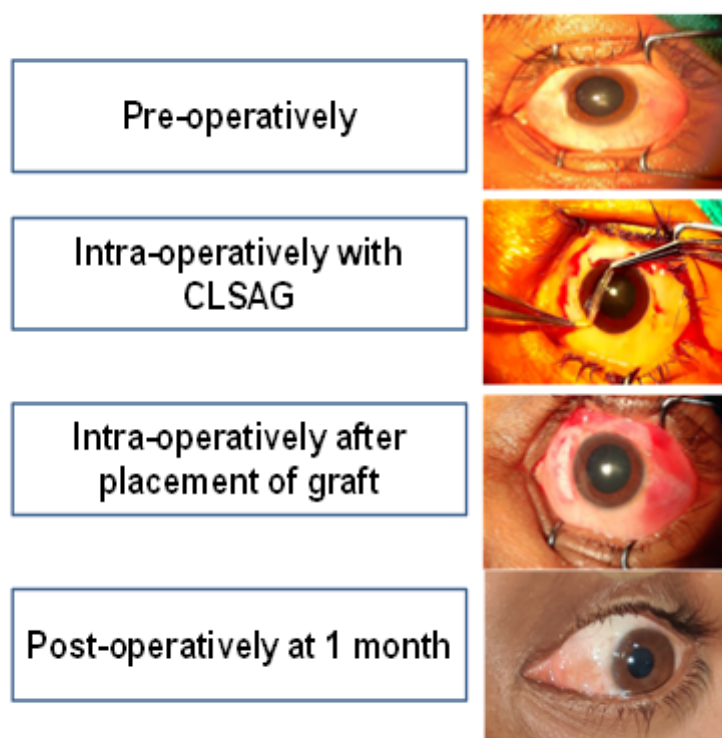


Figure 1: Pre-operative, intra-operative and post operation pictures

Result

The following results were obtained from an analysis of 268 eyes with primary pterygium treated with pterygium excision with CLSAG technique. The mean age was 47.5 ± 8.5 years (30–70 years). The study included 143 males and 101 females. The average duration of follow-up was 6 months. The average operating time was 10 ± 3 minutes.

The positive observations: This CLSAG minimised the overall surgical time, least destruction of conjunctival tissue at donor site, promoted early healing, reduced complications

related to large conjunctivo-limbal autograft and almost negligible recurrence rate.

CLSAG technique took about three to four weeks for conjunctival growth to completely cover the bare area. None of the patient showed graft retraction or haematoma underneath the graft.

The negative observations: Mild graft oedema was noticed in 35 cases which got subsided within a week with the same treatment, congestion over the graft and adjacent area was found in almost all the cases which resolved completely by the end of one month following surgery.

Table 1: Intra-operative challenges and their corrective measures

Sn	Challenges	Corrective Measures
1	Thick graft retrieval due to adherent sub conjunctival fibers	Removal of fibers
2	Button holing of the graft	Not to hold the graft with toothed forceps
3	Recognition of surface and side (superior and limbal)	Smoother surface identified as Epithelial Pigmented side recognized as limbal
4	Rolling/twisting because of thin graft	Unrolling of graft using non toothed forceps
5	Difficulty in securing the graft at ends	pressing ends of the graft along with adjacent conjunctiva with lim'sfoceps for adequate duration
6	Closing of lids	Taking care not to dislodge the graft by lids

Discussion

Pterygium excision with conjunctival autograft is considered as gold standard in the treatment of pterygium surgery and is widely performed by ophthalmologists. Intra-operative complications are quite common in different techniques i.e. thinning of sclera or cornea because of deep dissection, intraoperative bleeding, medial rectus muscle injury, button holing of graft, graft tear etc. Early postoperative complications like corneal dellen, subgraft haematoma, graft oedema, graft retraction/loss of graft and granuloma. Late postoperative complications like recurrence, corneo-scleral necrosis/thinning, scleritis and endophthalmitis.[9] In our study, intra operative challenges were thickened graft, button holing, recognition of superior and limbal side, rolling of the graft, difficulty in securing graft. All these problems were managed by minimal interventions and manipulations. Post-operative complications were mild congestion and oedema of the graft.

According to the study done by Petr, Kristian et al. [11] there was no significant difference between primary and recurrent pterygium surgery except increased bleeding while operating recurrent pterygium. In our study, bleeding was minimal as the patients having only primary pterygium were included and was easily managed by applying pressure directly on the bleeders using cotton buds or merocel sponge.

In our study we encounter recurrence in single case, however; some studies in spite of placing conjunctival autograft documented a significant rate of recurrence. [12,13,14]

Ramya deepthi P. et al; [15], SOO Hyun Kwon and Hong Kyun kim; [16]; VA Essuman, CT Ntim-Amponsah et al.[17]; have also reported 8.3%, 12.1%, and 37% recurrence rate respectively. Koranyi et al. compared conjunctival autograft fixation using fibrin glue adhesive with suture-assisted fixation, he concluded that fibrin glue had a 5.3% recurrence rate while suture-assisted procedure was associated with a recurrence rate of 13.5%.[18] Pterygium excision with CAG fixation

using fibrin glue is superior over suturing except some drawbacks i.e. costly, less readily available, bio-degradable within 3 hours of preparation, may carry potential risk of transmission of viral disease and anaphylactic reaction in susceptible individuals.[19, 20]

Using autologous serum with oozing blood as adhesive was comparable to fibrin glue and had none of the above mentioned drawbacks. Routinely a larger conjunctival autograft is used to cover the bare surface completely, but we grafted a thin strip of conjunctiva along with limbal tissue. The sclera at the donor site was minimally bare i.e. a strip of 2-3 mm, which was easily covered by pulling and cauterizing remaining conjunctiva similar to what is done to cover the sclera in small incision cataract surgery. This method of graft retrieval left the donor site almost undisturbed with minimal damage. Therefore, this technique has an added advantage of performing trabeculectomy or tube shunt surgery if required by the patients in the future. To the best of our knowledge, this is the first study reported worldwide in which a thin conjunctivo-limbal strip autograft has been used as a surgical technique to prevent the recurrence of pterygium and also cutting the cost and complications associated with suture or fibrin glue.

Conclusion

The CLSAG technique prevents the recurrence effectively along with minimal tissue destruction. It is a cost effective procedure as no fibrin glue or suture is required to secure the strip graft in place. The discomfort caused by suture in the form of foreign body sensation and fibrin glue associated complications are absent along with improved cosmesis. The conjunctiva of donor site is left almost undisturbed leading to early healing and left preserved for any future requirement. We recommend this technique to be considered as a viable alternative for conjunctival autograft fixation in pterygium surgery with all the benefits of other techniques without any complication.

References

1. Asokan R, Venkatasubbu RS, Velumuri L, Lingam V, George R: Prevalence and associated factors for pterygium and pinguecula in a South Indian population. *Ophthalmic Physiol Opt.* 2012, 32:39-44. 10.1111/j.1475-1313.2011.00882.x. Epub 2011 Nov 24.
2. McCarty CA, Fu CL, Taylor HR: Epidemiology of pterygium in Victoria, Australia. *Br J Ophthalmol.* 2000, 84:289-92. 10.1136/bjo.84.3.289.
3. Zhou WP, Zhu YF, Zhang B, Qiu WY, Yao YF: The role of ultraviolet radiation in the pathogenesis of pterygia (Review). *Mol Med Rep.* 2016, 14:3-15. 10.3892/mmr.2016.5223.
4. Di Girolamo N, Wakefield D and Coroneo MT: Differential expression of matrix metalloproteinases and their tissue inhibitors at the advancing pterygium head. *Invest Ophthalmol Vis Sci.* 2000, 41:4142-4149. 10.1167/iovs.00-00041.
5. Tan DT, Chee SP, Dear KB, Lim AS: Effect of pterygium morphology on pterygium recurrence in a controlled trial comparing conjunctival autografting with bare sclera excision. *Arch Ophthalmol.* 1997, 115:1235-40. 10.1001/archoph.1997.01100160405001.
6. Ghiasian L, Samavat B, Hadi Y, Arbab M, Abolfathzadeh N: Recurrent Pterygium: A Review. *J Curr Ophthalmol.* 2022, 6:367-378. 10.4103/joco.joco_153_20.
7. Nuzzi R, Tridico F: How to minimize pterygium recurrence rates: clinical perspectives. *Clin Ophthalmol.* 2018;19, 12:2347-2362. 10.2147/OPHTH.S186543.
8. Kenyon KR, Wagoner MD, Hettinger ME: Conjunctival autograft transplantation for advanced and recurrent pterygium. *Ophthalmology.* 1985, 92:1461-70. 10.1016/s0161-6420(85)33831-9.
9. Röck T, Bartz-Schmidt KU, Röck D: Management of double-head pterygium with conjunctival autograft and primary closure. *Int Med Case Rep J.* 2020, 13:111-115. 10.2147/IMCRJ.S203897.
10. Kodavoor SK, Preethi V, Dandapani R: Profile of complications in pterygium surgery - A retrospective analysis. *Indian J Ophthalmol.* 2021, 69:1697-1701. 10.4103/ijoo.IJO_3055_20.
11. Petr, Kristian: Recurrence of pterygium after surgery with conjunctival autograft- long term follow-up. *KlinikaOczna / Acta Ophthalmologica Polonica*, vol. 125, no.4. 2023:216-221. 10.5114/ko.2023.124694.
12. Chen PP, Ariyasu RG, Kaza V, LaBree LD, McDonnell PJ: A randomized trial comparing mitomycin C and conjunctival autograft after excision of primary pterygium. *Am J Ophthalmol.* 1995, 120:151-60. 10.1016/s0002-9394(14)72602-9.
13. Mahar PS: Conjunctival autograft versus topical mitomycin C in treatment of pterygium. *Eye (Lond).* 1997;11. 6:790-2. 10.1038/eye.1997.206.
14. Manning CA, Kloess PM, Diaz MD, Yee RW: Intraoperative mitomycin in primary pterygium excision. A prospective, randomized trial. *Ophthalmology.* 1997, 104:844-8. 10.1016/s0161-6420(97)30224-3.
15. Deepthi R P, Amruth K C, Kumar P P, Teja K: Conjunctival graft from pterygium tissue itself in primary pterygium surgery. *Ophthalmol J.* 2021, 6:245-248. 10.5603/OJ.2021.0041.
16. Kwon SH, Kim HK: Analysis of recurrence patterns following pterygium surgery with conjunctival autografts. *Medicine (Baltimore).* 2015, 94:518. 10.1097/MD.0000000000000518.
17. Essuman VA, Ntim-Amponsah CT, Vemuganti GK, Ndanu TA: Epidemiology and recurrence rate of pterygium post excision in Ghanaians. *Ghana Med J.* 2014, 48:39-42. 10.4314/gmj.v48i1.6.
18. Koranyi G, Seregard S, Kopp ED: Cut and paste: a no suture, small incision approach to pterygium surgery. *Br J Ophthalmol.* 2004, 88:911-4. 10.1136/bjo.2003.032854.
19. Panda A, Kumar S, Kumar A, Bansal R, Bhartiya S: Fibrin glue in ophthalmology. *Indian J Ophthalmol.* 2009, 57:371-9. 10.4103/0301-4738.55079.
20. Romano V, Cruciani M, Conti L, Fontana L: Fibrin glue versus sutures for conjunctival autografting in primary pterygium surgery. *Cochrane Database Syst Rev.* 2016, 12:011308. 10.1002/14651858.CD011308.pub 2.