

Radial Shortening as a Treatment Modality in an Advanced Stage of Lunatomalacia in Tertiary Care Centre of Western Rajasthan**Akhilesh Kumar Sharma¹, Raghuveer Meena², Anshul Meena³, Ajay Gupta⁴**¹Consultant Orthopaedics, Bhinmal Hospital and Research Centre, Jalore, Rajasthan, India²Medical Officer, Department of Medical Health and Family Welfare, Rajasthan, India³Assistant Professor, Department of General Surgery, Government Medical College, Sawai Madhopur, Rajasthan, India⁴Assistant Professor, Department of Community Medicine, Government Medical College, Sawai Madhopur, Rajasthan, India

Received: 01-01-2026 / Revised: 15-02-2026 / Accepted: 21-03-2026

Corresponding author: Dr. Ajay Gupta

Conflict of interest: Nil

Abstract**Introduction:** Lunatomalacia or osteonecrosis of the lunate, can lead to chronic, debilitating wrist pain. This study was done with the objective to evaluate the risks and benefits of radial shortening in advanced stage of lunatomalacia in Tertiary care centre in Western Rajasthan.**Materials and Methods:** This Hospital based observational study was conducted between the periods of April 2016 to May 2022. Total 24 cases that had undergone radial shortening for treatment of Lunatomalacia were included in our study. Cases were clinically evaluated for pain, range of motion and grip strength. Pain was quantified by Visual Analogue Scale (VAS), Range of motion was measured by goniometer and grip strength was measured relative to contralateral side with help of dynamometer. Data was analysed using Microsoft excel 2019.**Result:** Mean age of cases was 33.83±11.65 years. Male to female ratio was 2:1. Range of motion, Grip strength, Wrist extension and Wrist flexion in operated hand increased after the procedure and this improvement was found to be statistically significant (p value<0.05). Postoperative VAS and DASH score significantly decreased after the radial shortening (p value<0.05) and NKSS increased significantly postoperatively (p value<0.05).**Conclusion:** Radial shortening is a simple and reproducible procedure with low complication rate. We concluded that radial shortening is an effective procedure with respect to functional improvement in treatment of patients of Lunatomalacia even in advance stage 3A, 3B and 4 however radiologically improvement is mild.**Keywords:** Clinical Outcome, Functional improvement, Lunatomalacia, Radial Shortening.**DOI:** 10.25258/ijcpr.18.4.27This is an Open Access article that uses a funding model which does not charge readers or their institutions for access and distributed under the terms of the Creative Commons Attribution License (<http://creativecommons.org/licenses/by/4.0>) and the Budapest Open Access Initiative (<http://www.budapestopenaccessinitiative.org/read>), which permit unrestricted use, distribution, and reproduction in any medium, provided original work is properly credited.**Introduction**

Lunatomalacia is the avascular necrosis of lunate carpal bone. It was first acknowledged and defined by a Radiologist Robert in 1990. Almost seven patients out of 1,00,000 patients have Lunatomalacia [1]. Common presentation of the diseases is wrist pain with limited range of motion and decreased hand grip strength. Causes of the disease progression are still not identified.

In the initial stage, treatment is conservative which includes analgesic, anti-inflammatory medications and immobilization. The surgical procedure is reassured for non-respond patients of conservative trial. The surgical procedures consist of capitates shortening, lunate resection, revascularization, radial osteotomy, ulnar lengthening and limited

intercarpal fusion. Salvage procedure for Lunatomalacia include wrist denervation and proximal raw carpectomy. In 1928, Hulten, noticed 78% ulnar negative variance in patients of Lunatomalacia against 23% patients of general population, above study indicates causal association between negative ulnar variance and Lunatomalacia. Based on the above findings, radial osteotomies done predominantly who have negative ulnar variance. However, recent studies reported that Asian race also suffered from Lunatomalacia with ulnar positive and ulnar neutral variance [2].

Among various surgical procedures described for Lunatomalacia, radial shortening may be considered

preferred choice for patients. Salmon et al. provided evidence that in early stage of disease radial shortening may be superior to conservative treatment [3]. Nakamura et al provided that radial closing wedge osteotomy showed improvement in pain, range of motion and grip strength even in the advanced stage of the disease [4].

Some studies still suggest surgical technique like carpal procedure, inter-carpal arthrodesis or proximal row carpectomy preferred in advance stage [5][6]. So, there is ongoing controversial debate to find optimal treatment strategy for the advance stage of Lunatomalacia. To perform these complex surgeries a steep learning curve as well as modern equipments are required, which is a burden in health care services in developing countries like India. Simple and reproducible surgical procedure with short learning curve is need of hour to obtain equal results like radial shortening osteotomy.

Radial Shortening procedure is an extraarticular osteotomy which decreases the load across the radiolunate joint by restructuring the force to radiosaphoid and ulnolunate joint. This procedure also preserves intraarticular function of wrist joint postoperatively [7][8]. Radial shortening is simple surgical procedure with less postoperative complications. Radial shortening as surgical modality for advance stage of Lunatomalacia is yet to be established. There is limited paucity of literature regarding radial shortening osteotomy. The purpose of this study was to evaluate the risks and benefits of radial shortening in advance stage of Lunatomalacia in Tertiary care centre in Western Rajasthan.

Material and Methods

This Hospital based observational study was conducted in department of Orthopaedics Dr SN Medical College, Jodhpur. Out of 43 cases, 30 consecutive cases that had undergone radial shortening between the periods of April 2016 to May 2022 for treatment of Lunatomalacia were included in our study. Patients presented with complaint of wrist pain, tenderness, restriction of movements and decreased grip strength, their radiogram (anteroposterior view, lateral view, oblique view) and MRI (T1, T2 & STIR) were taken and classified according to Lichtmann et al [Table-I] [9]. Thirteen cases had stage 1 disease, eight cases had Stage II disease, six cases had Stage IIIA disease, twelve cases had Stage IIIB disease, and four cases had Stage IV disease. Cases with Lichtman stage first were managed with conservative treatment and excluded from the study. Out of 30 cases who had radial shortening, four cases were lost to follow up and two cases did not give consent to participate in our study. Remaining twenty-four cases were followed up for one year.

Clinical and Radiographic Evaluation: Cases were clinically evaluated for pain, range of motion and grip strength. Pain was measured by Visual Analogue Scale (VAS) ranging from 0 to 10 points (0 corresponds to no pain, 1-4 corresponds to mild pain, 5-6 corresponds to moderate pain and 7-10 corresponds to severe pain) [10]. Range of motion was measured by goniometer and grip strength was measured by dynamometer relative to contralateral side.

Preoperative and postoperative radiograph was obtained with sequential radiograph in each follow-up. Preoperative radiograph was compared with final follow-up radiograph which included Carpal height ratio and Stahl index.

Carpal height ratio is defined as Carpal height divided by length of 3rd Metacarpal height, calculated in Anteroposterior radiograph. Stahl's index is defined as height of lunate (proximal-distal) dimension divided by its diameter (AP) dimension, calculated in lateral radiograph. Clinical evaluation of pain, restriction of motion and grip strength is done objectively to reduce bias by Modified Nakamura Scoring System for Lunatomalacia (NSSK) [11] and Quick DASH9 (Disabilities of Arm Shoulder and Hand) questionnaire [12].

Surgical Procedures: Radiological assessment was done to pre determine the amount of radial shortening.

Radial shortening was done under general or regional anaesthesia. Cases were placed in supine position and a tourniquet applied with pressure systolic blood pressure +100 mmhg for duration of one hour was used. A modified Henry volar approach was used, the superficial plane made between flexor carpi radialis tendon and radial artery and deep dissection done between flexor pollicis longus and radial artery to save the median nerve and radial artery from injuries.

Pronator quadratus was first identified and cut in L shaped style and elevated periosteal to reach distal metaphysio-diaphyseal junction of radius. Oscillating saw was used to make two parallel cuts at metaphysio-diaphyseal junction and bone block of 2-3mm was removed, fixation was completed with compression plate. After fixation, pronator quadratus was reattached to its fascia and wound was closed. Postoperatively, a short arm splint was applied for 2-3 weeks. Passive physiotherapy was initiated as early as possible after postop period, it consists of stretching of fingers and movement of metacarpal phalanges joint as well as elbow and shoulder joint. Active physiotherapy was started after the splint removal, it includes weight bearing exercise and active wrist mobilization exercises.

Statistical Analysis: Data thus collected was entered in Microsoft Excel Sheet by investigator himself on same day to minimize data entry bias if any. Normal continuous data was summarized in form of mean and standard deviation. The significance of difference between two means was analyzed using student's t test [13]. Ordinal data was presented in form of median and interquartile range and repeated measure was analyzed using Wilcoxon rank test. The level of significance was kept at 95% for all statistical analysis.

Result

Mean age of cases was 33.83±11.65 years. Two third (16/24) cases were male and rest eight cases were female. Male to female ratio was 2:1. Range of motion, Grip strength, Wrist extension and Wrist flexion in operated hand increased after the procedure and this improvement was found to be statistically significant (p value<0.05). Postoperative VAS and Quick DASH9 score significantly decreased after the radial shortening (p value<0.05) and NKSS increased significantly postoperatively (p value<0.05). Figure 1 showed wrist radiogram of patients preoperatively and figure 2 showed wrist radiogram with radial shortening. Mean postoperative wrist extension, wrist flexion and grip strength in operated hand

was significantly lower than contralateral hand (p value<0.05).

[Table-II] depicts the difference in clinical outcome after procedure in cases of different stages. Post-operative Range of motion was higher in grade 2 cases, followed by grade 3A, 3B and least in grade 4 and this difference in post-operative range of motion among cases of different grades was statistically significant (p value<0.05). Similar presentation was also seen with wrist flexion and wrist extension in operated hand and this difference was also found to be statistically significant (p value<0.05). Post-operative grip strength was higher in grade 3A cases, followed by 3B, grade 4 cases and least in grade 2 cases and this difference in grip strength in operated hand was also statistically significant (p value<0.05)

(Table-III) Post-operative VAS score was highest in grade 4 cases, followed by grade 3B, grade 3A and grade 2 cases and this difference was statistically significant (p value<0.05). While, NKSS score was highest in grade 2 cases and least in grade 4 cases and this difference was also significant (p value<0.05). And the difference in postop Quick DASH 9 score among cases of different grades was statistically insignificant (p value>0.05)

Table 1: Lichtman's Radiographic classification

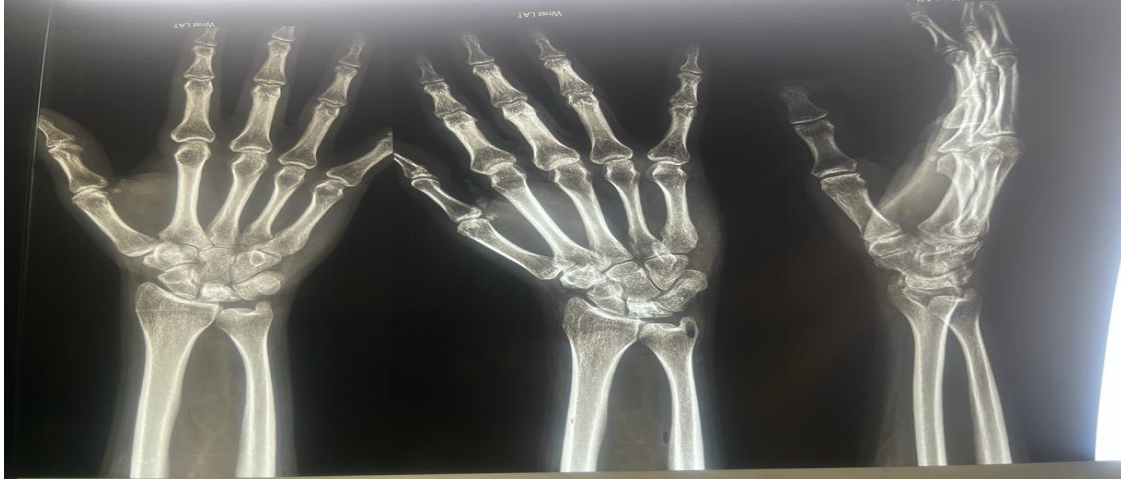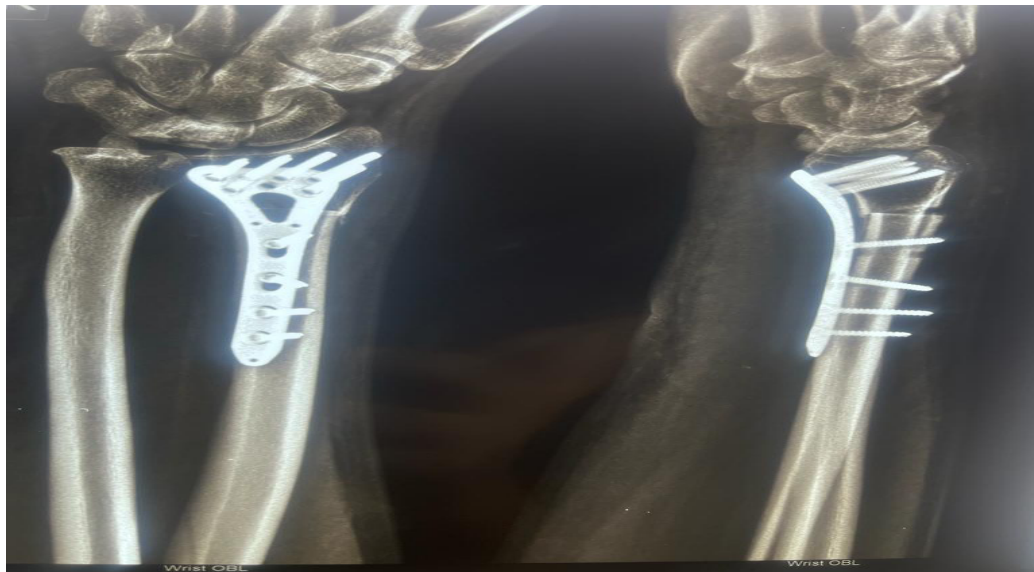
Stage	Findings
Stage I	<ul style="list-style-type: none"> ➤ Normal Radiograph ➤ May Show possible lunate fracture
Stage II	<ul style="list-style-type: none"> ➤ Sclerosis of lunate without collapse ➤ Portions of lunate begin to deteriorate
Stage IIIA	<ul style="list-style-type: none"> ➤ Lunate Collapse ➤ No Scaphoid rotation ➤ Surrounding bones may shift
Stage IIIB	<ul style="list-style-type: none"> ➤ Lunate Collapse ➤ Fixed scaphoid rotation ➤ Surrounding bones may shift
Stage IV	<ul style="list-style-type: none"> ➤ Degenerative changes around the lunate ➤ Wrist may become arthritic

Table 2: Difference in clinical outcome of patients of different stage of disease

Variables	Grade 2	Grade 3A	Grade 3B	Grade 4	p value
Preop ROM	89±2.4	75.5±4.4	72.4±3.9	71±1.2	<0.001
Postop ROM	104±1.8	103.3±2.5	102.6±1.8	99.5±1.7	0.004
Wrist extension operated Pre	43±2.4	49±2.6	37.6±6.9	33.5±1.7	0.023
Wrist extension operated Post	63.3±3.7	57.5±5.7	54.2±5.4	46.5±1.7	<0.001
Wrist extension contralateral	68.3±3.1	67±2.6	69.2±2.9	65.5±2.9	0.089
Wrist Flexion operated Pre	48±3.6	48.5±3.4	36.8±5.7	39±1.2	<0.001
Wrist flexion operated Post	65±2.4	65.3±2.2	52±1.2	53±3.5	<0.001
Wrist flexion contralateral	72	75.8±1.7	71.6±2.1	70±1.2	0.016
Grip Strength Pre	24±4.7	27.8±2.6	23.6±5.7	22.5±5.2	0.965
Grip Strength Post	30.3±4.4	40.5±1.3	35.6±1.4	34±2.3	0.001
Grip Strength Contralateral	33.3±3.7	44.3±1.7	41.6±1.6	41±1.2	<0.001

Table 3: Difference in VAS, NKSS and DASH of patients of different stage of disease

Variables	Grade 2	Grade 3A	Grade 3B	Grade 4	p value
Preop VAS	2(2.75-2)	3.5(4-3)	4(4-4)	4.5(5-4)	<0.001
Postop VAS	0(0-0)	0.5(1-0)	1(1-1)	1.5(2-1)	<0.001
NKSS Pre	12(12-10.5)	8(8.25-7.75)	8(9-6)	7(8-6)	0.002
Post NKSS	18(18-18)	16.5(17-13.5)	15(16-14)	14.5(15-14)	<0.001
Preop DASH	11(11.75-10.25)	11.5(12.25-10.75)	16(16-14)	19(20-18)	0.002
Postop DASH	6(12-6)	4.5(5.25-4)	8(10-8)	9.5(10-9)	0.113

**Figure 1: Preoperative radiogram of wrist showing Lunatomalacia****Figure 2: Postoperative radiogram of wrist showing radial shortening**

Discussion

Since the acknowledgment of Lunatomalacia, it is found to be a constant challenge for orthopaedic surgeons, as this disease had multifactorial causation including mechanical, vascular, traumatic factor [14]. Displacement of lunate with fixed rotation of scaphoid is a common finding in advance stage of Lunatomalacia. It was reported in some studies that realignment of scaphoid has a significant role in reducing compressive force on lunate [15,16], therefore some researchers had suggested radial osteotomy as a contraindication in

advance stage of the disease (3B and 4) [17]. As described in various biochemical studies, Patient with Lichtman radiologic classification stage 3b, presents with collapsed lunate and fixed scaphoid malrotation, which is often treated by realignment of scaphoid, cannot be corrected by radial shortening [15, 16].

In our study there was significant clinical improvement, however radiologic improvement was not significant. There was no casual association between clinical improvement and radiologic outcomes. Burns and Almquist [18] also

reported no significant association of postoperative radiological and clinical improvement after 5 to 10 years of radial shortening. Koh et al [19] proposed a grading system in which there was no association between radiologically improvement in parameters like (Stahl's index, Carpal height ratio and Lichtmann classification) with clinical improvement. In this grading system, improvement in cystic changes, sclerosis and fragmentation indicate revascularization of lunate. By using this new grading system, more than half of patients which were previously considered with no radiological improvement, showed to have good result in terms of revascularization of lunate's inner structure. Radial shortening causes radial translation of capitate and lunate, which results in reduced compressive force on lunate [20,21]. Radial shortening is an extraarticular procedure, hence able to preserve wrist function. Recent studies suggested that there are vascular anastomoses which surround the radius and extends up to carpals, osteotomy of radius will enhance blood flow and accelerate the process of revascularization of lunate [22-24]. Nakamura et al reported that radial shortening must not exceed 2mm otherwise it will cause ulnar sided wrist pain with unsatisfactory outcome. In our study no patient was reported with ulnar sided wrist pain [25].

Our study reported that radial shortening is effective in decreasing pain with improved range of motion and grip strength, even in advanced stage of disease without much radiologically improvement. Iwaski et al reported major improvement in wrist pain with improved hand grip and range of motion [26], Shin et al showed that radial osteotomy results in functional and radiologically improvement in advance stage (3b and 4) compared to grade 3a [27], Weiss et al also showed improvement of clinical and functional result while no radiographic improvement [28]. In our study VAS Score and DASH score significantly decreased with improvement in wrist function in advance stage (3A,3B and 4) without much radiologically improvement with union of radius in all cases.

Conclusion

Radial shortening is a simple and reproducible procedure with low complication rate and easily applicable technique with small learning curve, in compared to intraarticular procedure like intercarpal fusion and proximal row carpectomy. With long term follow-up in our study, we concluded that radial shortening could be an effective procedure with respect to patients' satisfaction and functional improvement in treatment of patients of Lunatomalacia even in advance stage 3A, 3B and 4 however radiologically improvement is mild.

Sharma *et al.*

References

1. Golay SK, Rust P, Ring D. The radiological prevalence of incidental Kienböck disease. *Arch Bone Jt Surg.* 2016 Jun; 4:220–223.
2. Watanabe K, Nakamura R, Horii E, Miura T. Biomechanical analysis of radial Wedge osteotomy for the treatment of Lunatomalacia disease. *J Hand Surg Am.* 1993 Jul;18(4):686-90.
3. Salmon J, Stanley JK, Trail IA: Lunatomalacia disease: Conservative management versus radial shortening. *Bone Joint Surg Br.* 2000 Aug;82(6):820-3.
4. Nakamura R, Tsuge S, Watanabe K, Tsunoda K. Radial wedge osteotomy for Kienböck disease. *J Bone Joint Surg Am.* 1991 Oct;73(9):1391-6.
5. Beredjikian PK. Lunatomalacia disease. *J Hand Surg Am.* 2009 Jan;34(1):167-75.
6. Condit DP, Idler RS, Fischer TJ, Hastings H 2nd. Preoperative factors and outcome after lunate decompression for Kienböck's disease. *J Hand Surg Am.* 1993 Jul;18(4):691-6.
7. Tatebe M, Horii E, Majima M, Koh S, Nakamura R, Hirata H. Radial osteotomy for Kienböck's disease with displaced fracture of the lunate. *J Hand Surg Am.* 2007 Nov;32(9):1343-1347.
8. Tsunoda K, Nakamura R, Watanabe K, Horii E, Miura T. Changes in carpal alignment following radial osteotomy for Kienböck's disease. *J Hand Surg Br.* 1993 Jun;18(3):289-93.
9. Lichtman DM, Mack GR, MacDonald RI, Gunther SF, Wilson JN. Kienböck's disease: the role of silicone replacement arthroplasty. *J Bone Joint Surg Am.* 1977 Oct;59(7):899-908.
10. Delgado DA, Lambert BS, Boutris N, McCulloch PC, Robbins AB, Moreno MR et al. Validation of Digital Visual Analog Scale Pain Scoring with a Traditional Paper-based Visual Analog Scale in Adults. *J Am Acad Orthop Surg Glob Res Rev.* 2018 Mar 23;2(3):e088.
11. Altay T, Kaya A, Karapinar L, Ozturk H, Kayali C. Is radial shortening useful for Litchman stage 3B Kienböck's disease? *Int Orthop.* 2008 Dec;32(6):747-52.
12. Gabel CP, Yelland M, Melloh M, Burkett B. A modified QuickDASH-9 provides a valid outcome instrument for upper limb function. *BMC Musculoskelet Disord.* 2009 Dec 18; 10:161.
13. Sharma S, Jamar S, Kataria T, Agarwal S, Gupta A, Pareek Y et al. An Observational Study on Association of Clinical Outcome of Diphtheria Cases with Immunization Status: A Tertiary Care Hospital, Jaipur. *Indian J Otolaryngol Head Neck Surg.* 2022 Dec;74(3): 5460-5464.

14. Irisarri C. Aetiologie der Lunatumnekrose [Aetiology of Kienböck's Disease]. *Handchir Mikrochir Plast Chir*. 2010 Jun;42(3):157-61.
15. Iwasaki N, Genda E, Minami A, Kaneda K, Chao EY. Force transmission through the wrist joint in Kienböck's disease: a two-dimensional theoretical study. *J Hand Surg Am*. 1998 May;23(3):415-24.
16. Short WH, Werner FW, Fortino MD, Palmer AK. Distribution of pressures and forces on the wrist after simulated intercarpal fusion and Kienböck's disease. *J Hand Surg Am*. 1992 May;17(3):443-9.
17. Condit DP, Idler RS, Fischer TJ, Hastings H 2nd. Preoperative factors and outcome after lunate decompression for Kienböck's disease. *J Hand Surg Am* 1993; 18:691-696.
18. Almquist EE, Burns JF Jr. Radial shortening for the treatment of Kienböck's disease--a 5- to 10-year follow-up. *J Hand Surg Am*. 1982 Jul;7(4):348-52.
19. Koh S, Nakamura R, Horii E, Nakao E, Inagaki H, Yajima H. Surgical outcome of radial osteotomy for Kienböck's disease--minimum 10 years of follow-up. *J Hand Surg Am*. 2003 Nov;28(6):910-6.
20. Wada A, Miura H, Kubota H, Iwamoto Y, Uchida Y, Kojima T. Radial closing wedge osteotomy for Kienböck's disease: an over 10 year clinical and radiographic follow-up. *J Hand Surg Br*. 2002 Apr;27(2):175-9.
21. Zenzai K, Shibata M, Endo N. Long-term outcome of radial shortening with or without ulnar shortening for treatment of Kienböck's disease: a 13-25 year follow-up. *J Hand Surg Br*. 2005 May;30(2):226-8.
22. Illarramendi AA, Schulz C, De Carli P. The surgical treatment of Kienböck's disease by radius and ulna metaphyseal core decompression. *J Hand Surg Am*. 2001 Mar;26(2):252-60.
23. Nakamura R, Watanabe K, Tsunoda K, Miura T. Radial osteotomy for Kienböck's disease evaluated by magnetic resonance imaging. 24 cases followed for 1-3 years. *Acta Orthop Scand*. 1993 Apr;64(2):207-11.
24. Tsunoda K, Nakamura R, Watanabe K, Horii E, Miura T. Changes in carpal alignment following radial osteotomy for Kienböck's disease. *J Hand Surg Br*. 1993 Jun;18(3):289-93.
25. Nakamura R, Imaeda T, Miura T. Radial shortening for Kienböck's disease: factors affecting the operative result. *J Hand Surg Br*. 1990 Feb;15(1):40-5.
26. Iwasaki N, Minami A, Oizumi N, Suenaga N, Kato H, Minami M. Radial osteotomy for late-stage Kienböck's disease. Wedge osteotomy versus radial shortening. *J Bone Joint Surg Br*. 2002 Jul;84(5):673-7.
27. Shin YH, Kim J, Gong HS, Rhee SH, Cho MJ, Baek GH. Clinical Outcome of Lateral Wedge Osteotomy of the Radius in Advanced Stages of Kienböck's Disease. *Clin Orthop Surg*. 2017 Sep;9(3):355-362.
28. Weiss AP, Weiland AJ, Moore JR, Wilgis EF. Radial shortening for Kienböck disease. *J Bone Joint Surg Am*. 1991 Mar;73(3):384-91.