

**Clinicopathological Study of Gall Bladder Specimen of Cholelithiasis**Shashi Ranjan Roy<sup>1</sup>, Priya<sup>2</sup>, K.M. Prasad<sup>3</sup>, Dilip Kumar<sup>4</sup><sup>1</sup>Tutor, Department of Pathology, Patna Medical College, Patna, Bihar, India<sup>2</sup>Tutor, Department of Pathology, Patna Medical College, Patna, Bihar, India<sup>3</sup>Professor, Department of Pathology, Patna Medical College, Patna, Bihar, India<sup>4</sup>Professor & HOD, Department of Pathology, Patna Medical College, Patna, Bihar, India

Received: 01-01-2026 / Revised: 15-02-2026 / Accepted: 21-03-2026

Corresponding author: Dr. Shashi Ranjan Roy

Conflict of interest: Nil

**Abstract**

**Background:** Gallstone disease, one of the most common biliary disorders worldwide, is a major cause of morbidity in middle-aged women. Histopathological changes can include malignancy and chronic cholecystitis when gallstones irritate the gallbladder mucosa. Clinicopathological and biochemical investigations can assist identify disease origins and detect issues early.

**Methods:** A prospective observational study conducted at Department of Pathology, Patna Medical College and Hospital (PMCH) from the year 2020–2021. A total of 100 gallstone-containing cholecystectomy specimens were examined. Gallstone biochemistry, shape, histology, and clinical data were studied. Traditional histology stains and biochemical testing were performed. Chi-square and Student's t-tests considered p-values below 0.05 significant.

**Results:** The average age of the 100 patients was 42.4 years, ranging from 17-74 years, and 78% were female and 22% male. Most histological results showed chronic cholecystitis (72%), but acute on chronic (12%), cholesterolosis (3%), xanthogranulomatous (3%), and adenocarcinoma (4%). Pigment (28%), mixed gallstones (48%), and cholesterol stones (24%), were the most common. There was no correlation between stone type and histopathological pattern ( $\chi^2 = 9.95$ ,  $p = 0.445$ ).

**Conclusion:** Cholelithiasis is the most frequent cholecystitis pathology in middle-aged women. All cholecystectomy tissues must be histopathologically examined to improve clinical outcomes and detect accidental premalignant or malignant abnormalities.

**Keywords:** Biochemical analysis, Cholelithiasis, Chronic cholecystitis, Gallstones, Histopathology.

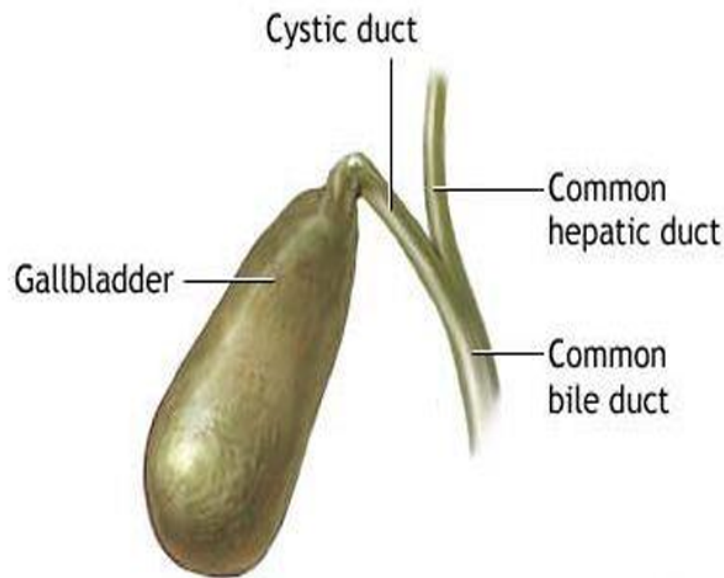
DOI: 10.25258/ijcpr.18.4.67

This is an Open Access article that uses a funding model which does not charge readers or their institutions for access and distributed under the terms of the Creative Commons Attribution License (<http://creativecommons.org/licenses/by/4.0>) and the Budapest Open Access Initiative (<http://www.budapestopenaccessinitiative.org/read>), which permit unrestricted use, distribution, and reproduction in any medium, provided original work is properly credited.

**Introduction**

The gallbladder stores bile under the liver and is pear-shaped. Bile is needed to break down lipids and absorb fat-soluble vitamins [1]. Gallstones characterise gallbladder problems, one of the most common surgical conditions worldwide. Gallstones cause approximately 95% of gallbladder lesions and many biliary system issues, making cholecystectomy one of the most common abdominal procedures [2]. Cholelithiasis, a multifactorial disease, precipitates cholesterol, bilirubin, and calcium salts [3]. Pathophysiology links cholesterol crystal nucleation, gallbladder hypomotility, mucus hypersecretion, and bile

supersaturation [4]. Clinical manifestation and pathological changes in the gallbladder wall depend on the stones' chemical makeup, which may be cholesterol, pigment, or both. Heredity, hormones, diet, and metabolic problems can cause stones [5]. Gallstones are linked to being female, overweight, having several children, eating a high-fat diet, not exercising enough, and being elderly [6]. Most illness victims are women in their 40s and 50s, the "fat, fertile, female, and forty" risk category. Diabetes, dyslipidaemia, pregnancy, oral contraceptives, and rapid weight loss increase vulnerability [7].



**Figure 1: Anatomy of Gall Bladder**

Gallstone disease can cause silent incidental symptoms, severe cholecystitis, and deadly perforation or malignancy [8]. Histological changes must be correlated with clinical presentation to understand the progression from benign to malignant tumours. Epithelial metaplasia, xanthogranulomatous inflammation, cholesterosis, and chronic cholecystitis are common histopathological findings in long-term cholelithiasis [9]. Histological examination of all cholecystectomy materials is essential for detecting incidental malignancies and premalignant lesions. Up to 95% of gallbladder cancer cases have gallstones.

Recent advances in Magnetic Resonance Cholangiopancreatography (MRCP) and ultrasonography have improved the detection of gallstones and gallbladder pathology in asymptomatic people. Despite these changes, many patients appear advanced because to delayed medical care and unclear symptoms. Cholelithiasis is also rising among younger adults, likely due to less active lifestyles and changing diets. Histopathological studies are the best technique to diagnose dysplastic changes, xanthogranulomatous inflammation, and cholesterosis. Metaplasia or atypia in the gallbladder mucosa also illuminates the path from chronic inflammation to malignancy. Thus, a full clinicopathological and biochemical investigation is needed to understand disease development and establish prevention interventions for vulnerable patients.

The incidence of cholelithiasis has shown a rising trend in India due to rapid urbanization, westernization of diet, and increased availability of diagnostic imaging such as ultrasonography. This

prospective investigation compares biochemical stone composition, histological changes, and clinical features in gallbladder samples from cholelithiasis patients to address that gap. This study aims to clarify the morphological trends and pathophysiology of gallbladder disease in India to aid early detection, treatment, and prevention.

#### **Objectives**

1. To study the age and sex distribution of patients with cholelithiasis.
2. To evaluate the different clinical presentations of gallstone disease.
3. To correlate histopathological changes in the gallbladder wall with the type of gallstones.
4. To analyze the biochemical composition of gallstones and classify them into cholesterol, pigment, and mixed types.
5. To identify any incidental premalignant or malignant lesions associated with gallstone disease.

#### **Materials and Methods**

**Study Design:** In this prospective observational study, gallbladder samples from cholelithiasis patients were examined for biochemical and clinicopathological features. The study examined the link between gallstone biochemistry, gallbladder wall histology, and clinical symptoms.

**Study Site and Duration:** This study was conducted at the Department of Pathology at PMCH. The study lasted two years, January 2020–December 2021.

**Sample Size:** The study included 100 cholecystectomy samples. When ultrasonography or other imaging techniques showed gallstones,

cholecystectomy was recommended. Sample size was based on the number of cases that matched inclusion criteria and were received throughout the research.

#### Inclusion Criteria

- All surgically resected gallbladder specimens containing gallstones.
- Patients of both sexes and all age groups.
- Adequately preserved specimens suitable for histopathological processing.

#### Exclusion Criteria

- Autolysed or poorly preserved specimens.
- Autopsy specimens.
- Cholecystectomy specimens without gallstones.

**Data Collection:** Clinical data included age, sex, presenting symptoms, clinical signs, and relevant laboratory and radiographic findings from patient records. A gross inspection was performed on each gallbladder specimen fixed in 10% buffered formalin. The outer layer, size, wall thickness, mucosal appearance, gallstone amount, kind, and presence were documented. Tissue sections were taken from the fundus, body, neck, and any unusually enlarged or atypical mucosa of the gallbladder. The specimens were processed using normal histological methods, including paraffin embedding, 3-5  $\mu\text{m}$  slicing, and H&E staining. Mucin or other components were PAS or Alcian Blue-stained.

**Biochemical Analysis of Gallstones:** Pestle and mortar pounded rinsed and air-dried gallstones into powder. Standard qualitative biochemical procedures examined the powdered substance

(Varley Harold and Oser). Multiple tests were done:

- **Cholesterol:** Liebermann–Burchard reaction (green color positive).
- **Calcium:** Addition of potassium oxalate and acetic acid (white precipitate positive).
- **Oxalate:** Addition of calcium chloride and acetic acid (white crystals positive).
- **Phosphate:** Ammonium molybdate and vitamin C test (yellow to blue color change).
- **Carbonate:** Effervescence with hydrochloric acid.
- **Bile pigments:** Diazotized sulphanilic acid or Fouchet's test (blue-green coloration positive).

The stones' biochemical makeup classified them as cholesterol, pigment, or mixed.

**Statistical Analysis:** Tabular data was analysed descriptively and inferentially. To represent quantitative elements like age, mean  $\pm$  standard deviation was used, whereas frequencies and percentages were used for qualitative data including sex distribution, stone type, and histological diagnosis. A chi-square ( $\chi^2$ ) test was used to analyse the correlation between gender, age, and gallstone type. Male and female patient mean ages were compared using Student's t-test. A p-value below 0.05 represented statistical significance.

**Ethical Considerations:** The study started with institutional ethical approval. All specimens were processed according to biosafety and ethical standards, and patient identity was maintained.

## Results

### Demographic Distribution

**Table 1: Age and Sex-wise Distribution of Cases**

Age Group (Years)	Male (n)	Female (n)	Total (n)	Percentage (%)
11–20	2	2	4	4.0
21–30	1	16	17	17.0
31–40	5	21	26	26.0
41–50	4	25	29	29.0
51–60	6	10	16	16.0
>60	4	4	8	8.0
<b>Total</b>	<b>22</b>	<b>78</b>	<b>100</b>	<b>100.0</b>

The study had participants aged 17-74, with an average age of  $42.4 \pm 13.1$  years. The 1:3.54 male-to-female ratio favoured women, consistent with hormonal and metabolic risk factors. The t-test

showed a significant difference in mean age between males and girls ( $t = 2.21$ ,  $p < 0.05$ ).

### Clinical Presentation

**Table 2: Presenting Symptoms of Cholelithiasis**

Clinical Feature	No. of Cases (n)	Percentage (%)
Pain in right hypochondrium/epigastrium	100	100
Nausea and vomiting	62	62
Dyspepsia	28	28
Fever	12	12
Jaundice	8	8

All patients had abdominal pain, usually from the right hypochondrium. Complex cases were more likely to have dyspepsia (28%) and nausea/vomiting (62%), fever (12%), and jaundice

(8%), which may indicate acute inflammation or biliary obstruction.

### Clinical Signs

**Table 3: Clinical Signs Noted on Examination**

Clinical Sign	Percentage (%)
Right hypochondriac tenderness	100
Icterus	8
Palpable mass	3

Every patient had right upper quadrant pain. Rare icterus and palpable gallbladder masses were connected to severe cholecystitis.

### Gross Findings of Gallbladder Specimens

**Table 4: Gross Pathological Findings**

Parameter	No. of Cases	Percentage (%)
Wall thickening (>3 mm)	53	53%
Normal wall thickness	47	47%
Single stone	14	14%
Multiple stones	86	86%

Most gallbladders had chronic inflammatory symptoms of wall thickening. Calculi, usually multifaceted and yellow-gray, were more numerous.

### Histopathological Findings

**Table 5: Distribution of Histopathological Diagnoses**

Histopathological Diagnosis	No. of Cases (n)	Percentage (%)
Chronic cholecystitis	72	72
Acute on chronic cholecystitis	12	12
Xanthogranulomatous cholecystitis	3	3
Cholesterolosis	3	3
Empyema (suppurative)	4	4
Adenocarcinoma	4	4
Acute cholecystitis	2	2
<b>Total</b>	<b>100</b>	<b>100</b>

Chronic cholecystitis (72%), gallstone-induced inflammation, was the most prevalent histological characteristic. 12% acute on chronic changes and six percent cholesterolosis suggested epithelial injury and lipid deposition. Inflammation with

fibrosis and foamy macrophages indicated xanthogranulomatous cholecystitis. Due to the 4% incidental cancer rate, all cholecystectomy tissues should be histopathologically examined.

### Biochemical Composition of Gallstones

**Table 6: Biochemical Classification of Gallstones**

Type of Stone	No. of Cases (n)	Percentage (%)
Mixed stones	48	48
Pigment stones	28	28
Cholesterol stones	24	24
<b>Total</b>	<b>100</b>	<b>100</b>

The most prevalent stones were mixed (48%), pigment (28%), and cholesterol (24%). This trend shows that food, infections, and bile composition produce gallstones in the analysed group.

### Correlation between Stone Type and Histopathological Findings

**Table 7: Detailed Stone type vs Histopathology**

Histopathological Diagnosis	No. of Cholesterol Stone	No. of Pigment Stone	No. of Mixed Stone	Total
Acute cholecystitis	01	00	01	02
Acute on chronic cholecystitis	02	02	08	12
Chronic cholecystitis	18	23	31	72
Cholesterosis	02	00	01	03
Empyema	00	01	03	04
Xanthogranulomatous cholecystitis	00	01	02	03
Adenocarcinoma	01	01	02	04
<b>Total</b>	<b>24</b>	<b>28</b>	<b>48</b>	<b>100</b>

Mixed stones accounted for the majority of the patients with chronic cholecystitis (43%), then followed by pigment stones (32%). Cholesterol stones were found to be more common in cholesterosis. The results of Chi-square indicated no significant correlation between stone type and histopathological pattern ( $\chi^2 = 9.95$ ,  $p = 0.445$ ), thereby indicating that stone composition was not a determinant factor for the severity of inflammation.

#### Statistical Summary

- **Age vs. Gender:** Significant association ( $\chi^2 = 11.55$ ,  $p = 0.041$ ).
- **Age vs. Stone Type:** No significant correlation ( $p = 0.445$ ).
- **Gender Distribution:** Females accounted for 78% of cases, confirming hormonal influence.
- **Histopathological Correlation:** Chronic inflammatory lesions dominated irrespective of stone composition.

This prospective study found that middle-aged women have cholelithiasis most often. Chronic cholecystitis was most common histologically. Mixed stones were the largest biochemical type, highlighting gallstone production's complexity. To detect concealed or precancerous tumours early, all cholecystectomy tissues must be examined for histological evidence of xanthogranulomatous cholecystitis and adenocarcinoma.

#### Discussion

This prospective study of 100 cholelithiasis cholecystectomy specimens sought to correlate clinical, histological, and biochemical aspects of gallbladder disease. The demographic trends, pathological characteristics, and biochemical composition of gallstones are similar with findings reported in both national and international literature. Most patients in this study were in their 40s and 50s, with an average age of 42.4, this supports [10], who reported the greatest occurrence between 41 and 50. Age-related gallbladder motility and bile acid production reductions cause bile supersaturation and cholesterol crystal formation. Cholelithiasis risk increases in middle-

aged persons, especially women, due to metabolic and hormonal variables. Women outnumbered men (78% vs. 1:3.54). These findings are consistent with [11], who reported females dominated 70–80%. Oestrogen and progesterone increase liver cholesterol release and gallbladder contractility, increasing risk in women. Oral contraceptives and multiple children increase risk. In India, women's cultural and dietary practices, such as eating too much and not exercising, may increase the gender disparity.

Clinically, dyspepsia, vomiting, nausea, and stomach pain were common. According to [12], 95% of victims had pain as the main symptom. Due to the predominance of ambiguous gastrointestinal symptoms, imaging and histology are essential for diagnosis. The study's histological examination found xanthogranulomatous cholecystitis (3%), cholesterosis (3%), acute on chronic (12%), and chronic (72%). Chronic inflammatory lesions are common on the gallbladder's mucosa and wall due to gallstone inflammation [13]. Xanthogranulomatous cholecystitis is rare but can be misinterpreted for malignancy clinically and radiologically. Biochemically, mixed gallstones made up 48%, pigment stones 28%, and cholesterol stones 24%. Similar patterns were found by [14], who found mixed stones in 45% of cases. Mixed stones prevail in India and are associated to many metabolic, viral, and environmental factors. Diets heavy in carbs and lipids, chronic infections, and bile stasis may cause mixed stones. Since stone type did not correlate with histology pattern ( $p = 0.445$ ), stone composition does not cause chronic inflammation. The stones' mechanical irritation, not their chemical composition, appears to damage the mucosa. This study discovered incidental cancer in 2% of specimens, which was noteworthy. Incidental gallbladder cancer rates range from 2 to 4% [15]. Chronic cholecystitis and gallstones are cancer risk factors due to epithelial damage, metaplasia, and dysplasia. Thus, all gallbladder specimens, regardless of clinical benignity, must be histopathologically analysed to detect premalignant and malignant tumours early.

**Table 8: Comparison of Present Study with Previous Studies on Cholelithiasis**

Author & Year	Study Population / Sample Size	Mean Age / Peak Age Group	Female: Male Ratio	Common Histopathological Findings	Predominant Stone Type	Incidental Carcinoma (%)
Study [16]	120 cholecystectomy specimens	41–50 years	3:1	Chronic cholecystitis (85%)	Mixed stones	2.5%
Study [17]	100 cases	45 years (mean)	3.6:1	Chronic cholecystitis (90%)	Pigment stones	2.0%
Study [18]	90 cases	31–50 years	3:1	Chronic cholecystitis (70%), xanthogranulomatous cholecystitis (15%)	Mixed stones	3.3%
Study [19]	110 cases	40–60 years	3.2:1	Chronic cholecystitis (78%), acute on chronic (12%).	Mixed stones	2.7%
Present Study (2020–2021)	100 cases	42.4 ± 13.1 years	3.54:1	Chronic cholecystitis (72%), acute on chronic (12%), cholesterolosis (3%), xanthogranulomatous cholecystitis (3%)	Mixed stones (48%)	2.0%

The results of this study are in concordance with several earlier Indian studies on cholelithiasis, such as study [16,17,18,19]. The age group of 4th–5th decades have highest occurrence of gallstone disease, but a distinct female dominance is noted here. The female-to-male ratio of 3.54:1 observed in our results corresponds to the hormonal and metabolic factors found in previous results.

Histopathologically, chronic cholecystitis was the most common diagnosis in all study series with an associated confirmation of a prolonged gallstone-induced mucosal irritation. Mixed stones were the most common biochemical type in our study (48%) as also observed by [18,19] which probably also indicates that multiple factors are responsible for gallstone development in Indians. Incidental finding of GBC in 2% cases in this series, will be similar to other reported incidence (2–4%) and make it evident that all cholecystectomy specimens need routine histopathological interpretation.

Gallstone disease is rising in India due to Westernised diets, faster diagnostic testing, and lifestyle changes. Preventative measures include weight control, fibre intake, saturated fat reduction, and exercise. Preventing empyema, perforation, and malignancy requires early surgical intervention and pathological investigation. This study confirms previous Indian and international studies on cholelithiasis' epidemiological and clinical features. Chronic inflammatory lesions and mixed stones emphasise the need for prevention and pathological evaluation.

### Conclusion

This prospective study of 100 cholelithiasis cholecystectomy specimens found that chronic

cholecystitis is the most common histological finding in middle-aged women. Most gallstones were mixed due to their complex metabolic and environmental aetiology. Even though most cholecystectomy specimens had benign inflammatory pathology, a small percentage had xanthogranulomatous inflammation and incidental malignancy, emphasising the necessity for regular histological examination. This study emphasises combining biochemical, histological, and clinical data to explain disease development. Lifestyle changes and early surgery can reduce gallstone morbidity. Histological examination of every gallbladder sample is necessary to diagnose chronic cholecystitis and detect premalignant or malignant tumours early. This improves patient outcomes and guides treatment.

### Reference

1. S. Sharma, B. S. Walia, M. Randhawa, A. Sharma, P. Dugg, and J. S. Pannu, "Histopathological changes in gall bladder mucosa in relation to the number and size of gallstones, and analysis of the findings in the context of age distribution of the patients: A perspective, *Ann. Hepato-Biliary-Pancreatic Surg.*, vol. 27, no. 3, pp. 277–286, 2023.
2. S. K. Shukla, P. Pant, G. Singh, Bhuvan, and K. S. Shahi, Histopathological examination of gallbladder specimens in Kumaon region of Uttarakhand, *J. Gastrointest. Cancer*, vol. 51, no. 1, pp. 121–129, 2020.
3. K. Jha et al., Outcome of routine histopathological examination of gallbladder specimen following elective laparoscopic cholecystectomy, *J. Carcinog.*, vol. 20, p. 19, 2021.

4. V. P. Bastiaenen et al., Safe, selective histopathological examination of gallbladder specimens: a systematic review, *J. Br. Surg.*, vol. 107, no. 11, pp. 1414–1428, 2020.
5. R. Goyal and I. Jialal, Diabetes Mellitus Type 2, in *StatPearls*, Treasure Island, FL: StatPearls Publishing, Jun. 19, 2022.
6. S. Das, R. Das, P. Gogoi, M. Das, A. Bhowal, and K. K. Singh, A histopathological study of gall bladder specimens in a tertiary care hospital in Assam, *Int. J. Acad. Med. Pharm.*, vol. 5, no. 5, pp. 1629–1633, 2023.
7. V. D. Kotasthane and D. S. Kotasthane, Histopathological spectrum of gall bladder diseases in cholecystectomy specimens at a rural tertiary hospital of Purvanchal in North India—does it differ from South India, *IP Arch. Cytol. Histopathol. Res.*, vol. 5, no. 1, pp. 91–95, 2020.
8. S. Garg, Gall bladder carcinoma: the value of histopathological assessment in routine cholecystectomy samples in a hospital-based study, *Int. Med.*, vol. 9, no. 3, 2023.
9. M. Lincoff, S. J. Nicholls, J. S. Riesmeyer, et al., Evacetrapib and cardiovascular outcomes in high-risk vascular disease, *New England Journal of Medicine*, vol. 376, pp. 1933–1942, 2017.
10. Ö. Öz and A. İnal, Assessment of gallbladder epithelial lesions and clinicopathological high-risk patient, *Med. J. Süleyman Demirel Univ.*, vol. 32, no. 2, pp. 177–183, 2025.
11. V. R. Vaddula, R. Kathula, and H. Kathula, A clinical pathological study on management of gall bladder stones, *Int. Arch. Integr. Med.*, vol. 7, no. 2, 2020.
12. R. Yadav, M. Sagar, S. Kumar, and S. K. Maurya, Incidental gallbladder carcinoma in north Indian population: importance of routine histopathological examination of all benign gallbladder specimens, *Cureus*, vol. 13, no. 7, 2021.
13. D. Di Mauro et al., Routine examination of gallbladder specimens after cholecystectomy: a single-centre analysis of the incidence, clinical and histopathological aspects of incidental gallbladder carcinoma, *Discov. Oncol.*, vol. 12, no. 1, p. 4, 2021.
14. R. Poudel and A. Shah, Incidence of incidental gall bladder cancer and role of routine histopathological examination in cholecystectomies specimens for benign disease, 2020.
15. K. Bora and C. J. Saikia, Clinicopathological evaluation of gallbladder lesions in cholecystectomy specimens with special emphasis on incidentally detected cases of gallbladder carcinoma: An immunohistochemical study of cytokeratin 7 and cytokeratin 20, *Asian Pac. J. Cancer Care*, vol. 8, no. 3, pp. 517–523, 2023.
16. S. K. Mathur, A. Duhan, S. Singh, et al., Correlation of gallstone characteristics with mucosal changes in gallbladder, *Tropical Gastroenterology*, vol. 33, no. 1, pp. 39–44, 2012.
17. R. Khanna, R. Chansuria, M. Kumar, et al., Histological changes in gallbladder due to stone disease, *Indian Journal of Surgery*, vol. 68, pp. 201–204, 2006.
18. H. Sharma, et al., Clinico-biochemical parameters in cholelithiasis, *International Journal of Anatomy, Radiology and Surgery*, vol. 4, no. 3, pp. 1–5, Jul. 2015.
19. S. C. Gupta, V. Misra, P. A. Singh, A. Roy, S. P. Misra, and A. K. Gupta, Gallstones and carcinoma gallbladder, *Indian Journal of Pathology and Microbiology*, vol. 43, pp. 147–154, 2000.