

Cytological-Radiological Correlation of Image Guided FNAC of Intra-Abdominal Mass Lesions: Our Experience in Tertiary Care CentreDiksha Singh¹, Anupriya Saraswat², Deepak Maini³, Dharampal Soni⁴¹Assistant Professor, Department of Pathology, JNU Medical College, Jaipur, Rajasthan, India²Resident, Department of Pathology, SPMC, Bikaner, Rajasthan, India³Senior Resident, Department of Pathology, GMC, Sriganganagar, Rajasthan, India⁴Senior Professor and Head, Department of pathology, SPMC, Bikaner, Rajasthan, India

Received: 01-02-2026 / Revised: 15-03-2026 / Accepted: 21-04-2026

Corresponding author: Dr. Anupriya Saraswat

Conflict of interest: Nil

Abstract**Background:** Fine needle aspiration cytology (FNAC) is a rapid, reliable, and inexpensive method for evaluating intra-abdominal tumours. Correlation with radiological findings enhances diagnostic accuracy.**Aims:** To assess the cytological-radiological correlation of image-guided FNAC in intra-abdominal mass lesions and to evaluate its diagnostic efficacy with reference to age and sex distribution.**Materials and Methods:** A prospective study was conducted between June 2022 and June 2024 on 95 intra-abdominal masses. Ultrasound (USG) or computed tomography (CT)-guided FNAC was performed in patients presenting with abdominal pain or lump. Radiological diagnoses were compared with cytological findings.**Results and Conclusions:** The liver was the most commonly involved organ, followed by the gall bladder. Neoplastic lesions predominated (93.69%), with malignant tumours (92.63%) far outnumbering benign ones (1.05%). Non-neoplastic lesions accounted for 6.31%. Correlation between radiological and cytological diagnosis was observed in 83 cases, while 12 were discordant. FNAC showed a sensitivity of 94.32% and a positive predictive value of 92.22%. The Kappa coefficient (0.092) indicated slight agreement between cytological and radiological diagnoses. Image-guided FNAC is a rapid, safe, and highly sensitive diagnostic procedure for intra-abdominal mass lesions. Although radiological correlation showed only slight agreement, FNAC remains a valuable tool for early and accurate diagnosis, guiding timely clinical management.**Keywords:** Fine-Needle Aspiration; Cytology; Diagnostic Imaging; Intra-Abdominal Neoplasms; Ultrasonography; Interventional; Tomography.

DOI: 10.25258/ijcpr.18.5.205

This is an Open Access article that uses a funding model which does not charge readers or their institutions for access and distributed under the terms of the Creative Commons Attribution License (<http://creativecommons.org/licenses/by/4.0>) and the Budapest Open Access Initiative (<http://www.budapestopenaccessinitiative.org/read>), which permit unrestricted use, distribution, and reproduction in any medium, provided original work is properly credited.

Introduction

Intra-abdominal masses always remain as an enigma in surgical practice. Documentary evidence of the nature of the pathology before the institution of therapy and also for prognosis is mandatory. In a majority of cases, the diagnosis which is obtained by FNAC (Fine needle aspiration cytology), is the substitute for surgical procedures like diagnostic laparotomy. [1]

FNACs are reliable, rapid and cost-effective procedure which plays an important role particularly in low resource centres as radiological examination alone proves inconclusive or leads to misdiagnosis in more than 20% cases. This provides help in guiding therapy and often leads to a complete change in the management protocol. [2] Most of the intra-abdominal masses are non-palpable and even if they are palpable, the idea of their size and shape and the extent of the lesion is

not possible by clinical examination alone. Moreover, such patients present with non-specific clinical findings like swelling or pain in the abdomen. FNAC under image guidance has brought about revolution in the field of cytological diagnosis because of its high degree of accuracy and minimum discomfort to the patient. It permits the accurate localization of non-palpable and deep-seated lesions in the body. [3]

Image guided FNAC is routinely done when single or multiple lesions are located in inaccessible sites. The techniques of image guided FNA not only permit precise anatomical imaging and targeting of lesions but also allow planning of a safe access route with constant visualization of needle tip during procedure, thereby reducing the risk of complications. Hence, image-guided FNAC should be advised for proper diagnosis and treatment. It is

very important to confirm the tissue diagnosis which is essential for both treatment as well as staging of cancer. Image guided FNA has an important role in diagnosing inflammatory, benign and malignant lesions of the abdomen.

The main advantage of FNAC is the possibility of multiple passes, which increases the chances of obtaining adequate viable cells. In this study, the cytological diagnosis was correlated with radiological data, to look for their efficacy in accurately diagnosing the intra-abdominal lesion.

Materials and Methods

This is a single centre prospective study and was conducted at our Department between June 2022 and June 2024 after institutional ethics committee approval.

Inclusion criteria included all patients irrespective of age, sex, nationality, diagnosed with intra-abdominal mass by radiography, who underwent image guided FNAC.

Exclusion criteria included inadequate specimens with handling artefacts and improper clinical record. After taking written and informed consent,

patients with complain of pain and lump in abdomen and who were diagnosed with intra-abdominal masses by radiography underwent USG or CT guided FNAC if their coagulation profile was normal. Slides were stained with hematoxylin and eosin and then examined.

Statistical analysis was performed using SPSS software version 28.0. The results are expressed as descriptive values. Kappa co-efficient was used to compare correlation between cytopathological and radiological data. Kappa result can be interpreted as follows: values ≤ 0 as indicating no agreement and 0.01–0.20 as none to slight, 0.21–0.40 as fair, 0.41–0.60 as moderate, 0.61–0.80 as substantial, and 0.81–1.00 as almost perfect agreement. Fischer’s exact test was used to compare categorical data. A p value of < 0.05 was considered statistically significant.

Results

Out of 95 patients, 39 were men and 56 were women. A total of 43 % of the cases were above 61 years of age. The youngest patient was 3 years old male child and the oldest patient was 93 years old male.

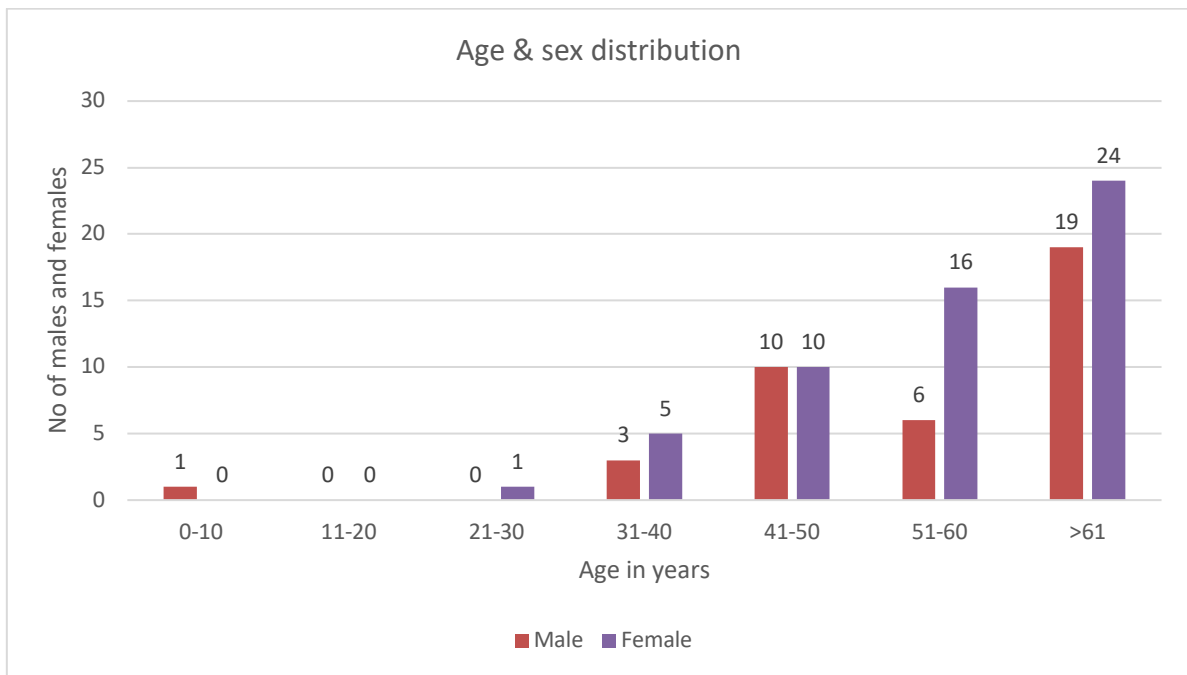


Figure 1: Shows age and sex distribution

Cases were observed across a wide age range, from childhood to elderly.

No cases were reported in the 11–20 years group, while only isolated cases occurred in the 0–10 and 21–30 years groups. A gradual rise in the number

of cases was noted from the 31–40 years group onward, with a marked increase after the age of 40 years.

The highest number of cases was seen in patients above 61 years, with 19 males and 24 females.

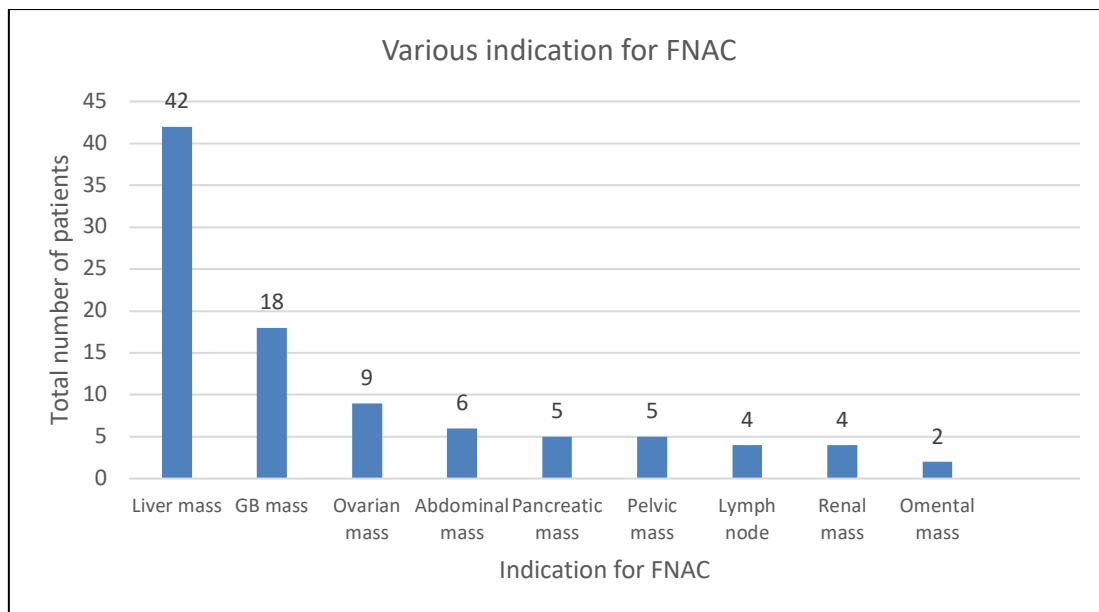


Figure 2: Shows various indications of FNAC for intra-abdominal masses.

The liver was the most common site, accounting for 42 cases, followed by the gall bladder with 18 cases. Other indications included ovarian masses (9 cases), abdominal masses (6 cases), pancreatic and pelvic masses (5 cases each), and lymph node and renal masses (4 cases each). The least common site was the omentum, with only 2 cases.

Table 1. Statistical analysis showing correlation between cytology and radiology.

	Radiology Positive	Radiology Negative	Total
Cytology Positive	78 (True Positive Agreement)	5 (Positive Disagreement)	83
Cytology Negative	7 (Negative Disagreement)	5 (True Negative Agreement)	12
Total	85	10	95

Positive agreement rate = $TP \div (TP + FN) \times 100 = 91.8\%$, Negative agreement rate = $TN \div (TN + FP) \times 100 = 41.6\%$, Overall agreement rate = $(TP + TN) \div Total \times 100 = 87.37\%$

The Kappa coefficient (κ) was calculated to assess the strength of agreement between the two diagnostic modalities. $\kappa = 0.092$, indicating slight agreement according to the Landis and Koch classification. $p = 1$, suggesting the result was not statistically significant.

These findings indicate that while cytology and radiology were highly consistent in detecting malignant lesions (high positive agreement), their ability to concurrently identify benign or non-neoplastic lesions was considerably lower (low negative agreement).

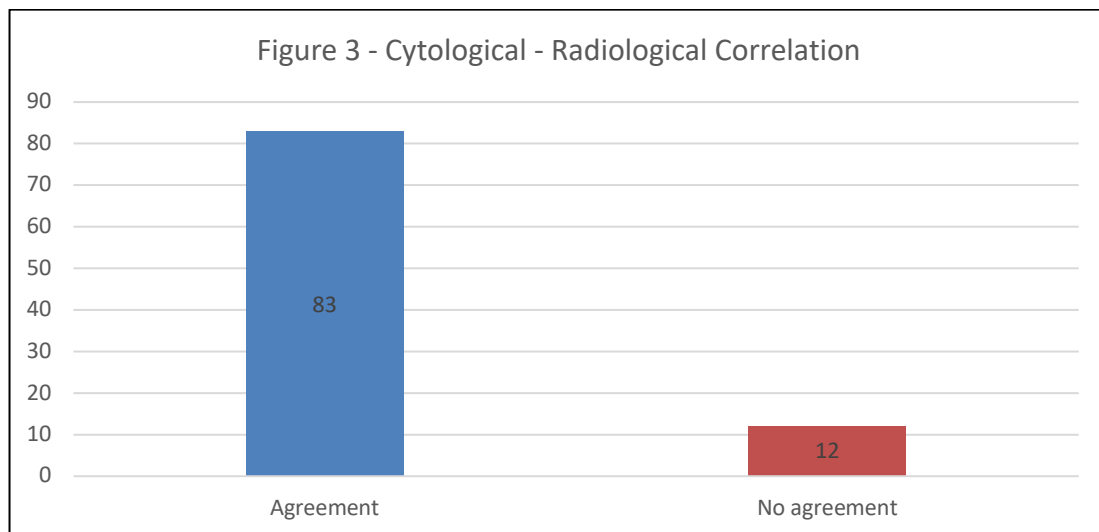


Figure 3: Showing Cytological - Radiological Correlation

Table 2: Discordant Cases between Radiological and Cytological Diagnoses

S. No.	FNAC Site	Radiological Diagnosis	Cytological Diagnosis	Discrepancy Type	Probable Reason
1.	Liver SOL	Atypical hemangioma	Metstasis – Adenocarcinoma	False negative	Indeterminate imaging or cytological pattern
2.	Ovarian mass	Solid cystic component	P/O MALIGNANCY	False negative	Indeterminate imaging or cytological pattern
3.	Adnexal tumour	Solid cystic component	P/O Malignancy	False negative	Indeterminate imaging or cytological pattern
4.	Retroperitoneal lymph node	Inflammatory ln	S/O Malignancy	False Negative	Cytology detected malignancy missed radiologically, possibly due to subtle or non-specific imaging features.
5.	Liver SOL	Lymphoma	Granulomatous inflammation	False positive	Indeterminate imaging or cytological pattern
6.	Liver SOL	Heterogenous mass in right lobe of liver p/o malignancy	Inflammatory	False Positive	Radiology over-interpreted inflammatory lesion as malignant due to overlapping imaging features.
7.	Liver SOL	Metastatic carcinomatous deposits	Inflammatory	False Positive	Radiology over-interpreted inflammatory lesion as malignant due to overlapping imaging features.
8.	Pelvic mass	Multiple intensely enhancing lesion seen in both lobes of liver p/o malignant lesion	Inflammatory	False Positive	Radiology over-interpreted inflammatory lesion as malignant due to overlapping imaging features.
9.	Liver SOL	Gb mass with liver sol p/o carcinoma	Inflammatory	False Positive	Radiology over-interpreted inflammatory lesion as malignant due to overlapping imaging features.
10.	Ovarian mass	Solid cystic lesion	P/O Malignancy	False negative	Indeterminate imaging or cytological pattern.
11.	Ovarian mass	Solid cystic lesion	P/O Malignancy	False negative	Indeterminate imaging or cytological pattern.
12.	Ovarian mass	Solid cystic lesion	P/O Malignancy	False negative	Indeterminate imaging or cytological pattern.

Out of 95 cases, twelve cases had discordance between radiological and cytological diagnosis. one case of liver was diagnosed as atypical hemangioma radiologically and as metastatic lesion cytologically.

Four cases of liver were diagnosed as malignant lesion radiologically and as inflammatory lesion cytologically. Five cases of ovarian lesions were diagnosed as solid cystic mass radiologically and as malignant lesion cytologically.

One case of pelvic mass was diagnosed as malignant lesion radiologically and as an inflammatory lesion cytologically. One case of lymph node swelling was diagnosed as inflammatory radiologically and as malignant

lesion cytologically. [Figure 3] [Table 2.] The sensitivity and positive predictive value of the cytology test is 94.32% and 92.22% respectively, indicating that it is highly effective in identifying true positives (malignant) cases. However, there was slight agreement between cytological diagnosis by image guided FNAC of intra-abdominal mass lesions and radiological diagnosis as Kappa coefficient was 0.092. The result was also statistically insignificant as P value was 1.

Discussion

FNACs are fast, accurate, and cost-effective treatment, particularly in low-resource centres where radiological examination alone is inconclusive or misdiagnosis occurs in more than

20% of patients.^[2] FNAC has a high diagnostic accuracy for intra-abdominal tumours that are deeply seated. With more than 90% sensitivity and 100% specificity, FNAC performed under ultrasonography supervision is highly efficient.

Table 3: Comparative analysis of discordance between radiological and cytological diagnosis between various studies

Study	Parajuli et al [5]	Mali et al [4]	Menka et al [6]	Chhadi et al [7]	Present study
Discordance between radiological and cytological diagnosis	2	11	8	9	12

Table 4: Comparative Analysis of Image-Guided FNAC Studies on Intra-Abdominal Masses

Author & Year	Sample Size	Most Common Site	Malignant (%)	Sensitivity (%)	Specificity (%)
Parajuli et al	106	Liver	79	92	96
Mali et al	85	Liver	67	90.9	96.1
Kumari et al	78	Liver	86	92.8	-
Gupta et al	90	Liver / GB	88	93.3	94.5
Agrahari et al	70	Liver	85.7	94	-
Shrestha et al	120	Liver	87	93.5	95
Baisakh et al	80	Liver / Ovary	90	95	97
Divya et al	100	Liver	90	94.1	96
Bohara et al	65	Liver / GB	92	96	-
Present Study	95	Liver	92.6	94.3	92.2

FNACs are fast, accurate, and cost-effective treatment, particularly in low-resource centres where radiological examination alone is inconclusive or misdiagnosis occurs in more than 20% of patients.^[2] FNAC has a high diagnostic accuracy for intra-abdominal tumours that are deeply seated. With more than 90% sensitivity and 100% specificity, FNAC performed under ultrasonography supervision is highly efficient. Our study had sensitivity and positive predictive value of 94.32% and 92.22% respectively, indicating that it is highly effective in identifying true positives (malignant) cases.

Comparative literature supports our observations. Gupta et al^[2] documented 93.3% sensitivity and 94.5% specificity. Mali et al^[4] reported 90.9% sensitivity and 96.15% PPV. Parajuli et al^[5] observed 79% malignancy with 83% concordance. Kumari et al^[8] found diagnostic accuracy of 92.8% in Bihar. Agrahari et al^[9] demonstrated improved clarity in liquid-based smears. Shrestha et al^[10] showed 93.5% accuracy in 120 cases with liver predominance, while Baisakh et al^[11] achieved 95% sensitivity and 97% specificity in 80 abdominopelvic lesions. Divya et al^[12] reported 94.1% sensitivity and 96% accuracy in 100 cases.

Bohara et al^[13] emphasized cell block preparation improving diagnostic confidence for liver and gall bladder lesions. Collectively, these studies confirm that image-guided FNAC is a robust and reproducible diagnostic technique with sensitivity ranging from 90–97%. Few complications after fine needle aspiration have been mentioned in the

Table 3. Shows comparative analysis of discordance between radiological and cytological diagnosis between various studies and our study. The results are comparable, thus further strengthening our findings.

literature, which are rare. No complications were reported in patients who underwent FNAC in our study following FNAC.

The spillage of tumour through the needle tract is not true if fine bore needle is used. Still, a lot of medical professionals are hesitant to diagnose intra-abdominal tumours with FNAC as they worry that cancer cells may spread throughout the needle tract. Malignant lesions were most common findings followed by non-neoplastic and benign lesion. Similar observations were made by Parajuli et al^[5] (79.25% malignant, 15.09% non-neoplastic and 5% benign) and Mali et al^[4] (67.65% malignant, 16.67% non-neoplastic, 15.68% benign).

Most common organ involved in present study was liver which is comparable to the study done by Parajuli et al^[5] and Mali et al^[4] Most common malignant lesion were found in the age group above 61 years of age which is comparable to study done by Parajuli et al Most common malignancy encountered in present study were metastatic lesions in liver which were similar to study done by Menka et al^[6]

Limitations of our study were:

- Single centre study.
- Factors like hypocellular smear, haemodiluted smear and excessive inflammation which hamper in making an accurate diagnosis.
- Interobserver variations in radiological and cytological reporting.

- Fewer true negative cases as FNAC is usually not recommended for cases reported as non-neoplastic on radiological examination.

Conclusion

The present study revealed a low level of agreement ($Kappa = 0.092$, $p = 1$) between cytological and radiological diagnoses of intra-abdominal masses, despite FNAC demonstrating high diagnostic sensitivity (94.32%) and predictive value (92.22%).

This finding highlights that radiological evaluation alone may not reliably distinguish between benign, inflammatory, and malignant lesions, particularly in deep-seated hepatic and ovarian masses.

The observed 12 discordant cases (12.63%) were mainly attributable to inflammatory or necrotic lesions mimicking malignancy on imaging (false positives) and indeterminate radiological patterns misinterpreting malignant lesions as benign (false negatives).

Therefore, image-guided FNAC should be regarded as a complementary and confirmatory tool to radiology rather than a substitute.

Combined radiologic–cytologic assessment significantly enhances diagnostic accuracy and guides appropriate clinical management, reducing unnecessary invasive procedures.

Key messages

- Image-guided FNAC is a rapid, safe, and cost-effective diagnostic method with high sensitivity (94.32%) and positive predictive value (92.22%) for intra-abdominal masses.
- Radiology alone is less reliable, showing only slight agreement with cytology, emphasizing the benefit of combined diagnostic approaches.
- The liver was the most common site sampled, with metastatic lesions predominating, particularly in patients above 61 years.

No complications were reported, confirming FNAC as a minimally invasive and reliable first-line diagnostic tool.

References:

1. Nautiyal S, Mishra RK, Sharma SP, Routine and ultrasound guided FNAC of intra-abdominal lumps – A comparative study. *Journal of Cytology*. 2004.
2. Gupta V, Dubey S, Gupta AK, Deshmukh G, Kariholu PL, Tripathi RP et al. Role of Image-Guided FNAC and Biopsy in Intra-abdominal and Pelvic Masses. *National Journal of Laboratory Medicine*. 2021.
3. Madhav N, Meenai FJ Role of USG guided FNAC in intra-abdominal masses-A study at tertiary care hospital Bhopal. *IP Arch Cytol Histopathol Res*. 2019.
4. Mali MHA, Anita AM, Meenakshi, Patil AG Evaluation of cell block diagnostics in intraabdominal lesions with radiological and clinical correlation in a tertiary centre in North Karnataka region. *J Evid Based Med Healthc*. 2021.
5. Parahjuli, S, Tuladhar A, Basnet R Ultrasound and computed tomography guided fine needle aspiration cytology in diagnosing intra-abdominal and intra-thoracic lesions. *Journal of Pathology of Nepal*. 2011.
6. Khanna M, Kaur K, Sharma M, Khanna A, Manjari M, Garg S, et al Cytological-Radiological Correlation of Image Guided FNAC Of Hepatic Mass Lesions: Our Experience In Tertiary Care Centre. *Annals of Pathology and Laboratory Medicine*. 2016.
7. Chhadi S, Chhadi T, Limbgaonkar J Ultrasound evaluation of non-cystic renal masses and correlation with ultrasound guided fine needle aspiration cytology/biopsy. *Int J Adv Med*. 2019.
8. Kumari N, Ranjan A. Ultrasound-guided FNAC of intra-abdominal masses in a tertiary center of Bihar, India. *Korean Assoc Hepato-Biliary-Pancreatic Surg*. 2021;25(Suppl 1): S348.
9. Agrahari R, Agarwal P, Bhalla S, Anand A, Akhtar N, Parihar A, Sonkar AA, Goel MM. Guided Needle Aspirations of Intra-Abdominal Masses. *Acta Cytol*. 2022;66(3):197–205.
10. Shrestha R, Baidya P, Paudel N, Shrestha A. Role of Image-Guided FNAC in Assessment of Intra-Abdominal and Retroperitoneal Masses. *JNGMC*. 2023;21(2).
11. Baisakh P, Baisakh MR, Kumari B et al. Diagnostic Accuracy of Ultrasonography-Guided FNAC in Abdominopelvic Masses. *Cureus*. 2023;15(6):e41228. doi: 10.7759/cureus.41228.
12. Divya KN, Biradar S, Shadaksri. Usefulness of Ultrasound-Guided FNAC in Diagnosing Intra-Abdominal Mass Lesions. *Int J Pharm Clin Res*. 2023;15(4):214–219.
13. Bohara S, Shukla P, Shah S, Chaturvedi R, Singh K. Utility of Guided FNAC and Cell Block Preparation from Liver and Gall Bladder Masses. *J Cancer Res Ther*. 2024;20(5):1459–1463.