

**A Prospective Randomised Comparative Study of Unilateral Paravertebral Block with Conventional Spinal Anesthesia for Inguinal Hernia Repair**Suvra Shankha Mukherjee<sup>1</sup>, Aparajita Sinha<sup>2</sup>, Titisha Mitra<sup>3</sup>, Manali Das Chowdhury<sup>4</sup><sup>1</sup>Assistant Professor, Department of Anaesthesiology, IQ City Medical College & Hospital, Durgapur, India<sup>2</sup>Assistant Professor, Department of Anaesthesiology, IQ City Medical College & Hospital, Durgapur, India<sup>3</sup>Senior Consultant, Department of Anaesthesiology, R. N. Tagore Hospital, Kolkata, India<sup>4</sup>Consultant, Department of Anaesthesiology, R. N. Tagore Hospital, Kolkata, India

Received: 22-03-2026 / Revised: 24-04-2026 / Accepted: 28-05-2026

Corresponding Author: Dr. Suvra Shankha Mukherjee

Conflict of interest: Nil

**Abstract:**

**Background:** Inguinal hernia repair is among the most frequently performed general surgical procedures worldwide. Spinal anesthesia remains one of the most commonly employed anesthetic techniques because of its simplicity, reliability, and rapid onset. However, spinal anesthesia is frequently associated with hypotension, urinary retention, nausea, delayed ambulation, and postoperative complications that may prolong recovery. Thoracic paravertebral block has emerged as an alternative regional anesthetic technique providing unilateral somatic and sympathetic blockade with potentially improved perioperative hemodynamic stability and postoperative recovery.

**Objective:** To compare unilateral paravertebral block with conventional spinal anesthesia in patients undergoing inguinal hernia repair with respect to intraoperative hemodynamic stability, postoperative analgesia, recovery characteristics, and perioperative complications.

**Methods:** This prospective randomized comparative study was conducted from January 2017 to December 2018 at a tertiary-level multispecialty hospital. Sixty patients undergoing elective unilateral inguinal hernia repair were randomly allocated into two groups: unilateral paravertebral block group (n=30) and spinal anesthesia group (n=30). Hemodynamic parameters, duration of analgesia, postoperative pain scores, recovery profiles, and complications were analyzed. Statistical analysis was performed using independent t-test, chi-square test, and repeated measures analysis where appropriate. A p-value <0.05 was considered statistically significant.

**Results:** Patients receiving unilateral paravertebral block demonstrated significantly lower incidence of hypotension (10.0% vs 36.7%, p=0.018), prolonged postoperative analgesia (489.2 ± 84.6 min vs 231.8 ± 56.4 min, p<0.001), earlier ambulation (5.1 ± 1.3 h vs 8.4 ± 1.8 h, p<0.001), and reduced postoperative pain scores. Hemodynamic parameters remained significantly more stable in the paravertebral group throughout the intraoperative period.

**Conclusion:** Unilateral paravertebral block provided superior postoperative analgesia, improved hemodynamic stability, earlier ambulation, and fewer complications compared with conventional spinal anesthesia during inguinal hernia repair. It may represent an effective alternative regional anesthetic technique for selected surgical patients.

**Keywords:** Paravertebral Block; Spinal Anesthesia; Inguinal Hernia Repair; Regional Anesthesia; Postoperative Analgesia; Hemodynamic Stability.

DOI: 10.25258/ijcpr.18.5.264

This is an Open Access article that uses a funding model which does not charge readers or their institutions for access and distributed under the terms of the Creative Commons Attribution License (<http://creativecommons.org/licenses/by/4.0>) and the Budapest Open Access Initiative (<http://www.budapestopenaccessinitiative.org/read>), which permit unrestricted use, distribution, and reproduction in any medium, provided original work is properly credited.

**Introduction**

Inguinal hernia repair represents one of the most commonly performed elective surgical procedures worldwide and constitutes a significant proportion of general surgical workload [1]. Appropriate anesthetic selection plays a crucial role in optimizing perioperative outcomes, postoperative recovery, patient satisfaction, and healthcare utilization [2].

Conventional spinal anesthesia remains among the most frequently employed techniques for lower abdominal procedures because of its rapid onset, predictable blockade, technical simplicity, and relatively low cost [3]. Despite these advantages, spinal anesthesia may be associated with several undesirable effects including hypotension, urinary

retention, motor blockade, delayed mobilization, nausea, and prolonged recovery room stay [4].

Growing emphasis on enhanced recovery pathways has shifted attention toward regional anesthetic techniques capable of minimizing physiological disturbance while maintaining adequate surgical anesthesia [5]. Regional techniques associated with earlier mobilization and reduced opioid requirements have gained increasing importance in modern perioperative care [6].

Paravertebral block involves injection of local anesthetic adjacent to spinal nerves as they emerge from the intervertebral foramina, producing unilateral somatic and sympathetic blockade [7]. Since its initial description, thoracic paravertebral block has been increasingly utilized in thoracic surgery, breast surgery, abdominal procedures, and postoperative analgesia [8].

The anatomical characteristics of the paravertebral space permit segmental unilateral blockade while minimizing extensive sympathetic involvement commonly observed with neuraxial techniques [9]. Consequently, paravertebral block may preserve cardiovascular stability and reduce complications related to bilateral sympathetic blockade [10].

Several studies have demonstrated effective analgesia with paravertebral techniques for abdominal and thoracic procedures, with reports suggesting reduced postoperative pain, lower opioid consumption, and improved recovery profiles [11]. The unilateral nature of paravertebral blockade may be particularly advantageous in unilateral surgical procedures such as inguinal hernia repair [12].

Inguinal hernia surgery requires adequate anesthesia involving lower thoracic and upper lumbar dermatomes, making unilateral paravertebral blockade theoretically attractive for providing targeted anesthesia while minimizing systemic physiological disturbance [13].

Despite increasing utilization of paravertebral techniques, comparative evidence evaluating unilateral paravertebral block against conventional spinal anesthesia during inguinal hernia surgery remains relatively limited, particularly in resource-constrained surgical settings [14]. Therefore, the present study was undertaken to compare unilateral paravertebral block with conventional spinal anesthesia in patients undergoing inguinal hernia repair.

## Materials and Methods

**Study Design:** This study was designed as a prospective randomized comparative study.

**Study Duration:** January 2017 to December 2018.

**Study Setting:** The study was conducted in the Department of Anaesthesiology in collaboration

with the Department of General Surgery at NH Rabindranath Tagore International Institute of Cardiac Sciences, Kolkata, a tertiary-level multispeciality hospital.

**Study Population:** Patients scheduled for elective unilateral inguinal hernia repair under regional anesthesia were screened for eligibility during the study period.

**Sample Size:** A total sample size of 60 patients (30 patients per group) was determined based on feasibility and availability of eligible patients during the study period.

**Sampling Technique:** Eligible patients meeting inclusion criteria were enrolled consecutively and subsequently randomized into study groups until the required sample size was achieved.

**Randomization:** Participants were randomly allocated into two equal groups using computer-generated random numbers.

Group P (Paravertebral Group): Unilateral paravertebral block (n = 30)

Group S (Spinal Group): Conventional spinal anesthesia (n = 30)

Allocation concealment was performed using sealed opaque envelopes opened immediately before anesthesia administration.

## Inclusion Criteria

1. Age between 18 and 70 years
2. American Society of Anesthesiologists (ASA) physical status I–III
3. Elective unilateral inguinal hernia repair
4. Willingness to participate and provide informed consent

## Exclusion Criteria

1. Refusal to participate
2. Local infection at injection site
3. Coagulopathy or anticoagulant therapy
4. Allergy to local anesthetic agents
5. Severe cardiac disease
6. Neurological disorders
7. Spine deformity preventing neuraxial block
8. Recurrent or complicated hernia

## Preoperative Assessment

All patients underwent:

- Detailed medical history
- Physical examination
- Routine hematological investigations
- Electrocardiography
- Chest radiography when indicated
- ASA grading

Patients were kept fasting according to institutional protocol.

**Anesthetic Technique:** Group P (Unilateral Paravertebral Block)

Patients were positioned sitting or lateral.

After aseptic preparation, unilateral multilevel paravertebral block was performed targeting dermatomes corresponding to surgical site (typically T10–L1 levels). A 22-gauge needle was advanced using landmark technique.

Following negative aspiration, local anesthetic solution containing:

- 0.5% bupivacaine
- Total volume 20–25 mL was administered incrementally.

Block adequacy was assessed before surgery.

Group S (Spinal Anesthesia)

Patients received conventional subarachnoid block at L3–L4 or L4–L5 interspace using:

- Hyperbaric bupivacaine 0.5%
- Dose: 3–3.5 mL (15–17.5 mg)

Sensory level adequacy was confirmed before surgical incision.

**Outcome Variables:** Primary Outcomes

- Intraoperative hemodynamic stability
- Duration of postoperative analgesia
- Secondary Outcomes
- Pain score assessment using Visual Analog Scale (VAS)
- Time to ambulation
- Incidence of hypotension
- Incidence of nausea/vomiting
- Urinary retention
- Patient satisfaction

**Definition of Variables**

**Hypotension:** Decrease in mean arterial pressure >20% from baseline or systolic BP <90 mmHg.

**Duration of Analgesia:** Time from completion of anesthesia to first rescue analgesic requirement.

**Postoperative Pain Assessment:** Pain was evaluated using VAS score (0–10):

- 2 hours
- 4 hours
- 8 hours
- 12 hours
- 24 hours

**Rescue Analgesia Protocol:** Intravenous paracetamol followed by tramadol when necessary according to institutional pain protocol.

**Statistical Analysis:** Data were analyzed using SPSS software version 24. Continuous variables were expressed as mean  $\pm$  standard deviation (SD), while categorical variables were presented as frequencies and percentages. Comparisons between continuous variables were performed using the independent t-test, whereas categorical variables were analyzed using Chi-square test or Fisher's exact test wherever appropriate. Repeated measures analysis of variance (ANOVA) was used for comparison of serial measurements recorded over time. A p-value of less than 0.05 was considered statistically significant throughout the study.

**Ethical Considerations:** Institutional Ethics Committee approval was obtained before commencement of the study.

Written informed consent was obtained from all participants prior to enrollment.

Confidentiality and anonymity of patient information were maintained throughout the study.

## Results

A total of 60 patients undergoing elective unilateral inguinal hernia repair were included in the study. Thirty patients received unilateral paravertebral block (Group P), while thirty patients received conventional spinal anesthesia (Group S). All randomized patients completed the study and were included in the final analysis.

## Baseline Characteristics of Study Participants:

Both groups demonstrated comparable baseline demographic and clinical characteristics with no statistically significant differences in age, body mass index, ASA physical status, or duration of surgery. Detailed baseline characteristics are shown in Table 1.

**Table 1: Baseline Characteristics of Study Participants**

Variable	Group P (n=30)	Group S (n=30)	p-value
Age (years)	48.7 $\pm$ 12.6	50.1 $\pm$ 11.9	0.662
Sex (Male/Female)	28 / 2	27 / 3	0.640
BMI (kg/m <sup>2</sup> )	24.8 $\pm$ 3.1	25.3 $\pm$ 3.4	0.561
ASA Physical Status I	16 (53.3%)	15 (50.0%)	
ASA Physical Status II	12 (40.0%)	13 (43.3%)	0.793
ASA Physical Status III	2 (6.7%)	2 (6.7%)	
Duration of Surgery (minutes)	63.4 $\pm$ 12.8	65.1 $\pm$ 13.5	0.618

Table 1 demonstrates comparable baseline characteristics between groups, suggesting successful randomization.

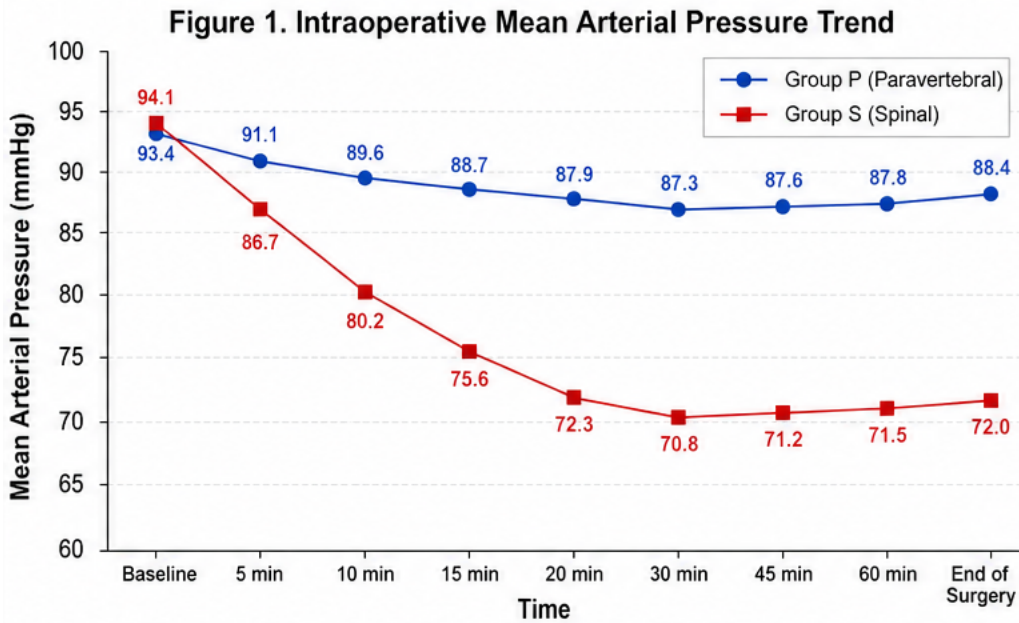
**Intraoperative Hemodynamic Parameters:** Group P demonstrated significantly better intraoperative hemodynamic profiles, characterized

by smaller reductions in mean arterial pressure and lower intraoperative heart rates compared with Group S. Mean arterial pressure reduction was more pronounced among patients receiving spinal anesthesia. Intraoperative hemodynamic trends are summarized in Table 2 and illustrated in Figure 1.

**Table 2: Intraoperative Hemodynamic Parameters**

Variable	Group P	Group S	p-value
Baseline MAP (mmHg)	93.4 ± 9.1	94.1 ± 8.8	0.774
Lowest MAP (mmHg)	84.6 ± 8.2	71.3 ± 10.1	<0.001
Mean HR intraoperative	77.2 ± 8.5	84.9 ± 9.7	0.002
Hypotension (%)	3 (10.0)	11 (36.7)	0.018

Table 2 demonstrates significantly greater hemodynamic stability in the paravertebral block group.



**Figure 1: Intraoperative Mean Arterial Pressure Trend**

Figure 1 demonstrates preservation of mean arterial pressure throughout surgery among patients receiving unilateral paravertebral block, whereas spinal anesthesia produced greater reductions in blood pressure.

**Postoperative Analgesia:** Duration of postoperative analgesia was significantly prolonged in Group P compared with Group S. Patients receiving unilateral paravertebral block required rescue analgesia considerably later. Findings are shown in Table 3 and Figure 2.

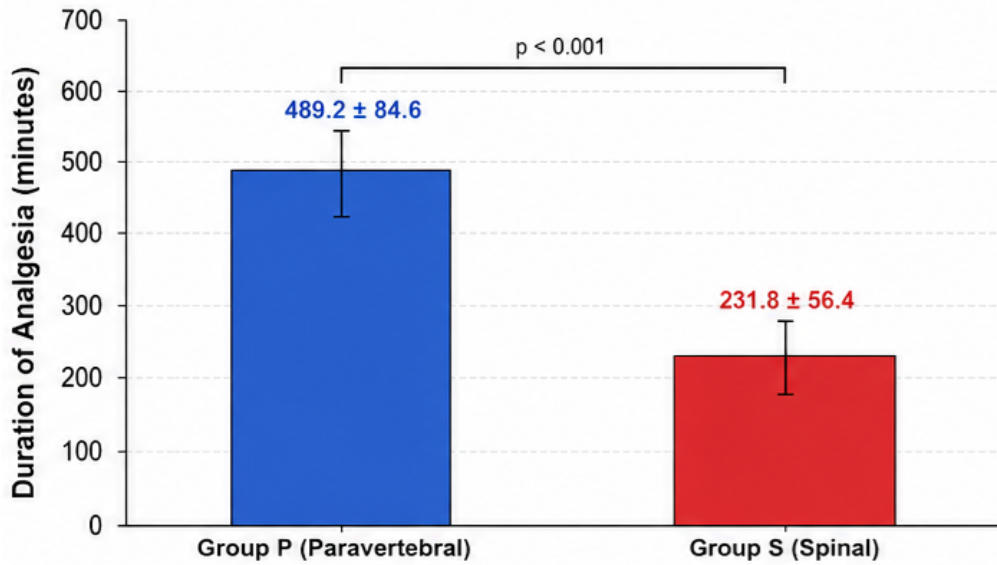
**Table 3: Postoperative Analgesic Characteristics**

Variable	Group P	Group S	p-value
Duration of Analgesia (minutes)	489.2 ± 84.6	231.8 ± 56.4	<0.001
Rescue Analgesic Requirement (%)	11 (36.7)	24 (80.0)	0.001
Total Analgesic Consumption (24 h)	1.4 ± 0.7	2.8 ± 0.9	<0.001

Table 3 demonstrates significantly prolonged analgesia and reduced analgesic requirements

among patients receiving unilateral paravertebral block.

**Figure 2. Comparison of Duration of Postoperative Analgesia Between Groups**



**Figure 2: Comparison of Duration of Postoperative Analgesia Between Groups**

Figure 2 demonstrates significantly longer analgesic duration among patients receiving unilateral paravertebral block.

**Postoperative Pain Scores:** VAS pain scores were significantly lower in Group P throughout the postoperative period. Detailed pain score comparisons are shown in Table 4.

**Table 4: Postoperative VAS Scores**

Time	Group P	Group S	p-value
2 Hours	1.8 ± 0.9	3.4 ± 1.1	<0.001
4 Hours	2.1 ± 1.0	4.1 ± 1.2	<0.001
8 Hours	2.6 ± 1.1	4.6 ± 1.4	<0.001
12 Hours	3.1 ± 1.2	4.9 ± 1.5	<0.001
24 Hours	2.8 ± 1.1	3.4 ± 1.2	0.047

Table 4 demonstrates significantly improved postoperative pain control in the paravertebral block group. Repeated measures ANOVA demonstrated a significant group–time interaction for postoperative VAS scores ( $p < 0.001$ ).

**Recovery Characteristics:** Patients receiving unilateral paravertebral block demonstrated significantly earlier mobilization and shorter recovery room stay. Findings are summarized in Table 5 and Figure 3.

**Table 5: Recovery Characteristics**

Variable	Group P	Group S	p-value
Time to Ambulation (hours)	5.1 ± 1.3	8.4 ± 1.8	<0.001
Time to Oral Intake (hours)	3.7 ± 1.1	5.4 ± 1.6	<0.001
Recovery Room Stay (minutes)	82.1 ± 21.4	126.3 ± 34.8	<0.001

Table 5 demonstrates accelerated recovery profiles in patients receiving unilateral paravertebral block.

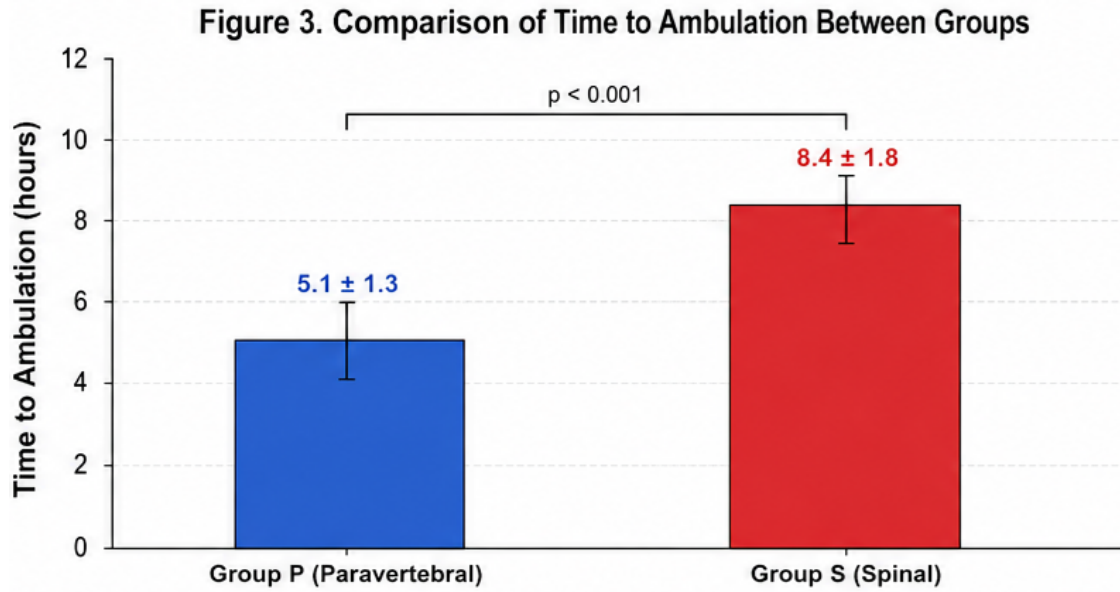


Figure 3: Comparison of Time to Ambulation Between Groups

Figure 3 illustrates significantly earlier postoperative ambulation among patients receiving unilateral paravertebral block.

**Perioperative Complications:** The incidence of perioperative complications was significantly lower

among Group P patients. Urinary retention, hypotension, nausea, and vomiting occurred more frequently in Group S. Findings are shown in Table 6.

Table 6: Perioperative Complications

Complication	Group P	Group S	p-value
Hypotension	3 (10.0%)	11 (36.7%)	0.018
Nausea/Vomiting	2 (6.7%)	8 (26.7%)	0.038
Urinary Retention	1 (3.3%)	7 (23.3%)	0.023
Block Failure	2 (6.7%)	1 (3.3%)	0.554

Table 6 demonstrates significantly fewer complications among patients receiving unilateral paravertebral block.

**Patient Satisfaction Scores:** Patient satisfaction scores were significantly higher in Group P compared with Group S. Results are shown in Table 7.

Table 7: Patient Satisfaction Scores

Variable	Group P	Group S	p-value
Satisfaction Score (0–10)	8.9 ± 0.8	7.2 ± 1.3	<0.001

Table 7 demonstrates improved patient satisfaction among patients receiving unilateral paravertebral block.

**Summary of Major Findings:** The present study demonstrated significantly improved hemodynamic stability, prolonged postoperative analgesia, earlier ambulation, lower pain scores, reduced complication rates, and improved patient satisfaction among patients receiving unilateral paravertebral block compared with conventional spinal anesthesia. These findings suggest that unilateral paravertebral block may provide superior perioperative outcomes in selected patients undergoing elective inguinal hernia repair.

**Discussion**

The present prospective randomized comparative study evaluated the efficacy and safety of unilateral paravertebral block compared with conventional spinal anesthesia in patients undergoing elective inguinal hernia repair. The findings demonstrated that unilateral paravertebral block provided superior hemodynamic stability, prolonged postoperative analgesia, earlier mobilization, reduced perioperative complications, and improved patient satisfaction compared with conventional spinal anesthesia.

One of the principal findings of the present study was significantly improved hemodynamic stability

among patients receiving unilateral paravertebral block. Patients receiving spinal anesthesia experienced a substantially greater reduction in mean arterial pressure and higher incidence of hypotension. Similar observations have been reported previously where unilateral segmental blockade provided by paravertebral techniques produced limited sympathetic blockade and consequently reduced cardiovascular instability [15]. Preservation of sympathetic tone may explain the reduced incidence of intraoperative hypotension observed in the present study.

The incidence of hypotension observed among patients receiving spinal anesthesia was considerably higher than among patients receiving paravertebral block. This finding is consistent with previous investigations demonstrating that neuraxial blockade frequently produces bilateral sympathetic blockade leading to vasodilation and hypotension, whereas unilateral regional techniques preserve hemodynamic function more effectively [16].

Postoperative analgesia was significantly prolonged among patients receiving unilateral paravertebral block. Patients in the paravertebral group demonstrated approximately twice the duration of analgesia compared with conventional spinal anesthesia. Similar findings have been described in previous studies evaluating thoracic paravertebral techniques for abdominal procedures, where prolonged sensory blockade contributed to superior postoperative pain control [17].

Postoperative pain scores remained significantly lower throughout the first postoperative day among patients receiving paravertebral block. Improved analgesic profiles following paravertebral blockade have been consistently reported in previous literature and may be attributed to sustained segmental blockade and reduced central sensitization [18].

An important finding of the present study was significantly earlier postoperative ambulation among patients receiving unilateral paravertebral block. Enhanced recovery protocols increasingly emphasize early mobilization because prolonged immobilization contributes to delayed discharge and postoperative complications. Previous studies have similarly demonstrated that regional techniques minimizing motor blockade facilitate earlier mobilization and functional recovery [19].

The incidence of postoperative nausea, vomiting, and urinary retention was significantly lower in the paravertebral group. These findings are clinically important because postoperative complications frequently contribute to delayed recovery and reduced patient satisfaction. Previous investigations have reported similar reductions in postoperative

complications with regional anesthetic techniques that avoid extensive neuraxial blockade [20].

Patient satisfaction scores were significantly greater among patients receiving unilateral paravertebral block. Improved satisfaction may reflect superior analgesia, earlier mobilization, fewer complications, and enhanced recovery profiles. Previous studies evaluating patient-centered outcomes following regional anesthesia have similarly demonstrated higher satisfaction with techniques associated with improved comfort and faster recovery [21].

The unilateral nature of paravertebral blockade may be particularly advantageous during inguinal hernia repair because surgical intervention is confined to a limited unilateral dermatomal distribution. Targeted segmental blockade minimizes unnecessary physiological disturbance while maintaining adequate surgical anesthesia [22].

The findings of the present study support growing evidence favoring regional anesthetic techniques within enhanced recovery pathways. Reduced opioid requirements, accelerated ambulation, and improved postoperative comfort observed with unilateral paravertebral block may contribute to shorter hospital stay and reduced healthcare resource utilization [23].

Although unilateral paravertebral block demonstrated several advantages, successful performance requires familiarity with anatomical landmarks and technical expertise. Block failure occurred in a small proportion of patients, highlighting the importance of operator experience and careful patient selection [24].

The present study possesses several strengths including prospective randomized design, standardized anesthetic protocols, and comprehensive perioperative assessment. However, certain limitations should be acknowledged. The study was conducted at a single center with relatively small sample size, which may limit external validity. Additionally, long-term outcomes including chronic postoperative pain and recurrence were not evaluated [25].

Overall, the present findings suggest that unilateral paravertebral block provides an effective alternative to conventional spinal anesthesia for inguinal hernia repair and may contribute to improved perioperative outcomes and enhanced recovery.

## Conclusion

The present prospective randomized comparative study demonstrated that unilateral paravertebral block provided several clinically significant advantages over conventional spinal anesthesia in patients undergoing elective inguinal hernia repair. Patients receiving unilateral paravertebral block exhibited superior intraoperative hemodynamic

stability, prolonged postoperative analgesia, lower postoperative pain scores, earlier ambulation, reduced recovery room stay, and fewer perioperative complications.

The incidence of hypotension, nausea, vomiting, and urinary retention was significantly lower among patients receiving unilateral paravertebral block, while patient satisfaction scores were significantly higher compared with conventional spinal anesthesia. These findings suggest that unilateral paravertebral block provides effective unilateral anesthesia with minimal physiological disturbance and improved postoperative recovery characteristics.

Therefore, unilateral paravertebral block may be considered a safe and effective alternative to conventional spinal anesthesia for selected patients undergoing elective inguinal hernia repair, particularly when early mobilization, enhanced recovery, and improved hemodynamic stability are desired. Further multicentric studies with larger sample sizes are recommended to validate these findings and establish standardized protocols for wider clinical application.

#### References

1. Kingsnorth A, LeBlanc K. Hernias: inguinal and incisional. *Lancet*. 2003;362(9395):1561–1571.
2. Kehlet H, Wilmore DW. Evidence-based surgical care and the evolution of fast-track surgery. *Ann Surg*. 2008;248(2):189–198.
3. Miller RD, Eriksson LI, Fleisher LA, Wiener-Kronish JP, Cohen NH, Young WL. *Miller's anesthesia*. 8th ed. Philadelphia: Elsevier; 2015.
4. Carpenter RL, Caplan RA, Brown DL, Stephenson C, Wu R. Incidence and risk factors for side effects of spinal anesthesia. *Anesthesiology*. 1992;76(6):906–916.
5. Ljungqvist O, Scott M, Fearon KC. Enhanced recovery after surgery: a review. *JAMA Surg*. 2017;152(3):292–298.
6. Kehlet H. Multimodal approach to postoperative recovery. *Curr Opin Crit Care*. 2009;15(4):355–358.
7. Karmakar MK. Thoracic paravertebral block. *Anesthesiology*. 2001;95(3):771–780.
8. Richardson J, Sabanathan S. Thoracic paravertebral analgesia. *Acta Anaesthesiol Scand*. 1995;39(8):1005–1015.
9. Lönnqvist PA, MacKenzie J, Soni AK, Conacher ID. Paravertebral blockade: failure rate and complications. *Anaesthesia*. 1995;50(9):813–815.
10. Coveney E, Weltz CR, Greengrass R, Iglehart JD, Leight GS, Steele SM, et al. Use of paravertebral block anesthesia in breast surgery. *Ann Surg*. 1998;227(4):496–501.
11. Davies RG, Myles PS, Graham JM. A comparison of analgesic efficacy and side effects of paravertebral vs epidural blockade. *Br J Anaesth*. 2006;96(4):418–426.
12. Naja ZM, Ziade MF, Lönnqvist PA. Nerve stimulator guided paravertebral blockade. *Br J Anaesth*. 2005;94(6):859–863.
13. Kulacoglu H. Current options in local anesthesia for groin hernia repair. *Acta Chir Belg*. 2011;111(5):281–285.
14. Wassef MR, Randazzo T, Ward W. The paravertebral nerve root block for inguinal herniorrhaphy. *Reg Anesth Pain Med*. 1998;23(4):451–455.
15. Greengrass R, O'Brien F, Lyerly K, Hardman D, Gleason D, D'Ercole F, et al. Paravertebral block for breast cancer surgery. *Anesth Analg*. 1996;83(4):703–710.
16. Pollard JB. Cardiac arrest during spinal anesthesia. *Reg Anesth Pain Med*. 2001;26(6):551–562.
17. Klein SM, Bergh A, Steele SM, Georgiade GS, Greengrass RA. Thoracic paravertebral block for breast surgery. *Anesth Analg*. 2000;90(6):1402–1405.
18. Richardson J, Vowden P, Sabanathan S. Bilateral paravertebral analgesia for major abdominal surgery. *Anaesthesia*. 1995;50(9):843–849.
19. Kehlet H, Dahl JB. Anaesthesia, surgery, and challenges in postoperative recovery. *Lancet*. 2003;362(9399):1921–1928.
20. Rodgers A, Walker N, Schug S, McKee A, Kehlet H, van Zundert A, et al. Reduction of postoperative mortality with neuraxial blockade. *BMJ*. 2000;321(7275):1493.
21. Wu CL, Naqibuddin M, Fleisher LA. Measurement of patient satisfaction as outcome of regional anesthesia. *Anesthesiology*. 2001;95(1):197–203.
22. Karmakar MK, Critchley LA. Continuous thoracic paravertebral infusion. *Br J Anaesth*. 2008;100(4):704–706.
23. Gustafsson UO, Scott MJ, Hubner M, Nygren J, Demartines N, Francis N, et al. Guidelines for perioperative care in enhanced recovery pathways. *World J Surg*. 2019;43(3):659–695.
24. Naja Z, El Rajab M, Al-Tannir M, Ziade F, Tayara K, Lönnqvist P. Thoracic paravertebral block technical considerations and outcomes. *Acta Anaesthesiol Scand*. 2004;48(3):328–332.
25. Blichfeldt-Eckhardt MR. Ultrasound-guided peripheral nerve blocks and regional anesthesia outcomes. *Dan Med J*. 2012;59(7):B4461.