

Empyema Thoracis – 10 Year's Experience of A Tertiary Hospital in Eastern India (2014 -2024)Bhaskar Das¹, Bhushan D. Thombre², Shilpa Gandhi³, Rajarshi Basu⁴¹Dept. of Cardiothoracic and Vascular Surgery, R. G. Kar Medical College, West Bengal, India²Dept. of Cardiothoracic and Vascular Surgery, R. G. Kar Medical College, West Bengal, India³Dept. of Cardiothoracic and Vascular Surgery, R. G. Kar Medical College, West Bengal, India⁴Dept. of Cardiothoracic and Vascular Surgery, R. G. Kar Medical College, West Bengal, India

Received: 10-04-2026 / Revised: 13-05-2026 / Accepted: 15-06-2026

Corresponding Author: Bhaskar Das

Conflict of interest: Nil

Abstract:**Background:** Empyema thoracis is defined as presence of pus in the pleural space.**Objective:** To study the clinicopathologic profile of patients with empyema thoracis including surgical interventions and final outcome.**Methods:** It is a single-centred, prospective, observational analysis of 93 patients of empyema thoracis treated in CTVS department of R. G. Kar Medical College, Kolkata, India.**Results:** Mean patient age was 48.2 years with male predominance (75.27%) and adult population being commonly involved (90.32%). 61.29% patients were of non-tubercular etiology and Klebsiella was the commonest organism isolated from the pleural fluid (19.29%). Most patients presented in Stage III empyema (75.3%). Thoracotomy and decortication were done in 85 patients (91.4%) whereas decortication with some form of lung resection was offered in remaining 8 patients. Prolonged air leak (more than 7 days) was observed in 35.48% cases post-operatively and 1 patient died due to sepsis. Average blood loss was around 600ml in perioperative period. Prolonged intercostal tube drainage was required in 26 patients (27.96%) out of whom 10 were discharged with the tube in-situ. Prolonged ICU stay beyond 3 days was needed in 8 patients and hospital stay beyond 3 weeks was observed in 13 patients. 12 patients needed a second surgery in later period.**Keywords:** Empyema, Decortication, Prolonged Air Leak.**DOI:** 10.25258/ijcpr.18.6.121

This is an Open Access article that uses a funding model which does not charge readers or their institutions for access and distributed under the terms of the Creative Commons Attribution License (<http://creativecommons.org/licenses/by/4.0>) and the Budapest Open Access Initiative (<http://www.budapestopenaccessinitiative.org/read>), which permit unrestricted use, distribution, and reproduction in any medium, provided original work is properly credited.

Introduction

Aristotle recognized the clinical entity of empyema thoracis and described its management by drainage of pus with incision, cautery and a metal tube [1]. Twenty-five centuries later, Dr. Evarts A. Graham stated in World War I Empyema Commission that an empyema should not be treated by open drainage in the "acute pneumonic phase" in order to lessen the risk of fatal pneumothorax [1]. Closed chest tube drainage of empyema had been described by Hewitt back in 1875 but came into widespread use only after Graham's report on 1918 [1].

An empyema lasting 4 weeks and beyond is classified as chronic empyema. It is divided into three stages (phases) according to 1962 classification by American Thoracic Society [2]. Stage I is acute exudative phase where the visceral pleura is elastic and dimensions of the thoracic cavity are maintained, fluid pH is usually > 7.2. Stage II is characterized by a turbid, infected fluid with fibrin deposits that septate the effusion, creating multiple loculations, fluid pH is usually < 7.2 with

presence of bacterial organisms [2]. In Stage III there is fibroblastic growth which forms thick peel over the lung and prevents expansion and requires definitive surgical intervention, i.e., decortication with or without lung resection and/ or pleural space obliteration procedures like thoracoplasty [2]. Empyema may also be classified as - primary (no underlying aetiology) and secondary (following trauma or surgery). Tubercular empyema is an important cause of concern in India apart from parapneumonic effusions, trauma and post-surgical cases.

Surgical treatment for empyema thoracis is well known since the time of Hippocrates (460 - 377 BC). He accomplished drainage of empyema through the intercostal space after resection of one rib [1]. Intercostal drainage still remains the initial, widely-accepted treatment modality [1].

Effective management of empyema requires control of infection and sepsis by appropriate antibiotic therapy, evacuation of pus from the pleural space

and obliteration of the empyema cavity and re-expansion of the underlying lung to restore its function [2]. This can be achieved by decortication of the thick pleural peel. In some cases of long-standing empyema, lung fails to expand even after thorough decortication. Thoracoplasty is reserved for such selected cases with problems of persistent residual space. Early recognition is crucial for successful outcome of empyema. Even with appropriate treatment, mortality from empyema may be as high as 15-20% [3].

Aims: To study the clinicopathologic profile of empyema thoracis and various surgical interventions along with their outcome.

Objectives

1. To study the demographic profile of the patients
2. To note the etiology of empyema
3. To study the clinical presentation and relevant investigations
4. To enlist the surgical interventions performed
5. To note down various complications (intraoperative and postoperative) and their management
6. To study the secondary operation(s) performed (whenever needed).
7. To follow-up the patients for a period of minimum 12 months and assess the final outcome.

Materials and Methods

Our study comprised of 93 patients of empyema thoracis in stage 3 requiring some form of surgical intervention. All the patients were examined and investigated with routine blood tests, chest X-ray, CT scan thorax and pulmonary function test. Fiberoptic bronchoscopy and study of BAL fluid and bronchial brushing were done in every patient. Bacteriological culture with antibiotic sensitivity testing of the pleural fluid and BAL fluid were routinely done. Special emphasis was given to exclude active tubercular disease. Intercostal tube drain was put during the pre-operative period in most of the patients to reduce the septic burden and relieve respiratory discomfort. All the patients were

posted for elective surgery. Lung isolation with double lumen endobronchial tube was routinely performed in all adult patients. Posterolateral thoracotomy was done in conventional fashion. Entry into pleural space was usually difficult in long standing cases due to thick pleural peel and lung adhesion to the parietes. Lung expansion was assessed on table after thorough decortication and diseased, non-expanding segments were resected. Chest closure was done in conventional fashion after placing two intercostal drains. Patients were kept on mechanical ventilation in the post operative period as and when needed. Chest X-ray was done routinely after 24 hours, 48 hours and after removal of drains before discharge and subsequently whenever needed. All the patients were followed up at 1 month, 3 months, 6 months and 12 months following surgery.

Inclusion Criteria

It is a Single-centred, prospective, descriptive, observational study on 93 patients of diagnosed empyema thoracis in CTVS department of R. G. Kar Medical College, Kolkata, India (1400 bedded tertiary level Government hospital of Eastern India) between January 2014 to December 2020. Patients referred from various other departments like Respiratory Medicine, General Medicine and General Surgery were also included along with patients of CTVS department.

Exclusion Criteria

1. Early Stage I empyema patients – Those who were managed with chest drain only and did not require any other surgical intervention.
2. Post operative cases of empyema (Following other thoracic surgical procedures like pneumonectomy, lobectomy etc)
3. Malignant pleural effusion and empyema
4. Patients with comorbidities like ischemic heart disease, chronic kidney disease and chronic liver disease which may significantly affect the outcome of surgery.

Results and Observations

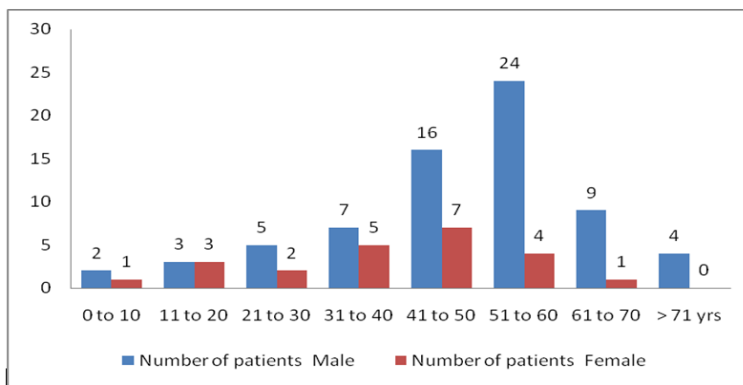


Figure 1: Bar diagram showing age and sex distribution

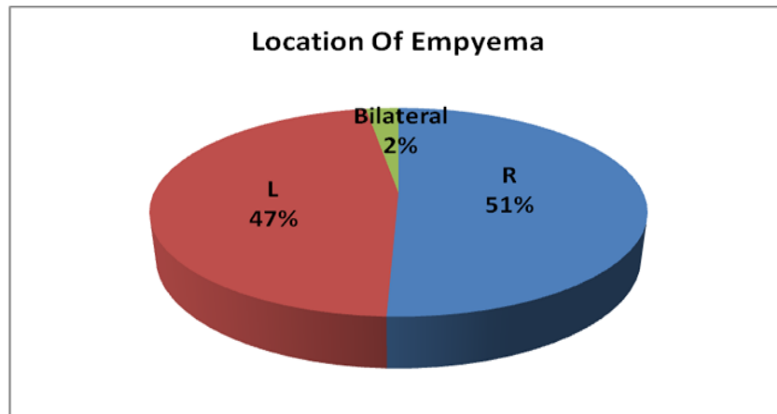


Figure 2: Pie diagram showing location of empyema

Table 1: Table showing patient stratification according to aetiology

Non infective	Post-traumatic – sequel of hemothorax	8
Infective	Tubercular (MDR – 2, Cat II-4)	28
	Nontubercular	53
	No organism on culture of pleural or BAL fluid	24
	Specific Organism on culture (Pseudomonas, Klebsiella, Acinetobacter etc.)	29
Others	Ruptured Hydatid cyst	01
	Ruptured amoebic liver abscess	01
	Post oesophageal injury following dilatation for corrosive stricture	02

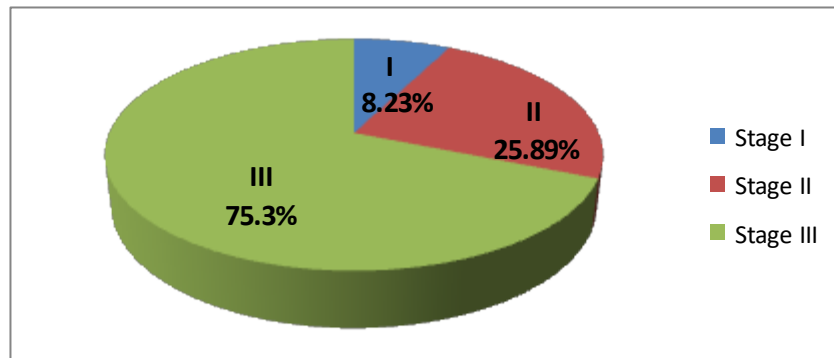


Figure 3: Pie diagram showing patient category in infective parapneumonic empyema

Table 2: Comorbidities and addictions –

Diabetes mellitus	17
Hypertension	18
Hypothyroidism	04
Tobacco use	Smoking – 21, Khaini, Gutka, Jarda etc – 8
Alcohol abuse	07

Table 3: Surgical treatment offered

Decortication	85	VATS (9) Open thoracotomy (76)
Decortication with lung resection (All performed through open thoracotomy)	8	Segmentectomy (2) Bisegmentectomy (3) Lobectomy (2) Pneumonectomy (1)

1. Average blood loss was around 600 ml (Mean – 606.34 ml, S.D. – 138.58 ml)
2. Postoperative complications-
 - a. Uneventful – 58 patients
 - b. Prolonged air leak (Beyond 14 days) – 26 patients
 - c. Persistent residual space with air leak – 12 patients
 - d. Bleeding – 3 patients
 - e. Surgical site infection – 11 patients

f. Sepsis – 2 patients

g. Death – 1 patient

Table 4: Second surgery – (n = 12)

Re-do decortication	2
Lung resection (pneumonectomy -1, lobectomy -1, bisegmentectomy-1)	3
Open window thoracostomy (Clagett)	2
Thoracoplasty	5

3. Prolonged post-operative Intercostal Drain (> 2 weeks) - 26 patients.

5. Prolonged hospital stay (> 3 weeks) – 13 patients.

4. Prolonged ICU stay (> 3 days) – 8 patients.

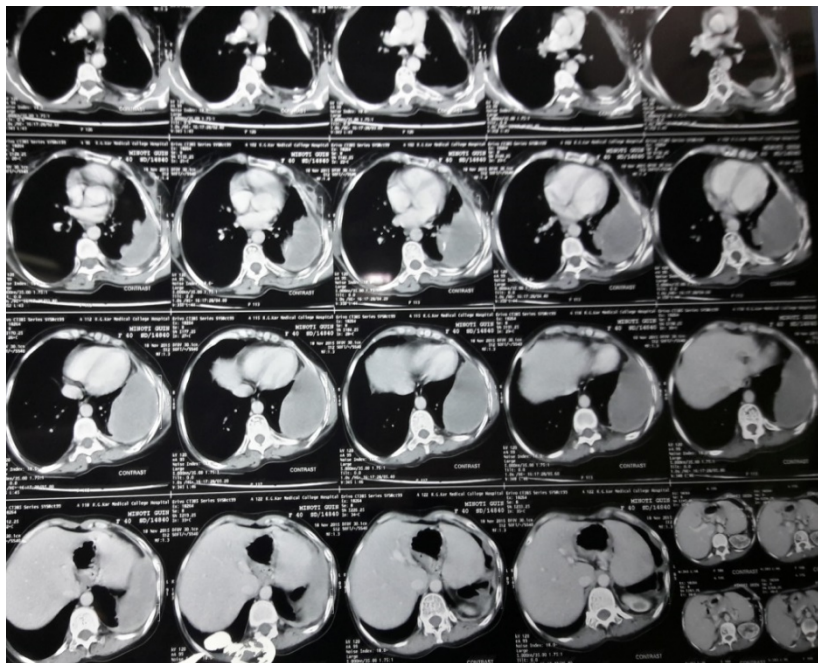


Figure 4: CT scan of Empyema thoracis

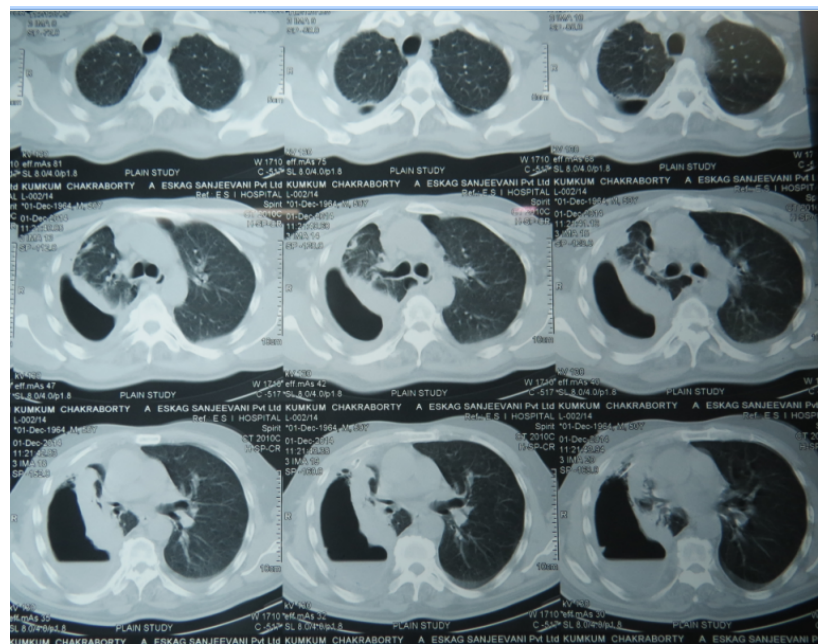


Figure 5: CT scan of Empyema thoracis

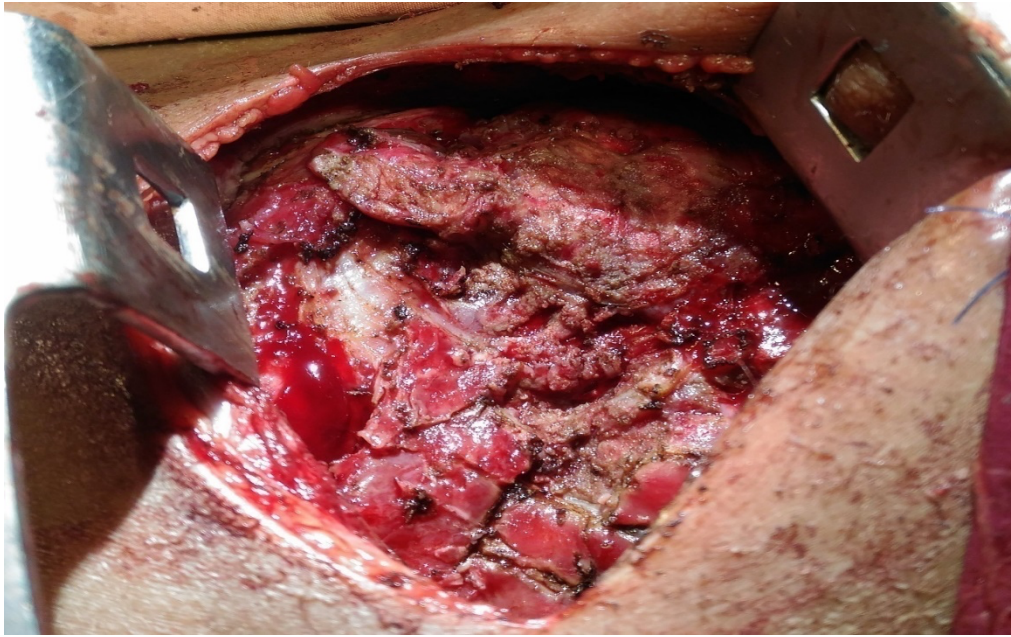


Figure 6: Decortication surgery by open thoracotomy

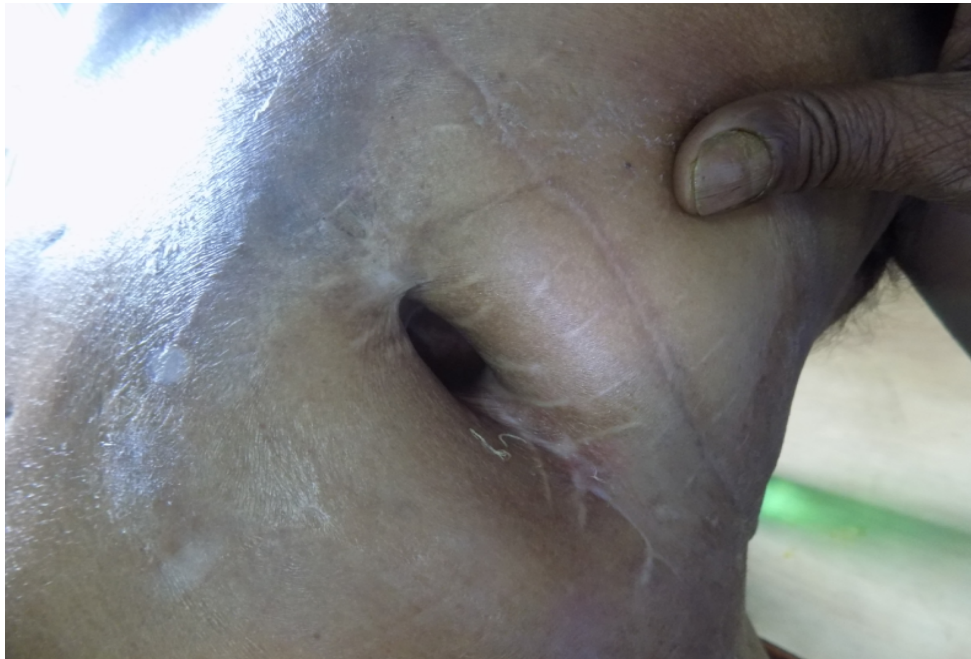

Figure 7: Pleurocutaneous window

Discussion

We found mean patient age was 48.2 years (maximum = 74 years, minimum = 18 months). Shin et al in his study in Korea, on 111 empyema patients observed mean age of 56.1 ± 20 years with 88 patients (79.3%) being male and parapneumonic effusion as the most common aetiology i.e. 65.8% [4]. Right sided location of empyema was seen in 51% of our patients whereas 2 patients had bilateral disease.

75.3% patients in our study presented in Stage III which was 61% in Shin et al group from Korea [4]. Parapneumonic empyema was commoner (~61.3%).

Molnar, in his review article has attributed parapneumonic empyema as more common aetiology contributing 40-60% cases [6]. Klebsiella (19.29%) was the commonest organism isolated in the nontubercular parapneumonic category in our study. It has been stated in old articles that Klebsiella pneumonia and empyema occur commonly in alcoholics or in immunocompromised hosts [1]. Pseudomonas was noted in 15.79% and Acinetobacter in 12.28% patients in our study. Staphylococcus aureus was commonly isolated (23.9%) in a study performed in IPGMER, Kolkata in 2010 by a group of chest physicians as against 10.53% in our series [5]. In nearly half of the

patient's pleural fluid culture was negative for any micro-organism. One patient had parasite infection (ruptured amoebic liver abscess). 28 cases (29.41%) were tubercular in origin. However, 2 patients were multi-drug resistant and 4 others were already on category II continuation phase when referred for surgical treatment. All the tubercular patients underwent surgical intervention after the intensive phase was completed. We encountered 8.6% cases were post-traumatic – following blunt or penetrating chest injury whereas Idris Ali and Helmet Unruh had noted 5% among 65 adult empyema patients to be post traumatic in aetiology [7]. However, Mandal et al noticed only 1.6% of these cases over a span of 24 years among 5474 trauma patients [8].

Timely surgical intervention - decortication has been shown to be the treatment of choice in majority of the studies and has been the critical determining factor for successful outcome [4]. Decortication only was sufficient in 91.39% (n=85) patients and majority were done by open thoracotomy (76 cases out of 85; 89.41%). Shin et al had performed open decortication in 88.9% of their patients [4].

Decortication with lung resection was done in 8 patients as primary treatment. 2 patients underwent segmentectomy followed by redo bisegmentectomy in 1 of these patients after 8 weeks. 3 patients underwent bisegmentectomy as primary procedure but 1 out of them required a redo lobectomy (right lower lobe). Similarly, 3 patients underwent lobectomy (right middle lobe, left lingual, left lower lobe) but one of them had to undergo a re-do procedure - pneumonectomy due to persistent space and non-expanding fibrotic lung.

75% patients in our study presented in Stage III disease where the chronic fibrotic peel had led to trapping of lung with intraparenchymal fibrosis. It is difficult to complete the procedure by VATS in these patients due to extensive fibrosis and usually conversion to open thoracotomy is required. We could complete VATS decortication in 9 patients (9.68%) - 6 patients of post-traumatic hemothorax with empyema and 3 cases of loculated nontubercular empyema. All these patients had good post-operative course in the form of shorter hospital stay, shorter chest tube drainage and earlier discharge from the hospital. This also asserts that VATS is definitely comparable and to some extent superior in selected patients for empyema surgery [4, 6, 10, 11]. We had to convert from VATS to open thoracotomy in another 13 patients.

The overall most common complication observed was prolonged air leak. Air leak beyond 7 days was noted in 33 patients (35.48%). Persistent air leak beyond 2 weeks was seen in 26 patients of whom 12 patients also had persistent space problems. Majority of these patients were managed conservatively with prolonged intercostal drainage,

fiberoptic bronchoscopy and toileting, chest physiotherapy, incentive spirometry. Among the 26 patients with prolonged intercostal drainage of more than 2 weeks 10 patients had post tubercular empyema (35.71%), 3 had traumatic hemothorax (22.22%) and 13 had parapneumonic effusion (22.8%). 10 of these patients were discharged with the tube in-situ and then removed on follow-up at 1 month in OPD.

Persistent space problem with incomplete expansion of the lung with persistent drainage with or without air leak was encountered in 12 patients (n=12, 12.9%). They were taken up for some form of definitive or palliative redo surgery. They were done after 2 - 3 months once the general condition and nutritional status was built up along with appropriate chest physiotherapy. Redo thoracotomy and decortication was offered in 5 patients. In 2 patients only redo decortication was done. In 3 patients diseased nonexpanding lung portions were excised (1-bisegmentectomy, 1-lobectomy and 1-pneumonectomy). 2 patients were managed with open window thoracostomy done after 8 weeks. Another 5 similar patients were treated with thoracoplasty after 3 months. Thoracoplasty was our surgery of choice for space reduction over myoplasty. Role of thoracoplasty in managing patients of empyema thoracis has been nicely elucidated by R. K. Dewan et al in their study [9].

4 patients developed bleeding in the immediate postoperative period (>1500ml in 12 hours) of whom 2 patients required reexploration. 2 patients developed sepsis out of whom 1 patient eventually died on 10th post-operative day due to multi organ dysfunction. 11 patients had surgical site infection of varying severities. They were managed conservatively with appropriate antibiotics and regular dressing. 2 patients among them required secondary suturing and closure of the wound. Prolonged intensive care of more than 3 days was required for 8 patients. The reasons for this were mostly various medical problems in 6 patients and 2 were the patients of reexploration. Prolonged hospital stay of more than 3 weeks was seen in 11 patients -11.83%.

Limitations

In this study we did not include patients with significant comorbidities like ischemic heart disease, chronic kidney disease and chronic liver disease that may influence the outcome of the surgical intervention. Moreover, we did not analyse the results i.e. post operative outcome in relation to pre-existing lung diseases like COPD, smoking and interstitial lung diseases from occupational exposures etc. To analyse the influence of these factors on the final outcome of surgery we need to stratify the patients in various subgroups with comparable parameters. We could not also draw any

comparison in the outcome between tubercular and non-tubercular patients. As pulmonary tuberculosis including drug resistant variants are so common in India, we firmly believe that a comparative study in this regard can yield interesting facts. Last but not the least we did not interpret the results as VATS versus Open thoracotomy group. As empyema thoracis is a common clinical entity we believe that there is a lot of scope to undertake similar studies, particularly comparative studies to address these issues.

Summary and Conclusion

We studied a series of 93 diagnosed empyema thoracis patients at the Cardiothoracic & Vascular Surgery department of RG Kar Medical College, Kolkata, India. Common causes of empyema thoracis include parapneumonic effusion with *M. tuberculosis* being the single most common organism and post traumatic empyema. There is a male preponderance as found in various studies. Most of the patients in stage II and beyond require definitive surgical intervention. Active infection should be adequately treated with appropriate antimicrobials before contemplating surgery. Open thoracotomy and thorough decortication remain the gold standard treatment. Strong adhesion of the underlying lungs with the parietes pose great challenge to accomplish the procedure by VATS or minimal access methods and it requires special surgical skill. In long standing cases surgery becomes challenging as the lungs often fail to expand completely due to underlying fibrosis. In those cases, limited lung resection may be needed to get rid of the diseased segments. Careful monitoring and postoperative management are extremely important for successful outcome. Vigorous chest physiotherapy and breathing exercise form the mainstay of care. Early mobilisation, nutritional supplementation and appropriate choice of antibiotics are equally important. Prolonged air leak is common in post operative period, however, mostly resolve with conservative management. Some patients may require a second surgery for persistent space problems which include lung

resection or thoracoplasty. The overall outcome is good and satisfactory particularly if the definitive surgery is performed early.

References

1. R. Bryant, C. Salmon. Pleural Empyema. The State-of-the-Art Clinical Article. CID 1996.
2. Lei Yu, Mark J. Krasna. Parapneumonic Empyema. In: Shields TW General Thoracic Surgery. 7th ed. Philadelphia: Lippincott Williams and Wilkins. 2009;776-780.
3. John A. M. Gotthard Bulau and Closed Water-Seal Drainage for Empyema. 1875–1891. The Ann of Thorac Surg. 48(4);1989:597-599.
4. Jung Ar Shin, Yoon Soo Chang, Tae Hoon Kim et al. Surgical decortication as the first line treatment for pleural empyema. Journal of Thorac Cardiovasc Surg. 2013;145(4):933-939.
5. Kundu S, Mitra S, Mukherjee S, Das S. Adult thoracic empyema: A comparative analysis of tuberculous and nontuberculous aetiology in 75 patients. Lung India. 2010;27:196-201.
6. Thomas Molnar. Current surgical treatment of thoracic empyema in adults-Review. Euro J of Cardiothorac Surg. 2007(32):422-430.
7. Idris Ali, Helmet Unruh. Management of Empyema. Ann of Thorac Surg. 1990; 50:355-9
8. Mandal AK, Thadepalli et al. Outcome of primary empyema thoracis: therapeutic and microbiologic aspects. Ann Thorac Surg. 1998; 66(5):1782-6.
9. R.K. Dewan, Sanjay Singh. Thoracoplasty-An obsolete procedure? Indian J Chest Dis Allied Sciences. 1999; 41:83-88.
10. Betty Tong, Jeniffer Hanna et al. Outcomes of Video-assisted thoracoscopic Decortication. Ann Thorac Surg. 2010; 89:220-5.
11. Anthony Chambers, Marco Scarci. Is Video-assisted thoracoscopic surgical decortication superior to open surgery in the management of adult empyema? Interact Cardiovasc and Thorac Surg. 2010:171-177.