

Varied Clinical Spectrum of Meckel's Diverticulum in Children: A Descriptive Observational Study

Abirami Krithiga Jayakumar¹, K. Prasanna²

¹Assistant Professor, Department of General Surgery, Tagore Medical College & Hospital, Chennai, Tamil Nadu, India

²Assistant Professor, Department of Radio diagnosis, Tagore Medical College & Hospital, Chennai, Tamil Nadu, India

Received: 01-03-2026 / Revised: 15-04-2026 / Accepted: 21-05-2026

Corresponding author: Dr. Abirami Krithiga Jayakumar

Conflict of interest: Nil

Abstract

Background: Meckel's diverticulum (MD) is the most common congenital anomaly of the gastrointestinal tract with diverse clinical presentations in children, often mimicking other surgical conditions.

Aim: To describe the varied clinical presentations, management strategies, and outcomes of pediatric patients with Meckel's diverticulum.

Methods: A descriptive observational study of nine pediatric patients diagnosed with Meckel's diverticulum. Clinical presentation, intraoperative findings, surgical management, and outcomes were analyzed.

Results: Presentations included perforation peritonitis (22.2%), intussusception (22.2%), umbilical granuloma (22.2%), and small bowel obstruction (11.1%), gastrointestinal bleeding (11.1%), inflamed Meckel's with appendicitis (11.1%), and neonatal presentation (11.1%). Surgical management primarily involved segmental resection and anastomosis. Mean hospital stay was 4 days with no major complications.

Conclusion: Meckel's diverticulum presents with a wide clinical spectrum in children. Early diagnosis and appropriate surgical management result in excellent outcomes. Minimally invasive approaches are safe and effective.

Keywords: Meckel's Diverticulum; Pediatric Surgery; Intussusception; Gastrointestinal Bleeding; Small Bowel Obstruction; Laparoscopy.

DOI: 10.25258/ijcpr.18.6.166

This is an Open Access article that uses a funding model which does not charge readers or their institutions for access and distributed under the terms of the Creative Commons Attribution License (<http://creativecommons.org/licenses/by/4.0>) and the Budapest Open Access Initiative (<http://www.budapestopenaccessinitiative.org/read>), which permit unrestricted use, distribution, and reproduction in any medium, provided original work is properly credited.

Introduction

Meckel's diverticulum is one of the most common congenital anomalies of the gastrointestinal tract and represents the most frequent anomaly of the vitelline duct. [1,2] It results from incomplete obliteration of the vitellointestinal duct and may remain asymptomatic or present with complications.

The clinical manifestations vary widely depending on age, presence of ectopic mucosa, and associated complications. This variability often poses diagnostic challenges. This study aims to describe the spectrum of clinical presentations and management outcomes of Meckel's diverticulum in children.

Materials and Methods

This descriptive observational study included nine pediatric patients diagnosed with Meckel's diverticulum at a tertiary pediatric surgical center.

Data collected are 1. Age and sex 2. Clinical presentation 3. Intraoperative findings 4. Surgical management 5. Postoperative outcomes

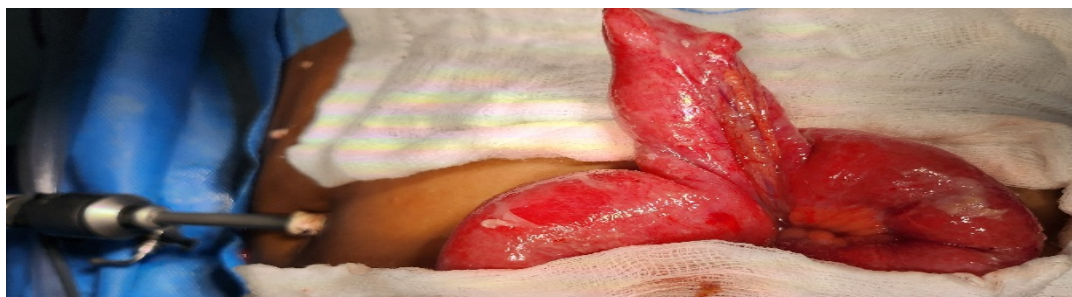All patients were managed according to standard pediatric surgical protocols.

Results

The clinical spectrum included two cases each of perforation peritonitis, intussusception, and umbilical granuloma, and one case each of small bowel obstruction, gastrointestinal bleeding, inflamed Meckel's diverticulum associated with appendicitis, and Meckel's diverticulum identified in a neonate with gastroschisis.

Table 1: Patient Characteristics, Clinical Presentation, Surgical Management, and Outcomes

Case	Age/Sex	Clinical Presentation	Intraoperative Findings	Surgical Management	Outcome
1	7 years/M	Acute abdomen with perforated appendicitis	Inflamed Meckel's diverticulum associated with perforated appendix	Laparoscopic appendectomy with laparoscopic-assisted Meckel's diverticulectomy, segmental resection, and primary anastomosis	Uneventful recovery
2	7 months/F	Perforation peritonitis	Perforated Meckel's diverticulum with peritoneal contamination	Exploratory laparotomy, segmental ileal resection, primary anastomosis, and peritoneal lavage	Uneventful recovery
3	Newborn/M	Gastroschisis	Aborted Meckel's diverticulum within exteriorized bowel loops	Primary resection on day 1 of life	Stable recovery
4	5 years/M	Painless hematochezia	Meckel's diverticulum identified as source of gastrointestinal bleeding	Laparoscopic-assisted segmental resection and primary anastomosis	Uneventful recovery
5	2 years/M	Bilious vomiting and small bowel obstruction	Distal jejunal and proximal ileal obstruction secondary to Meckel's diverticulum without bowel ischemia	Exploratory laparotomy, segmental resection, and primary anastomosis	Uneventful recovery
6	8 months/M	Intussusception with failed hydrostatic reduction	Intussusception associated with Meckel's diverticulum and vitelline band	Exploratory laparotomy, segmental resection, and primary anastomosis	Uneventful recovery
7	2.5 years/M	Long-segment small bowel intussusception with chronic anemia	Meckel's diverticulum acting as pathological lead point	Laparoscopic-assisted segmental resection and primary anastomosis	Resolution of anemia and uneventful recovery
8	Infant/F	Persistent umbilical discharge	Umbilical granuloma	Conservative management with common salt application	Complete resolution
9	Infant/M	Persistent umbilical discharge	Umbilical granuloma	Conservative management with common salt application	Complete resolution

Spectrum of Meckel's Diverticulum:**Figure 1 (A): Inflamed Meckel's diverticulum with perforated appendicitis**

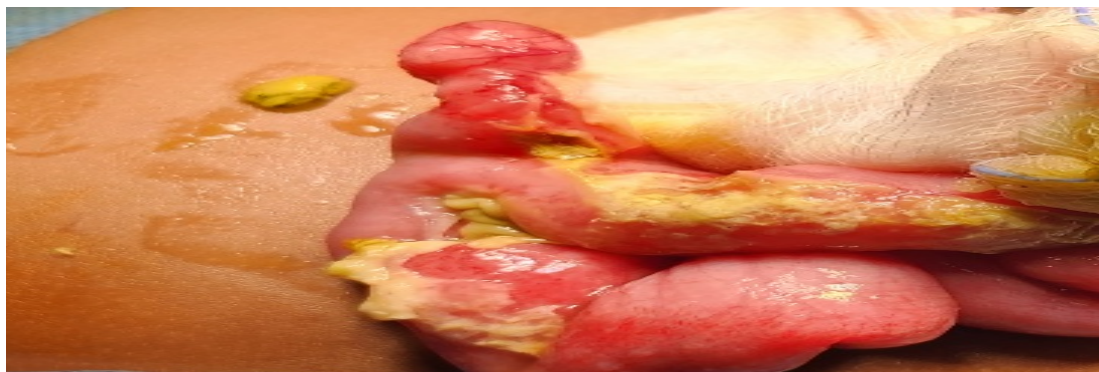

Figure 1 (B): Perforated Meckel's diverticulum

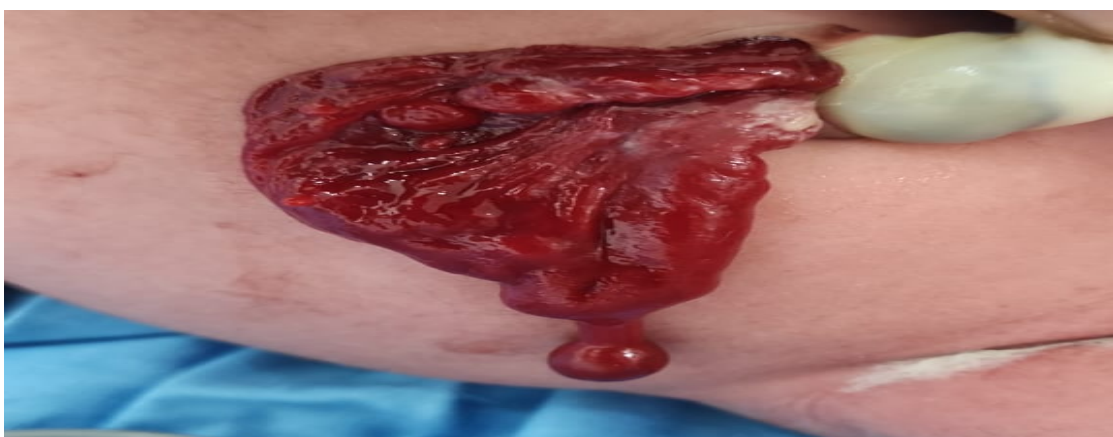

Figure 1 (C): Neonatal Meckel's in gastroschisis

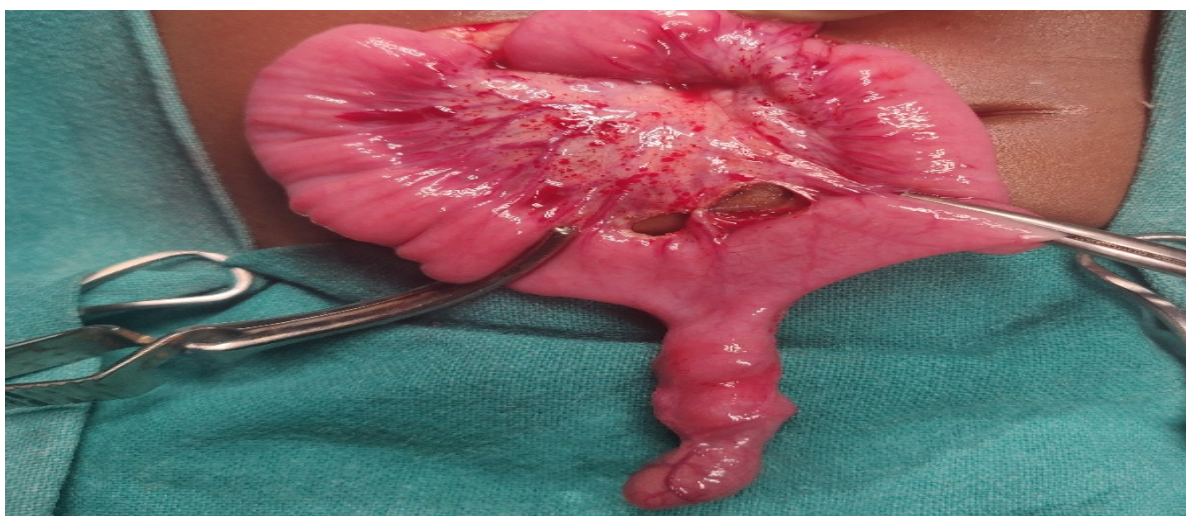


Figure 1 (D): Meckel's presenting with bleeding

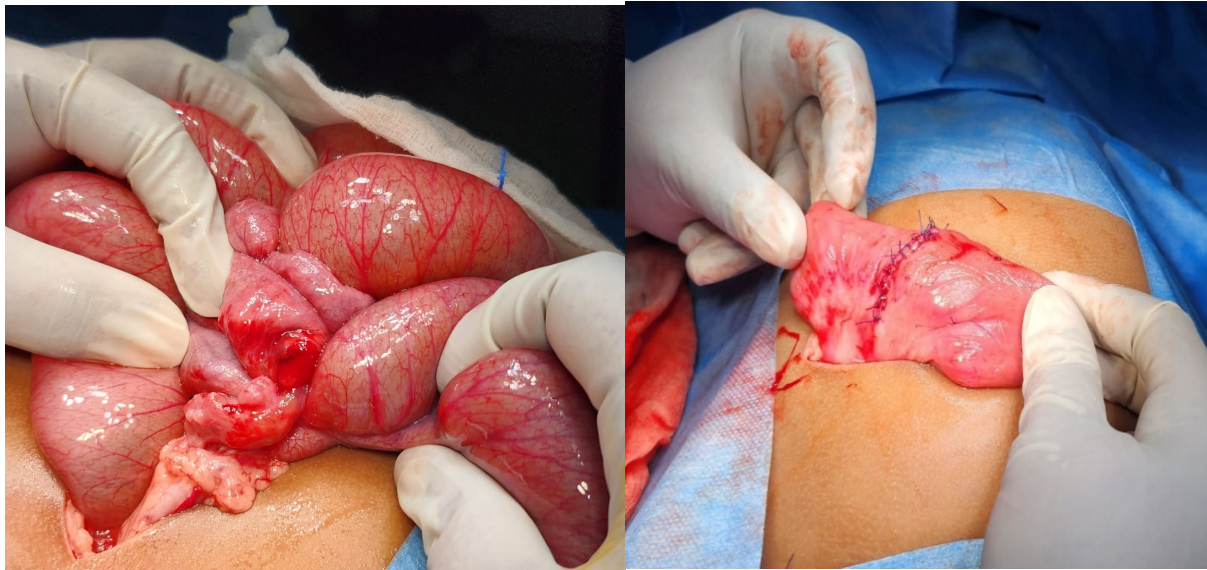


Figure 1 (E, F): Small bowel obstruction due to Meckel's

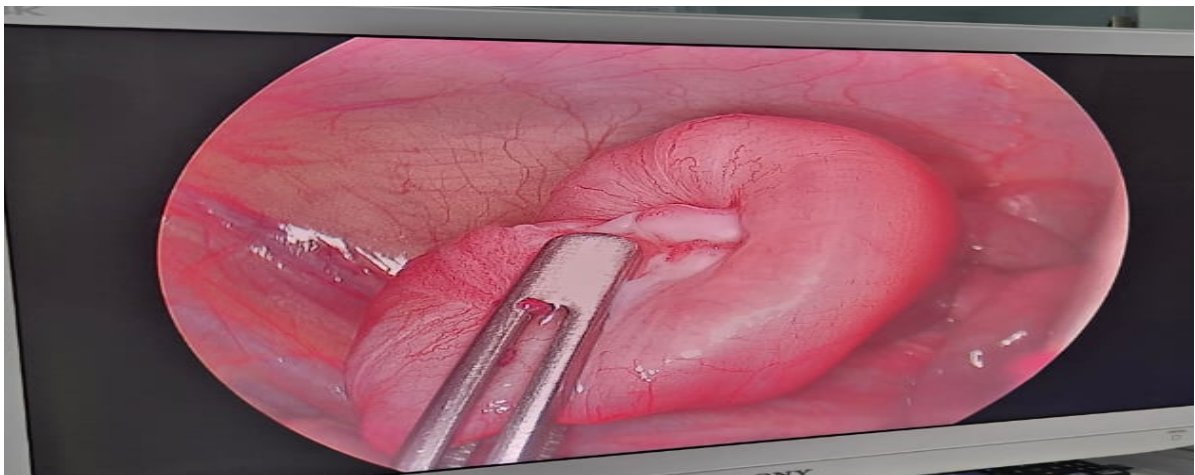


Figure 1 (G): Intussusception (failed hydrostatic reduction)

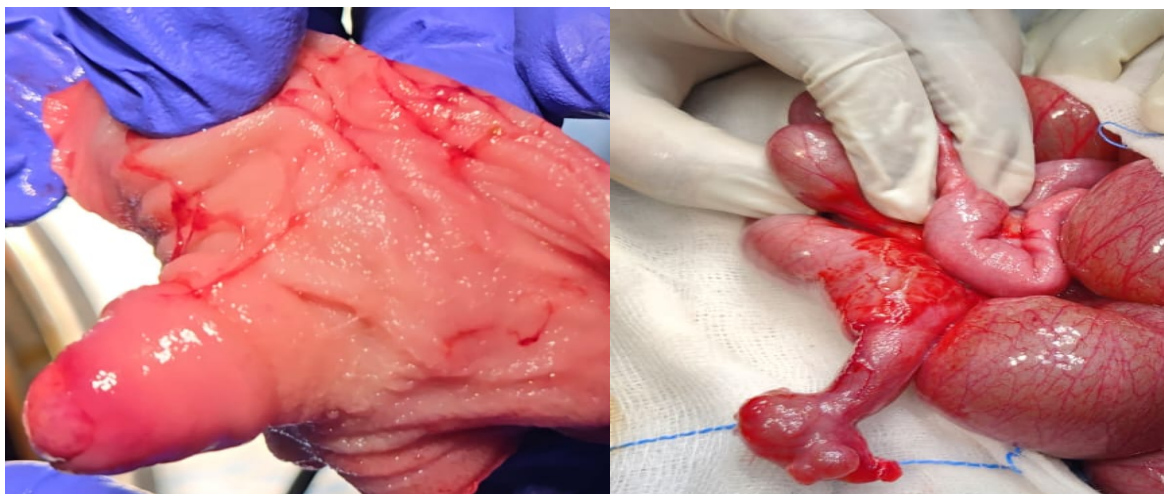


Figure 1 (H, I): Intussusception with chronic anemia and specimen

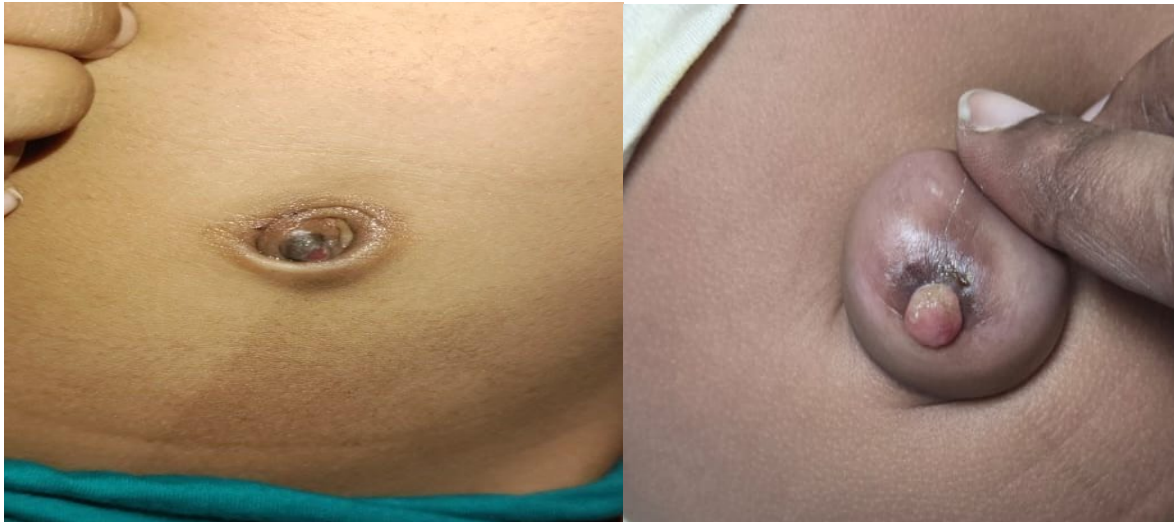

Figure 1 (J, K): Umbilical granuloma

Discussion

Meckel's diverticulum is well recognized for its varied clinical spectrum, with gastrointestinal bleeding, intestinal obstruction, and incidental intraoperative detection constituting the majority of presentations in pediatric practice. In contrast, its presentation as a component of gastroschisis in the neonatal period remains exceedingly rare and sparsely described in literature.

This unusual association poses both diagnostic and therapeutic challenges, as the diverticulum may be overlooked or its significance underestimated during initial evaluation of the abdominal wall defect [14]. A similar association was presented by Singh AP et al. [13] in their report with the defect being on the left side of the umbilical cord.

From a surgical standpoint, our experience reinforces that a minimally invasive approach is feasible and effective in the majority of cases, with laparoscopic-assisted resection offering the advantages of superior visualization, minimal bowel handling, and improved postoperative recovery.

However, in the subset of patients presenting with perforated Meckel's diverticulum, an open approach remains prudent to allow thorough peritoneal toileting and safe bowel resection. This highlights the importance of tailoring the surgical strategy based on intraoperative findings rather than a uniform approach.

Awareness of such rare presentations is crucial for pediatric surgeons, as early recognition and appropriate management can significantly influence outcomes in this vulnerable population. Gastrointestinal bleeding is one of the most common presentations of Meckel's diverticulum in children, with an incidence ranging from 27% to 56%. [2] Bleeding occurs due to ulceration from

acid or alkali secretion by ectopic mucosa. [2] Clinical presentation is variable, with abdominal pain and bleeding being most common.

Intestinal obstruction (41%) and hemorrhage (34%) are the most frequent complications, while perforation (10%) and diverticulitis (13%) are less common. [8] Morphology plays a significant role in complications.

Longer diverticula with narrow bases are prone to torsion and volvulus, whereas shorter diverticula with wider bases may predispose to foreign body entrapment. [3] Meckel's diverticulum should also be considered in children with persistent umbilical discharge, which may indicate a patent omphalomesenteric duct. [6] Symptomatic cases may present with small bowel obstruction, commonly due to intussusception or bands. [4] Meckel's scan is useful in detecting ectopic gastric mucosa, although sensitivity and specificity vary. [9-12] When imaging is inconclusive, laparoscopy serves as both a diagnostic and therapeutic modality. [5]

Both open and laparoscopic approaches are effective, with early intervention preventing complications and ensuring excellent outcomes. [7] Our series highlights the diverse clinical spectrum and demonstrates excellent outcomes with timely surgical management.

Conclusion

Meckel's diverticulum presents with a wide range of clinical manifestations in children. A high index of suspicion is required for early diagnosis. Surgical management, including minimally invasive approaches, yields excellent outcomes.

References

1. Tiwari C, Nagdeve N, Saoji R. Persistent Vitello intestinal duct beyond neonatal period. *ACG Case Rep J*. 2020;7(12):e00510.
2. Chen JJ, Lee HC, Yeung CY, et al. Meckel's diverticulum: factors associated with clinical manifestations. *ISRN Gastroenterol*. 2014;2014:390869.
3. Jatal SN, Jatal S, Ingle S. Giant Meckel's diverticulum causing small bowel obstruction. *Asian J Case Rep Surg*. 2023;6(1):313–318.
4. Hansen CC, Søreide K. Systematic review of Meckel's diverticulum. *Medicine (Baltimore)*. 2018;97(35):e12154.
5. Vitali V, Fusi G, Raffaele A, et al. Laparoscopic-assisted removal of Meckel's diverticulum. *Gastrointest Disord*. 2025;7:24.
6. Moore TC. Omphalomesenteric duct malformations. *Semin Pediatr Surg*. 1996; 5(2): 116–123.
7. *Int J Med Public Health*. Clinical presentation and management of Meckel's diverticulum. 2025; 15(2):1745–1750.
8. Keese D, Rolle U, Gfroerer S, Fiegel H. Symptomatic Meckel's diverticulum. *Front Pediatr*. 2019;7:267.
9. Lin XK, Huang XZ, Bao XZ, et al. Clinical characteristics of Meckel diverticulum. *Medicine (Baltimore)*. 2017;96(32):e7760.
10. Huang CC, Lai MW, Hwang FM, et al. Diverse presentations in pediatric Meckel's diverticulum. *Pediatr Neonatol*. 2014;55(5):369–375.
11. St-Vil D, Brandt ML, Panic S, et al. Meckel's diverticulum in children. *J Pediatr Surg*. 1991;26(11):1289–1292.
12. Kotha VK, Khandelwal A, Saboo SS, et al. Radiologist's perspective. *Br J Radiol*. 2014;87:20130743.
13. A.P. Singh, V. Mathur, R. Tanger, A.K. Gupta. Left-Sided gastroschisis with Meckel's diverticulum: a rare presentation *J Neonatal Surg*, 6 (3) (2017), p. 70
14. Khurram, N., Khawaja, R. D., & Mumtaz, S. (2021). A rare case of congenital midline cervical cleft: Case report and review of literature. *Journal of Pediatric Surgery Case Reports*, 74, 102047.