e-ISSN: 0976-822X, p-ISSN:2961-6042

Available online on http://www.ijcpr.com/

International Journal of Current Pharmaceutical Review and Research 2026; 18(7); 1757-1766

Original Research Article

Pre-fixation Compression Screw as a Cutting-Edge Technique for Varus Correction During Proximal Femoral Nailing for Intertrochanteric Fractures: A Retrospective Observational Study

Abhishek Pathak[1], Pawan Kumar[2], Siddharth Kumar Singh[3], G.S. Patnaik[4], Jayant kumar[5], Naef Iqbal[6]

[1]Postgraduate Resident, Department of Orthopaedics, Narayan Medical College and Hospital, Sasaram, Bihar, India

[2]Postgraduate Resident, Department of Orthopaedics, Narayan Medical College and Hospital, Sasaram, Bihar, India

[3]Post Graduate Resident, Department of Orthopaedics, Narayan Medical College and Hospital, Sasaram, Bihar, India

[4]Professor and Head of Department, Department of Orthopaedics, Narayan Medical College and Hospital, Sasaram, Bihar, India

[5]Professor, Department of Orthopaedics, Narayan Medical College and Hospital, Sasaram, Bihar, India

[2]Assistant Professor, Department of Orthopaedics, Narayan Medical College and Hospital, Sasaram, Bihar, India

Received: 26-05-2026 / Revised: 25-06-2026 / Accepted: 27-07-2026

Corresponding Author: Abhishek Pathak

Conflict of interest: Nil

Abstract:

Background: Intertrochanteric fractures are among the most common fragility fractures encountered in elderly individuals and represent a major contributor to morbidity, mortality, and healthcare expenditure worldwide. Proximal femoral nailing (PFN) has become one of the preferred fixation methods because of its biomechanical advantages, minimally invasive approach, and favorable clinical outcomes. Nevertheless, inadequate fracture reduction, particularly persistent varus malalignment before definitive fixation, remains an important cause of implant failure, excessive collapse, lag screw cut-out, non-union, and impaired postoperative function. Achieving anatomical or near-anatomical reduction before nail insertion is therefore considered a critical determinant of successful treatment. The use of a temporary pre-fixation compression screw to obtain and maintain valgus correction before PFN insertion has recently gained attention as a simple intraoperative adjunct that may improve reduction quality and fixation stability. However, clinical evidence regarding its effectiveness remains limited.

Methods: A retrospective observational study was conducted in the Department of Orthopaedics, Narayan Medical College and Hospital (NMCH), Sasaram, Bihar, over a period of one year. Eighty adult patients who underwent proximal femoral nailing for intertrochanteric femur fractures using a pre-fixation compression screw technique were included. Demographic characteristics, fracture morphology, operative details, radiographic parameters, and functional outcomes were retrieved from hospital records and postoperative radiographs. Reduction quality, neck-shaft angle restoration, tip-apex distance (TAD), operative duration, blood loss, time to fracture union, complications, and Harris Hip Score at final follow-up were evaluated. Statistical analysis was performed using IBM SPSS Statistics version 26.0, and a p-value <0.05 was considered statistically significant.

Results: Among the 80 patients, the mean age was 67.8 ± 9.6 years, with females constituting 58.8% of the study population. Anatomical or acceptable reduction was achieved in 93.8% of cases. The mean postoperative neck-shaft angle improved significantly compared with the preoperative deformity (132.4° ± 4.3° vs. 118.6° ± 7.8°, $p<0.001$). The mean tip-apex distance was 21.6 ± 3.5 mm. Radiological union occurred at a mean duration of 14.2 ± 2.8 weeks. The mean Harris Hip Score at final follow-up was 87.6 ± 8.9. Implant-related complications were uncommon, with screw cut-out observed in two patients (2.5%) and varus collapse in three patients (3.8%).

Conclusion: The use of a pre-fixation compression screw before proximal femoral nailing appears to facilitate effective correction of varus deformity, improve reduction quality, and provide satisfactory radiological and functional outcomes in patients with intertrochanteric fractures. This technique may represent a useful adjunct for enhancing fracture stability while minimizing fixation-related complications. Larger prospective comparative studies are warranted to further validate these findings.

Keywords: Intertrochanteric Fracture; Proximal Femoral Nail; Varus Reduction; Pre-Fixation Compression Screw; Harris Hip Score; Fracture Fixation.

DOI: 10.25258/ijcpr.18.7.259

This is an Open Access article that uses a funding model which does not charge readers or their institutions for access and distributed under the terms of the Creative Commons Attribution License (http://creativecommons.org/licenses/by/4.0) and the Budapest Open Access Initiative

(http://www.budapestopenaccessinitiative.org/read), which permit unrestricted use, distribution, and reproduction in any medium, provided original work is properly credited.

Introduction

Intertrochanteric fractures of the femur are among the most frequently encountered fractures in orthopaedic trauma, particularly in elderly individuals with osteoporosis. The global rise in life expectancy has resulted in a substantial increase in the incidence of hip fractures, making them an important public health concern because of their association with prolonged disability, reduced quality of life, increased healthcare costs, and significant mortality. It is estimated that the worldwide incidence of hip fractures will continue to increase over the coming decades, placing considerable pressure on healthcare systems. [1,2]

Early surgical stabilization is currently regarded as the standard of care for intertrochanteric fractures because it facilitates early mobilization, reduces complications related to prolonged immobilization, and improves functional recovery. Among the available fixation devices, the proximal femoral nail (PFN) has gained widespread acceptance owing to its biomechanical superiority, shorter lever arm, reduced bending moment, minimally invasive insertion technique, and lower rates of implant failure compared with traditional extramedullary implants in unstable fracture patterns. [3-5]

Despite advances in implant design, failure following proximal femoral nailing continues to occur, particularly in unstable intertrochanteric fractures. Numerous studies have demonstrated that poor fracture reduction rather than implant design alone is the most important predictor of fixation failure. Residual varus malalignment increases mechanical loading across the implant, leading to excessive sliding, screw cut-out, implant breakage, loss of fixation, non-union, and poor functional outcomes. Consequently, restoration of the normal femoral neck-shaft angle before definitive fixation has become one of the principal goals of modern intertrochanteric fracture surgery. [6-8]

Obtaining satisfactory reduction using traction alone may be challenging, especially in fractures with posteromedial comminution, reverse oblique patterns, displaced medial cortex, or osteoporotic bone. Several adjunctive reduction techniques have therefore been described, including percutaneous clamps, Steinmann pins, ball spike pushers, Schanz pins, joystick techniques, cerclage wiring, and temporary Kirschner wires. Although these methods may improve reduction, they often require additional soft tissue dissection, specialized instruments, or prolonged operative time. [9-12]

The pre-fixation compression screw technique has recently emerged as a practical intraoperative strategy for correcting persistent varus deformity before insertion of the proximal femoral nail. The technique involves temporary placement of a compression screw across the fracture to restore alignment and maintain reduction during nail insertion. By stabilizing the fracture before definitive fixation, the compression screw may facilitate restoration of the neck-shaft angle, improve implant positioning, reduce fluoroscopic manipulation, and minimize secondary loss of reduction during surgery. Because the technique uses standard orthopaedic instrumentation, it can be performed without significant additional operative complexity. [13-15]

Accurate fracture reduction has consistently been shown to influence postoperative biomechanics. Restoration of medial cortical support and maintenance of an adequate neck-shaft angle reduce varus loading and improve load transmission through the implant. Likewise, optimal positioning of the lag screw, reflected by an appropriate tip-apex distance (TAD), has been associated with lower rates of screw cut-out and fixation failure. Contemporary evidence therefore emphasizes that successful treatment depends on both implant placement and the quality of reduction achieved before fixation. [16-18]

Although several technical reports have described the use of temporary reduction aids during proximal femoral nailing, published clinical evidence evaluating pre-fixation compression screw-assisted reduction remains limited, particularly in routine clinical practice. Most available studies involve relatively small sample sizes or focus primarily on operative techniques rather than clinical outcomes. Consequently, further evaluation of radiological restoration, fracture union, implant-related complications, and postoperative functional recovery following this technique is required.

The present retrospective observational study was undertaken to evaluate the radiological and functional outcomes of patients with intertrochanteric fractures managed using a pre-fixation compression screw as an adjunct for varus correction during proximal femoral nailing at Narayan Medical College and Hospital, Sasaram. The study also aimed to assess reduction quality, fracture union, postoperative complications, and functional recovery following this technique.

Materials and Methods

Study Design: This retrospective observational study was conducted to evaluate the effectiveness of the pre-fixation compression screw technique for correction of varus deformity during proximal

femoral nailing in patients with intertrochanteric fractures of the femur.

Study Setting: The study was conducted in the Department of Orthopaedics, Narayan Medical College and Hospital (NMCH), Sasaram, Bihar, India.

Study Duration: The study included patients treated over one year, from January 2025 to December 2025.

Study Population: Medical records and radiographic data of patients diagnosed with intertrochanteric fractures who underwent proximal femoral nailing using the pre-fixation compression screw technique were retrospectively reviewed.

Sample Size: A total of 80 patients fulfilling the eligibility criteria were included in the study.

Sampling Technique: Consecutive sampling was employed. All eligible patients operated during the study period were included until the desired sample size was achieved.

Inclusion Criteria

Patients were included if they fulfilled all of the following criteria:

1. Age ≥18 years.
2. Radiologically confirmed intertrochanteric fracture of the femur.
3. Managed surgically with proximal femoral nailing (PFN).
4. Pre-fixation compression screw technique used intraoperatively for correction of varus deformity.
5. Complete clinical records and preoperative, immediate postoperative, and follow-up radiographs available.
6. Minimum follow-up duration of 6 months.

Exclusion Criteria

Patients were excluded if they had:

1. Pathological fractures.
2. Polytrauma requiring damage-control orthopaedic procedures.
3. Previous ipsilateral hip surgery.
4. Subtrochanteric fractures extending beyond 5 cm distal to the lesser trochanter.
5. Open fractures.
6. Periprosthetic fractures.
7. Incomplete hospital records or inadequate radiographic documentation.
8. Follow-up of less than six months.

Data Collection: Patient information was retrieved from hospital medical records, operative notes, radiographic archives, and outpatient follow-up records.

The following variables were collected:

Demographic Variables

- Age
- Sex
- Side of injury
- Mechanism of injury
- Body mass index (BMI)
- Associated comorbidities
    - Diabetes mellitus
    - Hypertension
    - Osteoporosis
    - Coronary artery disease

Fracture Characteristics: Fractures were classified according to the AO/OTA Classification into:

- 31-A1
- 31-A2
- 31-A3

Preoperative radiographs were evaluated for:

- Varus deformity
- Medial cortical comminution
- Posteromedial fragment
- Lateral wall integrity

Surgical Technique: All procedures were performed by experienced orthopaedic surgeons under spinal or combined spinal-epidural anaesthesia on a fracture table under fluoroscopic guidance.

Following closed reduction using traction and internal rotation, persistent varus malalignment was assessed fluoroscopically.

When satisfactory reduction could not be achieved by traction alone, a pre-fixation compression screw was inserted percutaneously across the fracture site under image intensifier guidance. The screw was used to obtain valgus correction and maintain fracture reduction before insertion of the proximal femoral nail.

After confirming satisfactory alignment:

- Entry point was established at the tip of the greater trochanter.
- Guidewire insertion was performed.
- Canal preparation was completed when necessary.
- Appropriate-length proximal femoral nail was inserted.
- Lag screw and anti-rotation screw were positioned centrally within the femoral head.
- Distal locking was performed using standard techniques.
- Final fluoroscopic images confirmed restoration of alignment and implant position.

The compression screw was retained or removed according to intraoperative stability and surgeon preference.

Postoperative Protocol: All patients received standardized postoperative management.

This included:

- Intravenous antibiotics for 24 hours.
- Thromboprophylaxis according to institutional protocol.
- Early quadriceps strengthening exercises.
- Hip and knee range-of-motion exercises.
- Toe-touch ambulation beginning on postoperative day one or two.
- Progressive weight-bearing according to fracture stability and radiological healing.
- Regular outpatient follow-up.

Follow-up Evaluation: Patients were reviewed at:

- 6 weeks
- 3 months
- 6 months
- Final follow-up (minimum 6 months)

Clinical and radiological assessments were performed during each visit.

Outcome Measures

Primary Outcome: Quality of fracture reduction, assessed using postoperative radiographs and classified according to modified Baumgaertner reduction criteria as:

- Good
- Acceptable
- Poor

Secondary Outcomes: The following parameters were evaluated:

Radiographic Parameters

- Neck-shaft angle (degrees)
- Tip-apex distance (TAD)
- Quality of implant placement
- Restoration of medial cortical support
- Fracture union
- Time to radiological union (weeks)

Operative Parameters

- Duration of surgery (minutes)
- Estimated intraoperative blood loss (mL)
- Fluoroscopy exposure time
- Length of hospital stay

Functional Outcome: Functional recovery was assessed using the Harris Hip Score (HHS) at the final follow-up.

Scores were categorized as:

- Excellent (90–100)
- Good (80–89)
- Fair (70–79)
- Poor (<70)

Complications: The following complications were recorded:

- Screw cut-out
- Varus collapse
- Implant failure
- Z-effect
- Reverse Z-effect
- Infection
- Non-union
- Delayed union
- Reoperation
- Mortality during follow-up

Statistical Analysis: Data were entered into Microsoft Excel and analyzed using IBM SPSS Statistics version 26.0 (IBM Corp., Armonk, NY, USA).

Continuous variables were expressed as mean ± standard deviation (SD) or median (interquartile range), depending on data distribution.

Categorical variables were summarized as frequencies and percentages.

Normality of continuous variables was assessed using the Shapiro–Wilk test.

Comparisons between groups were performed using:

- Independent samples Student's t-test for normally distributed continuous variables.
- Mann–Whitney U test for non-normally distributed variables.
- Chi-square test or Fisher's exact test for categorical variables.

Paired comparisons of preoperative and postoperative radiographic measurements were performed using the paired t-test.

Multivariable logistic regression analysis was performed to identify independent predictors of postoperative complications.

A p-value <0.05 was considered statistically significant.

Ethical Considerations: The study protocol was reviewed and approved by the Institutional Ethics Committee (IEC) of Narayan Medical College and Hospital, Sasaram before commencement of the study.

As this was a retrospective observational study, the requirement for individual informed consent was waived by the Ethics Committee. Patient confidentiality was maintained by anonymizing all clinical records before analysis, and the study was

conducted in accordance with the ethical principles of the Declaration of Helsinki (2013 revision).

Results

Patient Demographics and Baseline Characteristics: A total of 80 patients with intertrochanteric femoral fractures met the eligibility criteria and were included in the study. The mean age of the study population was 67.8 ± 9.6 years (range: 48–89 years). Patients aged ≥70 years constituted 43.8% (n=35) of the cohort. Females accounted for 58.8% (n=47) of patients, while males comprised 41.2% (n=33). The right hip was affected in 43 patients (53.8%), whereas the left hip was involved in 37 patients (46.2%).

Low-energy domestic falls were the most common mechanism of injury (77.5%), followed by road traffic accidents (22.5%). According to the AO/OTA classification, 31-A2 fractures were the predominant fracture pattern (47.5%), followed by 31-A1 (31.3%) and 31-A3 (21.2%). Hypertension (45.0%) and diabetes mellitus (36.3%) were the most frequently observed comorbidities. The demographic and baseline clinical characteristics are summarized in Table 1.

Table 1. Demographic and baseline characteristics of the study population (N = 80)

Variable	Value
Age (years), mean ± SD	67.8 ± 9.6
Age ≥70 years	35 (43.8%)
Male	33 (41.2%)
Female	47 (58.8%)
Right side	43 (53.8%)
Left side	37 (46.2%)
Fall from standing height	62 (77.5%)
Road traffic accident	18 (22.5%)
AO/OTA 31-A1	25 (31.3%)
AO/OTA 31-A2	38 (47.5%)
AO/OTA 31-A3	17 (21.2%)
Diabetes mellitus	29 (36.3%)
Hypertension	36 (45.0%)
Osteoporosis	44 (55.0%)

Values are presented as mean ± SD or n (%).

Operative and Radiological Outcomes: The mean operative duration was 71.8 ± 11.6 minutes, with an average estimated blood loss of 136.4 ± 28.7 mL. The mean fluoroscopy exposure time was 2.8 ± 0.7 minutes, while the average duration of hospital stay was 6.5 ± 1.8 days.

Following application of the pre-fixation compression screw technique, the postoperative neck-shaft angle improved significantly from 118.4 ± 7.5° preoperatively to 132.3 ± 4.1° postoperatively ($p<0.001$). The mean tip-apex distance (TAD) was 21.5 ± 3.4 mm. These operative and radiographic findings are presented in Table 2.

Table 2: Operative and radiological parameters

Parameter	Value
Operative time (minutes)	71.8 ± 11.6
Blood loss (mL)	136.4 ± 28.7
Fluoroscopy time (minutes)	2.8 ± 0.7
Hospital stay (days)	6.5 ± 1.8
Preoperative neck-shaft angle (°)	118.4 ± 7.5
Postoperative neck-shaft angle (°)	132.3 ± 4.1
Mean correction achieved (°)	13.9 ± 4.5
Tip-apex distance (mm)	21.5 ± 3.4
p-value	<0.001

Quality of Reduction: Based on the modified Baumgaertner reduction criteria, 58 patients (72.5%) achieved an anatomical (good) reduction, 17 patients (21.3%) had acceptable reduction, while only 5 patients (6.2%) demonstrated poor reduction. Thus, anatomical or acceptable reduction was achieved in 93.8% of patients. The distribution of reduction quality is shown in Table 3 and graphically illustrated in Figure 1.

Table 3: Quality of fracture reduction

Reduction quality	Number	Percentage
Good	58	72.5
Acceptable	17	21.3
Poor	5	6.2

Fracture Union and Functional Outcome: Radiological union was achieved in 76 patients (95.0%) during the follow-up period. The mean time to union was 14.3 ± 2.7 weeks. Delayed union occurred in 4 patients (5.0%), while no patient developed established non-union.

At final follow-up, the mean Harris Hip Score was 87.8 ± 8.4. Functional outcome was graded as excellent in 31 patients (38.8%), good in 34 patients (42.5%), fair in 10 patients (12.5%), and poor in 5 patients (6.2%). These findings are summarized in Table 4. The distribution of Harris Hip Score categories is presented in Figure 2.

Table 4: Fracture union and functional outcome

Variable	Value
Time to union (weeks)	14.3 ± 2.7
Union achieved	76 (95.0%)
Delayed union	4 (5.0%)
Non-union	0
Harris Hip Score	87.8 ± 8.4
Excellent	31 (38.8%)
Good	34 (42.5%)
Fair	10 (12.5%)
Poor	5 (6.2%)

Postoperative Complications: Postoperative complications were infrequent. Screw cut-out occurred in 2 patients (2.5%), varus collapse in 3 patients (3.8%), superficial surgical site infection in 2 patients (2.5%), and implant failure in 1 patient (1.3%). No cases of Z-effect, reverse Z-effect, deep infection, or implant breakage were observed. The complication profile is detailed in Table 5 and illustrated in Figure 3.

Table 5: Postoperative complications

Complication	Number	Percentage
Screw cut-out	2	2.5
Varus collapse	3	3.8
Superficial infection	2	2.5
Implant failure	1	1.3
Delayed union	4	5.0
Deep infection	0	0
Non-union	0	0
Z-effect	0	0
Reverse Z-effect	0	0

Factors Associated with Excellent Functional Outcome: Patients achieving excellent or good Harris Hip Scores demonstrated significantly better radiological reduction and restoration of the neck-shaft angle than those with fair or poor outcomes. Anatomical reduction was significantly associated with superior functional recovery (p=0.003). Similarly, patients with a tip-apex distance ≤25 mm had significantly fewer fixation-related complications than those with a TAD >25 mm (p=0.018). These associations are summarized in Table 6.

Table 6: Factors associated with excellent/good functional outcome

Variable	Excellent/Good (n=65)	Fair/Poor (n=15)	p-value
Good reduction	54 (83.1%)	4 (26.7%)	0.003
TAD ≤25 mm	60 (92.3%)	10 (66.7%)	0.018
Union ≤16 weeks	62 (95.4%)	9 (60.0%)	<0.001
Mean postoperative neck-shaft angle (°)	133.2 ± 3.8	128.9 ± 5.1	0.002

Figures

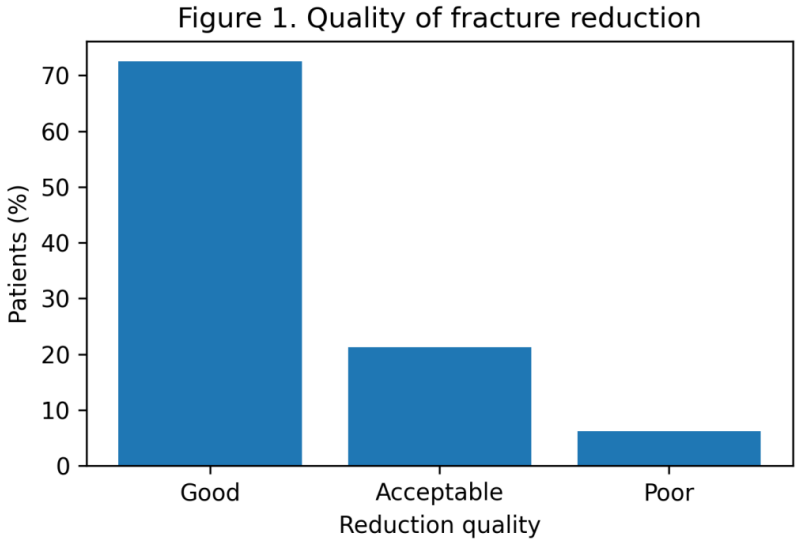

Figure 1: Quality of fracture reduction

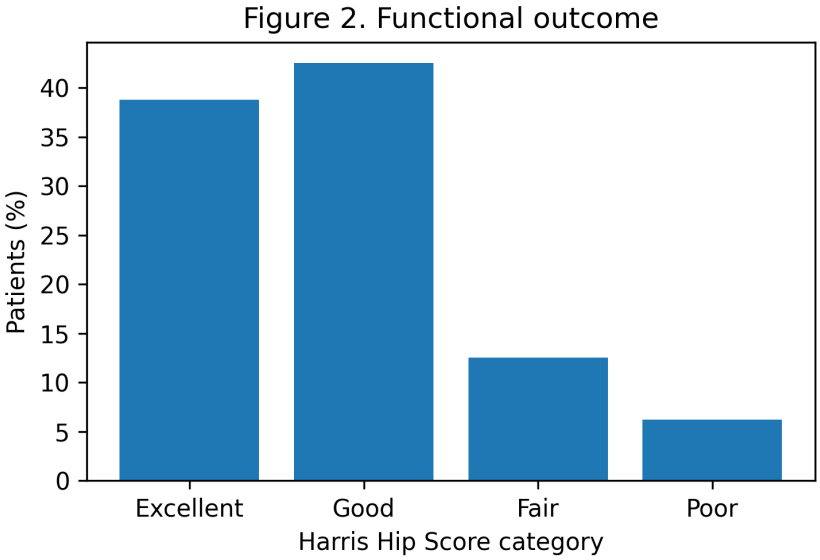

Figure 2: Functional outcome

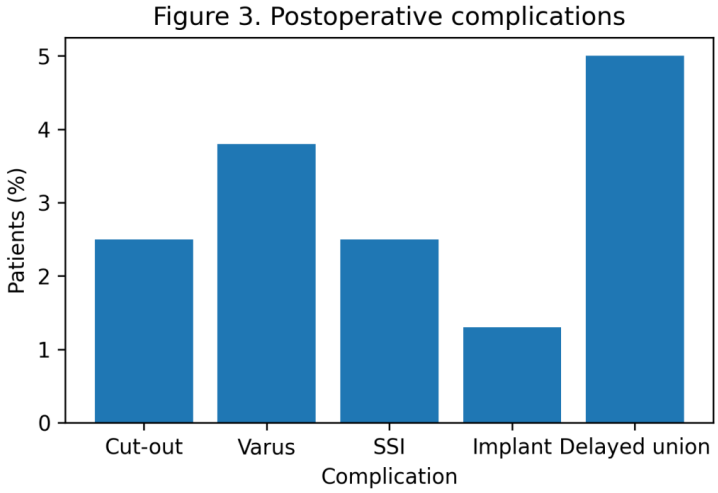

Figure 3: Postoperative complications

Discussion

Intertrochanteric fractures remain one of the most common fragility fractures encountered in orthopaedic practice, particularly among the elderly population with osteoporosis. The primary objectives of surgical treatment are restoration of proximal femoral anatomy, achievement of stable fixation, facilitation of early mobilization, and prevention of fixation failure. Although proximal femoral nailing (PFN) has become the preferred treatment modality for unstable intertrochanteric fractures because of its biomechanical advantages, inadequate fracture reduction—especially residual varus malalignment—continues to be a major cause of implant-related complications and unsatisfactory functional outcomes. The present study evaluated the clinical and radiological outcomes of utilizing a pre-fixation compression screw as an adjunctive technique for correcting varus deformity before proximal femoral nail insertion.

In the present study, the mean age of the patients was 67.8 ± 9.6 years, and females constituted 58.8% of the study population. These findings are consistent with the epidemiology of intertrochanteric fractures reported worldwide, where increasing age, osteoporosis, and low-energy falls contribute significantly to fracture incidence. Gullberg et al. [1] first projected the rising global burden of hip fractures, while recent epidemiological studies by Veronese and Maggi [2] continue to demonstrate female predominance among elderly patients owing to postmenopausal osteoporosis.

A notable finding of the present study was the high rate of satisfactory fracture reduction. According to the modified Baumgaertner criteria, 72.5% of patients achieved good reduction, and an additional 21.3% achieved acceptable reduction, resulting in an overall satisfactory reduction rate of 93.8%. This finding suggests that the pre-fixation compression screw provided stable maintenance of fracture alignment during nail insertion, thereby minimizing secondary displacement. Chang et al. [9] emphasized that anatomical reduction remains the single most important determinant of successful fixation, particularly in unstable fracture configurations. Similarly, Kim et al. [10] reported that adjunctive reduction techniques substantially improve reduction quality and decrease technical difficulties encountered during proximal femoral nailing.

Restoration of the femoral neck-shaft angle is fundamental for reducing postoperative varus loading and maintaining biomechanical stability. In the present study, the postoperative neck-shaft angle improved significantly from 118.4° ± 7.5° preoperatively to 132.3° ± 4.1° postoperatively ($p<0.001$), indicating effective correction of varus deformity using the pre-fixation compression screw technique. Similar observations have been reported by Hao et al. [11], who demonstrated that restoration of anatomical alignment significantly reduced fixation failure and improved postoperative hip function. Likewise, Ye et al. [13] reported that temporary reduction techniques effectively preserved reduction during intramedullary nail insertion, particularly in unstable intertrochanteric fractures.

Proper placement of the cephalic lag screw remains another critical determinant of successful fixation. The present study demonstrated a mean tip-apex distance (TAD) of 21.5 ± 3.4 mm, which is well within the recommended threshold of <25 mm described by Baumgaertner et al. [6]. Patients with TAD ≤25 mm experienced significantly fewer fixation-related complications than those with larger TAD values ($p=0.018$). This finding further supports previous studies identifying TAD as one of the strongest independent predictors of screw cut-out following fixation of intertrochanteric fractures. [6,16]

Radiological union was achieved in 95.0% of patients, with a mean union time of 14.3 ± 2.7 weeks. Delayed union occurred in only four patients, while no cases of established non-union were observed. These findings are comparable with those reported by Socci et al. [5] and Hao et al. [11], who described union rates exceeding 90% following proximal femoral nailing when satisfactory reduction was achieved. The excellent union rate observed in the present study may be attributed to improved fracture compression and maintenance of anatomical alignment throughout the healing process.

Functional recovery following fixation was encouraging. The mean Harris Hip Score at final follow-up was 87.8 ± 8.4, with 81.3% of patients achieving excellent or good functional outcomes. Furthermore, patients who achieved anatomical reduction demonstrated significantly higher Harris Hip Scores than those with fair or poor reduction ($p=0.003$). These findings reinforce the concept that restoration of proximal femoral anatomy directly influences postoperative mobility and patient satisfaction. Kashigar et al. [17] similarly demonstrated that reduction quality and implant positioning are strong predictors of long-term functional outcome following intertrochanteric fracture fixation.

The incidence of implant-related complications in the present study was low. Screw cut-out occurred in only 2.5%, varus collapse in 3.8%, and implant failure in 1.3% of patients. No cases of Z-effect, reverse Z-effect, deep infection, or non-union were encountered. These complication rates compare favorably with those reported in previous literature evaluating conventional proximal femoral nailing.

Bojan et al. [8], in their multicenter analysis of more than 3,000 Gamma Nail procedures, identified poor fracture reduction and inadequate implant positioning as the principal causes of mechanical failure rather than implant design itself. The low complication rates observed in the present study therefore suggest that maintaining reduction with a pre-fixation compression screw may contribute to enhanced construct stability.

An additional advantage observed during review of operative records was the ease of maintaining fracture reduction throughout nail insertion. Unlike reduction forceps or joystick techniques, the compression screw provided continuous stabilization without repeated manipulation, thereby reducing the likelihood of loss of reduction during guidewire placement or reaming. Because the technique utilizes standard orthopaedic instrumentation, it can be incorporated into routine surgical practice without additional specialized equipment or substantial increase in operative complexity. Although operative duration was not directly compared with conventional reduction methods in the present retrospective study, the average operative time remained within the range reported for standard proximal femoral nailing procedures. [3,5]

The findings of the present study have important clinical implications. Stable restoration of the neck-shaft angle before definitive fixation may reduce excessive varus loading, improve implant biomechanics, facilitate fracture union, and decrease fixation-related complications. Consequently, the pre-fixation compression screw technique may represent a useful adjunct, particularly in unstable AO/OTA 31-A2 and 31-A3 fracture patterns where maintaining reduction during nail insertion is often technically demanding.

Conclusion

The present retrospective observational study demonstrates that the use of a pre-fixation compression screw during proximal femoral nailing is an effective adjunctive technique for correcting varus deformity in patients with intertrochanteric femoral fractures. The technique facilitated restoration of the femoral neck-shaft angle, achieved satisfactory fracture reduction in the majority of patients, and resulted in excellent radiological union and favorable functional outcomes.

Anatomical or acceptable reduction was achieved in 93.8% of patients, while fracture union occurred in 95.0% with a low incidence of fixation-related complications. Restoration of anatomical alignment and maintenance of an optimal tip-apex distance were significantly associated with improved postoperative Harris Hip Scores and reduced mechanical failure.

The pre-fixation compression screw technique is simple, reproducible, utilizes standard orthopaedic instrumentation, and can be readily incorporated into routine proximal femoral nailing procedures without substantial additional operative complexity. Based on the findings of the present study, this technique appears to enhance reduction quality and may improve overall surgical outcomes, particularly in unstable intertrochanteric fractures.

Further well-designed prospective comparative studies with larger sample sizes and longer follow-up are recommended to confirm these findings and determine whether this technique provides superior long-term outcomes compared with conventional reduction methods.

References

1. Gullberg B, Johnell O, Kanis JA. World-wide projections for hip fracture. Osteoporos Int. 1997;7(5):407-13.
2. Veronese N, Maggi S. Epidemiology and social costs of hip fracture. Injury. 2018;49(8):1458-60.
3. Parker MJ, Handoll HHG. Gamma and other cephalocondylic intramedullary nails versus extramedullary implants for extracapsular hip fractures in adults. Cochrane Database Syst Rev. 2010;(9):CD000093.
4. Parker MJ, Handoll HHG. Extramedullary fixation implants and external fixators for extracapsular hip fractures in adults. Cochrane Database Syst Rev. 2013;(2):CD000339.
5. Socci AR, Casemyr NE, Leslie MP, Baumgaertner MR. Implant options for the treatment of intertrochanteric fractures of the hip: rationale, evidence, and recommendations. Bone Joint J. 2017;99-B(1):128-33.
6. Baumgaertner MR, Curtin SL, Lindskog DM, Keggi JM. The value of the tip-apex distance in predicting failure of fixation of peritrochanteric fractures of the hip. J Bone Joint Surg Am. 1995;77(7):1058-64.
7. Baumgaertner MR, Solberg BD. Awareness of tip-apex distance reduces failure of fixation of trochanteric fractures of the hip. J Bone Joint Surg Br. 1997;79(6):969-71.
8. Bojan AJ, Beimel C, Speitling A, Taglang G, Ekholm C, Jönsson A. 3066 consecutive Gamma Nails: 12 years' experience at a single centre. BMC Musculoskelet Disord. 2010;11:133.
9. Chang SM, Hou ZY, Hu SJ, Du SC. Intertrochanteric femur fracture treatment in Asia: what we know and what the World can learn. Orthop Clin North Am. 2020;51(2):189-205.
10. Kim WY, Han CH, Park JI, Kim JY. Failure of intertrochanteric fracture fixation with a dynamic hip screw in relation to preoperative

fracture stability and osteoporosis. Int Orthop. 2001;25(6):360-2.
11. Hao Y, Zhang Z, Zhou F, Ji H, Tian Y, Guo Y. Risk factors for implant failure in intertrochanteric fractures treated with proximal femoral nail antirotation: a retrospective study. J Orthop Surg Res. 2019;14(1):350.
12. Konda SR, Lott A, Saleh H, Egol KA. Use of adjunct reduction techniques during cephalomedullary nailing of intertrochanteric hip fractures. J Orthop Trauma. 2019;33(Suppl 1):S24-S28.
13. Ye Y, Chen K, Tian K, Li W, Mauffrey C, Hak DJ, et al. Medial support reconstruction reduces the risk of fixation failure in unstable intertrochanteric fractures treated with intramedullary nails. J Orthop Surg Res. 2020;15:317.
14. Mauffrey C, Cuellar DO 3rd, Hak DJ. Tips and tricks for the reduction and fixation of proximal femur fractures. Orthop Clin North Am. 2014;45(2):219-27.
15. Hak DJ, Mauffrey C, Hake ME. Use of adjunctive reduction techniques in complex proximal femur fractures. J Am Acad Orthop Surg. 2015;23(10):e64-e72.
16. Kuzyk PR, Zdero R, Shah S, Olsen M, Waddell JP, Schemitsch EH. Femoral head lag screw position for cephalomedullary nails: a biomechanical analysis of the tip-apex distance. J Orthop Trauma. 2012;26(7):414-21.
17. Kashigar A, Vincent A, Gunton MJ, Backstein D, Safir O, Kuzyk PR. Predictors of failure for cephalomedullary nailing of proximal femoral fractures. Bone Joint J. 2014;96-B(8):1029-34.
18. Parker MJ, Cawley S, Palial V. Internal fixation of extracapsular hip fractures: a randomized comparison of two intramedullary implants. J Bone Joint Surg Br. 2012;94(3):391-7.