RESEARCH ARTICLE

The Physiological and Histological Effect of Infected Wheat and Rice (with Aflatoxin and Benzoquinone) on Rat Kidneys

Hayder A. H. Al-Janabi,[1,2] Mohammed J. Mohammed[1]

[1]*Department of Food Science, College of Agriculture, Tikrit University, Tikrit, Iraq.*
[2]*State Company for Grain Broad, Ministry of Trade, Baghdad, Iraq.*

Received: 27th April, 2021; Revised: 9th May, 2021; Accepted: 20th August, 2021; Available Online: 25th September, 2021

ABSTRACT

The current study aimed to estimate the physiological and histological effect of rat kidneys feeding infected wheat and rice. Samples were collected in Kirkuk city and included Kirkuk silo, Riyadh Al-Makhzani complex, and Taza Grain Center of the General Company for Grain Trade, one of the Iraqi Ministry of Trade branches. 10 samples of wheat and rice were collected from 2 kg for each sample of grains from 1 to 22 September 2019. The rats were randomly divided into 6 groups (6 rats in each treatment). It included the following: The first treatment (T1): a group of control rats for normal wheat, the second treatment (T2): a group of control rats for normal rice, the third treatment (T3): a group of rats given orally 50% of normal wheat and 50% of the infected wheat contains different concentrations of aflatoxin and benzoquinone. The fourth treatment (T4): the group of rats given orally 25% of normal wheat is 75% of the infected wheat, containing different concentrations of aflatoxin and benzoquinone. The fifth treatment (T5): The group of rats given orally 100% to the infected wheat contains different aflatoxin concentrations and benzoquinone. The sixth treatment (T6): 100% infected rice. The current results showed that there were significant ($p \leq 0.05$) differences between the study groups. The current results showed that the group given infected 100% wheat showed a significant increase in creatinine and urea levels compared with control group. On the other hand, it was observed that the group given infected 100% rice showed a significant increase in the levels of creatinine and compared with the control group given regular rice. Different histological lesions were diagnosed in the histological study, including damaged glomerulus and urinary tubules with lymphocytes infiltration and the thickening wall of blood vessels.

Keyword: Aflatoxin, Benzoquinone, Kidney.

International Journal of Drug Delivery Technology (2021); DOI: 10.25258/ijddt.11.3.41

How to cite this article: Al-Janabi HAH, Mohammed MJ. The Physiological and Histological Effect of Infected Wheat and Rice (with Aflatoxin and Benzoquinone) on Rat Kidneys. International Journal of Drug Delivery Technology. 2021;11(3):896-899.

Source of support: Nil.

Conflict of interest: None

INTRODUCTION

Developing countries suffer from delays in production, harvesting, storage and marketing techniques, which leads to contamination of food and feed with these toxins.[1,2] From the time of harvest to the moment when it is received for consumption, the grain is subjected to insect damage, and it is generally considered that 5 to 15% of the losses in the various stored grains occur due to the occurrence of insect pests.[3,4] The interaction between insects and fungi in stored products is still in active research to establish the relationship between insects and fungi in food damage, since before milling grains are already contaminated with a range of agents that are likely to deteriorate.[5] In addition, insects can be vectors of fungi that act as both an endogenous and an exogenous carrier of spores, including serving as a mobile source of mycotoxins and mycotoxins.[6] In general, stored products of agricultural and animal origin are attacked by more than 600 species of Coleoptera, 70 species of Lepidopterans and about 355 species of mites. It causes quantitative and qualitative losses.[3] Insects that damage stored grain, several times obtained access from the field and settled in the storage site due to the microclimate and were kept during processing and storage.[7,8] Perhaps the most important problems of storing and marketing grains are controlling their quality since they are received after harvest and until they reach the facilities responsible for their manufacture. One of the conditions for maintaining the grain quality is controlling the growth of microorganisms contaminating grains during marketing operations, impacting these neighborhoods on human health, especially regarding fungi growth and production of mycotoxins and the difference in environmental conditions such as temperature and humidity during transportation and storage. In the absence of a local study, this study aimed to estimate rat kidneys' physiological and histological effects.

**Author for Correspondence: laithabidali2003@gmail.com*

MATERIALS AND METHODS

Sample Collection Sites

Samples were collected in Kirkuk city and included Kirkuk silo, Riyadh Al-Makhzani complex, and Taza Grain Center of the General Company for Grain Trade, one of the Iraqi Ministry of Trade branches. A total of 10 samples of wheat and rice were collected from 2 kg for each sample of grains for the period from 1 to 22 September 2019. Benzoquinone was extracted and determined by HPLC analysis.[9] Aflatoxin was detected by high performance Liquid Chromatography (HPLC).

Laboratory Animals

This experiment was conducted in the animal house of College of Veterinary Medicine at Tikrit University, in which 24 albino male rats were used, their ages ranged between 8 to 9 weeks and weights between 145 to 150 g.

Experimental Design

The rats were randomly divided into six group (6 rats in each treatment). It included the following: The first treatment (T1): a group of control rats for normal wheat, the second treatment (T2): a group of control rats for normal rice, the third treatment (T3): a group of rats given orally 50% of normal wheat and 50% of the infected wheat that contain different concentrations of aflatoxin 0.035 B1 and 0.15 NI and benzoquinone amounting to 1.250 MBQ and 0.8 EBQ and as indicated in the examination tables, the fourth treatment (T4): the group of rats given orally 25% of normal wheat is and 75% of the infected wheat that contain different concentrations of aflatoxin 0.05 B1 and 0.0225 NI, benzoquinone The fifth treatment (T5): The group of rats given orally 100% to the infected wheat contains different concentrations of aflatoxin 0.07 B1, 0.03NI and benzoquinone amounting to 2.5 MBQ and 1.6 EBQ and as for the sixth treatment (T6): 100% Uruguayan rice Infected containing different concentrations of aflatoxin g1 0.047, MBQ benzoquinone (2.00) and EBQ (0.650) PPM as indicated in the examination tables. Rats were dosed for 28 days by determining parameters of kidney functions and tissue.

Statistical Analysis

An experiment was conducted with a CRD design for wheat (0, 1, 2, 3, 4, 5, 6) months and two storage methods are laboratory. The comparison between the averages of transactions was made using the least significant difference test (LSD) at the level of significance 0.05 and calculating the correlation coefficient (SPSS, 2009).

RESULTS AND DISCUSSION

Kidney Functions

The current results showed that there were significant ($p \leq 0.05$) differences between the study groups. The current results showed that the group given infected 100% wheat showed a significant increase in creatinine levels (2.42 ± 0.14) and urea (63.2 ± 5.11) compared with the control group given normal wheat (0.93 ± 0.19, 25.2 ± 4.29, respectively). On the other hand, it was observed that the group given infected 100% rice showed a significant increase in the levels of creatinine (1.92 ± 0.18) and urea (49.2 ± 7.04) compared with the control group given normal rice (0.8 ± 0.06, 19.31 ± 2.61, respectively), as it is It is shown in the Table 1.

Table 1: Effect of aflatoxin and buzuquinone on kidney functions

	Renal function parameters in rats	
Treatments	*Creatinine mg/dL*	*Urea mg/dL*
T1	25.2 ± 4.29 d	0.93 ± 0.19 c
T2	19.31 ± 2.61 d	0.8 ± 0.06 c
T3	41.62 ± 7.32 c	2.06 ± 0.25 b
T4	56.2 ± 3.73 b	1.32 ± 0.13 b
T5	63.2 ± 5.11 a	2.42 ± 0.14 a
T6	49.2 ± 7.04 c	1.92 ± 0.18 b

The current results agreed with previous researches that oral administration of aflatoxin B1 at concentrations of 0.5 and 0.8 mg/kg to growing rats led to an increase in the creatinine ratio from 34.9–37.4 during 21 and 42 days, respectively, and the urea content was increased. The effect of aflatoxin B1 on kidney functions could be one of its negative effects on kidney cells and causing damage, which caused a decrease in their ability to filter, which caused the release of creatinine and urea in a greater amount than normal levels into the blood.

Kidney Tissue

Cross-sections of the control group given normal wheat (T1) showed the normal shape of the glomerulus, proximal tubules, and distal tubules, as shown in Figure 1. The cross-sections of control group given normal rice (T2) show the normal shape of the glomerulus, proximal tubules, and distal tubules, as shown in Figure 2. Otherwise, the infected wheat (T3) 50%, the microscopic examination showed different histological lesions including damage glomerulus and urinary tubules with lymphocytes infiltration and thickening of the vascular wall as shown in Figure 3. Also, the kidneys of the treated group showed 75% infected wheat (T4), the presence of various tissue lesions including damaged glomerulus and urinary tubules with lymphocytes infiltration and thickening of the vascular wall as shown in Figure 4. the treated group (100% infected with wheat) (T5), the microscopic examination showed the presence of various histological lesions including damage glomerulus and urinary tubules with lymphocytes infiltration and thickening of the vascular wall as shown in Figure 5. Also, the kidneys of the group given 100% infected rice showed different histological lesions including lymph damage glomerulus and urinary tubules with lymphocytes infiltration and thickening of the vascular wall as shown in Figure 6.

The results of the current study agreed with, Li *et al.*[11] who stated that feeding on tomofl aflatoxin caused renal damage and included degeneration of the cells lining the urinary tubules with the destruction of glomeruli in most of the renal cortex with the presence of lymphocyte infiltration, and the researcher attributed the reason to the toxicity of aflatoxin. The experiment showed that the effect of aflatoxin in mice had aflatoxin G1 effect on the kidney.

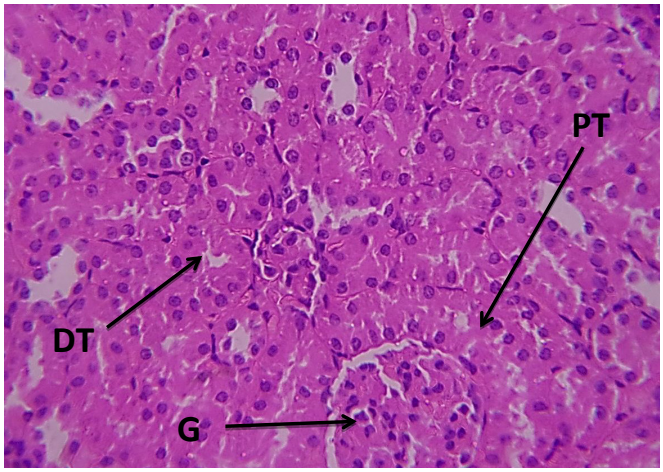

Figure 1: Cross-section of the kidneys of the control group given normal wheat (T1) showed the normal structure of glomerulus (G), proximal tubule (PT) and distal tubule (DT) H&E X400

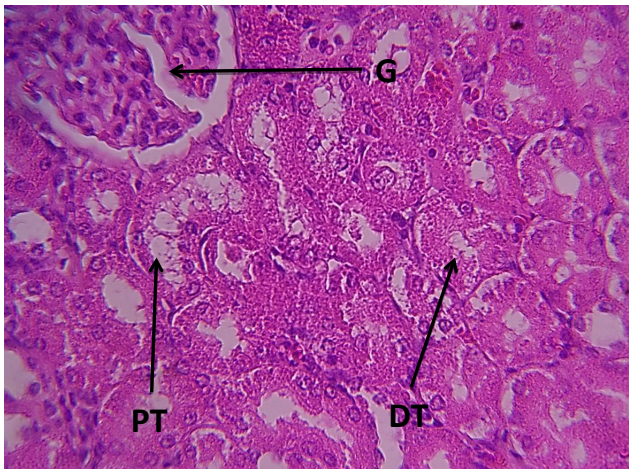

Figure 2: Cross-section of the kidneys of the control group given normal rice (T2) showed the normal structure of glomerulus (G), proximal tubule (PT) and distal tubule (DT) H&E X400

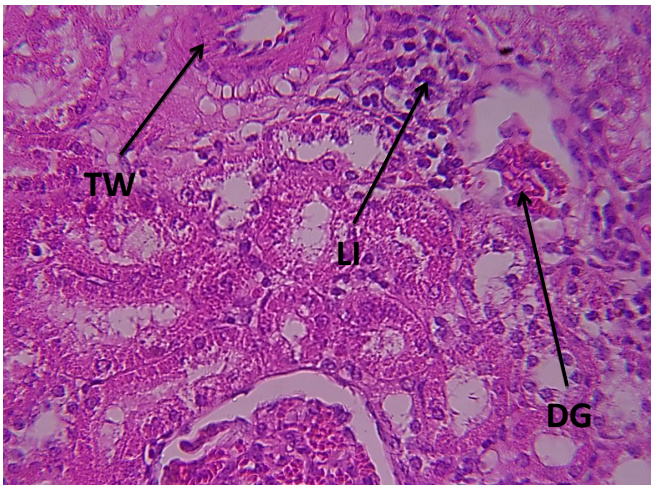

Figure 3: Cross-section of kidneys of group (T3) showed thickening wall (TW) of blood vessels, damage of glomerulus (DG) and lymphocyte infiltration (LI) H&E X400

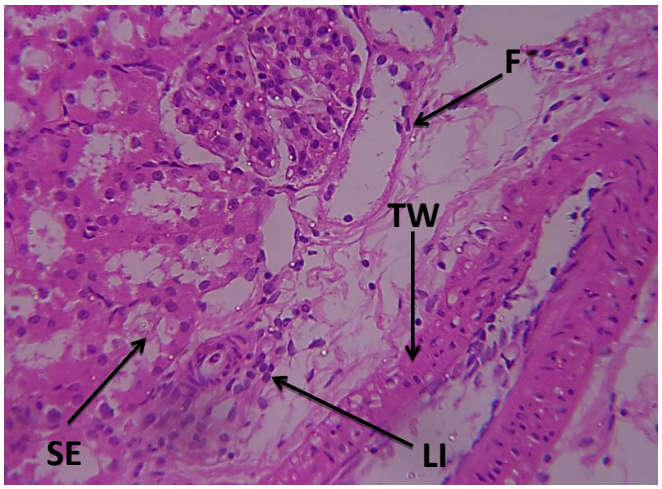

Figure 4: Cross-section of kidneys of the group (T5) showed thickening wall (TW) of blood vessels, slough endothelium (SE) and infiltration of lymphocytes (LI) with fibrosis (F) H&E X400

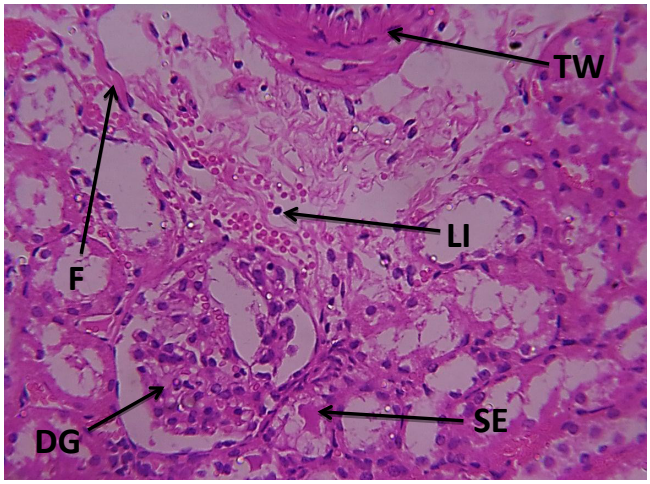

Figure 5: Cross-section of kidneys of the group (T4) showed damage of glomerulus (DG) and thickening wall (TW) of blood vessels, slough endothelium (SE) and infiltration of lymphocytes (LI) with fibrosis (F) H&E X400

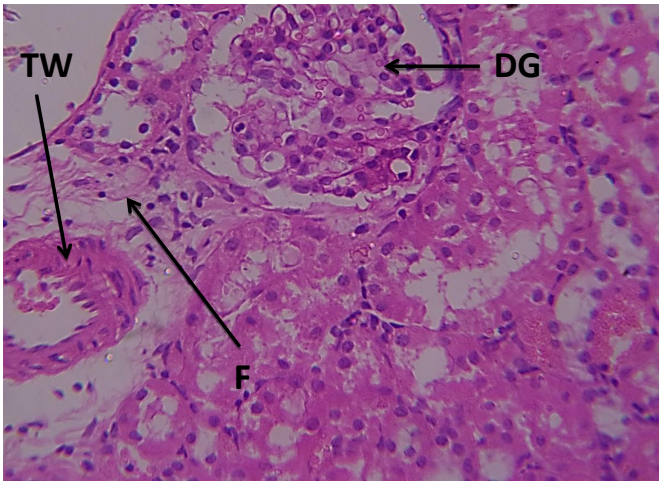

Figure 6: Cross-section of kidneys of the group (T6) showed damage of glomerulus (DG) and thickening wall (TW) of blood vessels with fibrosis (F) H&E X400

It is in agreement with some researches[12] which indicated that oral administration of aflatoxin B1 in different strains of mice, rats, and hamsters caused renal cell tumors with a lower incidence of tumors in other sites including the liver and colon; While taking aflatoxin G1 orally causes alteration of hepatocytes, hepatocellular adenomas, carcinomas and renal cell adenomas. Great emphasis has been placed on hepatocellular tumors caused by these mycotoxins. However, there is evidence that although the liver may be the primary site of tumor induction, other tumors may occur in the gastrointestinal tract. These are mainly from the digestive tract (esophagus, glandular stomach, duodenum, and colon in rats) and possibly also the salivary gland.[12] Kidney epithelial tumors can also be induced by aflatoxin G1. In their experiments, aflatoxin G1 produces a high proportion of such tumors, while it is rarely seen after aflatoxin B1, this may be because aflatoxin caused oxidative damage and caused the formation of free radicals that interacted with the cellular component and led to pathological changes in liver and kidney function.[14]

CONCLUSION

The current results showed that there were significant ($p \leq 0.05$) differences between the study groups. The current results showed that the group given infected 100% wheat showed a significant increase in creatinine and urea levels compared with control group. On the other hand, it was observed that the group given infected 100% rice showed a significant increase in the levels of creatinine and compared with the control group given regular rice. Different histological lesions were diagnosed in the histological study, including damaged glomerulus and urinary tubules with lymphocytes infiltration and the thickening wall of blood vessels.

REFERENCES

1. Kebede H, Liu X, Jin J, Xing F. Current status of major mycotoxins contamination in food and feed in Africa. Food Control. 2020 Apr 1;110:106975.
2. Phillips T. and James E T. Biorational Approaches to Managing Stored-Product Insects. Ann. Rev. Ent. 2009;55(1):375-397.
3. Rajendran S, Sriranjini V. Plant products as fumigants for stored-product insect control. Journal of stored products Research. 2008 Jan 1;44(2):126-135.
4. Padın S, Dal Bello G, Fabrizio M. Grain loss caused by Tribolium castaneum, Sitophilus oryzae and Acanthoscelides obtectus in stored durum wheat and beans treated with Beauveria bassiana. Journal of Stored Products Research. 2002 Jan 1;38(1):69-74.
5. Miller JD. Mycotoxins. In Encylopedia of food science and technology. Edited by F.J. Francis John Wiley, New York. 1999; 1698-1706.
6. Barney RJ, Price BD, Sedlacek JD and Siddiqui M. "Fungal species composition and abundance on stored corn as influenced by several management practices and maize weevil. (Coleoptera: Curculionidae)", Crop Protection 1995;14(2):159-164.
7. Hagstrum DW, Klejdysz TZ, Subramanyam Bh. Nawrot J. Atlas of Stored-Product Insects and Mites. Am. Assn. Cereal. Chem. (AACC) Int., St. Paul, Minnesota, USA, XX; 2013.
8. Hagstrum DW, Phillips TW. Evolution of Stored-Product Entomology: Protecting the World Food Supply.Annu. Rev. Entomol; 2017;62:379-397.
9. Tömösközi-Farkas R, Daood HG. Modification of chromatographic method for the determination of benzoquinones in cereal products. Chromatographia. 2004 Jul;60(1):S227-230.
10. Rajmon R, Sedmikova M, Jilek F, Koubkova M, Hartlova H, Barta I, Smerak P. Combined effects of repeated low doses of aflatoxin B~ 1 and T-2 toxin on the Chinese hamster. VETERINARNI MEDICINA-PRAHA-. 2001 Nov 1;46(11/12):301-308.
11. Li H, Xing L, Zhang M, Wang J, Zheng N. The toxic effects of aflatoxin B1 and aflatoxin M1 on kidney through regulating L-proline and downstream apoptosis. BioMed research international. 2018 Aug 12;2018.
12. IARC (1993) Chemicals, Groups of Chemicals, Complex Mixtures, Physical and Biological Agents and Exposure Circumstances to be Evaluated in Future IARC Monographs, Report of an ad-hoc Working Group.
13. Williams JH, Phillips TD, Jolly PE, Stiles JK, Jolly CM, Aggarwal D. Human aflatoxicosis in developing countries: a review of toxicology, exposure, potential health consequences, and interventions. The American journal of clinical nutrition. 2004 Nov 1;80(5):1106-1122.
14. Clifford JI, Rees KR, Stevens ME. The effect of the aflatoxins B1, G1, and G2 on protein and nucleic acid synthesis in rat liver. Biochemical Journal. 1967 Apr;103(1):258-261.