REVIEW ARTICLE

Use of the Erbium Yag Laser in the Treatment of Acne Scar for Male Patients

Hanaa H. Kadhim,[1] Ali K. Mohsin,[2] Murtadha H. Raheem[3]*

[1]College of Medicine, Sumer University, Rifai, Iraq
[2]College of Science,Wasit University, Wasit, Iraq
[3]College of Medicine, University of Kufa, Kufa, Iraq

Received: 18th March, 2021; Revised: 09th April, 2021; Accepted: 20th May, 2021; Available Online: 25th September, 2021

ABSTRACT

Erbium-doped yttrium aluminium garnet (Er:YAG) laser wavelength (2940 nm) was used to treat acne scars to a different type. There are many different characteristics related to the skin layer, such as the stimulation of the skin. The presented article discusses the technical aspects of the utilization of the Er:YAG laser, its preferential utilization has been most common in the dermatology areas, and the possible and side effects and hazards. Below are the photographs of the patients under this study before and after Er:YAG acne scar skin resurfacing. All of the patients had mixed trophic acne scar types, including the boxcar, ice pick, and rolling scars, even though some certain type is predominating, which is why it is utilized to classify patients in accordance. The difference in the protocols of treatment in addition to the scales of the evaluation that are utilized for the determination of the acne scarring severity in numerous clinical trials have made it difficult comparing the effectiveness of the variety of the fractional lasers that exist for treating the acne scars. In addition to that, studies that investigate the role of Erbium:YAG laser as the main choice in treating the atrophic acne scars are quite limited, which included 6 patient aged 18–25 years with the atrophic facial acne scars with Er:YAG laser. Acne scarring is one of the common dermatological conditions, causing cosmetic and psychological problems.

Keywords: Acne scar, Erbium Yag, Laser, Male.

International Journal of Drug Delivery Technology (2021); DOI: 10.25258/ijddt.11.3.77

How to cite this article: Kadhim HH, Mohsin AK, Raheem MH. Use of the Erbium Yag Laser in the Treatment of Acne Scar for Male Patients. International Journal of Drug Delivery Technology. 2021;11(3):1103-1106.

Source of support: Nil.

Conflict of interest: None

INTRODUCTION

The acronym laser, has its popularity in many places because of its usage. The laser is being used in diverse areas like industrial application, entertainment, data storage, military weapons, space communication systems, medicine, etc. It is limited with its uses and is adopted in many developmental fields related to research such as theoretical generation of laser, beam characteristics, design of laser system, and operating principle. Fundamentally, there are various names for generating laser equipment concerning its laser beam. However, the main components of the laser system are as follow:[1]

a) Active Medium or Gain Medium.
b) High Reflective Mirror.
c) Output Coupler.
d) Converging lens.
(e) Pumping Mechanism or Excitation.

ER: YAG LASER

Laser resurfacing of the facial skin is one of the most common methods of the removal of scars and rhytides, in 1990's; the high-energy, short-pulse CO_2 lasers have become the most common approach that was used for those reasons. Numerous researches were published, describing several treatments and approaches with various high–energy, short–pulse CO_2 laser facial skin resurfacing. The enthusiasm for those systems was decreased due to the lengthy period of recovery, the persistent erythema that has been observed in numerous patients, and the limited margins of safety that lead long-term side effects, even by the most experienced laser surgeons. Er:YAG laser, with the 2940 nm wavelength, creates the energy in mid infrared spectrum of the invisible light. Such wavelength has 10–15 times higher water absorption rate compared to the CO_2 laser at 10.600 nm wavelength. Er: YAG laser can produce a 250–350 microsecond pulse, which is less than the skin thermal relaxation time equals 1millisecond. In addition to that, Er: YAG laser results in causing the ablation of the tissues with very little desiccation and vaporization of the tissue in Figures 1 and 2.

ACNE SCARING

Acne vulgaris has been considered a multi-factorial chronic inflammatory skin disorder associated with various environmental and genetic factors in the portions of sebaceous

*Author for Correspondence: murtadhah.aljanabi@uokufa.edu.iq

gland. The clinical impact of the disease can drastically vary from a mild comedonal stage to a fulminant impact of the disease. This disease commonly affects all categories of aged people, but the people in the adolescent stage are more prone to infection.[13]

TYPES OF ACNE SCARS

Acne scars may exist in multiple forms like,

A. Superficial Macular Scars: This type of scar occurs in the epidermal and superficial dermal layer regions in the form of discolored erythematous macules. They do not undergo any form of thickenings in the surface layer of the skin. Additionally, these scars appear to be inflamed and cause damage to the skin associated with modified pigmentation skin disorders.[17]

B. Ice Pick Scars: These scars usually appear in a cone shape and are considered to be sharp, pointed, narrow (>2 mm) range prolonging to the marginal regions of the epithelial tract that continues vertically in the regions of dermal and subcutaneous tissue layers. The damaged surface opening does not appear more spacious than the funnel-shaped infundibulum as the ice pick scars elongate from the surface layer to its extreme possible spot,[18,19] as represented in Figures 3 and 4.

C. *R*olling Scars: This type of scar appears in a wavy fashion, which commonly occurs in dermal and epidermal regions of the skin. These scars appear in a wide diameter ranging from more than 4 to 5 mm. Anchoring fibrils in collagen VII molecules usually look abnormal in the dermal-epidermal linkage directing to the rolling or swelling appears in the skin layer[20,21] as represented in Figure 3 and 4.

D. Boxcar Scars (Chickenpox scar-like): These scars appear in the form of depressions like round continued to oval in shape associated with a pointed vertical edge, which looks similar to scars appearing during varicella infections. These scars look more exhaustive than the ice pick scars at the dermal layer of the skin but clinically does not taper to a deep portion inside the skin layer. Hence, they might exist in various forms comprising shallow range (0.1mm–0.5mm) or deep-tapered (>0.50 mm) or most commonly exist in diameter of 1.5 to 4 mm as represented in Figures 3 and 4.

E. Hypertrophic scars: These scars appear like other tissues formed, but they are restricted within the marginal layer of the damaged region. These are considered to be most prevalent during the initial period, and there may be an existence of remission occurring spontaneously in the event of post-injury in Figures 3 and 4.[22]

F-. Keloids: Keloids commonly protrude from the originally injured regions with the overgrowth of tissues that lead to the deposition of excess collagen VII molecules in marginal layers of dermal-epidermal regions of the skin. These keloids usually appear on the shoulders, ears, back, and chest in various sizes and might be infectious even after wound healing. The scars that appear due to these keloids might not disappear for a long time or even a lifetime. These keloids are not gender-specific, but they are less commonly visualized in young and older adults. There might be an influence of genetic inheritance, symbolizing both dominant and recessive characters in an autosomal mode in Figures 5 and 6.[23]

Laser-tissue Interactions

When the beam of laser strikes skin, there are 4 possible interaction cases: it may be absorbed, reflected, transmitted, or scattered. Only 4–7% of the light gets reflected off the skin (least reflectance with perpendicular incident light). The remaining 93–96% of incident light enters the skin, scattered, absorbed, or transmitted.[24] The scattering occurs when the particles in skin spread incoming light beam in every direction, limiting its penetration depth. The light undergoes transmission in the case where it passes through the unaltered tissue.[25] Generally, tissue effects occur only in the case where the light is absorbed (Figures 7 and 8).[25,26]

Several terms have been defined for understanding the effectiveness of laser in human tissue interaction:

1. *Fluence:* Quantity of energy per unit area, in (J/cm^2).
2. *Power:* Quantity of energy over an interval of time measured in Watts (W).
3. *Power density* (Pd): Quantity of Power per unit area in (W/cm^2).
4. *Thermal relaxation time (τ therm):* Time needed for the heated tissues to lose 50% of its temperature through diffusion, in second (s).
5. *Spot size:* laser beam diameter on the skin's surface in millimeter (mm).
6. *Pulse duration (Sd):* Laser exposure time, in second (s).
7. *Chromophore:* Region in the molecule that absorbs light.

RESULTS

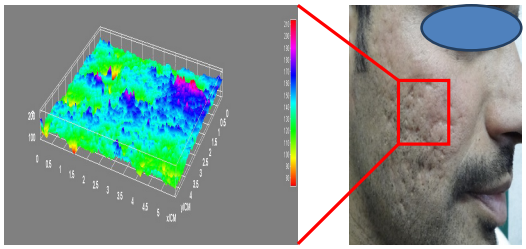

Figure 1a: The patientbefore using laser and showing the target area in left 3D picture after comparison with acne scar modelshows ice pickscar type.

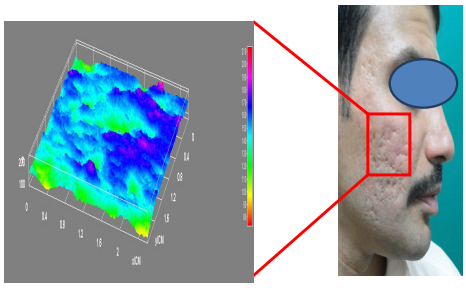

Figure 1b: The patientafterusing laser and showing the target area in left 3D picture.

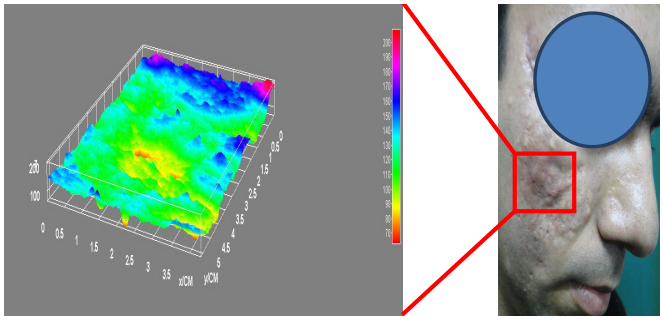

Figure 2a: The patientbefore using laser and showing the target area in left 3D picture after comparison with acne scar model shows ice pick scar type.

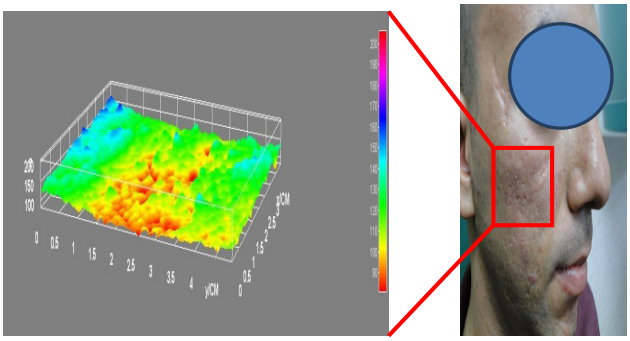

Figure 2b: The patientafter using laser and showing the target area in left 3D picture.

Figure 3: Type acne scars

Figure 4: Type acne scars

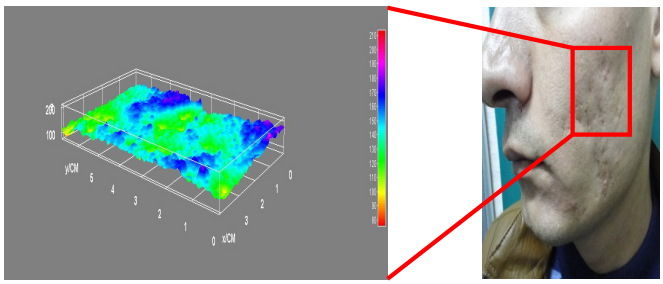

Figure 5: The patientbefore using laser and showing the target area in left 3D picture after comparison with acne scar model shows ice pickscar type.

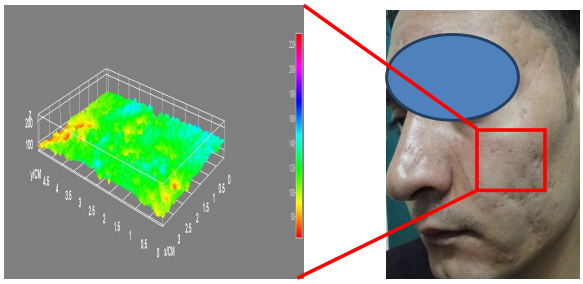

Figure 6: The patientafterusing laser and showing the target area in left 3D ice pickpicture.

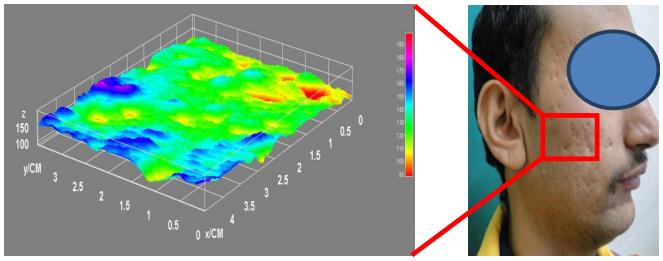

Figure 7: The patientbefore using laser and showing the target area in left 3D picture after comparison with acne scar model shows ice pick scar type.

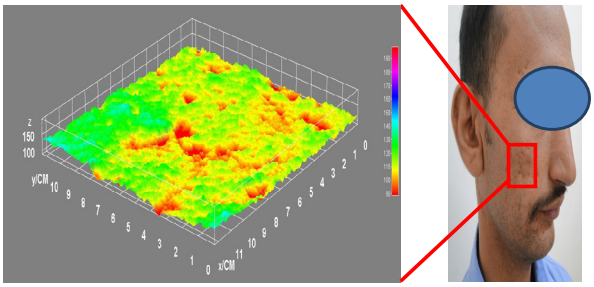

Figure 8: The patient after using laser and showing the target area in left 3D picture.

DISCUSSION

Nowadays of skin rejuvenation can be defined as one of the significant elements of cosmetic surgery. This study done inresearchesUite, Medicine College, Kufa Univ. The objective of the skin resurfacing is removing the damaged upper dermis and epidermis and promoting the formation of new, undamaged dermis and epidermis and resurfacing skin through the removal of skin scar shoulders and creating a new smooth skin surface. The optimal skin resurfacing approach is an approach that can accurately remove the abnormal dermis and epidermis and precisely determine the depth. Reliability and safety are significant criteria as well in the case of comparing various skin remodeling methods. In the present study, Iraqi patients (11 male) were treated with 2940nm ablative non- fractional Er:YAG laser device for their atrophic acne scars to evaluate its effectiveness and safety.

At the end of this study, an enhancement was observed in objective and subjective methods, and there is no significant residual complications.The efficacy of the Er:YAG laser and other laser systems have been permitted by the selective photo-thermolysis principle, along with the underlying interactions between the laser and the tissues and successive biological responses.

In theory, the action mechanism of laser resurfacing includes tissue ablation, dermal collagen remodeling, and immediate shrinkage of the collagen. This work has shown that the ablative non- fractional Er:YAG laser (2940nm) can be a safe and effective approach for treating acne scars in Iraqi patients.

Limitations of the present work include the small size of the sample, few sessions, and a short period of the follow-up, so a longer up is required to detect any further improvement due to continuous collagen remodeling.

REFERENCES

1. Al-Dhalimi M, and Jaber A. Treatment of atrophic facial acne scars with fractional Er: Yag laser. Journal of Cosmetic and Laser Therapy, 2015;17(4):184–188.
2. Layton A. Disorders of the sebaceous glands. Rook's textbook of dermatology, 2010;1:1–89.
3. Jacob CI, Dover JS, and Kaminer MS. Acne scarring: a classification system and review of treatment options. Journal of the American Academy of Dermatology, 2001. 45(1): 109-117.
4. Jemec GB and Jemec B. Acne: treatment of scars. Clinics in dermatology, 2004;22(5):434–438.
5. Alestas T. et al., Enzymes involved in the biosynthesis of leukotriene B 4 and prostaglandin E 2 are active in sebaceous glands. Journal of molecular medicine, 2006;84(1): 75–87.
6. Makrantonaki E. and Zouboulis C. Testosterone metabolism to 5α-dihydrotestosterone and synthesis of sebaceous lipids is regulated by the peroxisome proliferator-activated receptor ligand linoleic acid in human sebocytes. British Journal of Dermatology, 2007;156(3):428–432.
7. Rivera AE. Acne scarring: a review and current treatment modalities. Journal of the American Academy of Dermatology, 2008;59(4):659–676.
8. Nagy I et al., Propionibacterium acnes and lipopolysaccharide induce the expression of antimicrobial peptides and proinflammatory cytokines/chemokines in human sebocytes. Microbes and infection, 2006;8(8):2195–2205.
9. Suri HS et al., Pulmonary langerhans cell histiocytosis. Orphanet journal of rare diseases, 2012;7(1): 1–13.
10. Romero AM, and Robert A. Stereotactic body radiation therapy for primary and metastatic liver tumors: from technological evolution to improved patient care. Best Practice & Research Clinical Gastroenterology, 2016;30(4):603–616.
11. Herd RM, Dover JS, and Arndt KA. Basic laser principles. Dermatologic clinics, 1997;15(3):355-372.
12. Manstein D et al. Fractional photothermolysis: a new concept for cutaneous remodeling using microscopic patterns of thermal injury. Lasers in Surgery and Medicine: The Official Journal of the American Society for Laser Medicine and Surgery, 2004; 34(5):426-438.