RESEARCH ARTICLE

A Histological Study of the Effect of Strawberry Juice on Reducing Cholesterol-induced Effects in White Male Rats and Treating Renal Failure

Wurood M. Mutar*, Rasha H. Ayub

Department of Biology, College of Education, University of Samarra, Saladin, Iraq

Received: 30th August, 2021; Revised: 26th September, 2021; Accepted: 28th November, 2021; Available Online: 25th December, 2021

ABSTRACT

This study was conducted from March-May 2021. It included 4 groups of male albino rats for 60 days. The high level of fat leads to kidney injuries and failure in its functions. Whereas, the group treated with 2% cholesterol in the diet showed a significant increase ($p < 0.05$) in the levels of low-density lipoprotein (LDL), total cholesterol (TC), triglyceride (TG), and body weight. There was no significant difference between the other groups. Whereas, treatment with strawberries at a concentration of 7 mL/kg per day led to returning the cholesterol level to almost normal levels. The administration of strawberry juice led to the treatment of kidney tissue from the damage caused by high cholesterol to the renal tubules, renal glomeruli, and Henle loops, and returned them to their normal position.

Keywords: Strawberry juice, Hypercholesterolemia, Kidney failure

International Journal of Drug Delivery Technology (2021); DOI: 10.25258/ijddt.11.4.20

How to cite this article: Mutar WM, Ayub RH. A Histological Study of the Effect of Strawberry Juice on Reducing Cholesterol-induced Effects in White Male Rats and Treating Renal Failure. International Journal of Drug Delivery Technology. 2021;11(4):1238-1243.

Source of support: Nil.

Conflict of interest: None

INTRODUCTION

Diet and lifestyle play a significant effect in human health, according to studies.in causing kidney disease. Where a high-cholesterol diet appears to cause high blood pressure and kidney injury.[1] In the developed and third world countries, the incidence of acute and chronic kidney diseases and disorders is rising.[2] The risk of infection has serious complications that may be short or long in time, and the onset and fast progression of chronic kidney disease of the disease may lead to death.[3]

Hypercholesterolemia is one of the most common risk factors: chronic kidney disease (CKD) and acute kidney disease (AKD). Acute kidney failure is recognized by the rapid or fatal absence of kidney function, which leads to the kidneys not being able to continue filtering body fluids, electrolytes, and acid-base balance, and the reason for piling up nitrogen metabolites such as urea. Creatinine or decreased urine output.[4] This leads to the accumulation of fat in the visceral tissue of the kidneys and harms its function due to the increased absorption of free fatty acids (FFAs) from high-fat food. And the low oxidation rate leads to the accumulation of intracellular fats in non-fatty tissues. An increase in FFAs can damage Podocytes, Proximal Tubular Epithelial Cells, and Tublue interstitial tissue due to increased production of reactive oxygen species (ROS), Lipid peroxidation Mitochondrial damage tissue inflammation, leading to glomerular and tubular lesions.[5]

A relationship between excessive cholesterol and renal impairment has been established by researchers.[6] Most adults over half have high cholesterol levels.[7] The majority of past research has focused on the effects of elevated blood cholesterol on the kidneys. According to these studies, focal glomerulosclerosis and proteinuria develop fast, leading to kidney failure.[8]

Strawberries are characterized by containing high amounts of phenol and are a loaded source of Ascorbic acid, anthocyanins, and folic acid, and are rich in dietary fiber, glycosides, kaempferol, and quercetin, and a high content of Ellagic acid and tannins. Strawberry fruits are eaten fresh and made into jams and sweets, their leaves are used for therapeutic purposes in tea mixtures, and the juice of the fruits is used as a treatment for humans suffering from various diseases.[9] Recently, researchers have focused their attention on the benefits of strawberry fruits in lowering high levels of fat, which may lead to atherosclerosis and damage to the rest of the organs.[10]

The purpose of our study was to examine the effects of strawberry consumption on circulating lipid concentrations and LDL oxidation, a marker of oxidative stress.

MATERIALS AND METHODS

Plant Collection

The strawberry fruits were obtained from local markets for the period from March-May 2021 and they are fresh, and the method described by some researchers[11] was followed, where the fruits were washed and cut into small parts, and then pressed by a blender to obtain strawberry juice, and the juice was discarded with a machine Centrifuge at a speed of 3000 rpm

*Author for Correspondence: wuroodbio6@gmail.com

for 15 minutes, then filter the filtrate with filter paper and keep at 4°C until use.

Experience Design

Experiments were conducted performed in line with the ethical guidelines adopted by the Iraqi association for animal protection and have been accepted by the Biological Society of Iraq Animal Research Ethics Committee. In this experiment, 24 male Sprague dawelu white laboratory rats were obtained from the animal house of the College of Veterinary Medicine at University Tikrit, Tikrit, Iraq. The weights ranged from 170 to 190 gms and their ages ranged from 8 to 10 weeks. The animals were given a week to adapt to the environmental conditions and the temperature and lighting cycle were held constant. The animals were divided into four groups, and the weights were taken in each week of the experiment, and each group contained six males. The weight of the animals was calculated on the first day of the experiment and the weights were taken at the end of the experiment after 60 days. The first group was the control and was dosed with a normal saline solution, the second group was given with the diet 2% cholesterol (BHD England) daily for 60 days, the third group was given 7 mL/kg/day of strawberry juice for 2 months, the fourth group was given a diet containing 2% cholesterol and dosed with juice Strawberries 7 mL/kg/day for 2 months. After the end of the experiment, the animals were anesthetized with dimethyl ether and the kidneys were collected.

Biochemical Test

Total cholesterol (TC), TG, HDL-Cholesterol (HDL-C), and LDL-Cholesterol (LDL-C) were obtained from heart serum blood at the end of the experiment and were determined according to the enzymatic commercially kits from BioMerix France. The concentrations of LDL-C were determined from the equation.[12]

Statistical Analysis

The differences between the groups were analyzed statistically by using the SPSS v.22 software. Data has been represented as ± SD. Statistical significance of data was calculated by the variance (one-way ANOVA) analysis plus tuky check post hoc. $p < 0.05$ has been significant.

Histological Study

The kidneys were taken after 8 weeks and washed with normal saline and fixed with formalin 10% for a period of 24–48 hours and then washed with running water for half an hour and put with ethanol alcohol from 50–70–80–90–100–100% for an hour in each concentration to withdraw the dehydrated water and then buried The molten paraffin-embedded at a temperature of 60–62°C for a period of two hours was poured into the wax molds, then cut with a microtome of slee Germany 5 to 4 micrometers thick and stained with eosin-hematoxylin dye.

RESULT

The Lipid Profile and weight

The weight results showed significant changes in the average weight of the animals, as the treatment with G2 cholesterol led to a significant increase, while the animals treated with strawberry G3 decreased their weight from the start of the experiment, and the treatment with cholesterol and strawberry together G4 showed a small weight change.

The lipid profile showed a significant increase in the cholesterol group compared with the control group TC, LDL-C, TG, while it showed a decrease in the rate of HDL-C compared with the control group. As for the G3 group, the treatment led to a significant increase in the measurement of HDL-C and TC decreased. As for the G4 group, treatment with strawberry juice and cholesterol led to a decrease in TC, LDL-C, and TG, and it was close to the control group, and this is evidence that strawberry juice has a therapeutic effect in treating high fat, and this leads to the lack of fat accumulation and deposition as shown in Table 1.

Lipid profile parameters units are mg/dL; G1: Control; G02: 2% cholesterol; G3: 7 mL/kg/day of Strawberry juice; G04: strawberry juice and fed with 2% cholesterol, TC; TG; HDL-C; LDL-C: LDL-Cholesterol; Differences a,b,c are significant ($p \leq 0.05$) to compare between columns while there were non-significant ($p \leq 0.05$) differences between the same letters.

Effect of Strawberry Juice on Kidney Tissue

The results of the current study for the first group control G1: showed the normal shape of the glomerulus and the capsule Space (Figure 1).

The second group G2, which was induced with 2% cholesterol, showed that the cortex of the kidney was containing glomeruli, the glomerulus was atrophied slightly and segmented with the presence of many lymphocytes on its surface, also the capsular space around the glomerulus was wide, the distal convoluted tubules were wide in its lumen and have many sloughed cell, the lymphocytes were infiltrated between the convoluted tubules (Figure 2). However, The cortex of the kidney was containing atrophied glomeruli with segmentation, and its surface was infiltrated with lymphocytes, the capsular space was wide, the proximal convoluted tubules had normal structure, the distal convoluted tubules had wide lumens with the presence of remnant debris of cell (Figure 3). And The glomeruli of the renal cortex was

Table 1: The effect of strawberry juice on serum lipid profile levels and body weights

Group	*TC mg/dL*	*TG mg/dL*	*HDL-C mg/dL*	*LDL-C mg/dL*	*Weight*
G1	111 ± 1134a	102.2 ± 6.3a	41.2 ± 2.9ab	36.8 ± 3.3a	189.5 ± 7.5a
G2	202 ± 19.6b	163.8 ± 19.8b	24.5 ± 5.8c	75.2 ± 14.1b	290 ± 21.6b
G3	96.5 ± 10.8a	91.5 ± 6.4a	53.8 ± 5b	29.3 ± 2.9a	169 ± 4.5a
G4	120.8 ± 15.5a	111.3 ± 9a	38.5 ± 11.7ac	38.3 ± 2.7a	210 ± 18.5b

segmented into 4-5 segments, the capsular space was wide and the Bowman`s capsule was interrupted. Most of the blood vessels were congested with hemolysed blood. The interstitial connective tissue between the convoluted tubules was infiltrated with lymphocytes (Figures 4, and 5). The medulla of a kidney was containing the renal tubules, lined with simple cuboidal cells, the interstitial connective tissue was containing collagen fibers with fibroblasts, the blood capillaries in the interstitial connective tissue was congested with hemolyzed blood, surrounded with lymphocytes (Figure 6).

The third group G3: which was fed strawberry juice 7mL/kg/day in Figure 7. showed The renal cortex had normal glomeruli and normal Bowman's capsule. the proximal convoluted tubules and distal convoluted tubules are also normal in shape and structure and have no appearance lesions in tissue (Figure 7).

In, the last group G 4: which fed strawberry juice 7 mL/kg/day with 2% cholesterol appeared The renal cortex had glomeruli with mild atrophy, surrounded with the proximal convoluted tubules which were normal and the distal convoluted tubules had fibrinous edema (Figure 8). However The glomeruli of the renal cortex were normal in size and shape, the proximal and distal convoluted tubules were containing hypertrophied epithelial cells and the lumens of these tubules were rarely seen (Figure 9). and The renal cortex was invested by a capsule which was seen of delicate connective tissue, the renal glomeruli were normal and other was seen with the presence of vacuolated cytoplasm of glomerular epithelial cell, and its capsular space was wide peripherally, the lumen of certain tubules had fibrinous edema with cellular debris (Figure 10). The interstitial connective tissue with lymphocytes had congested blood capillaries, the renal tubules and Henle loops segments were normal (Figure 11).

DISCUSSION

The animal's consumption of a 2% cholesterol diet resulted in a significant increase in body weight, which is due to a defect in fat metabolism and absorption caused by cholesterol's effect on the mechanism of fat oxidation and thus its accumulation in various areas of the body, where cholesterol stimulates

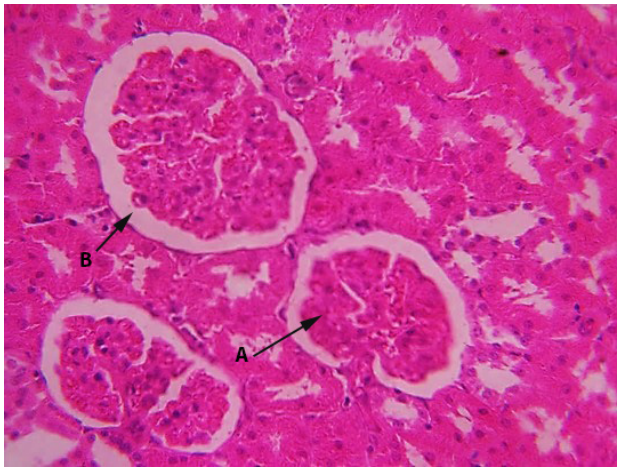

Figure 1: Kidney, Glomerulus, (A) Capsule space, (B) (H&E x40)

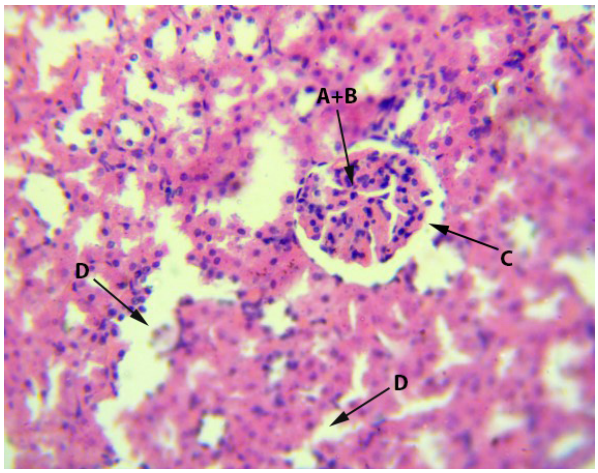

Figure 2: Renal cortex, slight atrophy of glomerulus (A) Lymphocytes, (B) Capsular space, (C) Sloughing cell in the lumen of convoluted tubules, (D) (H&E x40)

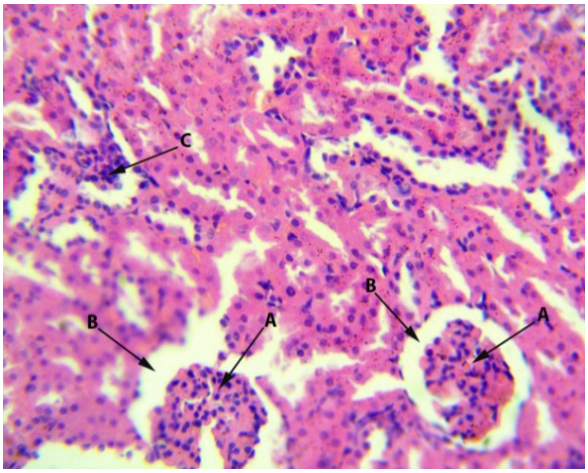

Figure 3: Atrophied glomeruli with segmentation (A) with lymphocytes on its surface widening of capsular space; (B), Lymphocytic aggregation; (C) (H&E x40)

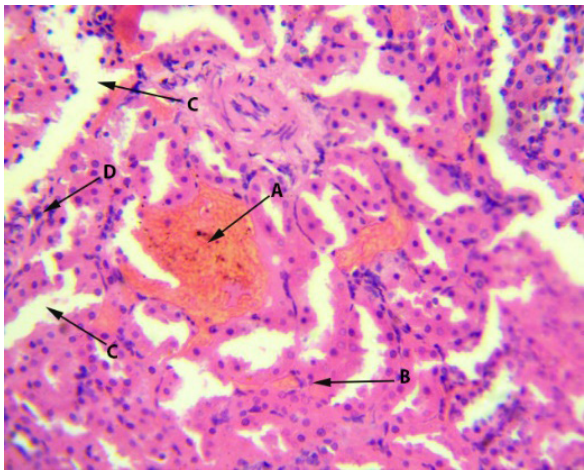

Figure 4: Congestion of renal blood vessels (A), Proximal convoluted tubules; (B), Distal connective tissue; (C), Lymphocytes; (D). (H&E x40)

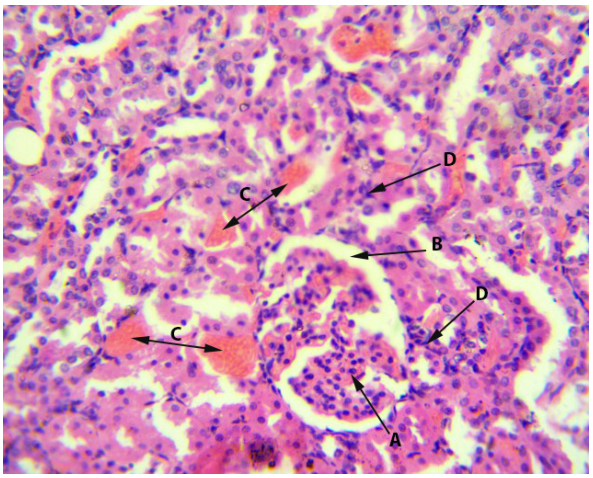

Figure 5: Segmentation of renal glomerulus (A), Interruption of Bowman's capsule(B), Congested blood vessels with hemolyzed blood(C), Lymphocytic infiltration (D). (H&E x40)

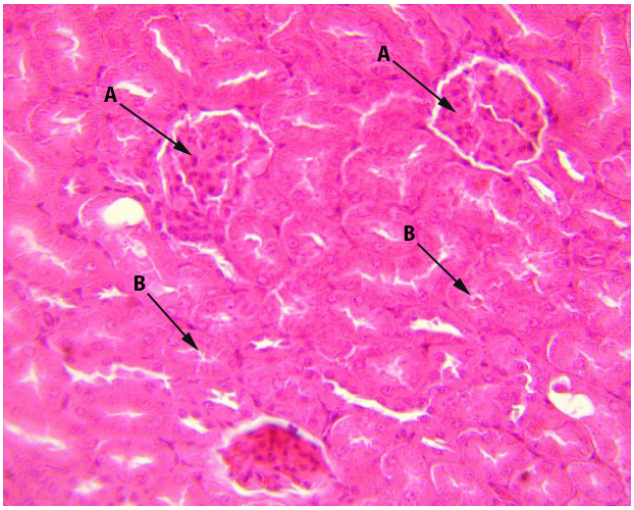

Figure 9: Normal size and texture of glomeruli (A), Hypertrophied epithelial cell of proximal and distal connective tissues (B). (H&E x40)

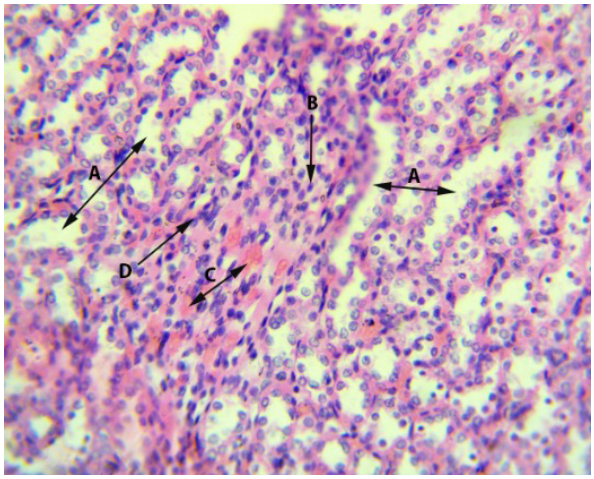

Figure 6: Medulla of kidney, renal tubules (A), interstitial connective tissue with fibroblasts (B), Congestion of blood capillaries (C), Lymphocytes (D). (H&E x40)

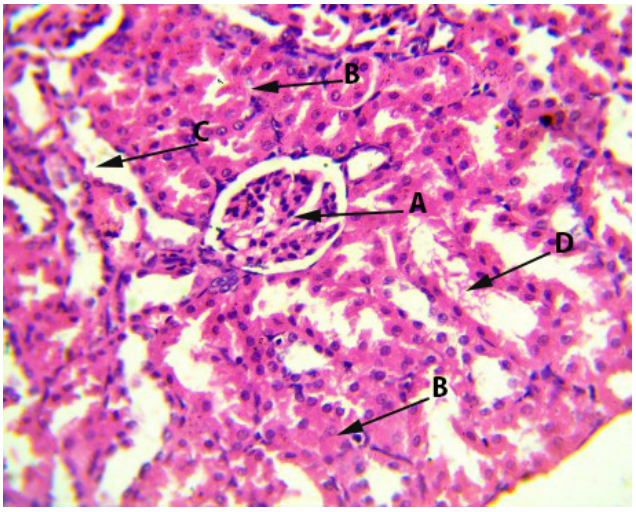

Figure 8: Renal cortex mild atrophy of glomerulus (A) proximal convoluted(B), distal C.T. (C) fibrinoid edema (D). (H&E x40)

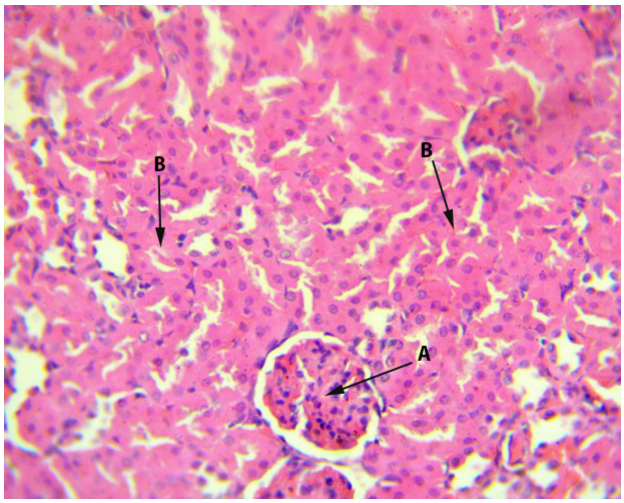

Figure 7: Renal cortex, normal glomerulus (A), Normal proximal and distal convoluted tubules (B). (H&E x40)

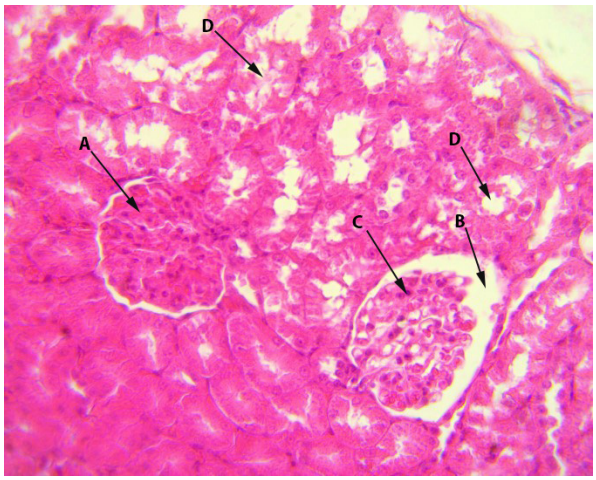

Figure 10: Normal size of the glomerulus (A), Capsular space (B), Vacuolated cytoplasm of the glomerular epithelium (C), Fibrinous edema (D). (H&E x40)

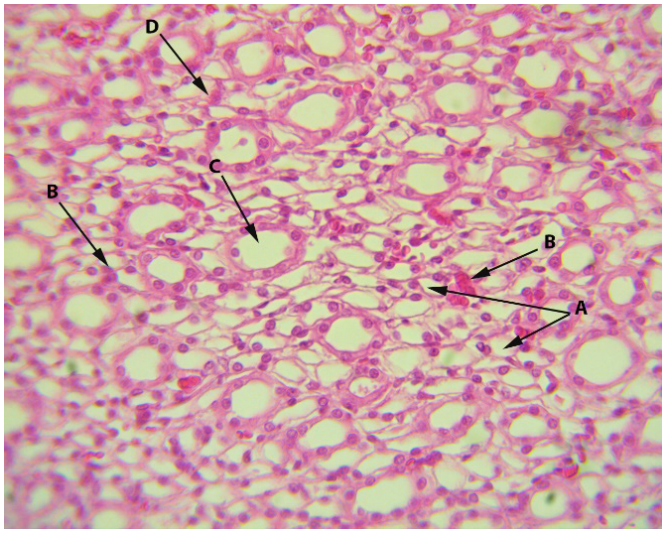

Figure 11: Interstitial connective tissue with lymphocytes (A), Congested blood capillaries; (B), Renal tubules; (C), Thin segments of Henle loops(D). (H&E x 40)

the synthesis of hormones such as cortisol, testosterone, and estrogens. Which represent steroid hormones and these hormones contribute to an increase in body weight.[13] In contrast to the other groups, weight was reduced, and this is due to the phenolic compounds possessed by strawberry juice, as it leads to fat reduction and thus weight reduction by reducing the growth of adipocytes and preventing the accumulation of fat through the events of the cell cycle.[14,15] And dyslipidemia, as demonstrated by the increase in the levels of total cholesterol in the blood significantly, and is consistent with the study conducted by other researchers,[16] which led to high levels of fats in the blood as a result of an imbalance in the metabolism of fats a noticeable loss in the level of HDL-C and thus change the metabolism of lipids And lipoproteins and their excess lead to nephrotic syndrome.[17,18] Our renal histological findings are consistent with what was mentioned.[6] One of the target cell types for hypercholesterolemia is mesangial because it binds lipoproteins through expressed receptors, which can lead to lipid accumulation and glomerular dysfunction.[19] One of its main roles in causing glomerular injury is through the production of the extracellular matrix. The reason for the damage in the kidney tissue is because excess fat increases the stimulation of energy houses and generates ROS and decreases glutathione with a weakness in the work of antioxidants, which causes the generation of oxidative stress, as it leads to lipid peroxidation, which is one of the causes of nephron poisoning and damage to renal tissue because Hypercholesterolemia is associated with oxidative stress that results from increased ROS production and impaired antibody system.[20] It is believed that the result of the accumulation of fat in the kidneys leads to kidney disease[21] because it's associated to macrophage infiltration, which triggers the release of pro-inflammatory cytokines containing tumor necrosis factor causing kidney injury.[21] Damage to the glomeruli and tubules and bleeding in the blood vessels as a result of gaps in the lining of the blood vessels, thus causing red blood cells to exit from inside the vessels, leading to hemorrhage and necrosis of the renal tubules resulting from the effect of free radicals that disrupt metabolic processes, which causes necrosis and stimulates defense cells and increases Infiltration and thus damage occurs.[22] Studies indicate that prolonged consumption of strawberry juice improves the cholesterol-lowering effect over time. It was earlier[23]observed that a 6 and 11% decrease in LDL-C concentration after taking strawberries for 4 and 8 weeks, respectively.[14] It also reported a decrease in LDL cholesterol and total cholesterol after feeding strawberries 454 g per day for a month.

CONCLUSION

This study showed that the use of strawberry juice led to lowering the level of lipids (cholesterol, triglycerides, and low-density lipids) and raising the level of high-density lipids while reducing the weights of the studied rats, and the ability of strawberry juice to prevent damage to the kidney tissue of the affected rats.

REFERENCES

1. Al-Rejaie SS, Abuohashish HM, Alkhamees OA, Aleisa AM, Alroujayee AS. Gender difference following high cholesterol diet induced renal injury and the protective role of rutin and ascorbic acid combination in Wistar albino rats. ipids Health Dis 2012 Dec;11(41):1-10.
2. Lameire NH, Bagga A, Cruz D, De Maeseneer J, Endre Z, Kellum JA, Liu KD, Mehta RL, Pannu N, Van Biesen W, Vanholder R. Acute kidney injury: an increasing global concern. Lancet. 2013 Jul 13;382(9887):170-1799.
3. Rewa O, Bagshaw SM. Acute kidney injury-epidemiology, outcomes, and economics. Nature Reviews. Nephrology 2014; 10(4):193-207.
4. Bellomo R, Kellum JA, Ronco C. Acute kidney injury. Lancet. 2012 Aug 25;380(9843):756-766.
5. Gai Z, Wang T, Visentin M, Kullak-Ublick GA, Fu X, Wang Z. Lipid accumulation and chronic kidney disease. Nutrients. 2019 Apr;11(4):722.
6. Ghada AH. Effect of Red Grape Juice on Renal Glomeruli in Hypercholestremic Rats. Life Science Journal 2014;11(6).
7. Chade AR, Mushin OP, Zhu X, Rodriguez-Porcel M, Grande JP, Textor SC, Lerman LO. Pathways of renal fibrosis and modulation of matrix turnover in experimental hypercholesterolemia. Hypertension, 2005;46(4):772-779.
8. Deepa PR, Varalakshmi P. Favourable modulation of the inflammatory changes in hypercholesterolemic atherogenesis by a low-molecular-weight heparin derivative. Int. J. Cardiol. 2006;106(3):338-347.
9. Aprona P. Micropropagation and field evaluation of Strawberry in Bangladish, MSc Thesis, Departmant of Botany, University of Rajishahi, Bangladish. 2006.
10. Azzini E, Intorre F, Vitaglione P, Napolitano A, Foddai MS, Durazzo A, Fumagalli A, Catasta G, Rossi L, Venneria E, Testa MF. Absorption of strawberry phytochemicals and antioxidant status changes in humans. J. Berry Res. 2010 Jan 1;1(2):81-89.
11. Kyung KH, Fleming HP. Antibacterial activity of cabbage juice against lactic acid bacteria. J. Food Sci. 1994 Jan;59(1):125-129.
12. Friedewald WT, Levy RI, Fredrickson DS. Estimation of the concentration of low-density lipoprotein cholesterol in plasma,

without use of the preparative ultracentrifuge. Clin Chem. 1972, 18;499-502.

13. Fidèle N, Joseph B, Emmanuel T, Théophile D. Hypolipidemic, antioxidant and anti-atherosclerogenic effect of aqueous extract leaves of C assia. occidentalis Linn (Caesalpiniaceae) in diet-induced hypercholesterolemic rats. BMC complementary and alternative medicine, 2017;17(1):76.
14. Jenkins DJ, Nguyen TH, Kendall CW, Faulkner DA, Bashyam B, Kim IJ, Ireland C, Patel D, Vidgen E, Josse AR, Sesso HD. The effect of strawberries in a cholesterol-lowering dietary portfolio. Metabolism. 2008 Dec 1;57(12):1636-44.
15. Stwick JC. Effect of the flavonoid Quercetin on adipocytes. Master of Science,University of Massachusetts, 2011;21-23.
16. Khaleel ZI, Mohammed ZH, AL-Samarraie MQ. Histological Effect of the Alcoholic Extract of Nerium Oleander in the Heart and Brain in Mice and its Effect on the Lymphocytes (In Vitro). Indian J Public Health Res Dev .2019;10(8):2362-2366.
17. Mohd Adzim Khalili R, Norhayati AH, Rokiah MY, Asmah R, Siti Muskinah M, Abdul Manaf A. Hypocholesterolemic effect of red pitaya (Hylocereus sp.) on hypercholesterolemia induced rats. Int. Food Res. J. 2009;16(3):431-440.
18. Vaziri ND. Disorders of lipid metabolism in 17 nephrotic syndrome: mechanisms and consequences. Kidney Int 2016; 90:41-2.
19. Bruneval P, Bariéty J, Bélair MF, Mandet C, Heudes D, Nicoletti A. Mesangial expansion associated with glomerular endothelial cell activation and macrophage recruitment is developing in hyperlipidaemic apoE null mice. Nephrol Dial. 2002 Dec 1;17(12):2099-3107.
20. Mustafa MA, AL-Samarraie MQ. Secondary menopause and its relationship to hormonal levels among women at Salah Al-Din Hospital. Eur. j. mol. 2020;7(9):96-104.
21. Dinh CH, Yu Y, Szabo A, Zhang Q, Zhang P, Huang XF. Bardoxolone methyl prevents high-fat diet-induced colon inflammation in mice. J. Histochem. Cytochem. 2016 Apr;64(4): 237-55.
22. Krishna V. Text book of pathology, printed in India by offset himayatnager. Hyderatbad 500029 (A.P) India, MBBS (Mysore) MD (PGI Chandigarh) consultan pathologist, Chennai. 2004
23. Basu A, Wilkinson M, Penugonda K, Freezedried strawberry powder improves lipid profile and lipid peroxidation in women with metabolic syndrome: baseline and post intervention effects. Nutr J. 2009;8:43-49.