RESEARCH ARTICLE

Anatomical and Histological Revision of Bulbourethral Gland in Reproductive System of Male Hamster

Methak A. A. A. Al-Shemkhi*[1], Zainab S. Mohammed[2], Zahraa S. R. Najjar[1], Wijdan K. N. Al-Qraawy[1]

[1]*Department of Biology, Faculty of Education for Girls, Kufa University, Najaf, Iraq*
[2]*Department of Pharmaceutical and Laboratory Science, College of Pharmacy, Ahl Al-bayt University, Karbala, Iraq*

Received: 19th December, 2021; Revised: 08th February, 2022; Accepted: 05th March, 2022; Available Online: 25th March, 2022

ABSTRACT

The anatomical consequences revealed that the bulbourethral glands in Syrian hamsters are in the form of a pair of small, oval-shaped glands and have a white color, similar to the fruit of a pea, each gland has a single duct that flows into the urethra, and these glands are buried under the cavernous bulbar muscle on both sides of the urethra. The length, width, and weight were about 0.7 cm, 0.4 cm, and 1-g. Histopathological outcomes presented that the bulbourethral glands are a complex tubular-alveolar gland, lined with simple columnar epithelium. These glands are multi-lobed, each lobe consists of small simple alveoli that are connected directly or through a narrow and short tube.

The goal of this study to know more anatomical and histological information for this gland for its significant and key role in the sexual reproduction.

Keywords: Bulbourethral glands, Hamster, Reproductive System.

International Journal of Drug Delivery Technology (2022); DOI: 10.25258/ijddt.12.1.33

How to cite this article: Al-Shemkhi MAAA, Mohammed ZS, Najjar ZSR, Al-Qraawy WKN. Anatomical and Histological Revision of Bulbourethral Gland in Reproductive System of Male Hamster. International Journal of Drug Delivery Technology. 2022;12(1):180-182.

Source of support: Nil.

Conflict of interest: None

INTRODUCTION

The Syrian hamster is a type of rodent that is used in experiments has global significance, as it has become today one of the most important laboratory animals on which scientific research is conducted in all parts of the world, as it is used in the diagnosis of human medical conditions, including various types of cancer and metabolic diseases.[1-5]

The posterior sexual glands, the seminal vesicle glands, the prostat and, bulbourethral glands, the ampullary, coagulating, and the prepuital glands play a major role in the function of M.R.S.[3,6-8] Glands around the pelvic urethra vary from one type to another, and sex hormones influence their growth and function. The cowper's or bulbourethral gland is unique of the later ascetic glands that play an important role in the male reproductive system function of different types of milk.[1]

The seminal secretion process in this gland usually takes place before ejaculation, and this substance works to cleanse the male urogenital tract of urine.[9-12]

The secretion of this gland contains glycoproteins that function as an immune defense line for the male reproductive system.[3]

In rodents, the secretion of this gland creates a gelatinous plug in females, which works to prevent the ejection of semen outside the body.[4]

The macroscopic and histological studies of these glands have shown significant differences between the several types of milk.[13,14] Secretions of these glands are usually released before ejaculation, which appears clearly on the urethra and the goal is to lubricate the vagina.[12]

Its secretions contain glycoprotein, which acts as an immune-defensive function in the urogenital system in males (2&3(. The researchers proved that the bulbourethral glands in camels are two amygdala-shaped glands located on both sides of the final parts of the pelvic urethra.

Some researchers[11] describe the bulbourethral glands in the inventory as a pair of glands located near the penis leg and can be seen visually in the white pea shape in between the bulbar cavernous muscles. These glands in the guinea pig are located behind the prostate gland in the dorsal part of urethra and on both sides of sciatic contractile muscle.[13]

MATERIALS AND METHODS

The study was conducted on three male Syrian hamsters (*Mesocrictus auratus*) whose ages ranged between (15–14)

**Author for Correspondence: dr.zaineb1988@gmail.com*

weeks brought from one of the animal stores in the holy city of Najaf, and their weights ranged between (300–400) gm. The animals were sacrificed by exposing them to a large amount of Chloroform, then opening the surface layer of skin in the pelvic region, and after opening the abdominal and pelvic cavity, the seminal vesicles and lymph nodes were removed from the prostate gland.

The anaplastic glands and lack of clarity of bulbourethral glands required to perform a pulling of the penis from the root area of the Crus to the top and towards the back to indicate the glands, as they appear on the side of the penis leg. After removing the fatty substances attached to these glands, their weight was recorded using a sensitive scale, and the dimensions of these glands were measured using a scale. A sensor and its dimensions were measured using Vernia, which included the length and width of thickness. For the histological study, hematoxylin-eosin H & E dye was used, and then the slides were examined by light microscope.

ANATOMICAL RESULTS

The bulbourethral glands appeared in hamsters in the form of a pair of small glands, oval and white in color and resembling a pea fruit (Figure 1) located directly under the crura leg of the penis and buried under the bulbar cavernous muscle on both sides of the urethra. Each gland has a single channel Poured into the urethra, The length, width and weight were respectively about 0.7 cm, 0.4 cm, and 1 g (Figure 2).

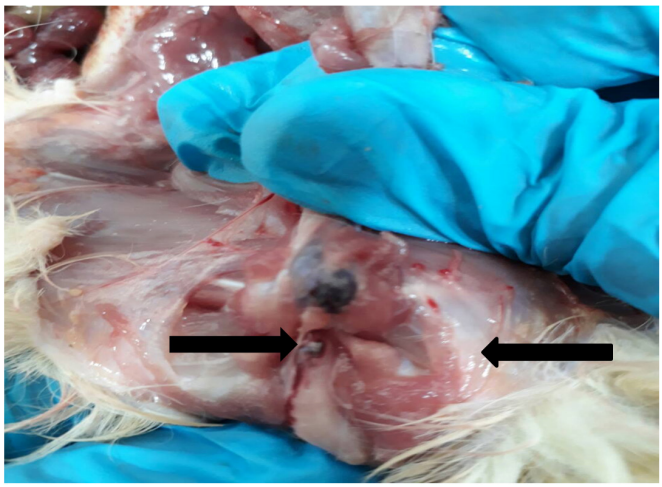

Figure 1: Arrows indicate bulbourethral glands in animal hamsters.

Figure 2: The bulbourethral glands after removing them from the animal's body.

HISTOLOGICAL RESULTS

The bulbar urethral gland in Syrian hamsters: It is a complex tubular-alveolar gland, lined with a simple vertical epiphysis, these glands are multi-lobed, each lobe consists of simple, small dens that are connected to each other directly or through narrow and short tubes, there is a large duct in the middle of each lobe. Through it, the socket of the gland opens and the cytoplasm fills the cells of the glands with secretory granules, and layers of wallet of fibrous connective tissue surrounding the glands and sends fibrous barriers separating the alveoli, as in Figures 3 and 4.

DISCUSSION

Among the male reproductive system components in humans and most mammary glands are advanced glands, which include the prostate gland, seminal vesicles, and bulbar urethral glands. These glands are of immense importance in the sexual reproduction process because they work on the secretion of seminal plasma, which is a medium in which sperm is attached and other functions of the proteins of the prostate

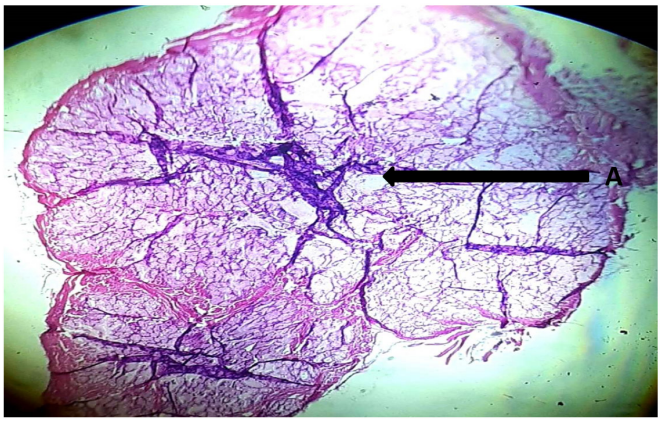

Figure 3: Histological section of the urethral bulbar gland of a male hamster, (A) illustrates abundant secretion within simple columnar epithelial cells lining the alveoli of the hamster's urethral bulbar glands (haematoxylin-eosin 10x stained).

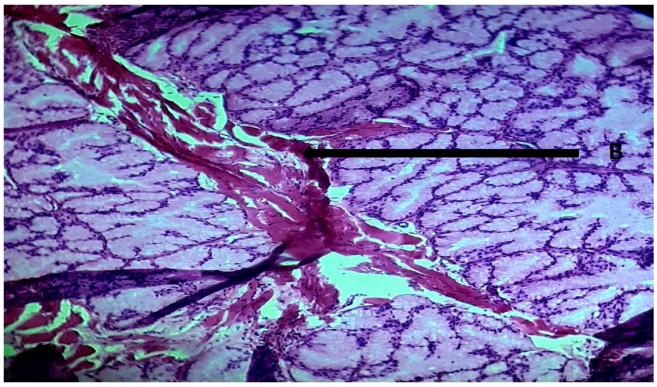

Figure 4: A histological section of the urethral bulbar gland of a male hamster, (B) illustrates cavities in which the alveoli of the hamster bulbourethral gland appear full of secretion (haematoxylin-eosin stain 40x).

and seminal vesicles. These include activities that inhibit immunity and stimulate sperm motility, and the secretion of the bulbar urethral glands has a role in lubricating the urethra and cleaning it from urine residues, which becomes harmful to the sperm.[8]

In equatic mammelia and some carnivores, the bulbar mammary glands do not exist, and this does not mean that their reproductive process does not take place completely.[5]

The bulbar urethral glands in hamsters are in the form of a pair of small glands, oval-shaped and white, resembling a pea fruit, located under the leg of the penis, and buried under the bulbar cavernous muscle on both sides of the urethra and each gland has a duct that flows into the urethra. The present is consistent with the results of other researchers.[6]

The anatomical results of the current study did not match some previous researches[11,15] in their description of the bulbar urethral glands of the rabbit as they are cubic in shape, extending from back to front and buried in the posterior neighborhood of the urethra, this gland is associated with the prostate gland and a gland around the prostate and Periprostate.

The results of this study were different from the results of the researchers when they described the bulbar urethral glands in European hedgehogs as being large, non-lobular, oval-shaped glands situated external to the pelvic cavity, on either side of anus, embedded in the muscles of sciatic-condylar, its channels Dorsolateral part of the pelvic urethra, their description is comparable to that of these glands in the Greater cane rat.[1]

Our results differed with other researches[9,11] on their description of the bulbar urethral glands in the squirrel where large glands were positioned adjacent to the leg's core on both sides of the anus.

They are tubular glands, a complex alveolar gland with several lobes lining a simple vertical epiphysis. Each lobe consists of simple, small alveoli that connect. Fibrous barriers are sent that separate the alveoli. The cytoplasm contains secretory granules. The results of the current study are identical to other research results in the rat, mouse and rabbit.[12,15]

REFERENCES

1. Adebayo AO, Akinloye AK, Olukole SG et al. Gross. Histological and Ultrastructural features of the Bulbourethral Gland in the Greater Cane Rat (Thryonomys swinderianus) Anat Histol Embryol. 2015; 44(1): 59-65, doi: 10.1111/ahe.12108.
2. Badia E, Briz MD, Pinart E, Sancho S, Garcia N, Bassols J, Pruneda A, Bussalleu E, Yeste M, Casas I, Bonet S. Structural and ultrastructural features of boar bulbourethral glands. Tissue and Cell. 2006 Feb 1;38(1):7-18.
3. Chughtai B, Sawas A, O'Malley RL, Naik RR, Khan SA, Pentyala S. Neglected gland: a review of Cowper's gland. Int. J. Androl. 2005;28:74-77.
4. Dunker N, Au Muller G. Transforming growth factor beta 2 heterozygous mutant mice exhibit Cowper's gland hyperplasia and cystic dilations of the gland ducts (Cowper's syringoceles). J. Anat. 2002;201:173-183.
5. Dyce KM, Sack WO, Wensing CJG. Anatomia Veterinaria. McGraw-Hill, Interamericana, Mexico, 1999.
6. Geuze JJ, Slot JW. Synthesis and secretion of glycoprotein in rat bulbourethral glands. II.Modes of mucinous secretion after stimulate by copulation. Am. J. Anat. 1978;152:391-418.
7. Kelly DE, Wood RL, Enders AC. Baileys text book of microscopic anatomy. 18th ed. William & Wilkins. London. 1985.
8. Kiupel M, Brown KS, Sundberg JP. Bulbourethral (Cowper's) gland abnormalities in inbred laboratory mice. J.Exp. Anim.Sc. 1999/2000;40:178-188.
9. Knoblahgh S, True L. Comparative Anatomy and Histology: A Mouse and Human Aties ʹKnoblahgh S. True L (2011). Comparative Anatomy and Histology : A Mouse and Human Aties Elsevier science Buelington, 2011, 285-309.
10. McCracken T, Kainer R, Carlson D. Color Atlas of small Animal Anatomy. Blackwell Publishing, USA, 2008.
11. A-Alshemkhi MAR. The Histological structure of Thyroid gland and the relationship between the hyperthyroidism and total protein, albumin, globulin, liver enzymes and some minerals deficiency. 2004;9(8):189-196.
12. Samudson. D.A. (ed.),: Male reproductive system, Ist edn.in : Text book of veterioary Histology.st.Louis.Ml : Saunders Elsevier, 2007;63146: 418-441.
13. Stan FG. Anatomical particularities of Male Reproductive System of Guinea Pigs (Cavia porcellus). Bulletin of University of Agricultural Sciences and Veterinary Medicine ClujNapoca. Vet Med. 2015;72(2):288-295.
14. Thomson AA, Marker PC. Branching morphogenesis in the prostate gland and seminal vesicles Differentiation. 2006; 74:382-392.
15. Vásquez B, del Sol M. Estudio morfológico de la glándula bulbouretral de conejo (Oryctolagus cuniculus). Revista chilena de anatomía. 2001 Aug;19(2):221-228.