

Causes and Treatment of Hematuria in Newborns

Ghanim A. Abbas*, Meraim A. Kazaal

Department of Nursing Techniques, Technical Institute of Al-Diwaniyah, Al-Furat Al-Awsat Technical University, Kufa, Najaf, Iraq

Received: 28th December, 2022; Revised: 11st January, 2023; Accepted: 22nd February, 2023; Available Online: 25th March, 2023

ABSTRACT

Background: Hematuria is one of the cases that has started to increase in newborns, but studies on the causes and treatment of this condition are very limited, especially in Iraq. Therefore, the current study aims to determine the prevalence of this condition and monitor its causes and appropriate treatment.

Methods: The current study includes the collection of questionnaires and medical examinations from 35 newborns (ages between 2 hours to 2.5 months) suffering from hematuria for various reasons. Samples were collected during the period from 2/1/2021 to 28/3/2021, and information and examinations for each diseased case were collected.

Results: The results of the study showed that most of the newborns had gross hematuria (91%) compared to microhematuria (9%), especially males and that the main causes of hematuria in newborns were due to bacterial septicemia (37%) and urinary tract infections (32%), congenital malformations (14%), and renal artery thrombosis (11%). The results also showed that most of the children who suffer from hematuria whose mothers suffer from health problems during pregnancy, the most important of which are anemia (31.4%), urinary tract infection (UTI) (14.2%) and gestational diabetes (14.2%). The results of this study also showed that the treatment of hematuria depends on the diagnosis of the pathogen, and the CT scan was a basic examination for all cases, in addition to that, the microscopic examination and the culture of urine were also used. Antibiotics and surgeries were the appropriate treatment in most cases of hematuria. In conclusion, blood in urine is a pathological condition that needs diagnosis and treatment as soon as possible to avoid complications or disorders that may threaten the newborn's life.

Keywords: Blood, Causes, Hematuria, Newborn, Treatment, UTI, Urine.

International Journal of Drug Delivery Technology (2023); DOI: 10.25258/ijddt.13.1.56

How to cite this article: Abbas GA, Kazaal MA. Causes and Treatment of Hematuria in Newborns. International Journal of Drug Delivery Technology. 2023;13(1):347-352.

Source of support: Nil.

Conflict of interest: None

INTRODUCTION

The appearance of blood in the urine is one of the common problems among children that terrifies any mother, because she does not know the reason behind this, which requires presenting to the doctor as soon as possible and often requires some tests such as urinalysis and ultrasound.^{1,2} In general, hematuria is divided according to the appearance of blood in the urine into microscopic hematuria, which can only be known by microscopic examination of urine, and the second type is gross or visible urine, which can be known by the appearance of blood clearly with the urine of the child, which is usually observed quickly by the mother.^{1,3} In many cases, the matter is simple and is not considered a complex health problem, but sometimes the cause is a serious problem.³ In a normal situation, blood never appears in the urine because the kidney's filters prevent the blood from leaving with urine. However, there are more than a hundred problems that may cause the exiting of blood with urine. The most important of which is

an anatomical defect in the urinary tract (especially urethral abnormalities in males). The presence of cyst on the kidneys that may lead to the appearance of blood in the urine problems can be detected by ultrasound.^{3,4} Also, some genetic diseases such as polycystic kidney disease, Albert's disease, sickle cell disease, and hereditary nephritis may cause the exiting blood with the urine of the child. Moreover, if the mother or the father suffers from one of these diseases, the child may be more susceptible to infection and exposure to hematuria.⁵⁻⁷

Urinary mineral imbalances such as high calcium levels may lead to blood in the urine and sometimes painful stones. In addition, glomerulonephritis and inflammation of the bladder or urinary tract due to bacteria may result in blood in the child's urine and with high fever.^{7,8} On the other hand, in rare cases, there is an effect of the mother's hormones that can lead to some blood flowing from the womb of the child and its quantity is small, and this phenomenon disappears after a short time and it does not lead to a health problem.⁹

*Author for Correspondence: ghanemoaiy@atu.edu.iq

In Iraq, we did not find any study that sheds light on the cases of hematuria that appear in some newborns, so the current study aims to know the incidence of this disease among newborns in the city of Diwaniyah and to determine its causes and the most appropriate tests for its diagnosis and appropriate treatment. Also, this study may pave the way for other studies within the framework in addition to the contribution of current study to health awareness about the reasons that make the fetus after birth or the newborn is more susceptible to this disease.

MATERIALS AND METHODS

Samples Collection

The current study is a cross-sectional study that included the collection of questionnaires and medical examinations from 35 newborn infants (ages 2 hours to 2.5 months) suffering from hematuria for various reasons. The samples were collected from 2/1/2021 to 28/3/2021, where 20 samples were collected from Maternity and Children's Teaching Hospital and 15 samples were collected from the outpatient clinics in Diwaniyah. The following information and examinations were collected from the patients:

- The name and gender of the child
- Child's age
- Causes of bloody urine
- Medical examinations
- Treatment
- The pathological conditions that the mother suffered during pregnancy
- Family history of hematuria or other UT disorders

DIAGNOSIS

Urinalysis

Changing the color of urine helps alert the mother and the specialist doctor that there is a health problem in the newly born child. Where the doctor diagnoses urinary tract problems through a clinical examination by noticing the swelling or redness of the genitals and the exit of blood with the urine, and then he sends the urine sample for bacterial culture and checks for any bacteria present in it. Often, the urine sample was taken from newborn babies by inserting a sterile, thin, flexible tube through the urethral opening into the bladder. This process is called catheterization. In some infants and newborns, the skin of the foreskin may be so tight that it is difficult to pull it back and away from head of the penis, so we need to take a urine sample directly from the bladder with a needle that is inserted through the skin above the pubic bone.

Sometimes the doctor attaches a vessel in the area between the genital opening and the anus in order to collect and test a urine sample. A urine sample taken this way is unsuitable for diagnosing a UTI, because the urine has been contaminated with bacteria or other substances on the skin. Urinary tract infections also increase the levels of white blood cells and bacteria in the urine. To check the levels of white blood cells and bacteria in the urine, we examined the urine under a microscope and performed several chemical tests. A bacterial

culture of urine is also done to check for any bacteria present in it. Bacterial culture is the most important of these tests.

Ultrasonography and CT Scan

Ultrasound is used to show a complete picture of urinary system disorders. Ultrasonography also investigates anatomical abnormalities and obstruction of the kidneys, bladder or urethra. Many abnormalities of the fetal urinary system can be detected and diagnosed during ultrasonography that is routinely done for the expectant mother. However, sometimes anatomical abnormalities can't be detected using ultrasonography during pregnancy. CT scan also examines the urinary tract, ovaries, urethra, bladder and pelvic blood. It allows viewing the size and shape of these structures to determine if they are working properly, and for any signs of disease that may affect the urinary system. Computerized tomography of the urinary system may be used to help diagnose conditions affecting the urinary system that may have a role in the discharge of blood with urine, such as:

- Kidney stones
- Bladder stones
- Infection
- Tumors or cysts
- Structural abnormalities

HEMATURIA

Analysis

When urine tests fail to confirm the diagnosis, blood and inflammatory detecting tests (C-reactive protein and erythrocyte sedimentation rate test) may help a doctor diagnose kidney and bladder infections.

Statistical Analysis

The results of the current study were analyzed using Excel 2010 and the Statistical Package for Social Science (SPSS) version-20 program, where the results were considered statistically significant if the *p*-value was less than 0.05.

RESULTS

The current study included the collection of 35 medically and laboratory-diagnosed cases of newborns suffering from hematuria, and their ages ranged from one hour to 2.5 months, with an average age of 27.37 ± 9.66 as shown in Table 1. The results of the current study, Figure 1, showed that most of the children who suffer from hematuria were males (65%). In addition, a large percentage of children (91%) appeared to suffer from gross or visible hematuria, while only 9% appeared to have micro-hematuria as in Figure 2.

The results of the current study showed that the main causes of hematuria in newborns are due to bacterial septicemia (37%), UTI (32%), congenital malformations (14%) and renal artery thrombosis (11%). On the other hand, sickle cell anemia and a child's kidney cyst were secondary causes of hematuria in newly born children, as it appeared at a rate of 3% for each one of them, especially in males, as shown in Figure 3 and Table 2.

Table 1: Age range and mean of newborns with hematuria

<i>Patients ages (year)</i>	
<i>Range</i>	<i>1 hour–2 months</i>
Mean ± SD	27.37 ± 9.66 day
SE	1.63 day
Total number of patients	35

SD= Standard Deviation; SE= Standard Error

Table 2: Causes of hematuria according to newborns' gender

<i>Causes of hematuria</i>	<i>Total number (%)</i>	<i>Females N (%)</i>	<i>Males N (%)</i>	<i>p-value</i>
Bacterial septicemia	13 (37)	5 (38)	8 (62)	0.0205
Renal artery thrombosis	4 (11)	0 (0)	4 (100)	< 0.0001
Congenital malformations	5 (14)	0 (0)	5 (100)	<0.0001
Urinary tract infection	11 (32)	7 (64)	4(36)	0.0191
Kidney cyst	1 (3)	0 (0)	1(100)	<0.0001
Sickle cell anemia	1 (3)	0 (0)	1(100)	<0.0001
Total number	35	12	23	

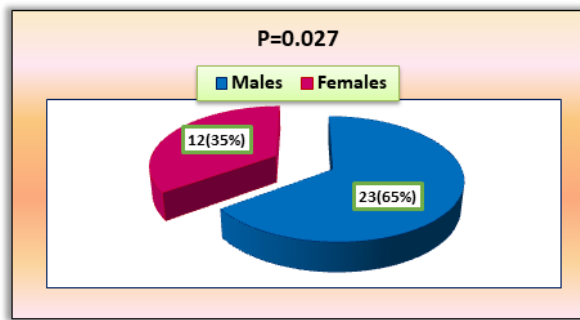


Figure 1: Distribution of patients according to gender.

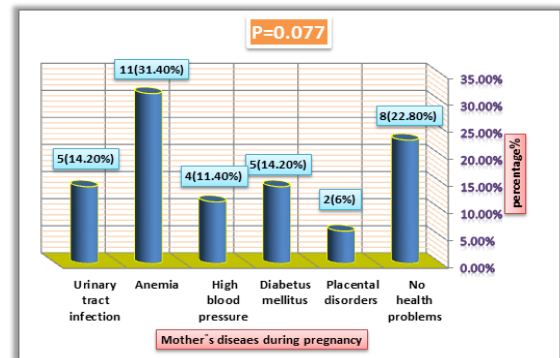


Figure 4: Healthy status of mothers during pregnancy.

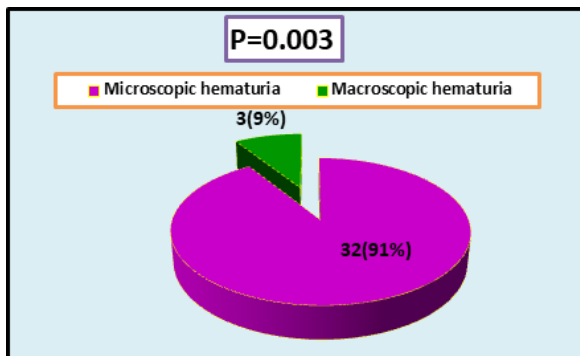


Figure 2: Distribution of cases according to type of hematuria.

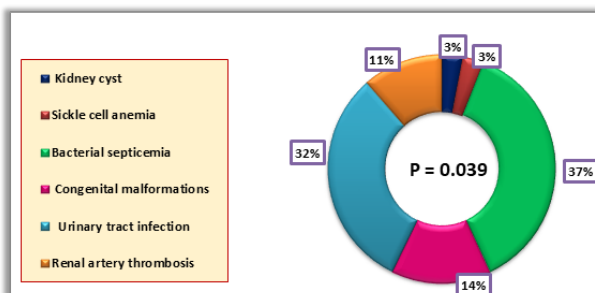


Figure 3: causes of hematuria in newborns

Also, the results recorded in Table 2 showed that some of the causes of hematuria are related to the sex of the fetus, as hematuria resulting from congenital malformations of the urinary tract appeared in males only (100%). Also, most cases of hematuria resulting from bacterial septicemia appeared in males by 62% compared to 38% in females, while most cases of hematuria resulting from urinary tract infection were recorded in females at 64% compared to 36% in males.

The results of the current study showed that most of the children who suffer from hematuria were their mothers suffering from health problems during pregnancy, as shown in Figure 4, where 31.4% of the mothers had anemia during pregnancy and 14.2% had urinary tract infection and 14.2% suffer from diabetes, and 11.4% of mothers suffer from high blood pressure, while 22.8% of mothers do not complain of any health problems during pregnancy.

The results in Table 3 showed that the treatment of hematuria depends on the diagnosis of the pathogen, and the CT scan was a basic examination for all cases. For hematuria resulting from bacterial septicemia and urinary tract infection, doctors have indicated microscopic analysis and culture of urine samples and prescribed antibiotics as an appropriate treatment for both cases. Congenital malformations and

Table 3: Diagnosis and treatment of hematuria

<i>Causes of hematuria</i>	<i>Total number (%)</i>	<i>Diagnosis</i>	<i>Treatment</i>
Bacterial septicemia	13 (37)	Microscopic analysis of urine urine culture CT scan	Antibiotics
Renal artery thrombosis	4 (11)	Microscopic analysis of urine ultrasound/sonar CT scan	Coagulation inhibitors antibiotics surgery
Congenital malformations	5 (14)	Cystoscopy ultrasound/sonar CT scan	Surgery antibiotics
Urinary tract infection	11 (32)	Microscopic analysis of urine urine culture CT scan	Antibiotics
Kidney cyst	1 (3)	Endoscopy ultrasound/sonar CT scan	Surgery antibiotics
Sickle cell anemia	1 (3)	Microscopic analysis of urine hemoglobin test	Blood transfusion bone marrow transplant L-glutamine

kidney cysts were diagnosed using cystoscopy, endoscopy and ultrasound, in addition to CT scan while approved treatment for both these cases was surgical operations (mostly circumcision in the case of male babies) with antibiotics. On the other hand, renal artery thrombosis was diagnosed by ultrasound and CT scan, as well as microscopic examination of urine, and the treatment used by doctors for this case included anticoagulants and antibiotics so vital surgeries have been the appropriate solution in some cases.

The hematuria that resulted from sickle cell anemia was diagnosed by microscopic examination of the blood, urine and hemoglobin test. Moreover, blood transfusion was one of the methods used in treating this case, and marrow transplantation was the best treatment also the doctors prescribed L- glutamine to reduce the symptoms of these diseases.

DISCUSSION

Hematuria is uncommon and can be harmful to the health of the newborn. Although nephrogenesis is complete in humans by 36 weeks of gestation, the glomerular filtration rate is about 10 to 20 mL/min per 1.73 m² that indicative of an immature kidney and the glomerular filtration rate of infants is even lower.^{10,11}

There are many aspects of hematuria in children, and it may be in the form of visible blood in urine, which draws the attention of parents, or it may be in the form of red spots on underwear or diapers that are discovered when changing. It may also be microscopic and is only detected when urine is analyzed under the microscope. On the other hand, some studies have shown that gross hematuria, although rare in healthy newborns, is more common in premature babies, especially those who are cared for in the neonatal intensive care unit. The hematuria may be transient but may require evaluation, investigation and timely intervention.¹² Furthermore, other studies have shown that the anatomical defect in the kidneys and the presence of cysts on the kidneys, or the presence of obstruction in the kidneys, may be the main cause of blood in the urine, as microscopic urinary bleeding is a common symptom of glomerulonephritis, an inflammation of the filtering system of the kidneys.¹³ Glomerulonephritis can be part of a systemic disease, such as diabetes, or it can occur on its own. Glomerulonephritis can be caused by a viral or streptococcal infection, blood vessel diseases such as vasculitis, and immune problems, such as factor A nephropathy, which affects the tiny

capillaries that filter blood in the glomeruli.¹⁴

Moreover, glomerulonephritis is a common cause of blood in the urine, as there are many types of this disease, some of them are simple and do not require treatment, and some require more treatment and examinations.¹⁵ Other medical reports have also indicated that genetic diseases such as polycystic kidney disease, Albert's disease, sickle cell anemia, and hereditary nephritis may cause blood in the child's urine. Especially if the mother or father suffers from one of these diseases, the child may be more susceptible to infection. Other studies have shown that an imbalance of minerals in the urine, such as a high calcium level, may lead to blood in the urine, sometimes leading to painful stones.¹⁶

Other studies have also found that inflammation of the kidneys (vesiculitis and nephritis) can occur when bacteria enter the kidneys from the bloodstream or travel from the urethra to the kidneys. The signs and symptoms are often the same as a bladder infection, although a kidney infection is more likely to cause fever and blood in the urine of the child. UTI is more common in females, sometimes transmitted during childbirth from mother to child, while congenital malformations appear in the urethra area in male children. This indicates that the histological anatomy is represented by the difference in the length of urethra between males and females. It has a role in the occurrence of UTIs or their disorders accompanied by blood in some cases.^{17,18}

The current study showed that anemia of the mother increases the chance of hematuria in the newborn, and the World Health Organization (WHO) and many medical studies confirmed this. Where those studies showed that a good and varied nutrition builds placental tissues, enhances the process of supplying the fetus with blood, and reduces risks and health problems for the mother and child after birth.¹⁷ In addition, another study determined that severe iron deficiency during pregnancy increases the risks of premature birth and the possibility of giving birth to a child with a low birth weight, as well as the occurrence of health problems in the child, the most prominent of which is hematuria.¹⁸

On the other hand, the current study showed that the mother's high pressure and urinary tract infection increase the chance of blood flowing. This may be due to the occurrence of complications, the most important of which is premature birth which occurs in the case of acute nephritis accompanied

by high blood pressure. The infection may be transmitted to the fetus, which may cause a delay in the development of the fetus, or sometimes the child is born with congenital abnormalities, including in the child's urethra, which are sometimes accompanied by bloody urine.¹⁹

Diabetes mellitus (DM) during pregnancy is one of the factors that emerged in the current study and that has a role in the occurrence of bloody urine or hematuria in the newborn child. As gestational diabetes occurs due to the mother's inability to secrete an adequate amount of the hormone insulin, the pregnant body needs a greater amount of insulin during pregnancy. When it is lacking, the amount of sugar in the blood rises, which leads to gestational diabetes, which begins in the second half.²⁰ High blood sugar during pregnancy leads to congenital malformations in the fetus and may lead to blockages in some organs of the child's body such as the urinary system, which may be accompanied by difficulty urinating in children, especially males, which often need to surgical intervention.²¹

Hematuria is a pathological condition, so the cause that led to its occurrence must be diagnosed and treated. In many cases, the clinical examination gives clues to the cause, so the doctor can find skin hemorrhages or notice a mass in the abdomen, but in most cases the treating doctor needs to order a set of auxiliary tests, the most important of which is urinalysis, which is the initial examination for diagnosis, as it confirms the presence of blood in urine and its quantity, as it is useful in evaluating the presence of a urinary infection; also the complete blood count (blood analysis) is useful in evaluating the presence of anemia and looking for a sign of infection and gives an idea of the number of platelets, which is low in many immune hematological diseases. Kidney function is also evaluated.²²⁻²⁴

More sophisticated tests are useful in detecting the presence of a blood or autoimmune disease that causes bleeding. On the other hand, imaging the abdomen using sonar, which is a safe and inexpensive procedure, gives a clear idea of the size of the kidneys and shows the presence of stones, cysts and tumors.²⁴ A CT scan of the abdomen can give a three-dimensional and clearer visualization of the kidneys and urinary tract. In some cases, a cystoscopy is performed to look for possible bladder problems, and a kidney biopsy may be required, especially if the disease is accompanied by high blood pressure.^{24,25}

In the current study, the doctors confirmed that blood in the urine is a matter that does not require any kind of treatment, as the blood often disappears on its own. If it happens once, there is nothing to worry about. In contrast, if a specific reason causes the blood, the specialist doctor determines the appropriate treatment for the child depending on the cause of blood in the urine, in the case of blood in urine resulting from urinary stones, it is treated by removing the stones, as for blood in urine resulting from urinary infections, it is treated by giving antibiotics to eliminate the infection, and if the child suffers from an immune disease that causes kidney inflammation, the doctor may prescribe cortisone. In contrast, if the child has an anatomical problem, he may need surgery

(One of the most common surgical procedures in Iraq is male circumcision in case of abnormalities or obstruction at the end of the ureter).^{22,26}

Regarding the source of hematuria in children, it was classified by some studies into three main categories, the first of which is diseases that affect the kidney tissues. The second is malformations and lesions of the urinary and reproductive system, and the third is systemic medical conditions that include blood diseases.^{27,28} Treatment is carried out according to the cause and in most cases there is no need for any treatment, but periodic follow-up and urine tests, especially in the case of bacterial urethritis or benign hereditary hematuria and some cases of acute glomerulonephritis. It is important to consult a pediatric nephrologist and urologist to diagnose and treat diseases of the first category.^{27,28} As for the second category, with its rarity, some of these cases, such as kidney and bladder tumors, may need complete surgical removal of these organs with chemotherapy or radiation or correction of obstruction in the urinary ducts or treatment stones medically or surgically, and treatment of bacterial urinary infections with antibiotics. As for children who belong to the third category must be referred to a pediatrician specializing in hematology to confirm the diagnosis and treatment.^{29,30}

CONCLUSION

The results of the current study showed that gross or visible hematuria was the most common compared with microscopic hematuria, especially in newly born males. The results of the current study also showed that most of the children who suffer from hematuria, their mothers suffer from health problems during pregnancy, the most important of which are anemia, urinary tract infection and gestational diabetes. The results of this study also showed that the treatment of hematuria depends on the diagnosis of the pathogen, and the CT scan was a basic examination for all cases. In addition, microscopic examination and urine cultivation were also used, and endoscopy and ultrasound were used to diagnose some cases. And antibiotics and surgeries (particularly male circumcision) were the appropriate solution in most cases of hematuria.

REFERENCES

1. Thakkar D, Deshpande AV, Kennedy SE. Epidemiology and demography of recently diagnosed cases of posterior urethral valves. *Pediatric research*. 2014 Dec;76(6):560-563.
2. Brownlee E, Wragg R, Robb A, Chandran H, Knight M, McCarthy L. Current epidemiology and antenatal presentation of posterior urethral valves: outcome of BAPS CASS national audit. *Journal of pediatric surgery*. 2019 Feb 1;54(2):318-321.
3. Heikkilä J, Holmberg C, Kyllönen L, Rintala R, Taskinen S. Long-term risk of end stage renal disease in patients with posterior urethral valves. *The Journal of urology*. 2011 Dec 1;186(6):2392-2396.
4. Lopez Pereira P, Urrutia MM, Jaureguizar E. Initial and long-term management of posterior urethral valves. *World journal of urology*. 2004 Dec;22(6):418-424.
5. Dewan PA, Goh DG. Variable expression of the congenital obstructive posterior urethral membrane. *Urology*. 1995 Mar 1;45(3):507-509.

6. Bernardes LS, Aksnes G, Saada J, Masse V, Elie C, Dumez Y, Lortat-Jacob SL, Benachi A. Keyhole sign: how specific is it for the diagnosis of posterior urethral valves?. *Ultrasound in Obstetrics and Gynecology: The Official Journal of the International Society of Ultrasound in Obstetrics and Gynecology*. 2009 Oct;34(4):419-423.
7. Dudley JA, Haworth JM, McGraw ME, Frank JD, Tizard E. Clinical relevance and implications of antenatal hydronephrosis. *Archives of Disease in Childhood-Fetal and Neonatal Edition*. 1997 Jan 1;76(1):F31-4.
8. Bhagat SK, Gopalakrishnan G, Kekre NS, Kumar S. Anterior and posterior urethral valves with subcoronal hypospadias: a rare association. *Journal of pediatric surgery*. 2008 Sep 1;43(9):e23-e25.
9. Jernigan SM. Hematuria in the newborn. *Clinics in perinatology*. 2014 Sep 1;41(3):591-603.
10. Diamond DA, Ford C. Neonatal gross hematuria as a presenting sign of posterior urethral valves. *Urology*. 1992 Sep 1;40(3):267-269.
11. Salam MA. Posterior urethral valve: Outcome of antenatal intervention. *International journal of urology*. 2006 Oct;13(10):1317-1322.
12. Caione P, Nappo SG. Posterior urethral valves: long-term outcome. *Pediatric surgery international*. 2011 Oct;27:1027-1035.
13. Roberts KB, Subcommittee on Urinary Tract Infection, Steering Committee on Quality Improvement and Management. Urinary tract infection: clinical practice guideline for the diagnosis and management of the initial UTI in febrile infants and children 2 to 24 months. *Pediatrics*. 2011 Sep;128(3):595-610.
14. American Academy of Pediatrics-Section on Nephrology and the American Society of Pediatric Nephrology: Choosing wisely: Five things physicians and patients should question, 2018. Available at: <https://www.choosingwisely.org/societies/american-academy-of-pediatrics-section-on-nephrology-and-the-american-society-of-pediatric-nephrology>
15. Feng CY, Xia YH, Wang WJ, Xia J, Fu HD, Wang X, Shen HJ, Qian GL, Liu AM, Mao JH. Persistent asymptomatic isolated hematuria in children: clinical and histopathological features and prognosis. *World Journal of Pediatrics*. 2013 May;9:163-168.
16. Mir S, Serdaroglu E. Quantification of hypercalciuria with the urine calcium osmolality ratio in children. *Pediatric Nephrology*. 2005 Nov;20:1562-1565.
17. Roberts KB, Subcommittee on Urinary Tract Infection, Steering Committee on Quality Improvement and Management. Urinary tract infection: clinical practice guideline for the diagnosis and management of the initial UTI in febrile infants and children 2 to 24 months. *Pediatrics*. 2011 Sep;128(3):595-610.
18. Paduch DA. Viral lower urinary tract infections. *Current urology reports*. 2007 Jul;8:324-335.
19. Roeper R, Massicotte P, AlAbbas A, Law BH. A preterm infant with hematuria. *Paediatrics & Child Health*. 2021 Nov;26(7):388-9.
20. Hahr AJ, Molitch ME. Management of diabetes mellitus in patients with chronic kidney disease. *Clinical diabetes and endocrinology*. 2015 Dec;1(1):1-9.
21. Bergstein J, Leiser J, Andreoli S. The clinical significance of asymptomatic gross and microscopic hematuria in children. *Archives of pediatrics & adolescent medicine*. 2005 Apr 1;159(4):353-355.
22. Davis KA, Stanek JR, Dunn AL. Screening urinalysis demonstrates that haematuria is a frequent finding in persons with haemophilia treated at a paediatric haemophilia treatment centre. *Haemophilia*. 2019 Sep;25(5):782-788.
23. Malkan AD, Loh A, Bahrami A, Navid F, Coleman J, Green DM, Davidoff AM, Sandoval JA. An approach to renal masses in pediatrics. *Pediatrics*. 2015 Jan;135(1):142-158.
24. Viteri B, Reid-Adam J. Hematuria and proteinuria in children. *Pediatrics in review*. 2018 Dec;39(12):573-587.
25. Clark M, Aronoff S, Del Vecchio M. Etiologies of asymptomatic microscopic hematuria in children—systematic review of 1092 subjects. *Diagnosis*. 2015 Dec 1;2(4):211-216.
26. Azar M, Jaitley A. Pink Hematuria in an Infant. *Pediatric Oncall Journal*. 2020 Sep 3;17(4):143-144.
27. Ohisa N, Yoshida K, Kaku M, Sato H. Comparison between optical microscopic examination and phase contrast microscopic examination for diagnosing the origin of urinary bleeding. *Nihon Jinzo Gakkai shi*. 2006 Jan 1;48(5):401-406.
28. Dell KM. The spectrum of polycystic kidney disease in children. *Advances in chronic kidney disease*. 2011 Sep 1;18(5):339-347.
29. Shin JI, Park JM, Lee JS, Kim MJ. Effect of renal Doppler ultrasound on the detection of nutcracker syndrome in children with hematuria. *European journal of pediatrics*. 2007 May;166:399-404.
30. Vianello FA, Mazzoni MB, Peeters GG, Fossali EF, Camozzi P, Bianchetti MG, Milani GP. Micro-and macroscopic hematuria caused by renal vein entrapment: systematic review of the literature. *Pediatric Nephrology*. 2016 Feb;31:175-184.