e-ISSN: 0975-1556, p-ISSN:2820-2643

Available online on www.ijpcr.com

International Journal of Pharmaceutical and Clinical Research 2022; 14(10); 289-297

Original Research Article

Distal Tibia Fractures Managed with Locking Compression Plate Osteosynthesis: A Prospective Study of 28 Patients

Raj Kumar[1], Praveen[2], Lal Bahadur Manjhi[3]

[1]Senior Resident, Department of Orthopaedics, Rajendra Institute of Medical Sciences, Ranchi, Jharkhand, India

[2]Post-Graduate Student, Department of Orthopaedics, Rajendra Institute of Medical Sciences, Ranchi, Jharkhand, India

[3]Professor, Department of Orthopaedics, Rajendra Institute of Medical Sciences, Ranchi, Jharkhand, India

Received: 25-08-2022 / Revised: 21-09-2022 / Accepted: 08-10-2022
Corresponding author: Dr. Raj Kumar
Conflict of interest: Nil

Abstract

Background: Distal tibia fractures are complex injuries having high complication rate. The conventional implants are unsuitable for managing such fractures successfully. The aim of this study was to evaluate clinical, functional and radiological outcomes after open reduction and internal fixation using distal tibial locking compression plate (LCP).

Materials and Methods: A total of 28 patients with distal tibia fracture were treated by using distal tibia LCP. All the patients were followed up for a minimum of 12 months in orthopaedic department, R.I.M.S. Ranchi. Functional and radiological results were evaluated at the end of study.

Results: There were 19 males and 9 females with mean age of 37.7 years. Majority of fractures were extra-articular (60.71%), while 32.14% were partial articular fractures and 7.14% were complete articular fractures. Out of 28 patients, 20 patients had closed fracture and 8 had open fracture. The mean fracture healing time was 22 weeks (range 16-36 weeks). Postoperatively, 5 patients developed superficial skin infection, 3 developed deep infection and 4 developed ankle stiffness, 6 had hardware problem like irritation in skin, 4 patients had delayed union and 2 patients had non-union. Functional outcome according to the Olerud and Molander score showed that 14 (50%) patients had an excellent outcome while 9 (32.14%) had good outcome and 5 (17.86%) patients had a fair outcome.

Conclusions: Locking plate for distal tibia fractures is an excellent option for managing such fractures and gives consistent and reproducible clinical results.

Keywords: Distal tibia fracture, AO/OTA classification, Open reduction and internal fixation, Locking compression plate, Olerud and Molander score.

Introduction

Treatment of distal tibial fracture with or without articular extension is demanding because of its unique anatomical characteristics of subcutaneous position with precarious blood supply and closeness to the ankle joint. Delicate soft tissue in this area, ligamentous injuries, presence of ankle joint in close contiguity, associated fibular fracture, small distal

fragment size and compression of cancellous bone among others are important confounding factors in its management. Functional outcome of the patients with such fractures can be convincingly enhanced by better understanding of the injury patterns, availability of better implants, conception of early surgical fixation and early post-operative mobilization of joint. [1]

Complications like mal-union, nonunion and ankle stiffness are usually results from conservative treatment of these fractures; affecting quality of life. [2] These fractures are usually not suitable for intramedullary nailing, however; certain reports showing satisfactory results in some of these fractures. [3] Mal-union and delayed union continued to be the major problems when using external fixation as either a temporary or definitive method of treatment, especially when associated with severe soft tissue injury. [4,5] Open reduction and internal fixation (ORIF) with plate has been advocated by Ruedi TP study as the standard approach for treatment of these fractures. [6]

Open reduction and internal fixation with conventional plate osteosynthesis can further devitalise fragments and lead to increased occurrence of infection, implant failure and non-union. [7] Further, minimally invasive approach offers the best possible option as it permits satisfactory fixation in a biological manner. [3,8] However, insufficient number of screws in a small comminuted distal fragment presents a definite limitation even with this technique. In recent years, locking compression plate has become more popular and is being used frequently for fixation of these fractures. Several studies are also reporting encouraging results of fixation with LCP. LCP osteosynthesis is technically feasible and produces a stable, fixed angle device when locking screw heads are locked with plate. LCP delivers excellent stability and provide better protection against loss of reduction and minimization of bone contact when compared with conventional plate. [9] Also, these plates can be used in a minimally invasive plate osteosynthesis (MIPO) technique without fear of secondary displacement in the absence of perfect contouring. [10] But, there are risks of delayed union and nonunion, when fragments are not tightly compressed especially for simple fractures (i.e. type A3). [11] Also, there is risk of great saphenous vein and saphenous nerve injury when screws are placed percutaneously. ORIF is advantageous as there is clear exposure and definite anatomical reduction. [12]

The purpose of this paper was to study the clinical, functional and radiological outcomes after open reduction and internal fixation using distal tibial LCP.

Materials and Methods

Twenty eight patients with distal tibia fractures with or without intra articular extension treated in Rajendra Institute of Medical Sciences, Ranchi, Jharkhand in between September 2020 to August 2022 were analysed prospectively. Institutional ethics committee clearance was taken for study and informed consent was obtained from all patients before surgical procedure and for participation in the study. Fractures were classified according to AO/OTA classification system (Figure 1). [13]

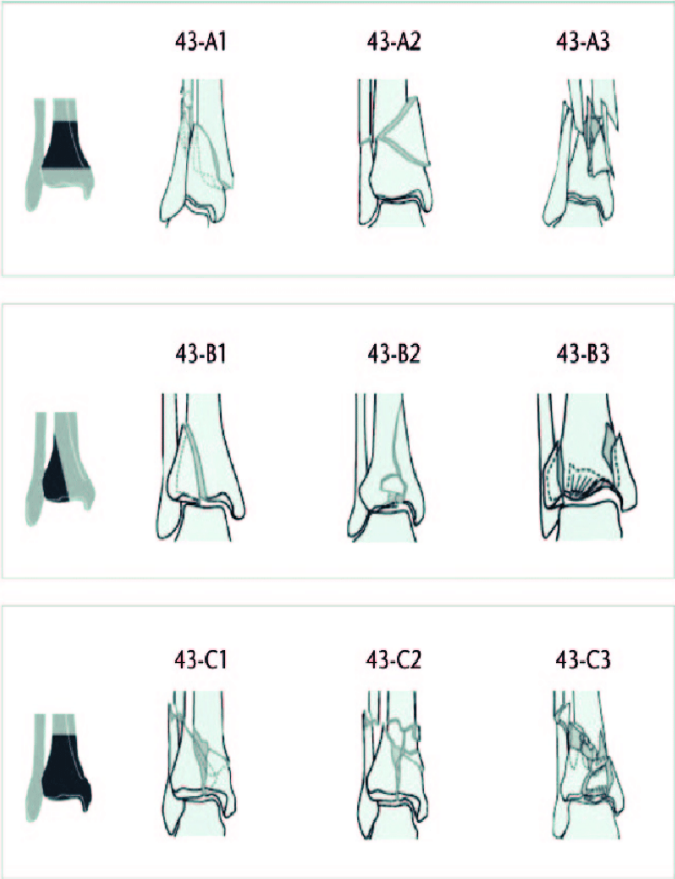

Figure 1: OA/OTA classification of distal tibia fracture

The inclusion criteria of the study were: 1. age between 19-70 years, 2. comminuted distal tibial metaphyseal fracture, 3. closed fractures and open injuries with Gustilo & Anderson grade I, and 4. unilateral involvement. The exclusion criteria were 1. old fractures (>4 weeks), 2. complex pilon fractures (AO 43C3), 3. pathological fractures, 4. bilateral involvement, 5. open injuries with Gustilo & Anderson grade II and more, 6. pre-existing arthrosis of the ankle or previous old healed fractures, 7. fractures with neurovascular deficit or compartment syndrome, 8. pregnant patients, and 9. systemically ill patient.

Standard antero-posterior and lateral radiographs of the affected leg with knee and ankle joint were taken. Fracture morphology, level and extent of comminution was evaluated by x-rays (Figure 2) and computed tomography (CT) scan done for more detailed fracture configuration. The limb was immobilized in a plaster of paris (POP) slab until surgical intervention. Patients with delicate skin condition were managed with prophylactic antibiotics, limb elevation, regular dressing care and surgery was performed after appearance of the 'wrinkle sign'. Patients were operated with LCP after getting pre-anaesthetic investigations and surgical fitness. All patients were managed with appropriate antibiotics, analgesics & anti-inflammatory medications pre & post operatively.

Figure 2: (a & b) Preop X-ray, (c) Intra-op c-arm image and (d) Post op X-ray

Surgical Technique: Surgery was performed under spinal or epidural anaesthesia with a tourniquet in the supine position on a radiolucent table. All operations were done with the help of image intensifier. A 3.5 mm one third tubular plate was used to stabilise the fibula before fixation of the tibia to maintain the alignment of the leg and ankle in case of tibial comminution.

Antero-medial open approach was used and the fracture fragments were reduced by direct means following standard principles and taking great care to preserve soft tissue and blood supply of fragments.[13] A 3.5 mm LCP was used to fix distal tibia with at least four screws engaging seven to eight cortices at each end to ensure the stability. In case of intra articular fractures, accurate reduction was conformed and provisionally fixed with k wires or screws before proceeding with plate fixation. Non locking screws were inserted first when required to aid in the reduction of the fracture so as to pull the

bone to the plate. Locking screws were then passed through holes of the plate.

Post operatively, below knee POP slab was applied in operated limb and elevated. Active toes and knee range of motion was started on the 2nd postoperative day, and non-weight bearing mobilization was allowed at approximately two weeks after proper wound healing. Patients were followed up clinically and radiologically at 6 week intervals for the first three months and then every three months to assess progress of union and possible complications. Full weight-bearing was permitted only after clinico-radiological evidence of union. Final functional outcomes were assessed at the end of one year using the Olerud and Molander scoring system. [14]

Statistical analysis: All data collected were entered into a Microsoft excel spreadsheet and analysed using Statistical Package for the Social Sciences (SPSS version 20.0). Descriptive and inferential statistical analysis included sex and age distribution, type of fracture, mechanism of injury, time to radiological union, complications and results were analysed on percentage basis.

Results

There were 31 patients with distal tibia fracture with or without intra articular extension treated with distal tibial locking compression plate system. Three patients not having a minimum follow-up of one year were excluded from the review, leaving 28 patients (19 men and 9 women) with a median age of 37.7 years (range: 19–70 years). Maximum (35.71%) patients were in the age group of 31-40 years followed by 19-30 years and 41-50 years (Table 1).

Table 1: Showing age distribution of patients

Age Group (in Years)	No of patients	Percentage (%)
19-30	7	25
31-40	10	35.71
41-50	6	21.42
51-60	3	10.71
61-70	2	7.14

There were 57.14% (16) right-sided and 42.85% (12) left-sided fractures. 18 (64.28%) patients were injured after road traffic accidents, 6 (21.42%) patients had a fall, 3 (10.71%) had sustained the injury during sports activities and 1(3.57%) due to assault (Table 2).

Table 2: Showing mode of injury

Mode of injury	No of patients	Percentage (%)
RTA	18	64.28
Fall from height	6	21.42
Sports injury	3	10.71
Assault	1	3.57

Eight patients had associated multiple injuries with visceral injuries and/or associated fractures. The injuries noted were contralateral supracondylar fracture of femur, subtrochentric fracture of femur of ipsilateral side, fractured ribs, fractured patella, fractured pubic rami, contralateral fractured tibia and fractured clavicle. There were 2 cases associated with head injury. 17 cases had associated ipsilateral fibular fracture. Using the AO classification, 17 (60.71%) fractures were type A, 9 (32.14%) fractures were type B and 2 (7.14%) fractures were type C (Table 3).

Table 3: Showing distribution of patients according to types of fracture (AO/OTA classification)

Type of fracture	No of patients	Percentage (%)
A	**17**	**60.71**
B	**9**	**32.14**
C	**2**	**7.14**

71.42% (20) cases had closed and 28.57% (8) cases had open fracture which was treated preoperatively with intravenous antibiotics and antiseptic dressing. The average number of days from injury to surgery was 10 days (range of 4 to 22 days). The operative time ranged from 65 to 125 minutes with average of 82 minute. Primary bone grafting was performed in four cases to fill up the gap at the fracture site caused by compression of cancellous bone. The mean follow up was 16 months (range 12 to 24 months).

All the fractures except two, united in average 22 weeks (range 16-36 weeks) with malunion observed in 2 (7.14%) and delayed union in 4 (14.28%) cases. Two cases (7.14%) of non union underwent revision surgery with secondary bone grafting and ultimately healed with good functional outcome. Infection occurred in 8(28.57%) out of which 5 cases were simple and 3 cases developed wound dehiscence. Simple infections were treated with antibiotics and regular antiseptic dressing. Wound dehiscence was treated with intravenous antibiotics as per culture & sensitivity report, debridement and wound coverage when good granulation tissue formed. Six patients had hardware problem like irritation in skin, 1 patent had reflex sympathetic dystrophy and 4 developed ankle stiffness (Table 4).

Table 4: Showing frequency of complications

Complication	No of patient	Percentage (%)
Infection	8	28.57
Delayed union	4	14.28
Malunion	2	7.14
Non union	2	7.14
Hardware problem	6	21.42
Ankle stiffness	4	14.28
Reflex sympathetic dystrophy	1	3.57

Most patients started partial weight bearing around 8-12 weeks post-surgical fixation. The time of full weight bearing was between 14-24 weeks with an average time of full weight bearing of 16.5 weeks. Functional outcome according to the Olerud and Molander score showed that 14 (50%) patients had an excellent (score >92) outcome while 9 (32.14%) had good (score 87-91) outcome and 5 (17.86%) patients had a fair (score 65-86) outcome (Table 5).

Table 5: Showing final outcome (Olerud and Molander score)

Outcome	No. Of patients	Percentage (%)
Excellent	14	50
Good	9	32.14
Fair	5	17.86

Discussion

Distal tibia fracture poses a major orthopaedic challenge for management. Though conservative management of these fractures has been described, these methods have been largely superseded by operative techniques for displaced or

irreducible fractures, and fractures with intra-articular extension. [15] The aim of this study was to evaluate clinical, functional and radiological outcomes after open reduction and internal fixation of distal tibia fracture plate using distal tibial locking compression plate. Twenty eight patients were followed on average for 16 months (range 12 to 24 months). [16]

The age of the patients in this study ranged from 19 and 70 (average 37.7) years. Most of the patients (82.13%) were in the age group of 19-50 years. The mode of injury in the majority of the patients (64.28%) was road traffic accident. The majority of the fractures operated were extra-articular fractures, i.e. AO/OTA 43-A (60.71%). These fractures were more common in males (67.85%) which can be attributed to the risk of injury due to occupational and ambulant life led by them. Eight patients had associated multiple injuries with visceral injuries and/or associated fractures. These findings were comparable to the studies made by Ahmad M16 and Verma R. [17]

The average number of days from injury to surgery in our study was 10 days (range of 4 to 22 days). The operative time ranged from 65 to 125 minutes with average of 82 minute. As experience gained during study, operative time reduced in later surgeries Mean time between injury and surgery in Cheng W study was 7.1±4.9 days and mean duration of surgery was 87±25.7 minute. [18] Mean operative time in Janssen KW study was 107 min (range 60–195). [19] Mean time between injury and surgery in Garg R study was 10.74 days (range 7-15 days) and mean duration of surgery was around 75 minute. [20] Delay in surgery in our study was due to time taken to reduce the gross swelling and/or settlement of wound.

In our study, all the fractures except two, united in average 22 weeks (range 16-36 weeks). Two cases (7.14%) of non union underwent revision surgery with secondary bone grafting and ultimately healed with good functional outcome. Most patients started partial weight bearing around 8-12 weeks post-surgical fixation. The time of full weight bearing was between 14-24 weeks with an average of 16.5 weeks. These results were quite comparable to other studies. In Janssen KW study, mean time to radiographic union was 19 weeks (range 14–32 weeks), mean time to weight bearing was 3.8 months, and patients returned to work after a mean time of 5.5 months. [19] In Garg R study, average period of union was 20 weeks and average time taken for full weight bearing was 24 weeks. [20] In Cheng W study, healing time was 19.2±23.5 weeks and time of recovery to work was 27.7±28.2 weeks. [18] Aksekili MA study reported a mean duration of radiological union to be 20.7 weeks (range: 16- 28 weeks) in open and 17.96 weeks (range: 10- 36 weeks) in closed fractures. [21]

In our study, there were 2 (7.14%) cases of mal-union and non-union each, and 4 (14.28%) cases having delayed union. Infection occurred in 8 (28.57%) out of which 5 cases were simple and 3 cases developed wound dehiscence. Six (21.42%) patients had hardware problem like irritation in skin, 1 (3.57%) patent had reflex sympathetic dystrophy and 4 (14.28%) developed ankle stiffness. In Dhakar A study, 2 (4%) patients developed superficial skin infection, 2 (4%) patients developed deep infection and 3 (6%) patients developed ankle stiffness, 4 (8%) patients had implant failure and 2 (4%) cases developed varus angulation. [22] Venkateswarlu K study observed 2 (9%) cases of superficial wound infection, 1 (4.5%) case of delayed union and non-union each in their study. [23]

In our study, functional outcome according to the Olerud and Molander score showed that 14 (50%) patients had an excellent result while 9 (32.14%) patients had good result and 5 (17.86%) patients had a fair outcome. In Varma R study, 53% patients had an excellent functional outcome while

30% patients had good outcome and 17% patients had a fair outcome. [17] Garg R study showed good to excellent outcome in 74% cases, fair in 15% and poor in 11% cases. [20,24]

Conclusion

Locking plates are a good device to stabilize the fractures of the distal tibia, especially when used in conjugation with meticulous intraoperative handling of soft tissue and active participation of patients in rehabilitation programme. In our hands, it has indeed been a useful addition to the techniques used to address the challenging problems. The use of locked plate technology allows us to manage fractures with indirect reduction techniques while providing stable fracture fixation.

The limitations of our study include small study group, lack of comparison to other technique and short duration of follow up. Future prospective randomized trials are required to determine the optimal treatment strategy for these injuries with more accuracy.

References

1. Pakalomattom SJ, Varghese V, Georgekutty AM, Ali F, Salil M. Assessment of Outcome of MIPPO in Distal Tibia Fractures Using Locking Compression Plate - A Retrospective Study. Eur. J. Mol. Clin. Med. 2022; 9(2):653-9.
2. Vikranth PS, Varenya NV. A prospective study of distal 1/3rd tibia fracture treated using locking compression plate by minimally invasive percutaneous plate osteosynthesis technique. Int J Res Orthop 2020; 6:951-5.
3. Janssen KW, Biert J, Kampen A. Treatment of distal tibial fractures: plate versus nail: a retrospective outcome analysis of matched pairs of patients. IntOrthop 2007; 31:709-14.
4. Dickson KF, Montgomery S, Field J. High energy plafond fractures treated by a spanning external fixator initially and followed by a second stage open reduction internal fixation of the articular surface—preliminary report. Injury 200;32:SD92-SD98.
5. Ristiniemi J, Flinkkilä T, Hyvönen P, Lakovaara M, Pakarinen H, Biancari F, et al. Two-ring hybrid external fixation of distal tibial fractures: a review of 47 cases. J Trauma 2007; 62:174-83.
6. Ruedi TP, Allgower M. The operative treatment of intra articular fractures of the lower end of tibia. Clin Orthop 1979; 138:105-10.
7. Borrelli J, Prickett W, Song E, Becker D, Ricci W. Extraosseous blood supply of the tibia and the effects of different plating techniques: a human cadaveric study. J Orthop Trauma 2002;16(10) :691-95.
8. Borg T, Larsson S, Lindsjö U. Percutaneous plating of distal tibial fractures. Preliminary results in 21 patients. Injury 2004;35(6):608-14.
9. Qanaw HA, Mar'éi MA, El-Kady RH, Abdelwahab AM. Functional Outcome Following Fixation of Extra Articular Distal Tibial Fracture with Locking Compression Plate Using Minimally Invasive Percutaneous Technique. Annals of R.S.C.B. 2021; 25:13576-89.
10. Frigg R. Development of the Locking Compression Plate. Injury 2003;34 (Suppl 2): B6-B10.
11. Hazarika S, Chakravarthy J, Cooper J. Minimally invasive locking plate osteosynthesis for fractures of the distal tibia- results in 20 patients. Injury 2006;37(9):877-87.
12. Ozsoy MH, Tuccar E, Demiryurek D, Bayramoglu A, Hayran M, Cavusoglu AT, et al. Minimally invasive plating of the distal tibia: do we really sacrifice saphenous vein and nerve? A cadaver study. J Orthop Trauma 2009; 23:132-8.
13. Rockwood and Green's fractures in adults. 8th edition. vol 2. Section four lower extremity. chap 55. 2015:2415-2540.

14. Olerud C, Molander H. A scoring scaling for symptom evaluation after ankle fracture. Arch Orthop Trauma Surg 1984;103(3):190-4.
15. Gupta RK, Rohilla RK, Sangwan K, Singh V, Walia S. Locking plate fixation in distal metaphyseal tibial fractures: series of 79 patients. Int Orthop 2010; 34:1285-90.
16. Ahmad M, Jindal S, Bansal V, Kapila R, Garg RS.Evaluation of outcome of management of o distal tibia fracture using distal tibia locking plate. J. Foot Ankle Surgery (Asia-Pacific) 2017;4 (1) 5-9.
17. Varma R, Rai SK, Arora NC, Sharma B, Wani SK. Management of comminuted distal metaphyseal tibial fractures with 3.5 mm anatomical anterolateral locking compression plate: A study of 34 cases. International Journal of Orthopaedics Sciences 2017;3(1):780-4.
18. Cheng W, Li Y, Manyi W. Comparison study of two surgical options for distal tibia fracture—minimally invasive plate osteosynthesis vs. open reduction and internal fixation. International Orthopaedics (SICOT). 2011; 35:737-42.
19. Janssen KW, Biert J, Kampen AV. Treatment of distal tibial fractures: plate versus nail. International Orthopaedics (SICOT) 2007; 31:709-14.
20. Garg R, Gupta R. Locking Compression Plate Osteosynthesis In Fracture Of Distal Tibia – Result Of 27 Patients. International journal of Innovative Research and Development 2013; 2:405-09.
21. Aksekili MA, Celik I, Arslan AK, Kalkan T, Uğurlu M. The results of minimally invasive percutaneous plate osteosynthesis (MIPPO) in distal and diaphysealtibial fractures. Acta Orthop Traumatol Turc 2012; 46(3) :161-7.
22. Dhakar A, Annappa R, Gupta M, Harshwardhan H, Kotian P, Suresh PK. Minimally Invasive Plate Osteosynthesis with Locking Plates for Distal Tibia Fractures. Journal of Clinical and Diagnostic Research 2016; z10(3):RC01-RC04.
23. Venkateswarlu K, Madiga N, Sivababu P. A study of MIPO by locking compression plate fixation in the management of distal tibial metaphyseal fractures. Int J Res Med Sci 2015; 3:675-9.
24. Kenfun, M. M., Gallouo M., Alafifi Mahmoud, Tsikambu A. C. D., Alafifi, R., Moataz A., Dakir M., Debbagh A., & Aboutaieb R. Pyonephrose: Risk factors, clinical, para-clinical and anatomopathological profile about 19 cases. Journal of Medical Research and Health Sciences, 2022;5(2): 1770–1773.