e-ISSN: 0975-1556, p-ISSN:2820-2643

Available online on www.ijpcr.com

International Journal of Pharmaceutical and Clinical Research 2022; 14 (10); 471-475

Original Research Article

Morphometric Assessment of the Insertion and Relation of Brachialis with the Neurovascular Structures of the Arm

Virwar Kumar Jha[1], Pramita Kumari[2], Kumari Ayushree[3]

[1]Senior Resident, Department of Anatomy, ESIC Medical College and Hospital, Bihta, Patna, Bihar, India

[2]Senior Resident, Department of Anatomy, ESIC Medical College and Hospital, Bihta, Patna, Bihar, India

[3]Assistant Professor, Department of Anatomy, ESIC Medical College and Hospital, Bihta, Patna, Bihar, India

Received: 25-08-2022 / Revised: 22-09-2022 / Accepted: 07-10-2022
Corresponding author: Dr. Pramita Kumari
Conflict of interest: Nil

Abstract:

Aim: The present study was done to observe the insertion of brachialis and course of the Median nerve and the Brachial artery related to it.

Methods: The study was conducted on 18 upper limbs from embalmed cadavers from the department of anatomy, ESIC medical college and hospital, Bihta, Patna, for the period of 1 year. A longitudinal incision was made in the anterior surface of brachial fascia from the level of pectoralis major to the elbow. The limbs were routinely dissected for observing the insertion of Brachialis and its relation to the neurovascular structures in the arm.

Results: In 16 specimens (88.9%), the Brachialis muscle is inserted into the anterior aspect of the coronoid process and the tuberosity of ulna, The Median nerve and the Brachial artery passes superficial to the brachialis muscles and the relationship was normal. In 2 specimen (11.1%) a tunnel was formed by brachialis muscles in the lower 1/3 of right upper limbs. The length of the tunnel was measured about 2.5 cm.

Conclusion: Considerable difference in the morphology of the brachialis was found in the present study as compared to the classical picture found in standard textbooks. And hence, there is a requirement for revising its anatomy.

Keywords: Anatomical variations, Brachialis tunnel, Entrapment syndrome, Median nerve

Introduction

The brachialis muscle, also known as the 'work-horse' [1] of the elbow is one of the three muscles of the anterior compartment of the arm. It is primarily involved in the flexion at the elbow joint as compared to the biceps brachii muscle which is also involved in supination of the radio-ulnar joints. It lies deep to the biceps brachii muscle after taking origin from the anterolateral and anteromedial surfaces of the shaft of the humerus as well as the anterior border and adjoining medial and lateral intermuscular septa below the insertion of the coracobrachialis and

deltoid muscles. [2] Thereafter, all the fibres converge below to form elongated and broad tendon which forms the floor of the cubital fossa. The tendon then gets inserted into the anterior surface of the coronoid process and ulnar tuberosity of the ulna. [2,3] Some of its fibres blend with the capsule of the elbow joint, known as Portal's muscle. [3]

The brachialis is an important flexor of the forearm at the elbow. [4] The brachialis provides flexion of the elbow at all physiologic positions and is considered a "purse flexor" of the forearm at the elbow. [5] The head is more superficial and has greater volume creating a biomechanical advantage that allows it to be the main actor in the elbow flexion. The smaller head, being oblique and deep, facilitates the beginning of the elbow flexion from a position of complete articular extension. The brachialis is an elbow flexor that originates from the distal anterior humerus and inserts onto the ulnar tuberosity. The brachialis is one of the largest elbow flexors and provides pure flexion of the forearm at the elbow. [5]

Being a hybrid or composite muscle, it has a dual nerve supply. The Musculocutaneous Nerve (MCN) supplies the major part of the muscle and RN supply small lateral part of muscle. It is the most powerful flexor of the elbow joint in any position of the elbow. [6] However, it has been highly ignored in history and consequently, the literature describing its morphology is relatively very scarce as compared to other muscles. Ascertaining the morphology of the muscle is of considerable clinical significance as infrequent mention of the pathologies like a tear, ruptures, tendinopathies etc., coupled with the conflicting reports of its morphology may often leads to inaccurate diagnosis of clinical conditions pertaining to it. [2,7]

The anatomical variations of the brachialis has its imprints in the prenatal life, when at about the fifth week of development a complex interaction between several components, such as the growth factors and pre-adhesion molecules facilitate the migration of the myoblast to the limb buds followed by their orderly and synchronised distribution. [8,9] The muscle develops from two fused muscular primordia namely the ventral/flexor and the dorsal/extensor pre-muscle masses and this is reflected in the dual nerve supply of the muscle. There is an alternate school of thought that believes that the muscle develops solely from the ventral one and the nerves supplying it originates from the ventral division of the brachial plexus and reach the muscle through the RN and supply it. [10]

Knowledge of anatomical variations in the muscular structure and its related neurovascular entrapment is important surgically for orthopaedic surgeons, plastic surgeons and also physiotherapist clinically, hence the present study was done to observe the insertion of brachialis and course of the Median nerve and the Brachial artery related to it.

Methods

The study was conducted on 18 upper limbs from embalmed cadavers from the department of anatomy, ESIC medical college and hospital, Bihta, Patna, for the period of 1-year. A longitudinal incision was made in the anterior surface of brachial fascia from the level of pectoralis major to the elbow. The limbs were routinely dissected for observing the insertion of Brachialis and its relation to the neurovascular structures in the arm. The course of the median nerve and brachial artery were observed. The photograph of the variations is taken for proper documentation and ready reference.

Results

In 16 specimens (88.9%), the Brachialis muscle is inserted into the anterior aspect of the coronoid process and the tuberosity of ulna, The Median nerve and the Brachial artery passes superficial to the

brachialis muscles and the relationship was normal. In five specimen (11.1%) a tunnel was formed by brachialis muscles in the lower 1/3 of right upper limbs. The length of the tunnel was measured about 2.5 cm. It was unilateral whereas in the left arm of the same cadaver, it was normal. Entrapment of the Brachial artery and the Median was observed in this case with in the tunnel of the brachialis.

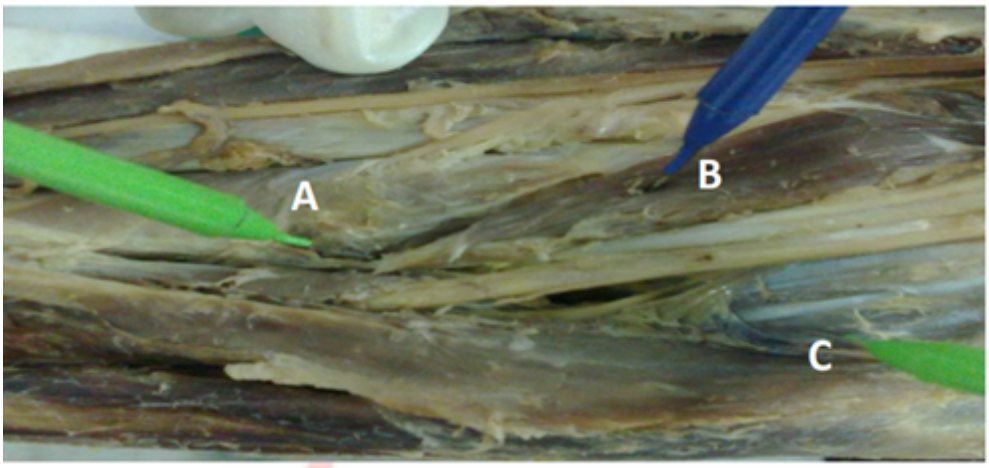

Figure 1: A - Showing insertion of accessory slip onto Radial Tuberosity B - Showing accessory slip C - Showing main brachialis

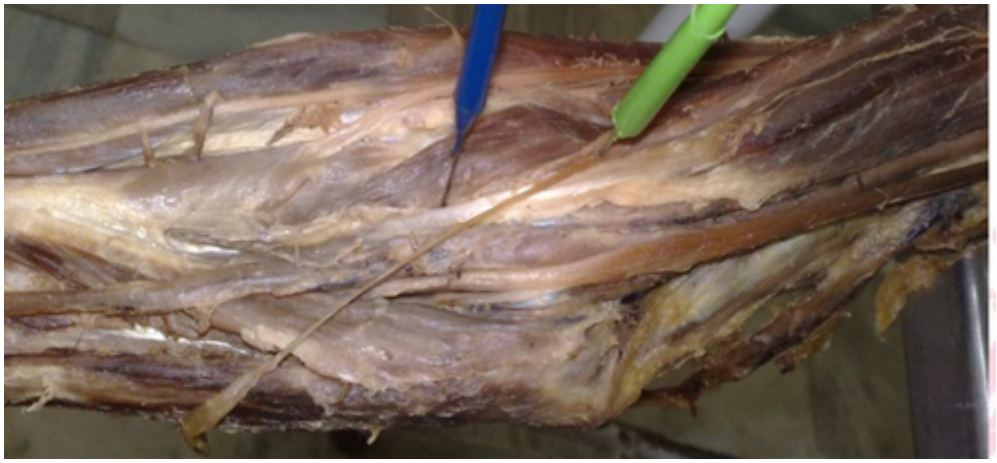

Figure 2: Showing Accessory slips insertion into the main brachialis muscle

Discussion

The morphological variations of the brachialis muscle are frequented mostly in the form of accessory slips[1] arising from the adjacent structures and merging with the muscle or vice versa till a decade back when a relook of the anatomy of the muscle revealed that it consisted of two heads; the larger and bulkier SH and the fan shaped DH. The SH is lateral and has longitudinal fibres whereas the DH is medially placed which had oblique fibres. [2,6] The insertion of the SH is at the ulnar tuberosity by a tendon whereas the DH is attached to the coronoid process of the ulna by an aponeurosis. [6,7,10-12]

Detailed knowledge of the morphology of the brachialis and its relations is a pre-requisite for any surgery in this region especially in pediatric patients where supracondylar fracture of the humerus is very common. [2]

The literature abounds with case reports of accessory slips of the brachialis muscle, which also known as brachialis anticus. [1] In the present study, the accessory slips of

origin were found in four (5%) specimens. The accessory slips of the muscle with regards to origin could have biomechanical consequences, since the elbow joint is also regarded as a buttress. [8] Accessory slips could have a role in restoration and enhancing supination of the forearm, in cases of tendon rupture of the biceps by the reconstruction of the tendon and its subsequent transfer to the radial tuberosity. [2,7,8]

This variation has all possibilities by entrapment neuropathy since the Median nerve and the Brachial artery were found compressed under the Musculo-fascial structure which had an unyielding nature. Hence, we assume that the clinical indications possibly presented in such entrapment might be similar to that pronator syndrome. But in advance stages compression could lead to endothelial damage & Thrombotic occlusion of the Brachial artery. Clinically these kinds of tunnel will produce symptoms in the forearm & hand also. [13] In the present study, the tunnel was formed by the Brachialis muscle which arose from the superficial fibre with its aponeurosis 2.5cm in length, extending downward and overlapping the median nerve and brachial artery to get inserted into the medial intermuscular septum. The clinical implications of the slips of brachialis are that it has the potential to cause the Median nerve entrapment & Brachial artery compression.

The Brachialis muscle is reported in this case may be explained on the basis of the embryogenesis of the muscles of the arm. During development of the limb bud, the Brachialis muscle develops from the fusion of two muscular primordial. Most of it is formed from the ventral or flexor pre muscular mass (which is supplied by the ventral rami of spinal nerves) and a part of it is formed from dorsal or extensor pre muscular mass (which is supplied by the dorsal rami of spinal nerves). Some authors state that Brachialis arises only from the ventral pre muscular mass and the branch of Radial nerve which supplies it, is derived from anterior division of Brachial plexus which uses Radial nerve only as route to Brachialis muscle by unknown mechanisms. However this view has no reliable evidence. The extensor pre muscular mass in the forearm differentiates into three parts. [13] Thereafter, some muscle primordia will disappear through cell death called apoptosis. The variation in the present study may be due to failure of muscle primordia to disappear during embryological development. [14,15]

Conclusion

Considerable difference in the morphology of the brachialis was found in the present study as compared to the classical picture found in standard textbooks. And hence, there is a requirement for revising its anatomy. A substantial difference was found in the innervations of the muscle which could be important from the anaesthetic, surgical and orthopaedic point of view and these differences should be kept in mind before undertaking any surgical procedure in the elbow region. It is highly recommended that more anatomical studies are carried out by correlating the gross morphology with ultrasonography, MRI based or EMG data analytical methods. Therefore, the knowledge about this kind of rare variations is important for surgeons to avoid mislead diagnosis and treatment.

References

1. Khandey S. Morphology of brachialis muscle: variations and clinical significance. Int J Anat Res. 2014; 2(1) :184-86.
2. Ilayperuma I, Uluwitiya SM, Nanayakkara BG, Palahepitiya KN. Re-visiting the brachialis muscle: Morphology, morphometry, gender diversity, and innervation. Surgical and Radiologic Anatomy. 2019;41(4):393-400.

3. Kamineni S, Bachoura A, Behrens W, Kamineni E, Deane A. Distal insertional footprint of the brachialis muscle: 3D morphometric study. Anatomy Research International. 2015; 2015.
4. Nygaard E, Houston M, Suzuki Y, Jørgensen K, Saltin B. Morphology of the brachial biceps muscle and elbow flexion in man. Acta Physiologica Scandinavica. 1983 Feb;117(2):287-9 2.
5. Palazzi S, Palazzi JL, Caceres JP. Neurotization with the brachialis muscle motor nerve. Microsurgery: Official Journal of the International Microsurgical Society and the European Federation of Societies for Microsurgery. 2006;26(4):330-3.
6. Leonello DT, Galley IJ, Bain GI, Carter CD. Brachialis muscle anatomy: a study in cadavers. JBJS. 2007 Jun 1; 89(6):1293-7.
7. Sanal HT, Chen L, Negrao P, Haghighi P, Trudell DJ, Resnick DL. Distal attachment of the brachialis muscle: anatomic and MRI study in cadavers. American Journal of Roentgenology. 2009;192(2):468-72.
8. Mehta V, Yadav Y, Arora J, Kumar H, Suri RK, Rath G. Clinico-embryological perspective of a rare accessory brachial muscle with possible musculocutaneous nerve compression. Morphologie. 2009 Mar 1;93(300):27-9.
9. Misba CA, Rajasekar SS. A slip from brachialis muscle to brachioradialis muscle– a case study. RGUHS Journal of Medical Sciences. 2013;3(4):222-24
10. Jayakumar, VR, Bajpe, R, Shubha, R. Variation in the insertion of brachialis muscle – a case report. IJSR. 2013;3: 172-75.
11. Yamamoto M, Kojyo U, Yanagisawa N, Mitomo K, Takayama T, Sakiyama K, Abe S. Morphology and relationships of the biceps brachii and brachialis with the musculocutaneous nerve. Surgical and Radiologic Anatomy. 2018 Mar;40(3):303-11.
12. Tagliafico A, Michaud J, Perez MM, Martinoli C. Ultrasound of distal brachialis tendon attachment: normal and abnormal findings. The British Journal of Radiology. 2013 May;86 (1025):20130004.
13. Tan ST, Smith PJ. Anomalous extensor muscles of the hand: a review. The Journal of hand surgery. 1999 May 1;24(3):449-55.
14. Lewis WH. vol. Vol 2. Keibel F, Mall FP, editors. Philadelphia: JB Lippincott; 1910. p. 455–522.
15. Demir, hulya, & Oyman, B. U. (2022). Essential Oil Essential Oil Analysis of Some Plants. Journal of Medical Research and Health Sciences, 5(8), 2197–2202. https://doi.org/10.52845 /JMRHS/2022-5-8-9