e-ISSN: 0975-1556, p-ISSN:2820-2643

Available online on www.ijpcr.com

International Journal of Pharmaceutical and Clinical Research 2022; 14(11); 1010-1019

Original Research Article

Evaluation of Early Weight Bearing Mobilization Following Surgical Fixation of Unstable Ankle Fractures: A Prospective Study

Sunil Kumar Kar

Assistant Professor, Hi-Tech Medical College &Hospital, Rourkela, Odisha, India

Received: 25-08-2022 / Revised: 23-09-2022 / Accepted: 26-10-2022

Corresponding Author: Dr Sunil Kumar Kar

Conflict of interest: Nil

Abstract:

Objective: The study aimed to evaluate and compare the benefits of immediate early weight-bearing over late weight-bearing mobilization and the results of early weight-bearingin unstable ankle fractures treated surgically.

Design: Prospective study.

Materials and Methods: The current study was a prospective study carried out at the Department of Orthopedics, IMS & SUM Hospital from Oct 2017 to June 2019. The Institutional Ethics Committee, IMS & SUM Hospital, Bhubaneswar approved the current study. The study proforma was designed according to the aim of the study and data were collected. A total of 120 skeletally mature patients underwent ankle surgery, 50 of which were allowed immediate weight bearing as tolerated (IWBAT) in the acute postoperative period and were taken into the study.

Outcome Measures: Patients underwent wound assessment, radiographic analysis of fracture reduction maintenance, clinical evaluation of fracture healing and evaluation of complications necessitating additional surgery at the scheduled follow-up. Each patient was assessed six months later using the Modified American Academy of Orthopaedic Surgeons Foot and Ankle Scale (MAAOSFS). The study was carried out from Oct 2017 to June 2019 in IMS and SUM Hospital, Bhubaneswar.

Results: The current study explored whether IWBAT is a safe substitute for a period of protected weight-bearing in a subset of patients with stable osteosynthesis after an ankle fracture. Early return to full weight bearing is linked to earlier weight-bearing without compromising the functional outcome scores. It was found that a fraction of 52% of patients come under the low energy falls mode of injury out of 50 patients.

Conclusions: A safe substitute for a period of protected weight-bearing after an ankle fracture is IWBAT in a subgroup of patients with stable osteosynthesis. Better mobility, shorter hospital stays, and an earlier return to work have all been linked to earlier weight-bearing. Patients with closed ankle fractures that do not involve the tibial plafond, do not have syndesmotic disruption and have stable fixation are candidates for IWBAT.

Keywords: IWBAT, osteosynthesis, Foot and Ankle Scale.

Introduction

Ankle fractures rank among the injuries that orthopedic surgeons treat most frequently [1, 2]. Although osteosynthesis techniques for bimalleolar ankle fractures are comparatively well-established, patient comorbidities, surgeon preference, and fracture pattern can all affect the surgical plan.

There have been several descriptions of fixation techniques for lateral malleolar fractures; currently in use methods include intramedullary devices, lag screws with neutralization plating, anti-glide plating, and bridge plating in cases of combination. Similar to this, medial malleolus fractures can be stabilized with screws, tension band structures, or buttress plating methods [3,4].

While the guidelines for surgery are fairly well established, there is still debate about the best time to allow patients in this group to bear weight after surgery due to a lack of research on postoperative weight-bearing protocols.

Correct implementation of the rehabilitation plan is associated with a quicker return to function and an earlier return to daily activities. Most surgeons recommend a 6-week non-weight-bearing period after surgical treatment for ankle fractures, followed by gradually increasing weight bearing.

Reducing fracture-related disability is the main objective of both the surgical procedure and the rehabilitation program. Reducing the length of convalescence or prolonged periods of immobilization is a secondary objective since it can prevent complications like joint stiffness, ligamentous and musculotendinous atrophy, longer recovery times before returning to work, and challenges performing activities of daily living (ADLs) [5, 6].

The prime aim of the study was to elucidate the benefits of immediate early weight bearing over LWB mobilization and the outcomes of early weight bearing in lower extremity fractures treated surgically. Even though the earlier studies help compare different postoperative courses, there still needs to be more literature that sufficiently explains the safety and effectiveness of early weight bearing after ankle fractures, particularly for bimalleolar variants [7]. Hence, the current study postulated that nonunion, malunion, and hardware failure rates would not adversely affect early weight bearing after bimalleolar ankle fracture fixation nor would postoperative radiographic alignment. The crucial objective in the current study was to determine the functional outcome and radiological variation after early weight bearing in patients with unstable ankle fractures.

Materials and Methods

The current study was approved by the Institutional Ethics Committee of the concerned institutional review board, IMS &SUM Hospital, Bhubaneswar. The author of the current study retrospectively reviewed a prospectively collected orthopedic trauma database at a Level 1 trauma center to identify patients who had unstable ankle injuries treated between from Oct 2017 to June 2019.

In total, 110 skeletally mature patients underwent ankle surgery, 60 of whom were allowed to bear weight during the acute postoperative phase as soon as they were able to do so. The author experience indicates that patients were not permitted to become weight-bearing as tolerated for the following reasons:

- Frank fracture dislocation requiring manipulation and reduction under sedation.
- Frank fracture and dislocation requiring revision surgery.
- Plafond or talarosteochondral defect
- Soft tissue problems and bone loss (requiring a bone graft and additional fixation).
- Syndesmotic fixation
- Polytraumatic patients with injuries otherwise prohibiting weight-bearing.
- Combinations of two or more of those above.

Of the 60 patients, seven did not follow up after the two-week mark, three did not attend their scheduled two-week clinic appointment. Fifty patients were therefore included for evaluation.

A thorough medical history and physical examination of patients, either in the emergency room or in a clinic was undertaken. The AO/OTA classification system was used to categorize fractures. When stress radiographs or positive gravity stress views showed more than 4 mm medial clear space widening, bimalleolar, trimalleolar, fracture dislocation and fibular fractures in distal one third were considered unstable. Internal fixation of the fibula and open anatomic reduction were part of the operational protocol. A well-contoured 6- to 8-hole 3.5mm DCP or one third tubular plate or intramedullary nail were used to fix the lateral malleolus. Two lag screws or 4.5 mm malleolar screws or tension band wiring using two k wires and stainless steel wires were used to fix the fractures in the medial malleolus. If the malleoli were fixed and stress testing showed widening, the syndesmosis was reduced and secured with one or two 3.5 mm screws.

Postoperative protocols were similar for each patient; for patients who were granted IWBAT, walker boots with controlled ankle motion (CAM) were utilized as protection. The boot was worn nonstop for the first two weeks. Patients were told to keep the wound dry until they were seen at the two-week clinic follow-up. After two weeks, the dressings were removed, and the wound was assessed. The patients were then instructed to continue wearing the CAM Walker Boot for an additional two to four weeks. The lateral, anteroposterior, and mortise views of an ankle three-view radiograph were obtained at weeks six, twelve, twenty-four, and fifty-two. The boot was taken off if the patient had not transitioned to shoes after six weeks of surgery. An adjustable ankle brace was provided to patients to help with the weaning process.

Patients underwent wound assessment, radiographic analysis of fracture reduction healing, clinical evaluation of fracture healing, and evaluation of complications necessitating additional surgery at the scheduled follow-up(Figure 1-3).

Figure 1: Case 1.a Preoperational condition

Figure 2: Case 1.b Post-operational condition

Figure 3: Case 1.c. Six months follow up post- operational condition

Figure 2: a. Case -2 pre-operation **Figure 2: b. immediate post operation**

Figure 2: c. Post operation condition 6 months follow up

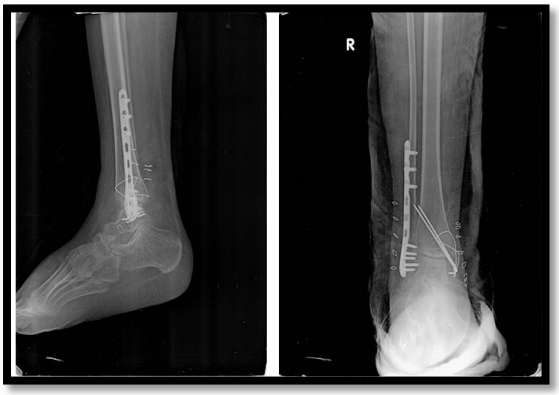

Figure 3: a. Case -2 Pre-operation condition **Figure 3: b. Post operation**

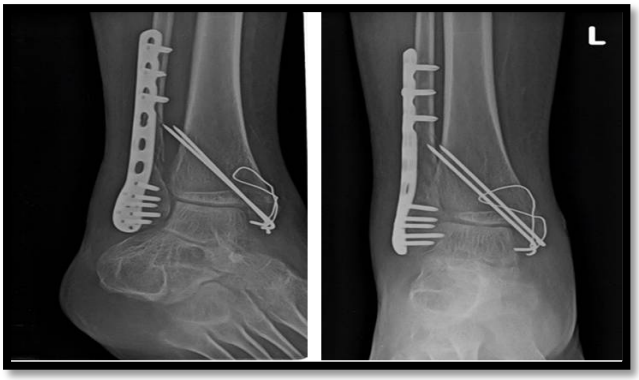

Figure 3: c. Follow up post operation condition

Figure 1-3 different conditional figures pre-operation, immediate post-operational condition and 6 month follow-up condition.

Each patient was assessed six months later using the Modified American Academy of Orthopaedic Surgeons Foot and Ankle Scale (MAAOSFS). The American Academy of Orthopaedic Surgeons (AAOS) scale, 2004, served as the model for this modification. It consists of four subscales (20 items) totalling 100 points, with 45 items related to pain, 30 to function, 10 to stiffness and swelling, and 15 to give way.

The four subscales—20 for function, 20 for pain, 20 for stiffness and swelling, and 20 for giving way-each consisting of ten questions and a maximum score of 10 on an objective scale remain in the revised scale. The items were graded using a variable system from 0 to a maximum of 10. To represent functionality, the scores are added up and then deducted from 100; the lower the score, the more disabled the patient is (a maximum score of 100 points and a minimum score of 0 points could be obtained). Running is the highest activity on the AAOS scale. We had difficulty evaluating this because most of our patients don't jog. As a result, we started climbing stairs.

Statistical analysis:

The data generated from the study was analyzed by the SPSS software version 22; all the data were shown inform of fractional distribution and percentages.

Results

In the current study the average age of the 26 patients who received at least six weeks of follow-up was 50 years old (range: 20–95 years), with 38 (76%) being male and 12 (24%) being female (Table 1).

Table 1:

Ankle fractures	Frequency (n)	Fraction distribution (%)
Male	38	76
Female	12	24
Age range		
40-50	9	18
51-60	14	28
61-70	19	38
>70	8	16

The mode of injury was distributed and the results obtained were a fraction of 52% low energy fall, 22% were from road traffic accidents, 14% were from the sports injuries and 12% were assaulters from the included patients (Table 2).

Table 2:

Mode Of Injury	Frequency	Fractional distribution (%)
Low Energy Falls	26	52%
Road Traffic Accidents	11	22%
Sports Injuries	7	14%
Assault	6	12%

There were four of type-44 A (4%), twenty-one of type-44 B (81%), and one of type-44 C1 (4%), which did not require syndesmotic reduction and fixation, according to the AO/OTA fracture classification. Out of all the patients, two (8%) had noninsulin dependent diabetes without peripheral neuropathy and fifteen (58%) smoked cigarettes.

Twenty one third tubular plates (77%), four pre-contoured posterolateral plates (15%), and one intramedullary nail (4%) was used in the fixation of the lateral malleolus. Eighteen patients (69%) required bimalleolar fixation, five cases (19%) needed syndesmotic fixation, three cases needed isolated fibular fixation and two cases (12%) involved the need for

fixation due to a posterior malleolus fracture.

Intraoperative post fixation radiographs of twenty-five patients showed symmetric joint space surrounding the talus. One patient's lateral collaborative space was elevated by 1.7 mm compared to medial and superior clear space.

The follow-up period was 140 days on average (40–478 days). A brief course of oral antibiotics (8%), which resolved the peri-incisional erythema in two patients, was observed during the two-week clinical evaluation.

There were no wound complications at six weeks. By the six-week mark, twenty patients were wearing regular shoes, and six were still wearing CAM boots for comfort. Three patients had persistent ankle stiffness at the last clinic visit; one patient had symptoms suggestive of a peroneal tendon subluxation, which was treated with physical therapy; and one patient needed to have the medial malleolar fixation removed because of symptomatic hardware.

At six weeks, radiographic evaluation showed one loss of reduction (4%) and no loss of reduction in 25 patients (96%) overall. Compared to medial and superior clear space, this patient's lateral joint space was 1.7 mm greater.

At six weeks, the lateral joint space was 4.8 times larger than the superior and medial clear spaces. Upon reviewing intraoperative fluoroscopy images, a missed syndesmotic injury in the patient was identified.

Discussion

This study shows that IWBAT is a safe substitute for a period of protected weight-bearing in a subset of patients with stable osteosynthesis after an ankle fracture. Early return to full weight bearing is linked to earlier weight-bearing without lowering functional outcome scores.

Treating stable ankle fractures with early weight-bearing is standard practice. It makes rehabilitation easier and improves the patient's range of motion. Additionally, research has demonstrated that early weight-bearing is associated with decreased osteoporotic changes and decreased calf atrophy. Simanski et al.'s research shows a positive trend toward earlier weight bearing after ankle fractures, return to work, and shorter hospital stays.

The purpose of this study was to determine whether early loss of fixation would occur from immediately assuming weight after stabilization of unstable ankle fractures. Only one other group, as far as I know, has released a series on immediate weight bearing following ankle fixation without the need for a cast. Time to return to work was the primary outcome measure used by Egol in his evaluation of two groups of patients who had suffered ankle fractures.

Following fixation, a functional brace was used for one group of patients while a below-the-knee cast was used for the other. On the afflicted side, neither group could bear any weight. The functional brace early movement group experienced a significantly shorter mean time from surgery to return to work (7.6 versus 15.2 weeks). At six weeks, the functional outcome scores of the patients in the functional brace group were notably higher.

In a prospective study, Ahl et al. contrasted weight-bearing immediately and later following ankle fixation in a cast

below the knee. There was no discernible difference between the two groups at three or six months according to radiographic and clinical analysis.

A return-to-work timeline was not established. More recently, 126 patients who underwent surgery to repair acute unilateral closed ankle fractures and were able to bear weight in a short leg cast within 15 days were examined retrospectively by Starkweather et al. On the final follow-up examination, 99 percent of the radiographs revealed no loss of reduction. In a prospective study, Simanski et al. compared six weeks of non-weight bearing in a below-the-knee cast with three weeks of functional early weight-bearing.

Following surgery, the early weight-bearing group was permitted to return to partial weight-bearing (10–15 kg) while wearing an Aircast Air-Stirrup Brace. After three weeks, if no issues were found, the patients were then permitted to bear their entire weight. Before the delayed group, early weight-bearing patients achieved full weight bearing (7.7 versus 13.5 weeks, P = 0.01). Clinically and radiographically, the early weight-bearing group did not show any disadvantages.

The current study compared with the other studies to see the ankle score of the patients and it was shown that the standard deviation by Laarhoven et al had 16.84, Egolet al.14.25, Sonderaa et al had 10.66 and from our data the ankle score was 76 with standard deviation 11.45. This indicates the stable ankle score while comparing with other studies (Table 3).

Table 3: Review and comparison with the current study in terms of ankle score and SD with the previous studies

	Laarhoven et al	Egol et al	Sondenaa et al	Current study
Ankle Score	54	55	73	76
SD	16.84	14.25	10.66	11.45

I only found one study by Arif et al. that permitted immediate weight-bearing without needing a cast below the knee. In this retrospective study, patients were divided into two groups: those placed in a cast and rendered non-weight-bearing for six weeks and those permitted to bear weight as tolerated after surgery without a cast.

There was no statistically significant difference in Olerud's and Molander's scores between the groups. It was statistically significant that the early weight-bearing group took 55 days to return to work, while the delayed weight-bearing group took 91 days. The above-stated studies all suggest that earlier weight-bearing and motion would allow patients to return to function without any compelling disadvantage. This study shows that the patients can fully bear weight as tolerated during the immediate postoperative period if the fixation is stable, similar to patients with stable ankle fractures. In this study there was one case of loss of reduction and fixation failure. This occurred as a result of a missed syndesmotic injury. This reaffirms the importance of identifying syndesmotic disruptions.

Limitations of the study: This study has several limitations inherent in any

retrospective case series. The major limitation was that only a subset of patients with unstable ankle fractures was allowed immediate full weight-bearing.

A discretion practice guideline was followed in this study, which does not allow IWBAT in polytrauma patients, cases of syndesmotic disruption, and concerns for soft tissue compromise. Additionally, one should consider not allowing patients with poorly controlled diabetes and peripheral neuropathy to bear weight immediately due to soft tissue healing concerns. Patients with poor bone quality and comminution should also be excluded. While such patients were not excluded in this study, they can theoretically result in early failures in patients who are allowed to bear weight immediately.

Moreover, limitation of this study is that of not having a control group, and seven patients did not have appropriate follow-up and were therefore excluded. If all seven of these patients had a loss of reduction, then the failure rate would be unacceptable at 24%. Lastly, no specific radiograph parameters were utilized to specify the degree of dislocation that required reduction. Although this study supports immediate weight-bearing postoperatively for a subset of patients with ankle fractures,Ifeel that a controlled, prospective trial is warranted to look further at the influence of delayed versus immediate weight-bearing after ankle fixation surgery.

Conclusion

A safe substitute for a period of protected weight-bearing after an ankle fracture is IWBAT in a subgroup of patients with stable osteosynthesis. Better mobility, shorter hospital stays, and an earlier return to work have all been linked to earlier weight-bearing.

Patients with closed ankle fractures, without involvement of the tibial plafond, who do not have syndesmotic disruption and have stable fixations, are the candidates for IWBAT.

Acknowledgment: The study investigator isobliged to the medical management and other staffs who helped to undertake the study smoothly.

References

1. D. Michelson, “Ankle fractures resulting from rotational injuries,” The Journal of the American Academy of Orthopaedic Surgeons, 2003; 11(6): 403–412.
2. Praemer, S. Furner, and D. P. Rice, Musculoskeletal Conditions in the United States, The American Academy of Orthopaedic Surgeons, Park City, Ill, USA, 1992.
3. Kubiak EN, Beebe MJ, North K, Hitchcock R, and Potter MQ: Early weight bearing after lower extremity fractures in adults. J Am AcadOrthop Surg. 2013, 21:727738.
4. Ağır İ, Tunçer N, Küçükdurmaz F, Gümüstaş S, Akgül ED, Akpinar F: Functionalcomparison of immediate and late weight bearing after ankle bimalleolar fracture surgery . Open Orthop J. 2015, 9:188-190.
5. Simanski CJ, Maegele MG, Lefering R, et al.: Functional treatment and early weightbearing after an ankle fracture: a prospective study. J Orthop Trauma. 2006, 20:108-114.
6. Firoozabadi R, Harnden E, Krieg JC: Immediate weight-bearing after

ankle fracture fixation. AdvOrthop. 2015, 2015:491976.

7. Lin CW, Donkers NA, Refshauge KM, Beckenkamp PR, Khera K, Moseley AM: Rehabilitation for ankle fractures in adults. Cochrane Database Syst Rev. 2012, 11:CD005595.
8. Egol, K.A., Dolan, R. K. and Koval, J. A prospective, randomised comparison of management in a cast or a functional brace. J. Bone Joint Surg. [Br] 2000; 82-B: 246-249.
9. Lindsjö, U. Operative treatment of ankle fracture-dislocations. A follow-up study of 306/321 consecutive cases. Clin. Orthop. Relat. Res.1985; 199:28-38.
10. Papachristou G. Efstathopoulas, N; Levidiotis, C; Chronopoulos, E. et al. Early weight bearing after posterior malleolar fractures: An experimental and prospective clinical study. J. Foot Ankle Surg. 2003; 42(2):99-104.
11. Lin, C.W., Moseley, A.M. and Refshauge, K.M. Rehabilitation for ankle fractures in adults. Cochrane Database Syst. Rev. 2008 Jul 16;(3): CD005595.
12. Ahl, T., Dalén, N., Lundberg, A. and Bylund, C. Early mobilization of operated on ankle fractures. Prospective, controlled study of 40 bimalleolar cases. ActaOrthop. Scand. 1993; 64(1):95-99.
13. Simanski, C.J., Maegele, M.G., Lefering, R., Lehnen, D.M., Kawel, N. et al. Functional treatment and early weightbearing after an ankle fracture: a prospective study. J. Orthop. Trauma. 2006; 20 (2):108-114.
14. Honigmann, P., Goldhahn, S., Rosenkranz, J., Audigé, L., Geissmann, D. and Babst, R. After-treatment of malleolar fractures following ORIF -- functional compared to protected functional in a vacuum-stabilized orthotics: a randomized controlled trial. Arch. Orthop. Trauma Surg. 2007 Apr; 127(3):195-203. Epub 2006 Dec 30.
15. Harager, K; Kisten, H; Claus, J.M. Kim S. et al. Successful immediate weight bearing of internal fixated ankle fractures in a general population. J. Orthop. Sci. 2000; 5: 552–554.