e-ISSN: 0975-1556, p-ISSN:2820-2643

Available online on www.ijpcr.com

International Journal of Pharmaceutical and Clinical Research 2022; 14(11); 169-175

Original Research Article

Outcome Analysis of Transforaminal Lumbar Interbody Fusion in Degenerative Spine Diseases

Manish Rajpoot[1], Praveen Khatri[2], Chetan Solanki[3], Kuldeep Dinkar[4], Vishal Nigwal[5], Brajesh Meher[6], Suneet Tandon[7]

[1]Assistant Professor, Gandhi Medical College, Bhopal
[2]Senior Resident, Gandhi Medical College, Bhopal
[3]PG Resident, Gandhi Medical College, Bhopal
[4]PG Resident, Gandhi Medical College, Bhopal
[5]Senior Resident, Gandhi Medical College, Bhopal
[6]PG Resident, Gandhi Medical College, Bhopal
[7]Professor and Head of Department of Orthopaedics, Gandhi Medical College, Bhopal

Received: 14-92022 / Revised: 21-10-2022 / Accepted: 06-11-2022
Corresponding author: Dr Kuldeep Dinkar
Conflict of interest: Nil

Abstract

Prevalence of Low Back Pain (LBP) seeking medical treatment ranges from 59% to 84%. Lumbar degenerative diseases are among common aetiologies of lower back pain and significantly affect quality of life. Over 90 % of spine surgeries are performed because of degenerative disc diseases (DDD).

Aim: To assess the outcome of open transforaminal lumbar interbody fusion (TLIF) performed in degenerative lumbar spine diseases having chronic low back pain.

Study design: A prospective interventional study.

Material and Methods: our study included 20 patients of degenerative lumbar spine diseases having chronic lower back pain, underwent open transforaminal lumbar interbody fusion (TLIF) were studied at tertiary care centre from January 2020 to June 2021 in the Department of Orthopaedics Gandhi Medical College and associated Hamidia Hospital, Bhopal, Madhya Pradesh. Outcome was assessed using Visual analogue scale (VAS score) for Pain relief at back and leg, Oswestry disability index (ODI) was used to assess quality of life pre-operatively and post-operatively at 1 month and 6-month follow-ups.

Statistical analysis used: paired t test.

Results: The Mean age of patients was 46.9 years , with 12 cases (60%) were males and most common pathology was spinal instability arising from prolapsed intervertebral disc (PIVD) 65%. The preoperative mean VAS score was 7.9±0.85 which improved to 2.2±0.79 at final follow-up which is statistically significant improvement ($p<0.0001$). The preoperative mean ODI score was 64±8.1 which improved to 27.5±5.9 at final follow-up. The improvement in mean ODI score was statistically significant with p value of < 0.001).

Conclusion: The present study demonstrates that TLIF is safe and effective procedures for management of degenerative spine diseases with clinical improvement in pain and disability.

Keywords: Lumbar degenerative disease, Degenerative disc disease, oswestry disability index, transforaminal lumbar interbody fusion, spinal fusion.

Introduction

Low Back Pain (LBP) is one of the most important reasons for seeking medical treatment with a prevalence ranging from 59% to 84% [1]. Lumbar degenerative diseases, such as lumbar spinal stenosis, lumber disc herniation, lumbar degenerative instability, degenerative spondylolisthesis, etc are common aetiologies of Lower Back Pain and can have a significant influence on quality of life [2]. Degenerative disc disease (DDD) encompasses disc herniation, spinal stenosis and degenerative spondylolisthesis, among other changes. DDD becomes a source of chronic pain. Over 90 % of spine surgeries are performed because of Degenerative Disc Diseases (DDD) [3].

Spinal fusion surgeries are commonly used to treat Lumbar degenerative diseases which includes disc herniation with instability, spinal stenosis, and degenerative spondylolisthesis. Surgery provides sufficient neural decompression and stabilization through interbody fusion for pain relief [4].

Transforaminal lumbar interbody fusion (TLIF) was popularised by Harms and Jeszensky as an alternative to posterior lumbar interbody fusion (PLIF) [5]. TLIF offers several advantages including a decreased retraction of dural sac that lessens the risk of post-operative radiculopathy. The major difference in the TLIF from conventional approach is the operation is performed unilaterally and the bone graft is inserted into disc space through one side [6].

Conventional PLIF and TLIF surgeries have got disadvantages which includes large midline incision is required, extensive muscle and aponeurosis detachment, resulting in significant iatrogenic soft tissue damage, lengthy procedures, which may results in atrophy and ischemic necrosis of paraspinal musculature and resultant prolonged back pain [7].

Our study is to assess the functional outcome of single level open TLIF performed at our centre in terms pain relief using Visual Analogue Scale (VAS) [8] for pain for back and leg and quality of life using Oswestry Disability Index (ODI) [9] pre-operatively and post-operatively.

Aim

To assess the outcome of open transforaminal lumbar interbody fusion (TLIF) performed in degenerative lumbar spine diseases having chronic low back pain.

Material and Methods

This study is a prospective interventional study conducted at Gandhi medical college and associated Hamidia hospital, between January 2020 to September 2021, included 20 cases of degenerative lumbar spine diseases having chronic low back pain.

Inclusion Criteria

1. Patients with disabling lower back pain with or without radiculopathy for ≥ 6 months
2. Pain not relieved by the conservative line of management
3. Age ≥ 18 years.

Exclusion Criteria

1. Patient's with extensive epidural scarring, arachnoiditis, active infections, osteoporotic patients and comorbidities.
2. Age < 18 years

Pre-Operative assessment and Rehabilitation

Radiological evaluation with Standard anterior-posterior (AP) and lateral radiographs were taken. An informed consent then was taken to include the patient for the study. Any sensory, motor, or/and autonomic function below the lesion was evaluated. Magnetic resonance imaging (MRI) was obtained to assess the involved part of spine.

All patients were investigated as soon as possible thoroughly for evaluation and obtaining fitness for anaesthesia and surgery. Rehabilitation was started pre-operatively unless contraindicated by other associated injuries. Patient was given appropriate nursing care, active and passive physiotherapy, centripetal massage, bowel care, skin care, air/water mattresses (in patients with sensory loss), chest physiotherapy and psychological support. Pre-operatively prophylactic antibiotics including a cephalosporin and an aminoglycoside were given. All patients were operated under general anaesthesia using posterior midline approach and TLIF was done.

Postoperative care and Rehabilitation

Postoperatively the patient was mobilized on the first postoperative day with a thoraco-lumbar spinal orthosis (Taylor's brace) unless other injuries preclude this. X-rays were done to verify screw position and rod and cage placement. The orthosis is continued for 8 to 12 weeks, depending on resolution of pain and evidence of fusion and maintenance of spinal alignment.

Follow Up

Patients were called for follow up at completion of 1 month and 6 months from Surgery. During follow up visits clinical outcomes measured using VAS Score and ODI score and check X-rays were done to assess the pedicle screws placement and fusion of lumbar vertebrae. Patients gaining useful muscle power were provided orthosis for mobilisation.

Figure 1

Preoperative and postoperative x-ray: 1 month and 6 month

Statistical Analysis

Statistical analysis was done using SPSS Version 22,(Chicago Inc., USA). Paired t-test was used to find the significance between various variables. The observed results were determined to be significant if the P value was <0.05 and not significant if it was >0.05.

Observations and Results

In the present study 20 cases of Chronic lower back pain with degenerative spine diseases were managed by surgical fusion of lumber vertebrae using trans-foraminal lumbar interbody fusion (TLIF) between June 2019 and July 2021 and followed up for 6 months.

The Mean age of patients was 46.9 years with range 23-64 years. Out of 20 patients, 12 cases (60%) were males and 8 cases (40%) were females. Most common pathology was spinal instability arising from prolapsed intervertebral disc (PIVD) 65%, spondylolisthesis 30 % and only 5 % with spinal canal stenosis . Majority of the patients (50%) had lesion at L4-L5 region followed by L5-S1 (20%) . 10 percent of the patients have two level involvement.

The pre-operative VAS score of each patient are compared with postoperative and follow up values. In our study the improvement in mean VAS score is statistically significant (p value less than 0.001). (figure 1)

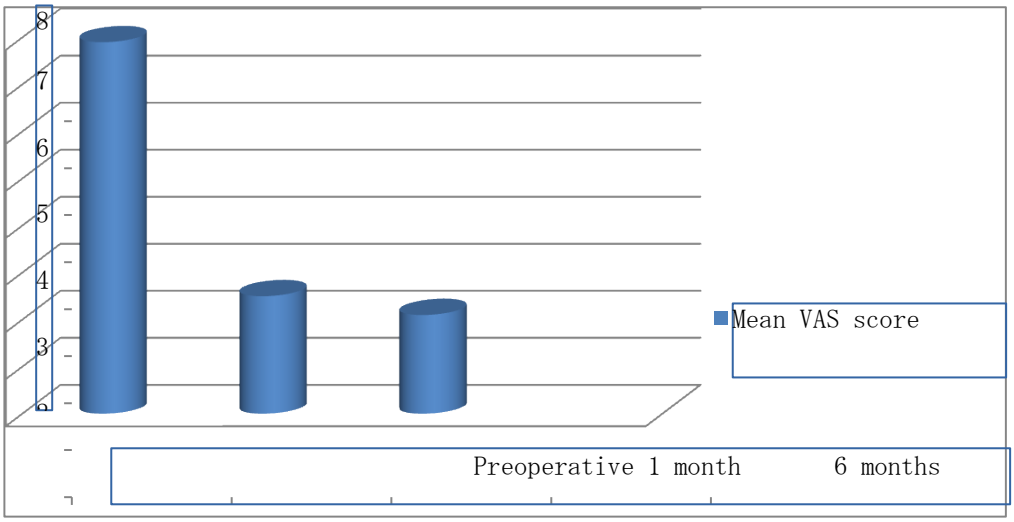

Figure 1: Mean VAS score.

2) Distribution according to change in ODI score:

P Value for above preoperative and postoperative follow-up is less than 0.001, which is statistically significant. All patients have reported some degree of fusion at 6 months follow up. One patient reported surgical site infection and one patient reported chronic back pain.

Table 1: Distribution according to change in mean VAS score

	Preoperatively	One Month	Six Months
Mean VAS Score	7.9±0.85	2.8±1.24	2.2±0.79

Table 2: Distribution of change in mean ODI score

	Preoperative	One Month	Six Months
Mean ODI Score	64±8.1	37.2±6.0	27.5±5.9

Table 3: Improvement in mean VAS score in different studies

Name of study	PREOP MEAN ±SD	Last follow-up MEAN ±SD
Wang et al. (2010) [10]	5.8±0.9	1±0.9
Zhang et al. (2014) [6]	6.97±2.49	4.55±3.81
Yee et al. (2015) [12]	6.3±2.5	1.3±0.6
Kulkarni et al. (2016) [13]	6.3±2.9	2.3v3.0
Adogwa et al. (2017) [11]	8.4±1.7	5.5±2.6
Present study	7.9±0.85	2.25±0.79

Table 4: Distribution of mean ODI score among different studies

Study	Preop mean	Final follow-up mean
Wang et al. (2010) [10]	49±15.21	34.27±22.7
Zhang et al. (2014) [6]	57.8±23.54	26.4±25.45
Yee et al. (2015) [12]	44.4±18	20.7±16.5
Kulkarni et al. (2016) [13]	36.9±6.3	15.7±8.9
Adogwa et al. (20170 [11]	41.2±6.6	10.8±3.3
Present study	64.3±8.1	27.5±5.94

Table 5: Complication rates among different studies

Study	Complications rates
Zhang et al. (2014) [6]	11/78
Yee et al. (2014) [12]	0/15
Adogwa et al. (2017) [11]	12/108
Present study	2/20

Discussion

In our study mean age was 46.9 years, with 60% males which corresponds to the earlier studies. Labour work and vigorous activities could have predisposed them to degenerative spinal pathologies in younger age group. In most of previous studies done in various regions of the world Degenerative Disc Diseases were found to be the most common cause for spinal fusion procedures.

In our study and Zhang *et al* [6] degenerative disc diseases (65%) was found to be the most common cause. Studies by Adogwa *et al* [10,11] and Yee et at [12] depicts the higher incidence of spondylolisthesis followed by degenerative disc disease . This type of distribution can be attributed to occupational hazards which are still a problem in our region.

(1) Distribution according to change in VAS score

In our study the improvement in mean VAS score is statistically significant (P value < 0.0001).

Improvement in mean VAS score in our study is consistent with previous studies. We should also aim for better results as our experience, techniques and skill in surgery improves with time, follow strict protocols for rehabilitation with trained staff and longer follow-up duration. [4] Distribution according to change in Oswestry Disability index.

Improvement in mean ODI score in our study have been highly consistent with most of the previous studies. In our study the improvement in mean VAS score is statistically significant (P value < 0.0001).

Improved results can be achieved with gain in experience, techniques, skills, following strict protocols for rehabilitation with trained staff and longer follow-up duration

(5) Distribution according to complication

Complications rates in our study was 10 % which is comparable with study by Adogwa *et al* (2017) [11] 10.1 % and Zhang *et al* (2014) [6] 14.1 % and Study by Yee *et al* (2015) [12-14] reported no complications .

Deep wound infection was present in only one case, which was managed by Intravenous antibiotics and debridement. Chronic backache was seen in one patient only which responded to analgesics and physiotherapy. Due to short term follow up of 6 months. No other complications like loosening and failure of implant was not noticed in any case in our study.

Conclusion

From our study, we have found that open transforaminal lumbar interbody fusion (TLIF) performed in degenerative lumbar spine diseases having chronic low back pain produce satisfactory results in terms of functional improvement on ODI score and pain relief on VAS score. Our results are in accordance with literature on TLIF in degenerative lumbar spine diseases. However, However, more comparative studies are needed to assess the benefits of TLIF over PLIF. Larger sample size and longer follow up duration studies are required to assess long term functional improvement and long-term complications.

References

1. Resnick DK, Choudhri TF, Dailey AT, *et al*. Guidelines for the performance of fusion procedures for degenerative disease of the lumbar spine. Part 7:

intractable low-back pain without stenosis or spondylolisthesis. J Neurosurg Spine. 2005; 2:670-2.
2. Eck JC, Hodges S, Humphreys SC. Minimally invasive lumbar spinal fusion. J Am Acad Orthop Surg. 2007; 15:321-9.
3. Briggs H, Milligan PR. Chip fusion of the low back following exploration of the spinal canal. J Bone Joint Surg Am. 1944; 26:125-30.
4. Hibbs R.A. An operation for progressive spinal deformities. A preliminary report of three cases from the service of the Orthopaedic Hospital. NY Med J. 1911; 93:1013–1016.
5. Harms J., Rolinger H. A one-stager procedure in operative treatment of spondylolistheses: dorsal traction-reposition and anterior fusion. Z Orthop Ihre Grenzgeb. 1982; 120(3): 343–347.
6. Zhang Q, Yuan Z, Zhou M, *et al*. A comparison of posterior lumbar interbody fusion and transforaminal lumbar interbody fusion: a literature review and meta-analysis. BMC Musculoskelet Disord. 2014; 15:367.
7. Hsieh PC, Koski TR, O'Shaughnessy BA, *et al*. Anterior lumbar interbody fusion in comparison with transforaminal lumbar interbody fusion: implications for the restoration of foraminal height, local disc angle, lumbar lordosis, and sagittal balance. J Neurosurg Spine. 2007; 7:379-86.
8. Bird SB, Dickson EW. Clinically significant changes in pain along the visual analog scale. Ann Emerg Med. 2001; 38:639–643.
9. Fairbank JC, Pynsent PB.The Oswestry Disability Index. Spine. 2000; 25:2940– 2953.
10. Wang J., Zhou Y., Zhang Z.F., Li C.Q., Zheng W.J., Liu J. Comparison of one-level minimally invasive and open transforaminal lumbar interbody fusion in degenerative and isthmic spondylolisthesis grades 1 and 2. Eur Spine J. 2010;19(10):1780–1784.
11. Adogwa, Owoicho MPH; Parker, Scott L. MD; Shau, David BS; Mendelhall, Stephen K. BS; Aaronson, Oran MD; Cheng, Joseph MD; Devin, Clinton J. MD; McGirt, Matthew J. MD Cost Per Quality-adjusted Life Year Gained of Revision Fusion for Lumbar Pseudoarthrosis, Journal of Spinal Disorders and Techniques. April 2015; 28(3): 101-105.
12. Timothy J. Yee, Darryl Lau, Adam A. Khan, Frank La Marca, and Paul Park. Minimally invasive versus open transforaminal lumbar interbody fusion: comparison of clinical outcomes among obese patients. Journal of Neurosurgery: Spine. 2015.
13. Kulkarni, A.G., Bohra, H., Dhruv, A. *et al*. Minimal invasive transforaminal lumbar interbody fusion versus open transforaminal lumbar interbody fusion. IJOO. 2016; 50: 464–472.
14. Kelly JP, Alcala-Marquez C, Dawson JM, Mehbod AA, Pinto MR. Treatment of degenerative spondylolisthesis by instrumented posterolateral versus instrumented posterolateral with transforaminal lumbar interbody single-level fusion. Journal of Spine Surgery. 2019;5(3):351.