e-ISSN: 0975-1556, p-ISSN:2820-2643

Available online on www.ijpcr.com

International Journal of Pharmaceutical and Clinical Research 2022; 14(8); 605-609

Original Research Article

Retrospective Study of Histopathological Spectrum of Ovarian Sex Cord Stromal Tumours at Tertiary Care Hospital – A Three Year Study

Aditi Sanjay Sakarkar[1], Mukund Shivaji Unde[1]

[1]Dr Vithalrao Vikhe Patil Medical College, Ahmednagar

Received: 16-06-2022 / Revised: 20-07-2022 / Accepted: 10-08-2022
Corresponding author: Dr Aditi Sanjay Sakarkar
Conflict of interest: Nil

Abstract

Background: Sex cord-stromal tumours of the ovary are rare tumours as compared to epithelial tumours of the ovary showing variable histological and biological patterns. Adolescence and young adults are the two age groups in which these tumours are frequently found except for adult granulosa cell tumour which is typically found to develop later i.e. at the age of 50 to 55 years.

Objectives: This study has been done to find out the frequencies of various subtypes of these tumours and their histopathological spectrum.

Methods: It is the retrospective observational type of study conducted over three years from June 2019 to May 2022. 20 cases of sex cord-stromal tumours of the ovary which were received in the histopathology section of our department are taken and their various histopathological features have been studied. Also, the frequency of occurrence of their various morphological subtypes has been estimated.

Results: A total of 40 cases of sex cord-stromal tumours of the ovary received in our department were studied. Among different subtypes, the most common tumour was granulosa cell tumour (10) i.e. 25 % out of which one was showing bilaterality. Frequencies of other tumours were – Fibroma (8) i.e. 20% , Fibrothecoma (8) i.e. 20% , Thecoma (6) i.e. 15% , Sertoli cell tumour (4) i.e. 10% Steroid (lipid) cell tumour (2) i.e. 5 %, Sclerosing stromal tumour (2) i.e. 5%.

Conclusion: According to this study, sex cord-stromal tumours of the ovary is a rare entity showing diverse histological features. Among them, granulosa cell tumours and fibromas were the most frequently occurring sex cord-stromal tumours of the ovary in favour of previously done studies.

Keywords: Granulosa cell tumour, Sertoli cell tumour, lipid cell tumour.

Introduction

Sex-cord stromal tumours (SCST) are a subtype of ovarian neoplasms that are relatively infrequent. These account for only about 7% of all primary ovarian tumours. The sex cord-stromal tumours are most of the time low grade and present generally in younger patients than ovarian epithelial malignancies [1]. They encompass a heterogeneous group of neoplasms containing a variety of cells which are derived from gonadal sex cords or stromal cells [2]. Because of the smaller size, lower

grade of malignancy and rarity of these tumours, they are often diagnosed by pathology following surgery [3].

Sex cord-stromal tumours of the ovary are rare tumours as compared to epithelial tumours of the ovary showing variable histological and biological patterns. Adolescents and young adults are the two age groups in which these tumours are frequently found except for adult granulosa cell tumour which is typically found to develop later i.e. at the age of 50 to 55 years.

These tumours are commonly present with a wide range of hormone-mediated syndromes varying from hyperandrogenic virilizing symptoms to hyperoestrogenic symptoms [4,9].

We performed a retrospective study of the histopathological spectrum of ovarian sex cord-stromal tumours at a tertiary care hospital.

Aims and Objectives

This study has been done to find out the frequencies of various subtypes of these tumours and their histopathological spectrum.

Material and Methods

It is a retrospective observational type of study conducted over three years from June 2019 to May 2022. 40 cases of sex cord-stromal tumours of the ovary which were received in the histopathology section of our department are taken and their various histopathological features have been studied. Also, the frequency of occurrence of their various morphological subtypes has been estimated.

We performed a retrospective analysis of all patients diagnosed with ovarian sex cord-stromal tumours over three years from June 2019 to May 2022, whose specimens were received at the Histopathology section, Department of Pathology, Vikhe Patil medical college. As this was an observational study and confidentiality was thoroughly maintained, the ethical review committee's approval was not required, which is mandatory in experimental research according to Helniski's declaration.

A total of 40 cases of sex cord-stromal tumours of the ovary which were received in the histopathology section of our department are taken and their various histopathological features have been studied. Also, the frequency of occurrence of their various morphological subtypes has been estimated.

Results

Table 1: Type of tumour

Type of tumour	Frequency	Percent
granulosa cell tumour	10	25
Fibroma	8	20
Fibrothecoma	8	20
Thecoma	6	15
Sertoli cell tumour	4	10
Steroid (lipid) cell tumour	2	5
Sclerosing stromal tumour	2	5
Total	40	100

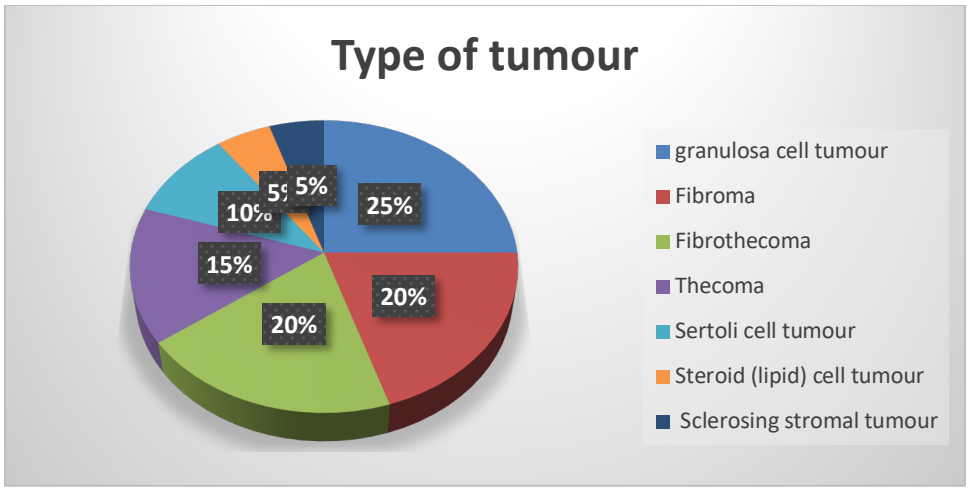

Figure 1: Type of tumour

A total of 40 cases of sex cord-stromal tumours of the ovary received in our department were studied. Among different subtypes, the most common tumour was granulosa cell tumour (5) i.e. 25 % out of which one was showing bilaterality.

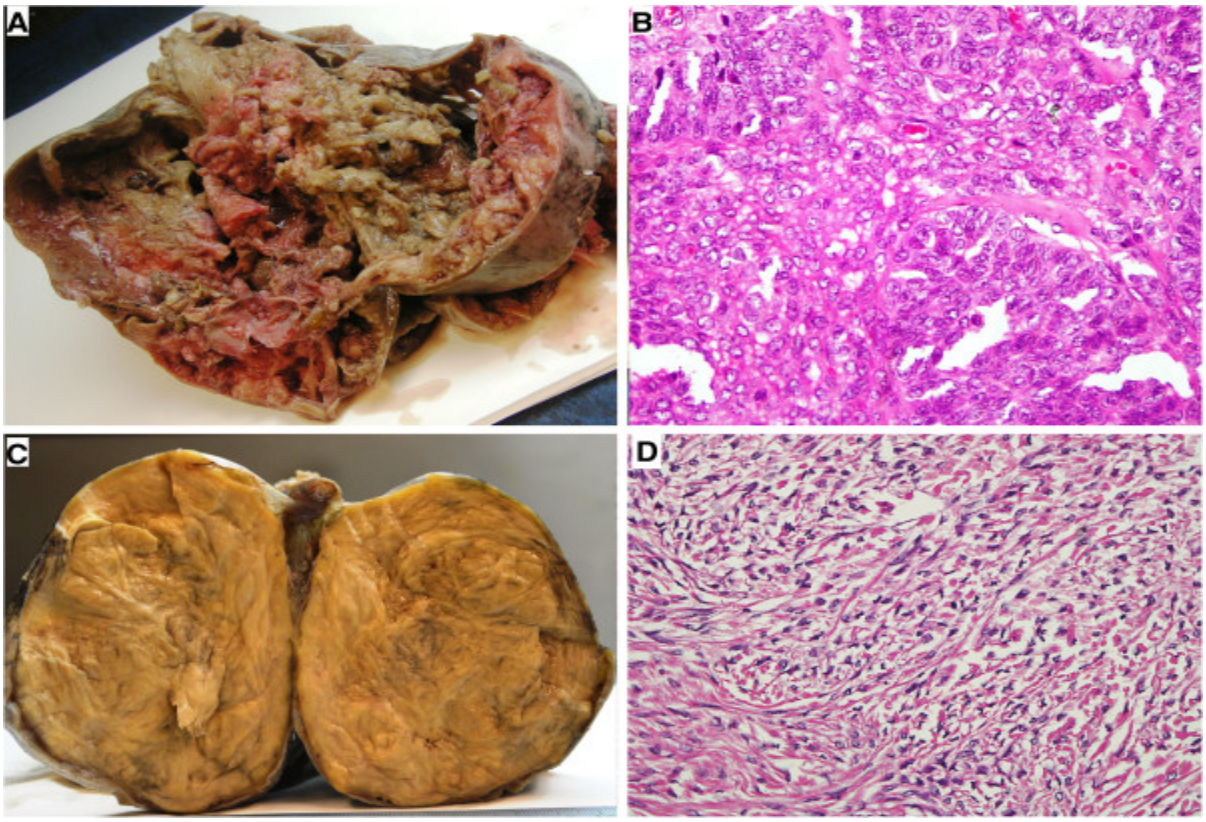

Figure 2: Gross and microscopic features of the two most frequent SCSTs; Adult granulosa cell tumour and Fibroma. A) Gross appearance of Adult granulosa cell tumour. **B)** Microscopic picture shows coffee bean nuclei of the tumour cells present in form of sheets. (Hematoxylin and Eosin, 40×). **C)** Gross picture of Fibroma. **D)** Microscopy shows bland nuclei with scant cytoplasm. (Hematoxylin and Eosin, 40×).

Frequencies of other tumours were – Fibroma (8) i.e. 20%, Fibrothecoma (8) i.e. 20%, Thecoma (6) i.e. 15%, Sertoli cell tumour (4) i.e. 10% Steroid (lipid) cell tumour (2) i.e. 5 %, Sclerosing stromal tumour (2) i.e. 5%.

Fibromas

Total 8 cases had fibromas. The gross appearance of fibromas showed whorled tan white areas

Fibrothecoma

Two cases were bilateral.

Thecoma

Out of 6 cases, one case behaved in an aggressive fashion extending into the urinary bladder.

Discussion

Among different subtypes, the most common tumour was granulosa cell tumour (10) i.e. 25 % out of which one was showing bilaterality. Frequencies of other tumours were – Fibroma (8) i.e. 20%, Fibrothecoma (8) i.e. 20% , Thecoma (6) i.e. 15% , Sertoli cell tumour (4) i.e. 10% Steroid (lipid) cell tumour (2) i.e. 5 %, Sclerosing stromal tumour (2) i.e. 5%. In the study conducted by Ranjana Hawaldar *et al*., sex cord-stromal tumours constituted 5.9% of all ovarian tumours out of which granulose cell tumour was more common (3.4%) followed by fibroma(2.5%). Nirali Thakkar *et al* reported 1.5% granulose cell tumours and 3.1% fibroma in their study. (16) Two cases of Sertoli Leydig cell tumour were reported in their study.

Most of the ovarian sex cord-stromal tumours, in which information regarding the FIGO stage was available, presented at Stage I. FIGO staging is the most important, globally accepted, prognostic factor. Most fibromas and thecomas presented at stage I, in all cases except one in which tumour infiltrated the urinary bladder wall, and only in this case, moderate atypia.

The most common specimen received was unilateral oophorectomy, relating to the clinically and radiologically benign nature of most of the tumours. Predominantly only in granulosa cell tumours and Sertoli Leydig cell tumours among our study population, surgical staging procedures were done.

The morphology of these tumours varies and these can simulate epithelial ovarian neoplasms or mesenchymal tumours histologically to an extent of misdiagnosis [4]. Immunohistochemical staining may be useful for establishing the diagnosis in problematic cases due to its varied appearance and rarity [3,5].

The most important immunohistochemical aspect is negative staining of these tumours for their epithelial membrane antigen as well as positive staining 3 for inhibin and calretinin [6].

As per previously done studies, lymph node metastasis is seen to be rarely associated with these tumours [7,8].

Due to a less aggressive growth pattern, sex cord-stromal tumours diagnosed in an early stage have more survival rates and a good prognosis as compared to other ovarian malignancies [9,10].

Conclusion

According to this study, sex cord-stromal tumours of the ovary are rare entities showing diverse histological features. Among them, granulosa cell tumours and fibromas were the most frequently occurring sex cord-stromal tumours of the ovary in favour of previously done studies.

References

1. Koonings PP, Campbell K, Mishell DR Jr, Grimes DA. Relative frequency of primary ovarian neoplasms: a 10-year

review. Obstet Gynecol. 1989;74(6):921–926.
2. Shim SH, Kim DY, Lee SW, Park JY, Kim JH, Kim YM, Kim YT, Nam JH. Laparoscopic management of early-stage malignant nonepithelial ovarian tumors: surgical and survival outcomes. Int J Gynecol Cancer. 2013;23(2):249–255.
3. Aboud EA. A review of granulosa cell tumours and thecomas of the ovary. Arch Gynecol Obstet. 1997;259(4):161–165.
4. Rosai J. In: Rosai and Ackerman's surgical pathology. Rosai J, editor. Philadelphia7: Elsevier, Mosby; 2004. Ovary; pp. 1649–1650.
5. Nucci MR, Oliva E. In Sex cord-stromal tumors of the ovary. Deaver MT, Oliva E, Nucci MR, editor. Churchill Livingstone: Elsevier Churchill Livingstone; 2009. Gynecologic Pathology; pp. 457–460
6. Young RH. Sex cord-stromal tumors of the ovary and testis: their similarities and differences with consideration of selected problems. Modern Pathology. 2005 Feb;18(2): S81-98.
7. Thrall MM, Paley P, Pizer E, Garcia R, Goff BA. Patterns of spread and recurrence of sex cord-stromal tumors of the ovary. Gynecologic oncology. 2011 Aug 1;122(2):242-5.
8. Zhang M, Cheung MK, Shin JY, Kapp DS, Husain A, Teng NN, Berek JS, Osann K, Chan JK. Prognostic factors are responsible for survival in sex cord-stromal tumors of the ovary—an analysis of 376 women. Gynecologic oncology. 2007 Feb 1;104(2):396-400.
9. Horta M, Cunha TM. Sex cord-stromal tumors of the ovary: a comprehensive review and update for radiologists. Diagnostic and Interventional Radiology. 2015 Jul;21(4):277.
10. Wang J, Li J, Chen R, Lu X. Contribution of lymph node staging method and prognostic factors in malignant ovarian sex cord-stromal tumors: a worldwide database analysis. European Journal of Surgical Oncology. 2018 Jul 1;44(7):1054-61.