e-ISSN: 0975-1556, p-ISSN:2820-2643

Available online on www.ijpcr.com

International Journal of Pharmaceutical and Clinical Research 2022; 14(9); 1037-1044

Original Research Article

A Study on Outcome Analysis of Segmental Fractures of Tibia

Srimukhthi Madhusudan[1], Vishwanath M[2], Endoori Babu Rao[3]

[1]Assistant Professor, Department of Orthopaedics, Government Medical College Siddipet,

[2]Assistant Professor, Department of Orthopaedics, Mamata Academy of Medical Sciences, Bachupally,

[3]Assistant Professor Department of Orthopaedics, Government Medical College Nizamabad, Telangana State.

Received: 25-07-2022 / Revised: 25-08-2022 / Accepted: 30-09-2022

Corresponding author: Dr. Endoori Babu Rao

Conflict of interest: Nil

Abstract:

Background: Segmental fracture of the tibia is a rare injury. Segmental tibia fracture is considered as separate clinical entity compared to the normal tibia fractures for different reasons. The aim towards treatment for the segmental fracture tibia is union maintaining normal length, normal alignment without rotational deformity, normal joint movements and reduced hospital stay.

Aim and Objectives: To evaluate the functional and radiological outcome following open/closed reamed interlocking intramedullary nailing for segmental fractures of the tibia.

Materials and Method: A prospective and retrospective study was conducted in the Department of Orthopaedics, Mamata Academy of Medical Sciences, Bachupally, for the duration of one year, in which 30 patients were included in the study after following inclusion and exclusion criteria given bellow, getting informed consent form the patients and ethical approval from institutional ethical committee.

Results: Majority of the cases union time lies between 19 to 28 weeks. The proximal segment unites faster than the distal segment. The final outcome based on JOHNER AND WRUCH'S criteria were excellent in 19 cases good in 6 cases. Postoperative complications were observed among 26 cases.

Conclusion: Injuries caused by high energy trauma involving extensive soft tissue damage, so the proper clinical assessment of soft tissue and timing of the surgery is important. Patient counselling regarding the complex nature of injury and the possible requirement of secondary procedures should be anticipated and addressed.

Keywords: JOHNER AND WRUCH'S criteria, Segmental fracture, Tibia Fractures

Introduction

Segmental fracture of the tibia is a rare injury. This fracture type usually follows high-energy trauma and is often associated with a significant soft tissue injury. [1] Segmental tibia fractures is defined as a unique fracture type characterized by least two different fracture lines with a completely isolated intercalary osseous fragment. Segmental fractures of tibia are uncommon and are usually caused by a high-energy trauma. They have a high complication rate. Rising incidence of

high velocity trauma due to motor vehicle accidents usually results in fractures of long bones. Incidence is about 12-15% of all tibia fractures. The tibia is the most commonly fractured long bone in the body.

Modes of injury commonly are road traffic accidents, falls from height, industrial and train accidents. Almost 37.5 % to 83.8 % of these fractures are open and they often sustain injury to the others parts of body. Since it is caused by high energy trauma there is severe soft tissue injury and periosteal stripping due to which the central fragment is devoid of blood supply. Segmental tibia fracture is considered as separate clinical entity compared to the normal tibia fractures for the following reasons like, they are almost always caused by high-energy injuries, approximately 50% are compound, they are often part of multiple injuries, they are frequently associated with sever soft tissue injuries, they have high complication rates, also their prognosis is often poor. The aim towards treatment for the segmental fracture tibia is union maintaining normal length, normal alignment without rotational deformity, normal joint movements and reduced hospital stay. Current treatment options are locked intramedullary nailing, external fixators, plate osteosyntheses and plaster of Paris cast immobilization. The present study has been taken evaluate the functional and radiological outcome following open/closed reamed interlocking intramedullary nailing for segmental fractures of tibia

Materials and Method

A prospective and retrospective study conducted in the Department of Orthopaedics, Mamata Academy of Medical Sciences, Bachupally, for the duration of one year, in which 30 patients were included in the study after following inclusion and exclusion criteria given bellow, getting informed consent form the patients and ethical approval from institutional ethical committee.

Inclusion Criteria

- All segmental tibia fracture.
- Age >18 years and <65 years

Exclusion Criteria

- Associated vascular injury
- Associated neurological injury
- Pathological fracture
- Severe systemic illness like active cancer elsewhere in body, chemotherapy, insulin dependent diabetes mellitus, renal failure and other medical contraindication for surgery

Methodology

All patients were subjected to a detailed history and clinical examination. Clinical examination was performed including general, systemic, neurovascular and local examination of injured part. Depending on nature of injury relevant radiological examination was done. If clinical examination indicates diminished distal pulses, further workup for vascular consultation was done. Anteroposterior and lateral radiograph of knee with leg with ankle were done to diagnose fracture type. Routine preoperative investigation was followed. Open fractures were immediately irrigated, washed and temporarily immobilized with posterior POP above knee slab. Plastic surgeon opinion was obtained for grade 2 and grade 3 compound cases. Patients were operated within 3 weeks of hospital admission.

Pre-operative Planning

X ray of the injured leg in AP & Lateral views taken. Fracture angulation is noted in all planes and reduction method was planned. Tibia and fibula fracture location from the proximal and distal articular surface was noted. If the fracture is within proximal 1/3 of tibia then lateral and high entry point was planned. If it was in the diaphysis of tibia then central entry point

was planned. If there is fibula fracture within 8 cm from distal articular surface is noted then planned for fixation.

Approximate length of the nail was measured in the contralateral leg from the tibial tuberosity to most prominent point of medial malleolus. The diameters of medullary canal at is thumus was measured.

Operative Protocol

The nails used were cannulated stainless steel nail, with 2 proximal (mediolateral) and 3 distal (2 mediolateral and 1 anteroposterior) locking options, of diameter 8, 9 or 10 mm. Then through a patellar tendon splitting approach, entry point made as planned previously Progressive reaming done in proximal fragment and guide wire was passed under image intensifier control, reduction verified, if not satisfactory then fracture site opened tibia reduced then serial reaming has been done while the intermediate fragment is controlled with reduction clamp or unicortical schanz pin or drill bit depending upon the availability in our theatre in all cases. Intramedullary nail introduced and locked with two proximal screws and two or three distal screws (if distal fragment was within 4 -5 cm). Closed reduction was done in 19 cases. In the remaining 11 cases, closed reduction was attempted and we had to do open reduction as there was a marked overriding of the fragments or delay in taking up the case due to some reasons. Achieving the alignment was confirmed in both coronal and sagittal plane with image intensifier. For one cases supplementary fibular plating, through posterolateral incision has been done. Skin, subcutaneous tissue and fascia incised. The peroneal muscles are retracted anteriorly. The interosseous membrane is stripped from the anterior border of the fibula from proximal to distal direction. Fibular fracture site exposed, freshened and reduced. After achieving the proper alignment and reduction, fibular plating done with appropriate one third tubular plate (seven holed plate) and cortical and cancellous screws of different sizes. Once proper length and rotation of fibula is achieved, in fresh cases the tibia aligns itself and malalignment in both sagittal and coronal planes could be avoided. In those delayed cases where alignment of fibula does not result delayed in alignment of tibia, Open reduction and internal fixation with intramedullary nail is done. In our case it was a two weeks old so reduction was not achieved with fibula plating but we could able to negotiate the guide wire through the segment and reaming was done by controlling the intermediate fragment with reduction clamp. Tourniquet was not used in any cases. All cases were done under spinal anesthesia.

Statistical Analysis

Collected data were entered in the Microsoft excel 2016 for further statistical analysis. Quantitative data were expressed in terms of mean and standard deviation and qualitative data were expressed in terms of frequency and proportion. Mean difference between the variable was assessed with the help of parametric t-test. P-value<0.05 was considered as statistically significant at 5% level of significance.

Results

Thirty patients were admitted in our Department of Orthopaedics with segmental tibia fractures during the described period prospectively and retrospectively with either open or closed segmental tibia fractures with compromised soft tissue and treated with interlocking nail. Demographic profile of the patients were shown in the table 1,

Table 1: Distribution of demographic profile of study population.

Variable	Frequency	Percentage
Gender		
Female	6	20
Male	24	80
Side Affected		
20 - 30 Years	4	13.3
31 - 40 Years	6	20.0
41 - 50 Years	11	36.7
> 50 Years	9	30.0
Side Affected		
Right	22	73.3
Left	8	26.7
Mode of Injury		
2 X 4 Wheeler	9	30
Pedestrian X 2 Wheeler	11	36.7
2 X 2 Wheeler	9	30
Self	1	3.3

Demographic profile showed that there were more number of male were admitted due to the segmental tibia fractures compared to the female. 66.7% of the patients were form age group of more than 40 years of age. Most affected side was right side and among 36.7% of the patients mode of injury was pedestrian and 2 wheeler RTA, followed by 30% each by 2X4 wheeler and 2X2 wheeler respectively. Only there was one case of self-accident was observed in our study.

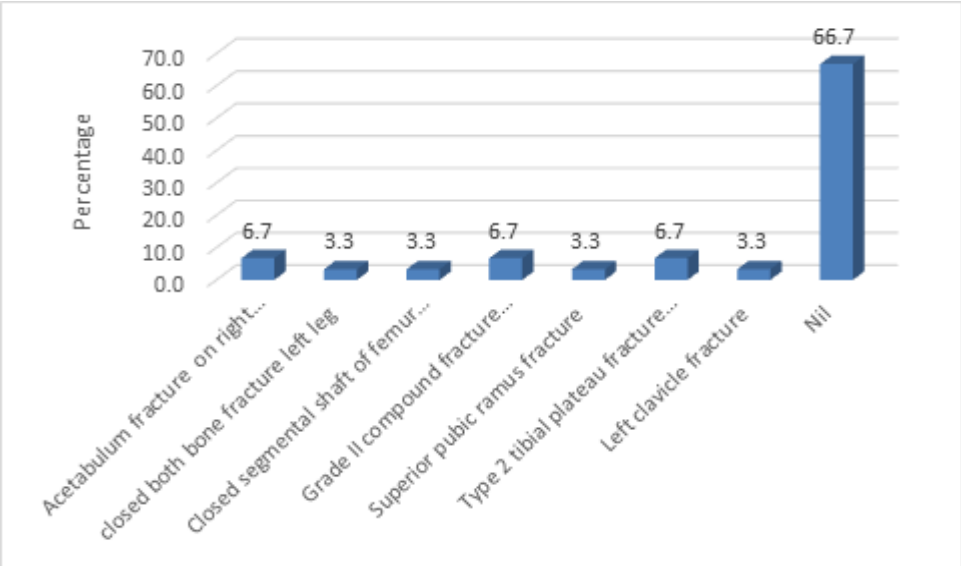

Figure 1: Distribution of associated Injury in the study population.

Table 2: Distribution of Fibula fracture in the study population.

No of fracture line	No of patients	percent
single facture	20	66.70%
segmental fracture	6	20%
double segmental fracture	1	3.30%
No fracture	3	10%
Total	30	100%

Table 3: Distribution of Diagnosis.

Diagnosis	No of patients	Percent
Closed segmental both bone fracture	12	40
Compound segmental both bone fracture	18	60
Total	30	100

Table 4: Distribution of mean difference in segment length in different diagnosis

Parameter		N	Mean	Std. Deviation	t value	p value
segment length in cms	Closed	19	8.89	2.46	3.29	0.0027
	Open	11	5.63	2.87		

Table 5: Distribution of Treatment done

Treatment done	No of patients	Percent
Closed interlocking nailing	19	63.3
Open interlocking nailing	11	36.7
Total	30	100

Table 6: Mean Distribution of Fracture Union in Weeks

Treatment done group		N	Mean	Std. Deviation	t value	p value
Proximal fracture union in weeks	Closed	20	19.3	4.1	2.09	0.045
	Open	9	23.1	5.4		
Distal fracture union in weeks	Closed	18	21.12	2.12	6.86	0.0001
	Open	7	28.36	2.96		

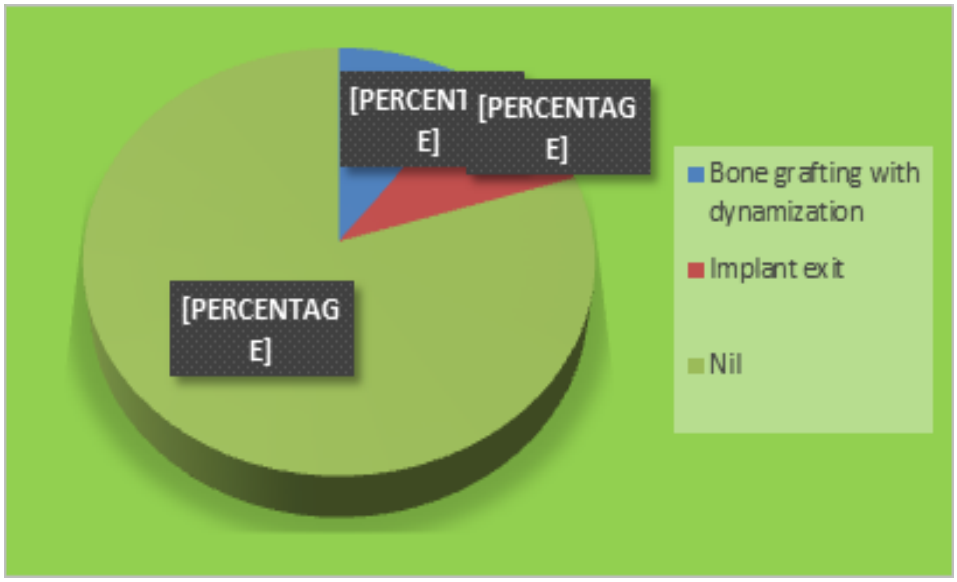

Figure 2: Distribution of Secondary procedure

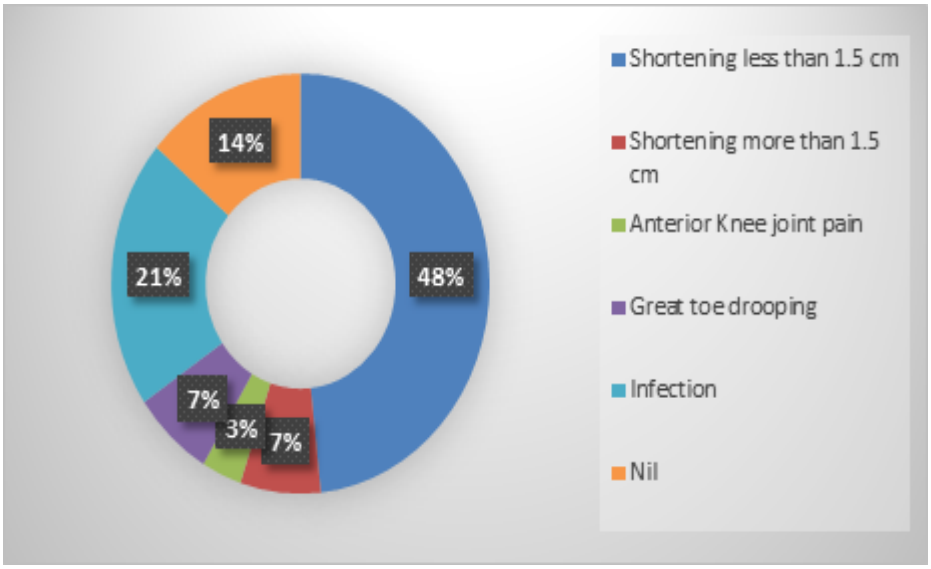

Figure 3: Distribution of Complication

Table 7: Distribution of Johner and Wruchs Criteria and Knee society Scoring

Criteria	No of patients	Percent
Johner and Wruchs criteria		
Excellent	19	63
Fair	4	13
Good	6	20
Poor	1	3
Knee Society Score		
Excellent	23	77
Fair	3	10
Good	3	10
Poor	1	3

Discussion:

Present study was conducted prospectively and retrospectively in in the Department of Orthopaedics, of our institute in which 30 patients were included to evaluate the functional and radiological outcome following open/closed reamed interlocking intramedullary nailing for segmental fractures of tibia. Study observed female predominance in the study for segmental features of tibia. Majority of affected patients were mainly form the age group of more than 40 years. Average age of the people affected was 43.12 and most of them were working personals from their families. Consistent with our study Dr. Vivek P Nikumbha et al[2] observed mean age of patients affected in their study was 40.6 years. In case of gender our study had more number of males compared to female which was consistent with study by Ramji Lal Sahu et al. [3] shows male female ratio was 4.8:1. A study done by Ching-Kuei Huang et al. [4] shows right leg was involved in 20 cases, left leg in 13 cases in the ratio of 2.5:1, these results are more consistent with our results, in our study also there were 22 cases in which right leg was involved.

Tibia fracture are the commonest among the major long bones fractures. The commonest cause of the fracture being road traffic accident which was in our study and also consistent with study by Dr. Vivek P Nikumbha et al [2]

In our study 18 (60%) patients had open injury which is due to subcutaneous location of entire length of tibia shin and high energy trauma and 12 (40%) patients

had closed injury. A study conducted by Ramji Lal Sahu et al. [3] shows that 44.5% of patients sustained compound injuries which is also consistent with our result.

In our study we used reamed interlocking nailing in all 30 patients. Closed nailing has been done for 19 (63.3%) patients and open nailing has been done for 11 (36.7%) patients. Most of the patients are followed up for 18 months. In present study, average union time of proximal fracture is 19.3 weeks in closed fracture and 23.1 weeks in compound fracture. Average distal fracture union time is 21.12 weeks for closed and 23 weeks for compound fractures with overall average union time of 22.4 weeks. In our series one case went for nonunion at the distal fracture site the which bone grafting was done and united. As consistent with other studies proximal fracture united faster than distal fracture and closed fractures united earlier than compound fracture. The distal fractures united later than proximal fracture site as a result of direct injury to the soft tissue overlying this fracture and natural tendency to slow union in fractures at this location. John Mcmurtry et al. [5] shows that the average union times range from 15 weeks to greater than 40 weeks with fractures demonstrating more delayed unions and nonunion in open injuries which is consistent with our result. Another study done by Terra et al. [6] median time to union was longer for segmental tibial fractures 34 weeks compared with non-segmental tibial fractures which is 24 weeks respectively.

It is also observed from our study that with the increase in length of intermediate fragments fracture union has a better chance, which is due to relatively better blood supply, control of intermediate fragment while reaming and the fractures in the metaphyseal region. It is also observed that compound fractures has smaller fragment than closed fracture due to the high force of injury.

Most common postoperative complication in our series was insignificant shortening of affected lower limb (46.7%). Infection was seen in 6 (20%) cases where open nailing has been done. One of them had a deep infection and other three had superficial infection. Intravenous antibiotics has been given and superficial infection has been controlled. Implant exit has been done after fracture union in deeply infected patient. Knee pain was seen in one patients. A study done by Dr. Vivek P Nikumbha et al. [2] shows superficial infection was found in 2 (5.8%) cases, deep infection in one case which is consistent with our study. Most common postoperative complication in their series was anterior knee pain in 5 (9.8%) cases. Bonnevialle et al.analyzed in his study and came out with nonunion for 4 (8%) patients in distal fracture site and 2 (4%) nonunion at proximal fracture site.

In our series 6 patients underwent secondary procedure. 3 patient underwent bone grafting for nonunion at the distal fracture site and another three patient went on for implant exit for infection control. Terra et al. [6] found a larger need for reoperation in segmental tibia fracture when compared to non-segmental tibia fracture which is related to increased occurrence of problems regarding bone healing and higher incidence of soft tissue complications.

In our study, we used Knee Society Scoring system for analyzing functional outcome of knee. It depends on variables like range of motion, stability and alignment, fixed flexion deformity. Results was 77% of the patients had excellent outcome, 10% of patients had good outcome, 10% for patients fair outcome and only 1(3%) patient had poor outcome which is consistent with study done by Prashant Patel et al [7] in which excellent outcome was seen in 73% of patients treated with interlocking nailing. Out of 30 cases in our series, 26 (86%) had acceptable Johner and Wruch's criteria for functional outcome. Excellent in 19 (63%), good in 6 (13%), fair in 4 (20%) and poor

in 1 (3%) which is consistent with a study done by Ekeland and Alho et al (8) reported excellent in 29 (64%), good in 13 (29%) and fair in 2 (4.5%) and poor in one out of 45 cases. [9]

Conclusion

From above observation and discussion we can conclude that, injuries in our study were caused by high energy trauma involving extensive soft tissue damage so the proper clinical assessment of soft tissue and timing of the surgery is important. Preservation of vascularity of intermediate segment and nontraumatic reduction of fracture fragments requires expert surgical skill. Experience regarding appropriate usage of polar screw and tibial entry point makes the surgical procedure easier with excellent functional outcome. Patient counselling regarding the complex nature of injury and the possible requirement of secondary procedures should be anticipated and addressed.

Acknowledgement : None

Funding : None

References

1. G.C. Melis *et al.* Intramedullary nailing in segmental tibial fractures J. Bone Joint Surg. Am. 1981.
2. Dr. Vivek P Nikumbha, Dr. G Krishna N Goud, Dr. Siddharth Baidya and Dr. Kuldeep Mishra. Prospective study of management of close or compound segmental fracture tibia by close reduction and internal fixation with interlocking nail. International Journal of Orthopaedics Sciences 2017; 3(2): 5 71-575.
3. Ramji Lal Sahu. Fracture Union with Closed Interlocking Nail in Segmental Tibial Shaft. J Crit Rev. 3(2):60-64.
4. Ching-Kuei Huang, Wei-Ming Chen, Tain-Hsiung Chen & Wai- Hee Lo. Segmental tibial fractures treated with interlocking nails: A retrospective study of 33 Cases. ISSN: 0001-6470.
5. John Mcmurtry, Varatharaj Mounasamy. Segmental Tibia Fractures. Mcmurtry J, Mounasamy V. Segmental Tibia Fractures. Ann Orthop Rheumatol 2015;3(3): 1051.
6. Martin Teraa MD, Taco J. Blokhuis MD, PhD, Lisa Tang MS, Loek P. H. Leenen MD, PhD. Segmental Tibial Fractures: An Infrequent but Demanding Injury. Clin Orthop Relat Res. 2013; 471:2790–2796.
7. Prashant Patel, Ketan Kakani, Pratik Prajapati, Viral Prajapati, Sandeep Patil. Orthopedic department, Shri M. P. Shah Government medical college, Jamnagar. Gujarat, India. Modalities of treatment for segmental tibia fracture. Journal of Research in Medical and Dental Science. July –September 2016; 4(3).
8. Ekeland A, Stromsoe K et al. Locked Intramedullary Nailing for displaced tibial shaft fractures. J Bone Joint Surg. 1990; 805-809.
9. IJ O., BU O., & SO N. Prevalence of Post-Operative Anaemia and its Complications among Obstetric and Gynaecological Patients in Enugu. Journal of Medical Research and Health Sciences, 2022; 5(9): 2250–2255.