e-ISSN: 0975-1556, p-ISSN:2820-2643

Available online on www.ijpcr.com

International Journal of Pharmaceutical and Clinical Research 2022; 14(9); 423-428

Original Research Article

A Study of the Assessment of Morphometric Evaluation of the Mental Foramen of Dry Adult Human Mandibles

Jay Prakash Bharti[1], Premjeet Kumar Madhukar[2], Manish Kumar[3], Soni Kumari[4]

[1]Assistant Professor, Head of Department, Department of Anatomy, Jannayak Karpoori Thakur Medical College & Hospital, Madhepura, Bihar (India)

[2]Associate Professor, Department of Anatomy, Jannayak Karpoori Thakur Medical College & Hospital, Madhepura, Bihar (India)

[3,4]Tutor, Department of Anatomy, Jannayak Karpoori Thakur Medical College & Hospital, Madhepura, Bihar (India)

Received: 15-07-2022 / Revised: 23-08-2022 / Accepted: 15-09-2022
Corresponding author: Dr. Soni Kumari
Conflict of interest: Nil

Abstract

Background: The identification and precise location of the mental foramen is of great importance to dental surgeon during the surgical procedures on the mandible. The present study performed morphometric evaluation of mental foramen of dry adult human mandibles.

Materials & Methods: 86 dry dentulous adult mandibles of both genders were included and parameters such as the distance between the MF to symphysis menti (SF), posterior border of the ramus (FR), alveolar crest (AF) and base (FB) were taken by a metallic wire parallel to the standard horizontal plane was measured by using a standard scale.

Results: Out of 86 mandibles, 52 were of males and 34 were of females. The mean (mm) SF on right side was 27.5 and on left side was 27.1, FR on right side was 70.4 and on left side was 70.2, AF on right side was 13.2 and on left side was 16.8 and FB on right side was 16.8 and on left side was 14.5. The difference was non- significant (P>0.05). The mean size of right mental foramen was 2.8 mm and left foramen was 3.0 mm. Location was at the level of apex in 20, above the apex in 18 and below the apex in 48. Shape was oval in 46 and round in 40. The difference was non- significant (P>0.05).

Conclusion: The most common shape of mental foramen was oval and in maximum cases it was found below the apex of premolars.

Keywords: Mental foramen, morphology, Shape

Introduction

Mental foramen (MF) is situated in anterolateral aspect of the body of the mandible which transmits the mental nerve and vessels, gradually migrates posteriorly after birth and through childhood [1]. In adults, it lies an average of 2.5 cm from the midline face, between the root apices of mandibular teeth 4 and 5 (range: teeth 3–6) [2]. Most foramina usually sit either level with or inferior to the tooth root apex and accessory mental foramina, if present, are mainly situated posterior or inferior to the main foramen. The mandibular foramen sits on the medial surface of the

ramus an average of 1.9 cm posterior to the third molar, 21 mm needle is therefore sufficient to reach the foramen for dental anaesthesia. The foramina almost always sit level with or below the occlusal plane, the remainder sitting above [3].The mandibular canal opens on the surface as a mental foramen between the space of first and second premolar tooth [4].The mental foramen can be seen below the second premolar tooth. It transmits the terminal branches of the inferior alveolar nerve and vessels [5].Variations in the position of the MF have been reported by many authors in different ethnic groups and various shapes have also been noticed [6]. Any foramen which is in addition to MF is considered as an accessory mental foramen (AMF) and it is usually located below the 1st molar teeth. This accessory mental foramen may transmit the branches of the mental nerve [7].

Aims and Objectives: The present study performed morphometric evaluation of mental foramen of dry adult human mandibles.

Materials & Methods

The present cross-sectional study, which was conducted on 86 dry dentulous adult mandibles of both genders in the Department of Anatomy, Jannayak Karpoori Thakur Medical College & Hospital, Madhepura, Bihar(India).This study was approved from institutional ethical committee.The study was carried out over a period of 6 months, from january 2022 to june 2022. Parameters such as the distance between the MF to symphysis menti (SF), posterior border of the ramus (FR), alveolar crest (AF) and base (FB) were taken by a metallic wire parallel to the standard horizontal plane, after which it was measured by using a standard scale. The distance between apex of the alveolar socket and upper border of the MF was measured from the values of A1 and A2. SF is distance between symphysis menti and most anterior margin of MF, FR is distance between most anterior margin of MF and posterior border of ramus of mandible. FB is distance between inferior margin of MF and inferior border of mandible perpendicular to horizontal plane. AF is distance between the alveolar crest and inferior margin of MF, perpendicular to horizontal plane. A1 is the distance between alveolar crest to upper most point of MF. A2 is the distance between the alveolar margins to the apex of second premolar socket. The size, shape was also noted. Data thus obtained were subjected to statistical analysis. P value < 0.05 was considered significant.

Results

Table 1: Distribution of dry mandible

Total- 86		
Gender	**Males**	**Females**
Number	52	34

Table 1 shows that out of 86 mandibles, 52 were of males and 34 were of females.

Table 2: Morphometrical parameters of mental foramen

Parameters (mm)	**Right side(in mm)**	**Left side (in mm)**	**P value**
SF	26.12±6.76	25.91±7.10	0.13
FR	71.71±7.10	71.78±7.92	0.17
AF	13.01±3.21	14.13±3.00	0.21
FB	15.11±2.71	14.14±3.12	0.28

SF= Distance from symphysis menti , **FR**= Distance from the posterior border of ramus of mandible, **AF**= Distance from alveolar crest and **FB**= Distance from base of mandible

Table 2 shows that mean (mm) ± SD. SF on right side was 26.12±6.76 mm and on left side was 25.91±7.10 mm, FR on right side was 71.71±7.10 mm and on left side was 71.78±7.92 mm, AF on right side was 13.01±3.21 mm and on left side was 14.13±3.00 mm and FB on right side was 15.11±2.71 mm and on left side was 14.14±3.12.The difference was non-significant (P>0.05).

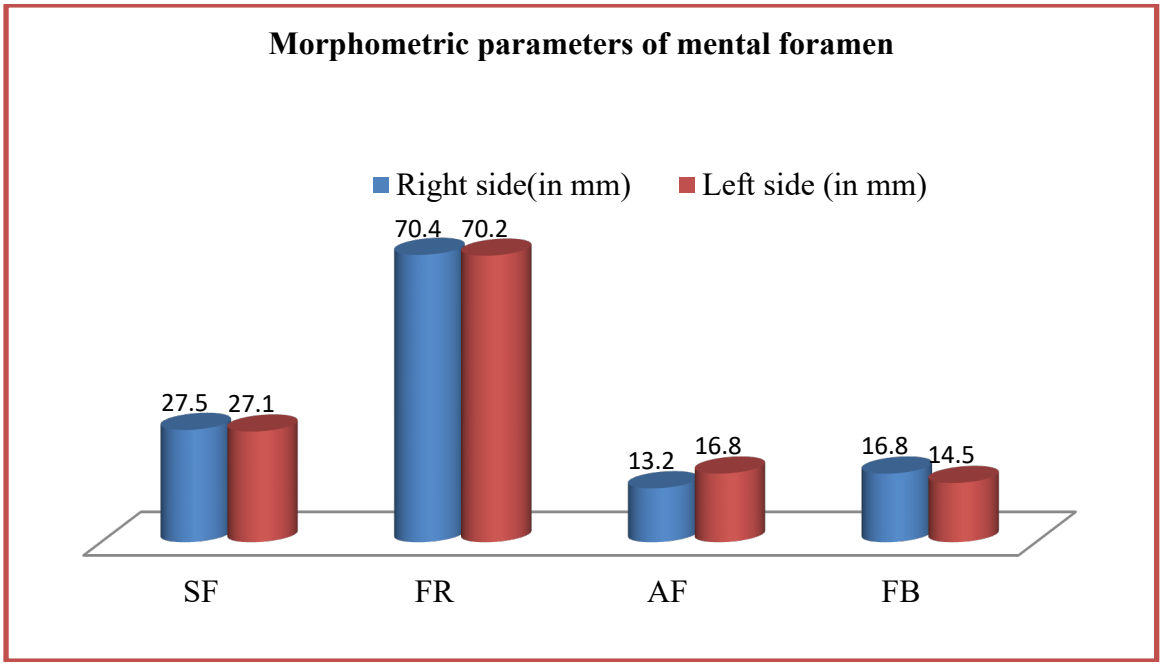

Figure 1: showing morphometric parameters of mental foramen

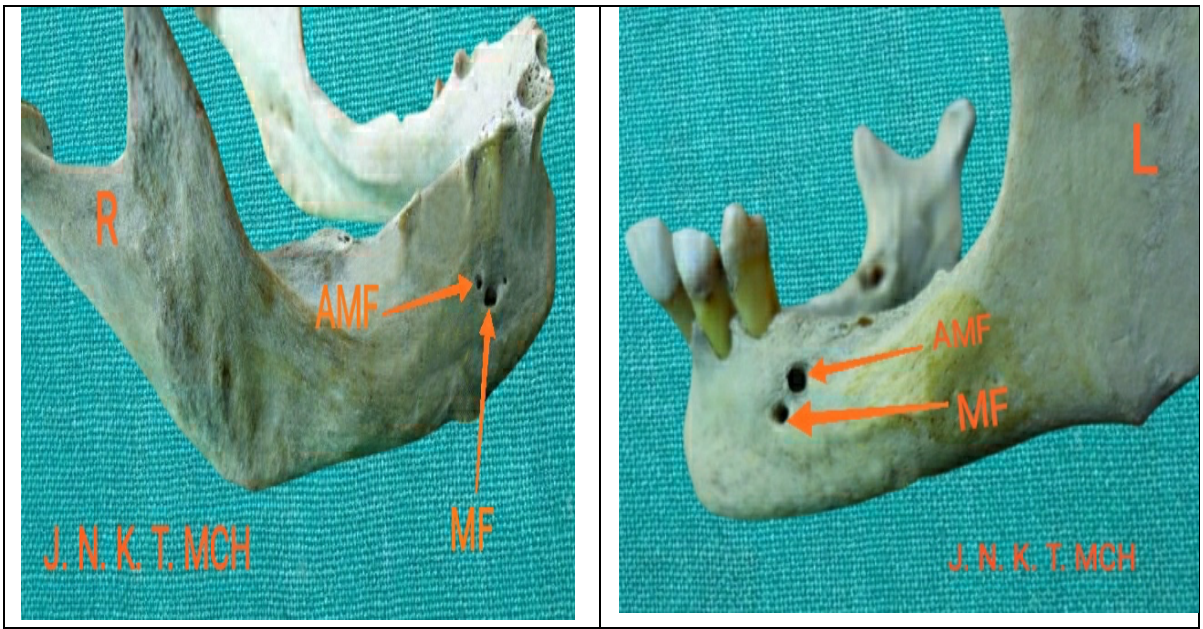

Pictures showing presence of accessory mental foramen(AMF) and mental foramen(MF) in right(R) and left(L) side of the mandible

Table 3: Size and location of mental foramen

Parameters	Variables	Mean(in mm)	P value
Size	Right	2.8	0.85
	left	3.0	
Location	At the level of apex	20	0.19
	Above the apex	18	
	Below the apex	48	
Shape	Oval	46	0.92
	Round	40	

Table III shows that mean size of right mental foramen was 2.8 mm and left foramen was 3.0 mm. Location was at the level of apex in 20, above the apex in 18 and below the apex in 48. Shape was oval in 46 and round in 40. The difference was non- significant (P>0.05).

Discussion

Variations of the mental foramen are often encountered ranging from difference in shape and positions to presence of accessory foramen or even complete absence in some cases [8,9]. Knowledge of its position, shape, and size is important for performing anesthetic block prior to clinical procedures in lower anterior teeth and to preserve integrity of the mental nerve trunk in surgical interventions [10,1]. The mental foramen is an important anatomical landmark to facilitate surgical, local anesthetic, and other invasive procedures [11,12]. The present study performed morphometric evaluation of mental foramen of dry adult human mandibles. We found that out of 86 mandibles, 52 were of males and 34 were of females. Budhiraja et al [13] determined morphometric parameters of mental foramen in 105 dry adult human mandibles of unknown sex. In most cases (74.3%), the MF was oval in shape and situated on the longitudinal axis of the 2nd premolar tooth (61% on right side and 59.1% on left side). The mean distance for the right and left sides was measured from various landmarks. Udhaya et al [2] conducted a study on 90 adult dry human mandibles. In a majority of the mandibles, the mental foramen was located at the level of the root of the 2nd premolar, midway between the inferior margin and the alveolar margin of the mandible. Most of the mental foramina were oval in shape. The orientation of the foramen was postero-superior in 83% of the mandibles. The accessory foramens were noted in five mandibles. We found that mean size of right mental foramen was 2.8 mm and left foramen was 3.0 mm. Location was at the level of apex in 20, above the apex in 18 and below the apex in 48. Shape was oval in 46 and round in 40. Tapas et al [14] assessed sixty- four dry adult human mandibles. In the present study the most common position of the mental foramen was in line with the longitudinal axis of the mandibular second premolar and was found to be in 67.46 % of the cases on the right side and 65.06 % on the left side. The mean distance of the mental foramen from the symphysis menti was 26.12±6.76 mm and 25.91±7.10 mm on the right and left sides respectively and from the posterior border of the ramus was 71.71±7.10 mm and 71.78±7.92 mm on the right and left sides respectively. The mental foramen was situated at a mean distance of 15.11±2.71 mm on the right side and 14.14±3.12 mm on the left side from the mandibular base and at a mean distance of 13.01±3.21 mm on the right side and 14.13±3.00 mm on the left side from the alveolar crest. The most prevalent shape was found to be oval on both sides (71.87% on right and 60.93% on left side). The mean transverse diameters was 3.45±0.70 mm on right and 2.90±0.87 mm on left sides whereas the mean vertical diameters was 2.33±0.56 mm and

2.23±0.94 mm on right and left sides respectively. Sankar et al [14] assessed the morphometry and morphology of MF in 90 dry dentulous mandibles Various parameters investigated are, the horizontal distance between symphysis menti and MF was 27.2 mm on right and 27.7 mm on the left, MF and posterior border of ramus was 70.7 mm on both sides, vertical distance between MF and inferior border of mandible was 16.5 mm on right and 14.3 mm on left, alveolar crest and MF was 13.7 mm on right and 16.4 on left, distance between the MF and below the apex of premolar socket was +2.8 mm on right and +3.5 mm on left and above the socket was -2.8 mm on right and -2.7 mm on left. Occurrence of MF below the second premolar tooth was found to be highest (73.2%). Average size of MF was larger on left and its way of exit was in postero-superior direction. Shape of MF was round in 79% and oval in 21% and double MF was found in 8.9% of mandibles. [15, 16]

The limitation the study is small sample size.

Conclusion

Authors found that the most common shape of mental foramen was oval and in maximum cases it was found below the apex of premolars.

Acknowledgment

We are immensely grateful to Prof. Dr. Bhupendra Kumar, Principle, Jannayak Karpoori Thakur Medical College & Hospital, Madhepura, Bihar (India). and Dr. Birendra Kumar Sinha, Associate Professor and Head of the Department of Anatomy, Patna Medical College & Hospital, Patna, Bihar (India) for their support and valuable suggestions.

References

1. Balcioglu A H et al. Horizontal migration of pre- and postnatal mental foramen: An anatomic study. International journal of paediatric otorhinolaryngology, Volume 75, Issue 11, November 2011, Pages 1436-1441
2. K Udhaya et al. The Morphometric Analysis of the Mental Foramen in Adult Dry Human Mandibles: A Study on the South Indian Population. J Clin Diagn Res. 2013 Aug; 7(8): 1547–1551.
3. Standring Susan Gray's Anatomy, the anatomical basis of clinical practice, International 41st Edition (2016), page no. 409- 410.
4. Romanes J. G et al. Cunningham's textbook of anatomy, 12th edition, page no.- 127-129
5. Mehta Vandana, Suri R k. Snell's clinical anatomy by regions, South Asian edition, 2018, page no.- 650-651.
6. Greshchenson AL, Nathan H, Luchansky E. Mental foramen and mental nerve: Changes with age. Acta Anat 1986; 126:21-8.
7. Al Jasser NM, Nwoku AL. Radiographic study of the mental foramen in a selected Saudi population. Dentomaxillofacial Radiol 1998; 27:341-3.
8. Green RM. The position of the mental foramen: a comparison between the southern (Hong Kong) Chinese and other ethnic racial groups. Oral Surg Oral Med Oral Path 1987; 63:287-90.
9. Morrant GM. A biometric study of the human mandible. Bio metrika 1936; 28:84-122.
10. Amorim MM, Prado FB, Borini CB, Bittar TO, Volpato MC, Groppo FC, et al. The mental foramen position in dentate and edentulous Brazilian's mandible. Int J Morphol 2008; 26:981-7.
11. Drennan MR. The mental foramen with special reference to its position in the edentulous mandible. South Afr Dent J 1930; 4:494-509.
12. Wical KE, Swoope CC. Studies of residual ridge resorption. In use of panoramic radiographs for evaluation and classification of mandibular

resorption. J Prosthet Dent 1974; 32:7-12.
13. Budhiraja V, Rastogi R, Lalwani R, Goel P, Bose SC. Study of position, shape, and size of mental foramen utilizing various parameters in dry adult human mandibles from north India. International Scholarly Research Notices. 2013;2013.
14. Tapas S. Morphometric Analysis of the Mandibular Foramen in Dry Adult Human Mandibles. International Medical Journal. 2016 Feb 1;23(1).
15. Sankar DK, Bhanu SP, Susan PJ. Morphometrical and morphological study of mental foramen in dry dentulous mandibles of South Andhra population of India. Indian Journal of Dental Research. 2011 Jul 1;22(4):542.
16. Khan A., Tidman D. M. M., Shakir D. S., & Darmal D. I. Breast Cancer in Afghanistan: Issues, Barriers, and Incidence. Journal of Medical Research and Health Sciences, 2022;5(8): 2125–2134.