e-ISSN: 0975-1556, p-ISSN:2820-2643

Available online on www.ijpcr.com

International Journal of Pharmaceutical and Clinical Research 2022; 14(9); 471-477

Original Research Article

The Assessment of Speckle Tracking Echocardiography and Coronary Angiography in Patients with Suspected Stable Angina Pectoris with Normal Conventional Transthoracic Echocardiography a Single Center Study from South India

Syed Imran Hussain[1], Jaisankar Perumal[2], T. Balasubramanian[3]

[1]Senior Resident, Department of Cardiology, KAPV Government Medical College, Trichy.

[2]HOD & Professor, Department of Cardiology, KAPV Government Medical College, Trichy.

[3]Professor, Department of Cardiology, KAPV Government Medical College, Trichy

Received: 15-04-2022 / Revised: 20-05-2022 / Accepted: 05-06-2022

Corresponding author: Dr Syed Imran Hussain

Conflict of interest: Nil

Abstract

Background: With current burden of suspected stable angina pectoris patients, there is need for evaluation with appropriate diagnostic modality.

Aims and Objectives: With the above concern, we aimed to observe speckle tracking echocardiography for presence and extent of coronary artery disease in patients with suspected stable angina pectoris.

Materials and Methods: 43 patients of suspected stable angina pectoris with normal resting electrocardiogram and resting conventional echocardiography with normal cardiac biomarker were subjected to speckle tracking echocardiography and coronary angiography. Global Longitudinal Peak Systolic Strain (GLPSS) and Segmental Longitudinal Peak Systolic Strain (SLPSS) and coronary angiography was interpreted.

Results: Measurable difference in the mean of global longitudinal peak systolic strain between normal coronaries and different extent of coronary artery disease (CAD) (-19.76±0.58 for normal, -17.01 ± 0.46 for single vessel, -15.47 ± 0.46 for two vessels, -14.27 ±0.54 for three vessels, -13.80 ± 0.14 for left main disease). GLPSS had considerable difference in mean value for single vessel CAD; two vessel CAD, three vessel CAD and isolated Left main disease . Also segmental LPSS showed significance for localization of the affected vessel.

Conclusion: GLPSS and SLPSS are useful in suspected stable angina patient who have normal resting electrocardiography and conventional echocardiography, to select patients for coronary angiography.

Keywords: Suspected Stable Angina Pectoris, Speckle Tracking Echocardiography, Coronary Angiography.

Background

A major cause of mortality and morbidity is Coronary artery disease. The diagnosis and risk stratification of suspected stable angina pectoris (SAP) [1] involves non-invasive imaging modalities (NIIM). Resting conventional transthoracic

echocardiography (TTE) for evaluation of stable CAD may show structurally normal heart without wall motion abnormalities despite critical CAD. Myocardial perfusion scintigraphy (MPS), Stress echocardiography and Exercise Electrocardiography have varying sensitivity and specificity with limitations for stable CAD [2]. In stable CAD, coronary computed tomography angiography (CTA) is another non-invasive option, but expert consensus considers only selected patients for CTA [3].

Nuclear imaging gives high diagnostic accuracy at cost of radiation exposure [4]. Dobutamine stress echocardiography is without radiation exposure, has high sensitivity and specificity, but requires controlled setting and expertise [5]. Despite NIIM, non-significant coronary lesions are not rare with a study showing rate of significant CAD in elective coronary angiograms was 38% [6].

Longitudinal deformation is a sensitive marker of CAD, especially for myocardial stunning from intermittent ischemia that remain occult for conventional resting TTE [7]. Thus, Two Dimensional Speckle Tracking Echocardiography (2D STE) assessment of Myocardial strain has a higher diagnostic accuracy in detecting left ventricular dysfunction. Previous studies showed lower values of deformation in patients with acute coronary syndrome, diabetes mellitus [8] hypertension [1] and SAP [9-15]. Simple, non-invasive method is required to improve selection of stable angina patients for coronary angiography.

Aims and Objectives

This study aimed to evaluate the value of global longitudinal peak systolic strain (GLPSS) performed at rest to predict the presence and extent of CAD in patients with suspected stable angina pectoris.

Materials and Methods

This study was conducted at Mahatma Gandhi Memorial Government Hospital / K.A.P Viswanatham Government Medical College, Tiruchirappalli, Tamil Nadu.

Study design- Single center, prospective, observational study enrolled 43 consecutive patients with suspected stable angina pectoris from August 2021 to April 2022. All patients signed an informed consent and the study was approved by the local ethics committee.

Inclusion criteria

1. Patients ≥ 18 years clinically suspected to have stable CAD. Patients included had:
   (i) Symptoms suspected to be related to CAD such as breathlessness and exertional fatigability;
   (ii) Previously symptomatic with known obstructive or nonobstructive CAD, became asymptomatic with treatment;
   (iii) Similar symptoms for several months and are clinically considered to be in a chronic stable condition.
   (iv) Normal conventional two-dimensional (2D) echocardiography

Exclusion criteria

1. Post Percutaneous Coronary Intervention (PCI) or Coronary Artery Bypass Graft (CABG) status.
2. Positive cardiac enzymes. (Serum troponin / CKMB).
3. Patient in heart failure.
4. Resting ECG with Intra-ventricular conduction disturbances, pathological Q waves and/or atrial fibrillation.
5. Assessment of all segments by Speckle Tracking Examination (STE) not possible.
6. Mehran prediction score for Contrast induced nephropathy ≥ 6
7. Patient Refusal to CAG.

Medical history of patients was taken regarding presenting symptom and risk factors for CAD. Demographic data (age, gender, body mass index [BMI]) was noted. Physical examination was done.

Resting ECG and necessary laboratory investigations were conducted.

Conventional TTE was performed for all patients using Vivid E95 v204 General Electric echocardiography machine. All TTE parameters were measured.

Patients included were taken up for STE. In the apical four-, two-chamber and apical long axis views we recorded three consecutive end-expiratory cardiac cycles using high frame rate (80–100 frames/s) and harmonic imaging was acquired.

Quantification of peak systolic strain by automated functional imaging was done. Strain analysis software using a 17-segment model in a 'bull's eye' plot calculated the average of a longitudinal peak systolic strain of each view and the mean of the three views and provided GLPSS for the complete LV .The normal value of longitudinal peak systolic strain is -18% [16].

CAG was done within 1 week of echo study. A reduction in arterial lumen area of ≥ 50% for left main coronary vessel and >70% for left anterior descending (LAD), left circumflex (LCX) and right coronary artery (RCA) were considered significant. All angiograms were analysed visually by an experienced operator who was blinded to the results of the echocardiographic examinations.

Results

Our study included 43 patients. Mean age of the studied population was 52.697 ± 1.469 year and mean BMI was 28.20±0.321 kg/m^2 (Table 1). 26 patients (60.46%) were diabetic, 27 patients (62.79%) were hypertensive, 24 patients (55.81%) were dyslipidemic, 16 patients (37.20%) were smoker, 6 patients (13.95%) had a family history (Table 1). According to the results of CAG, 10 (23.26%) patients had normal CAG and 33 (76.74%) patients had CAD (Table 1)

Table 1: Demographic data and risk factors of the studied patients (N=43) and extent of angiographic CAD.

			Patients with CAD n_2=33 (76.74%)			
	Study Variables	Normal [n_1=10 (23.26%)]	SVD without LM [n_{2a}=15 (45.45%)]	DVD without LM [n_{2b}=7 (21.21%)]	TVD without LM [n_{2c}=9 (27.27%)]	Isolated LM disease [n_{2d}=2 (6.06%)]
Age (years)	Mean ± SD (52.697±1.469)	51.5 ± 3.69	51.5333 ± 1.972	53.0 ±3.192	54.444 ± 3.019	58.5±2.079
	Range	44–60	45–57	48–59	47–60	57–60
Gender	Male n=25 (58.13%)	6 (60%)	9 (60%)	3 (42.85%)	6 (66.67%)	1 (50%)
	Female n=18 (41.86%)	4 (40%)	6 (40%)	4 (57.15%)	3 (33.33%)	1(50%)
BMI (Kg/m^2)	Mean ± SD (28.20±0.321)	27.70 ± 0.718	27.973 ± 0.509	29.057 ±0.612	28.366 ±0.57	28.7±0.554
	Range	26–29.4	26.5–29.7	27.7–30.1	27.4–30.2	28.3–29.1
Risk Factors	DM n= 26 (60.46%)	5 (50%)	10 (66.66%)	4 (57.14%)	5 (55.55%)	2 (100%)
	HTN n= 27 (62.79%)	6 (60%)	10 (66.66%)	4 (571.4%)	5 (55.55%)	2 (100%)
	Smoking n=16 (37.20%)	3(30%)	7 (46.66%)	2 (28.57%)	3 (33.33%)	1(50%)

	Dyslipidemia n=24 (55.81%)	6 (60%)	10(66.66%)	3(42.85%)	4(44.44)	1 (50%)
	Family history n=6 (13.95%)	0 (0%)	2(13.33%)	1(14.28%)	2(22.22)	1 (50%)

Among 33 patients with CAD, 15 (45.45%) patients had SVD, 7 (21.21%) patients had DVD, 9 (27.27%) patients had TVD all with normal LM and 2 (6.06%) patients had isolated LM disease. Among 31 patients with CAD with normal LM, 18 (58.06%) had LAD disease, 13 (41.93%) had LCX disease and 12 (38.70%) had the RCA disease.

2D Speckle tracking assessment- Mean GLPSS in study was -19.76 ± 0.58, -17.01 ± 0.46, -17.01 ± 0.46, -14.27 ±0.54 and -13.80 ± 0.14 for normal, SVD, DVD, TVD and isolated left main disease, respectively (Table 2)

Table 2: Mean of Longitudinal Peak Systolic Strain.

Mean of GLPSS (Mean±SD)			
Normal	SVD	DVD	TVD
-19.76±0.58	-17.01 ± 0.46	-15.47 ± 0.46	-14.27 ±0.54
Mean Segmental LPSS (Mean±SD)			
LAD disease territory		LCX diseaseterritory	RCA disease territory
-14.355±0.604		-14.907±0.543	-14.658±0.867

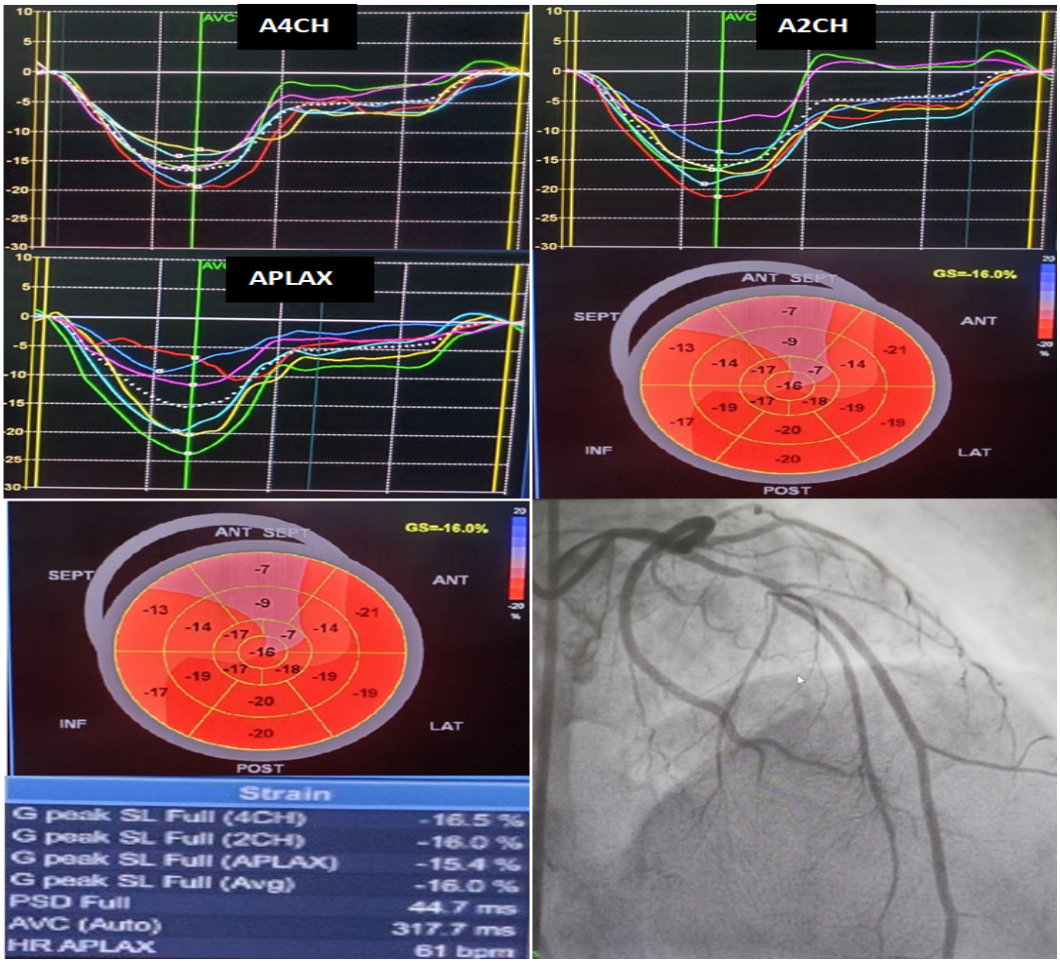

Figure 1: Global and segmental longitudinal strain in a patient with significant LAD lesion. There is reduced GPLSS (-16.0%) and reduced regional strain in distribution of diseased LAD.

Discussion

A non-invasive and economical screening of CAD is required in patients with suspected SAP without history of MI with structurally and functionally normal heart on conventional TTE [17] GLS by 2-D STE at rest is sensitive to detect significant CAD [12]. Results of our study are in agreement with those of Liou *et al* [18] and Stancovic *et al* [8] which highlighted the superiority of STE in early prediction and detection of CAD respectively.

We found that patients with normal coronaries had Mean of GLPSS -19.76±0.58 in agreement with Moustafa S *et al* [15] where GLPSS of normal group was -20.11 ±0.8.

In the present study, there was lower GLPSS in patients with CAD compared to those with normal coronary artery.

SLPSS was also abnormal in diseased territory thus appropriate for localization of the affected vessel. This finding was in agreement to Chaichuum *et al* [19] that demonstrated segmental longitudinal strain and Strain Rate values of the particular vessel-supplied myocardium were significantly decreased corresponding to the severity of vessel stenosis. Findings was also concordant with Moustafa S *et al* [15] as they demonstrated SLPSS was statistical significant for localization of the affected vessel ($p = 0.001$).

Our results are in agreement with Biering-Sørensen [14] study that included 296 consecutive patients with clinically suspected SAP without previous cardiac disease and normal left ventricular ejection fraction (LVEF). GLPSS was significantly lower in patients with CAD compared with patients without CAD (-17.1 ±2.5% versus -18.8 ± 2.6%; $p < 0.001$)

Our observation of 2DSTE showed abnormal GLPSS and SLPSS in suspected stable angina patient with normal ECG and conventional echocardiography with normal cardiac marker. Thus 2DSTE is rational in this subset of patients to detect the presence and extent of CAD.

Study limitation-This study was done in single center with small number of patients without correlating the CAD risk factors.

Conclusion

Conclusion: GLPSS and SLPSS are useful in suspected stable angina patients who have normal resting electrocardiography and conventional echocardiography, to select them for coronary angiography.

References

1. Task Force M, Montalescot G, Sechtem U, Achenbach S, Andreotti F, Arden C, Budaj A, Bugiardini R, Crea F, Cuisset T, *et al*. 2013 ESC guidelines on the management of stable coronary artery disease: the task force on the management of stable coronary artery disease of the European Society of Cardiology. Eur Heart J. 2013;34(38):2949–3003.
2. Tsai WC, Liu YW, Huang YY, Lin CC, Lee CH, Tsai LM. Diagnostic value of segmental longitudinal strain by automated function imaging in coronary artery disease without left ventricular dysfunction. J Am Soc Echocardiogr. 2010; 23:1183–1189.
3. Parato VMA, Mehta D, Delfino S, Amabili M, Partemi P, Grossi Nardini E. Resting echocardiography for the early detection of acute coronary syndromes in chest pain unit patients. Echocardiography. 2010; 27:597.
4. Buechel RR, Kaufmann BA, Tobler D, Wild D, Zellweger MJ. Non-invasive nuclear myocardial perfusion imaging improves the diagnostic yield of invasive coronary angiography. Eur Heart J Cardiovasc Imaging. 2015;16(8):842–7.
5. Sicari R, Cortigiani L. The clinical use of stress echocardiography in ischemic heart disease. Cardiovasc Ultrasound. 2017;15(1):7.
6. Patel MR, Peterson ED, Dai D, Brennan JM, Redberg RF, Anderson HV, Brindis RG, Douglas PS. Low diagnostic yield of elective coronary

angiography. N Engl J Med. 2010;362(10):886–95.

7. Damman P, van Geloven N, Walentin L, *et al*. Timing of angiography with a routine invasive strategy and long-term outcomes in non-ST segment elevation acute coronary syndrome: a collaborative analysis of individual patient data from the FRISC II (Fragmin and Fast Revascularization During Instability in Coronary Artery Disease), ICTUS (Invasive versus Conservative Treatment in Unstable Coronary Syndromes), and RITA-3 (Intervention versus Conservative Treatment Strategy in Patients With Unstable Angina or Non-ST elevation Myocardial Infarction) Trials. JACC Cardiovasc Interv. 2012; 5:191– 199.
8. Stankovic I, Putnikovic B, Cvjetan R, Milicevic P, Panic M, Kalezic-Radmili T, Mandaric T, Vidakovic R, Cvorovic V, Neskovic AN. Visual assessment vs. strain imaging for the detection of critical stenosis of the left anterior descending coronary artery in patients without a history of myocardial infarction. Eur Heart J Cardiovasc Imaging. 2015;16(4):402–9.
9. Zhang L, Wu WC, Ma H, Wang H. Usefulness of layer-specific strain for identifying complex CAD and predicting the severity of coronary lesions in patients with non-ST-segment elevation acute coronary syndrome: compared with syntax score. Int J Cardiol. 2016; 223:1045–52.
10. Caspar T, Samet H, Ohana M, Germain P, El Ghannudi S, Talha S, Morel O, Ohlmann P. Longitudinal 2D strain can help diagnose coronary artery disease in patients with suspected non-ST-elevation acute coronary syndrome but apparent normal global and segmental systolic function. Int J Cardiol. 2017; 236:91–4.
11. Bendary A, Tawfeek W, Mahros M, Salem M. The predictive value of global longitudinal strain on clinical outcome in patients with ST-segment elevation myocardial infarction and preserved systolic function. Echocardiography. 2018;35(7):915–21.
12. Zuo H, Yan J, Zeng H, Li W, Li P, Liu Z, Cui G, Lv J, Wang D, Wang H. Diagnostic power of longitudinal strain at rest for the detection of obstructive coronary artery disease in patients with type 2 diabetes mellitus. Ultrasound Med Biol. 2015;41(1):89–98.
13. Huang H, Ruan Q, Lin M, Yan L, Huang C, Fu L. Investigation on left ventricular multi-directional deformation in patients of hypertension with different LVEF. Cardiovasc Ultrasound. 2017;15(1):14.
14. Biering-Sorensen T, Hoffmann S, Mogelvang R, Zeeberg Iversen A, Galatius S, Fritz-Hansen T, Bech J, Jensen JS. Myocardial strain analysis by 2- dimensional speckle tracking echocardiography improves diagnostics of coronary artery stenosis instable angina pectoris. Circ Cardiovasc Imaging. 2014;7(1):58–65.
15. Moustafa S, Elrabat K, Swailem F, Galal A. The correlation between speckle tracking echocardiography and coronary artery disease in patients with suspected stable angina pectoris. Indian Heart J. 2018;70(3):379–86.
16. Farsalinos K.E., Daraban A.M., Unlu S., Thomas J.D., Badano L.P. and Voigt J.U.: Head-to-Head Comparison of Global Longitudinal Strain Measurements among Nine Different Vendors: The EACVI/ASE Inter-Vendor Comparison Study". Journal of the American Society of Echocardiography: official publication of the American Society of Echocardiography 2015; 28**:** 1171. e2.
17. Nesbitt GC, Mankad S, Oh JK. Strain imaging in echocardiography: methods and clinical applications. Int J Cardiovascu Imaging. 2009;25(Suppl 1):9–22.
18. Liou K, Negishi K, Ho S, Russell EA, Cranney G, Ooi SY. Detection of obstructive coronary artery disease

using peak systolic global longitudinal strain derived by two-dimensional speckle-tracking: a systematic review and meta-analysis. J Am Soc Echocardiogr. 2016;29(8):724–35 e724.

19. Chaichuum, Srisakul & Chiang, Shuo-Ju & Daimon, Masao & Chang, Su-Chen & Chan, Chih-Lin & Hsu, Chu-Ying & Chen, Hsiang-Ho & Tseng, Ching-Li. Segmental Tissue Speckle Tracking Predicts the Stenosis Severity in Patients With Coronary Artery Disease. Frontiers in Cardiovascular Medicine. 2022.