e-ISSN: 0975-1556, p-ISSN:2820-2643

Available online on www.ijpcr.com

International Journal of Pharmaceutical and Clinical Research 2023; 15(1); 497-502

Original Research Article

A Study of Proximal Femur Locking Compression Plate in the Fixation of Extracapsular Proximal Femoral Fractures

Akhil R[1], K Kumaran Chettiar[2], Jacob Mathew[3]

[1]Senior Resident, Department of Orthopaedics, Government Medical College Kozhikode, Kerala

[2]Additional Professor, Department of Orthopaedics, Government Medical College Konni, Pathanamthitta, Kerala

[3]Professor, Department of Orthopaedics, Government Medical College Kozhikode, Kerala

Received: 26-10-2022 / Revised: 30-11-2022 / Accepted: 30-12-2022

Corresponding author: Dr K Kumaran Chettiar

Conflict of interest: Nil

Abstract

Globally, femoral fractures are of great interest. Because people are living longer, incidence has grown dramatically over the past few decades, and this trend is likely to continue in the foreseeable future. The therapy was primarily conservative before the development of adequate fixation devices. Due to the high likelihood of complications, this conservative approach has now earned a bad reputation, making operational management the preferable course of action. The goal of the current investigation is to examine the function of surgical treatment for proximal femoral fractures and evaluate its effectiveness. Between October 2019 and October 2021, the trial involved patients receiving treatment for a closed displaced proximal femoral fracture. The study comprised a total of 29 patients with proximal femoral fractures. There were 14 men and 15 women patients, ranging in age from 50 to 90. Intertrochanteric and subtrochanteric fractures were categorised in accordance with Boyd and Griffin and Seinsheimer's, respectively. According to the Larson (IOWA) Hip Scoring System, the functional outcome was assessed. A score of 91–100 indicates an excellent result, 80–90 is good, 70–79 is reasonable, and 70 is a poor result. The aim of treatment for unstable proximal femoral fractures is stable fixation and less complicated early mobilisation. PF-LCP was used to accomplish this more successfully. Finally, in summarize PF-LCP represents a feasible alternative for unstable proximal femoral fractures.

Keywords: Femoral Fractures, Internal Fixation, Proximal Femur Locking Compression Plate Boyd And Griffin, Seinsheimer's.

Introduction

One of the leading causes of illness and mortality in the elderly worldwide is hip fractures. According to studies, proximal femur fractures are becoming more common as a result of urbanization's increased sedentary lifestyle and longer average life expectancy [1] Intertrochanteric fractures, which make up 50% of proximal femoral fractures and a significant portion of which are unstable, and subtrochanteric fractures, which make up 5-11% of extracapsular proximal femur fractures, respectively, account for 73.3% and 26.7% of all proximal femoral fractures [2,3]. According to studies,

there would be 2.6 million hip fractures by 2025 and 4.5 million by the end of 2050 [4]. Proximal Femur Locking Compression Plate (PF-LCP), as a treatment option of these kinds of fractures [5]. It provides three-dimensional and angular stable fixations of fracture fragments. PF-LCP is a limited-contact implant and provides angular stability because of 3 screw fixation patterns at the fracture site [6]. PF-LCP act as an internal external fixator and provides a strong anchor in osteoporotic bone. PF-LCP also had the advantage that it will not fail at the screw bone interface and also avoid the need for excessive bone removal. The plate is designed such a way to accommodate average femoral neck anteversion. It also holds the advantage that in comminuted segmental fractures, it spans the entire diaphysis [7,8].

This study is intended to access the outcome of fixation of Proximal femoral fracture using a Proximal femoral locking plate at the Orthopaedic emergency and outpatient department

Materials and Method

This study was conducted from Oct 2019 to Oct 2021. During this period 29 cases of adult patients with unstable proximal femur fractures, attending the Orthopaedic emergency and outpatient department were selected.

Inclusion Criteria

1. Extra capsular proximal femoral fractures
2. Age between 50 – 90 years.
3. Skeletally mature patients.
4. No medical contraindication for anesthesia.
5. Patients willing to give written and informed consent for participation in the study.

Exclusion Criteria

1. Age less than 50
2. Age greater than 90,
3. Polytrauma
4. Pathological fractures.
5. Medical contraindication to anaesthesia and/ or surgery.
6. Skeletally immature patients.
7. Patients neurologically unstable

A radiolucent, padded counter traction pole was positioned between the patient's legs as they lay supine on the fracture table. Image intensifier was accommodated by flexing and abducting the unaffected leg. A traction foot component was used to support the afflicted leg. The antero-posterior and true lateral views were both able to be captured thanks to the positioning of the C-arm image intensifier in between the patient's legs. All patients received a prophylactic antibiotic 30 minutes prior to the start of surgery.

Observation and Results

The Study involved 29 patients of proximal femur fractures, which were operated in Orthopeadic department in our hospital. The study was limited to age group between 50-90 years. Maximum cases were in the age group between 60-80 years i.e. with an average age of 67.3 years. Youngest was 51 while oldest was 86 years. The Study involved 14 (48.27%) males and 15 (51.72%) females. Male: Female ratio was 1: 1.07. There was a slight female preponderance (51.72%). Left Side was involved in 18 (62.06%) and right in 11 (37.93%). Shelf fall being most common mode of injury accounting 86.20% of all the cases. Out of the 29 patients, 18 (62.06%) were Intertrochanteric, 4 (13.79%) were Subtrochanteric and rest 7 (24.13%) were Intertrochanteric fractures with subtrochanteric extension.

According to Boyd and Grrifin classification, we have 15 (51.72%) Type 2, 3 (10.34%) Type 3 and 7 (24.13%) Type 4 Intertrochanteric fractures but in Seinsheimer classification we have 1 (3.4%) in Type 2B,

2 (6.80%) in Type 3A and 1 (3.4%) in Type 3B (Figure 1). 2 (6.89%) patients were alcoholic, 1(3.44%) patient was a smoker and rest 3 (10.34 %) were Alcoholic & smokers (Figure 2). 15 (51.72%) patients have comorbidities of Diabetes Mellitus, 13(44.82%) patients have comorbidities of Hypertension (Figure 3). In our study, most of the patients were operated on within 6-8 days of hospital admission (89.66%). This delay was due to time is taken for treatment of preexisting diseases and scheduled operating days in the hospital. The average time lapse for surgery is 6.05 days.

The average time for delay in fixation was 7 days ranging from 3 to 10 days with an average hospital stay of 14 days (range 10 to 18 days). The mean follow-up was 11 months (range 6 to 18 months). In this study, most of the surgery was completed in 90 minutes, and the average time taken for surgery was 93.3 minutes. The average duration from surgery to mobilization (partial weight bearing) was 14.5 weeks, with a minimum of 13 weeks to a maximum of 18 weeks. In our study, there was 1 case each of chest infection and Urinary Tract Infection, noted along with 4 cases of bed sore. Superficial wound infection was seen in 3 (10.3%) cases. There were no cases of deep wound infection. In cases of wound infection, IV antibiotics were prolonged. All 29 cases united within 6 months of follow-up, with an average of 19.3 weeks (range 17-21). We have used criteria for the union as, the presence of bridging callus radiologically & absence of pain at the fracture site. In our study, 5 cases (17.24%) showed varus collapse. In our study 1 case (3.44%) had developed medialization of the femur. 2 cases (6.88%) had implant failure as complications i.e., screw back out, proximal migration of plate and loosening of proximal screws. No cases of non-union, or breakage of the plate were noted. No patient required revision surgery. The functional outcome results were graded according to Larson (IOWA) Hip Scoring System [9] at the end of the 6th month. A score of 91-100 denotes an excellent outcome, 80-90 is good, 70-79 fair, and <70 - is a poor outcome. In this study, there were 3 cases (10.34%) with good results, of these 2 were below 60 years, and all of them were without any postoperative complications. 23 patients (79.31%) had fair results. 3 patients (10.34) % had poor results. Most of the patients with poor results were of older age, with postoperative complications and comorbidities. The average Larson hip score in our study was 73.48%.

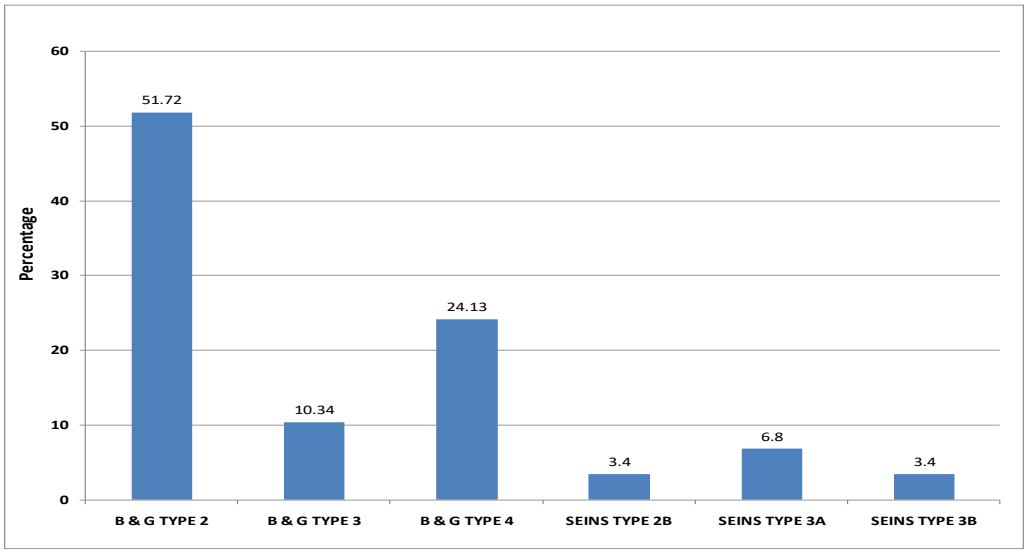

Figure 1: Classification of Fracture

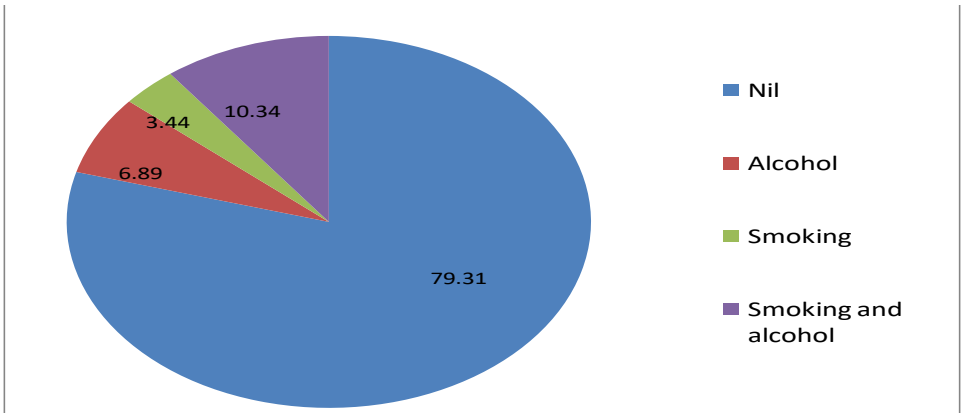

Figure 2: Habits

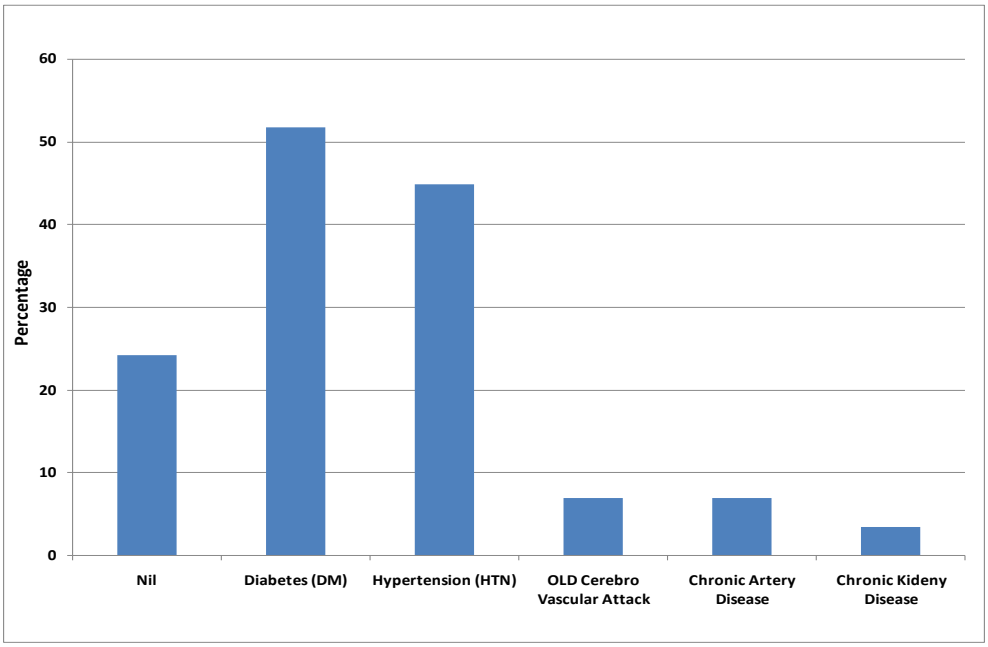

Figure 3: Comorbidities

Discussion

The most popular implants for proximal femoral fracture fixation are the Dynamic Hip Screw, Dynamic Condylar Screw, and Proximal Femoral Nailing. Varus collapse, cut-out of the head screw, implant failure, limb length discrepancy and primarily shortening, are problems associated with dynamic condylar screws (DCS), dynamic hip screws (DHS), and angled blade plates. Although intramedullary devices have mechanical advantages, they also have certain drawbacks, such as a challenging insertion process, a lengthy learning curve, and the potential for implant-related fractures. With satisfactory success, stable per trochanteric fractures can be repaired with traditional implants. A surgical challenge arises from unstable extracapsular proximal femur fractures because reduction and fixation are challenging to achieve and sustain due to fracture comminution, powerful deforming pressures, complex fracture patterns, and inadequate bone stock. Even though numerous extramedullary and intramedullary implants have been developed, none of them has achieved

widespread approval. Various authors have shown a high complication rate with the use of these implants. The failure rate of gamma nails for the treatment of these fractures ranges from 12.7% to 15% [10]. Fogagnolo *et al*., showed a complication rate of about 23.4% with the use of PFN for the treatment of this unstable fractures [11]. In another study done by Uzun *et al* [12]. Nonunion was seen in 5.7%, secondary varus collapse in 25.7%, cut out of proximal screws in 5.7% and reoperation in 14.3% cases. As for PFNA, Takigami *et al* [13] showed complications in 14% of the cases and 4% required reoperation. In another study by Yaozeng *et al*., intraoperative complications were seen in 20% cases and 9.1% of cases had femoral shaft fractures [14]. Contrary to intramedullary implants, plating has a number of theoretical benefits, such as the ability to achieve and maintain anatomical reduction and the avoidance of iatrogenic surgical stress to the abductor mechanism. In comparison to earlier plate designs, proximal femur locking plates (PFLP) significantly improve on anatomic pre-contouring and locking screws with multiple fixation locations into the femoral head and neck. Because there are three screw fixations at the fracture site, PFLCP gives the surgeon the freedom to achieve plate-to-bone apposition as well as axial compression or angular stability. Due to the fact that it takes very little bone upon treatment, it is perfect for osteoporotic bones. In the head and neck region of the proximal femur, several screws are positioned at different angles, offering superior mechanical stability.

Conclusion

So, despite a few negative outcomes, such as a low Larson Hip Score, we arrive at the conclusion that PF-LCP offers satisfactory results in these types of fractures. However, this method is not ideal, particularly in comminuted unstable fractures with poor bone quality. It is a technically difficult operation. Complications may be seen as a result of a variety of patient- or implant-related issues, such as improper placing of the locking screws in the neck and surgical varus malpositioning. In the event that the Regular implant is not appropriate, PF-LCP may be used as a backup plan. To prevent problems, PF-LCP needs extensive postoperative immobilisation.

References

1. Davis, T.R.C, Sher JL, Horsman A, Simpson M, Porter BB, and Checketts RG. Intertrochanteric femoral fractures. Mechanical failure after internal fixation. J Bone and Joint Surg. 1990; 72-B (1): 26-31.
2. Kyle R.F, Cabanela M.E, Rusell T.A. Fractures of the proximal part of the femur. Instr Course Lect 1995; 44:227-253.
3. Manish R, Sourabh S, Suresh U, Chetan S, Gopala R M. To Assess the Functional Outcome of Intertrochanteric Fractures of Femur Treated with Proximal Femoral Nail. International Journal of Toxicological and Pharmacological Research 2022; 12(9); 180-186
4. Kumar N, Kataria H, Yadav C, Gadagoli BS, Raj R. Evaluation of proximal femoral locking plate in unstable extracapsular proximal femoral fractures: Surgical technique & mid-term follow up results. Journal of Clinical Orthopaedics and Trauma. 2014; 5(3):137-145.
5. Sanjib K.B. Comparative Evaluation of Hip and Femur Fractures by DHS versus PFN Treatment. International Journal of Pharmaceutical and Clinical Research 2022; 14(12); 666-671.
6. Vikash M.H, Kunal S, Laljee C. A Prospective Assessment of the Outcome in Terms of Radiology and Functions after Open Reduction and Internal Fixation of Distal Femur Fractures by Locking Compression Plate. International Journal of Pharmaceutical

and Clinical Research 2022; 14(9); 233-239.

7. Kumar S, Shankar N, Shashikant K.S. Retrospective Assessment of Intertrochanteric Fractures of Femur Managed Using Proximal Femoral Nail. International Journal of Toxicological and Pharmacological Research 2022; 12(1); 48-53.
8. Hanschen M, Aschenbrenner I.M, Fehske K, Kirchhoff S, Keil L, Holzapfel B.M. Mono- versus polyaxial locking plates in distal femur fractures: A prospective randomized multicentre clinical trial. Int Orthop 2014; 38:857-63.
9. Pan X.H, Xiao D.M, Lin B.W, Huang G. Dynamic hip screws (DHS) and proximal femoral nails (PFN) in treatment of intertrochanteric fractures of femur in elderly patients. Chinese Journal of Orthopaedic Trauma. 2004; 6(7): 785-9.
10. Sehat K, Baker RP, Pattison G, Price R, Harries WJ, Chesser TJ. The use of long gamma nail in proximal femoral fractures. Injury. 2005;36(11):1350-54.
11. Fogagnolo F, Kfuri Jr M, Paccola C. Intramedullary fixation of pertrochanteric hip fractures with the short AO-ASIF proximal femoral nail. Arch Orthop Truama Surg. 2004; 124:31-37.
12. Uzun M, Erturer E, Ozturk I, Akman S, Seckin F, Ozcelik IB. Long term radiographic complications following treatment of unstable intertrochanteric femoral fractures with proximal femoral nail and effects on functional results. Acta Orthop Truamatol turc. 2009;43(6):457-63.
13. Takigami I, Matsuoto K, Ohara A, Yamanaka K, Naganawa T, Ohashi M. Treatment of trochanteric fractures with PFNA nails system- report of early results. Bull NYU Hosp Jt Dis. 2008;66(40):276-79.
14. Yaozeng X, Dechun G, Huilin Y, Guangming Z, Xianbin W. Comparative study of trochanteric fracture treated with proximal femoral nail antirotation and third generation of gamma nail. Injury. 2010;41(7):986-90.