e-ISSN: 0975-1556, p-ISSN:2820-2643

Available online on www.ijpcr.com

International Journal of Pharmaceutical and Clinical Research 2023; 15(2); 812-816

Original Research Article

Clinical Study of Visual Field Defects in Occipital Lobe Lesions

Tanushree V.[1], Deeksha Bekal[2], Madhuri P.[3], Ayesha Musthafa[4]

[1]Assistant Professor, Minto Ophthalmic Hospital, Bangalore Medical College and Research Institute, Bangalore, Karnataka, India.

[2]Senior Resident, Minto Ophthalmic Hospital, Bangalore Medical College and Research Institute, Bangalore, Karnataka, India.

[3]Senior Resident, Minto Ophthalmic Hospital, Bangalore Medical College and Research Institute, Bangalore, Karnataka, India.

[4]Junior Resident, Minto Ophthalmic Hospital, Bangalore Medical College and Research Institute, Bangalore, Karnataka, India.

Received: 05-12-2022 / Revised: 11-01-2023 / Accepted: 18-02-2023

Corresponding author: Dr. Tanushree V

Conflict of interest: Nil.

Abstract

Background: Visual field defect due to occipital lobe lesion can impair day-to-day activities and reduce the quality of life. Occipital lobe lesion usually do not cause neurological manifestation other than visual field defects. Hence visual field assessment is an important tool to localise the same.

Methods: All patients detected with occipital lobe lesions on neuroimaging were included in the study for a duration of one year. Visual field defects were examined on the Humphrey visual field analyser.

Results: Total 4 patients with occipital lobe lesions were studied. All 4 patients were males. Causes of occipital lobe lesion were head injury and stroke. Inferior altitudinal defect was seen in two patients. One patient had Homonymous inferior quadrantanopia and another patient had Homonymous hemianopia with superior quadrantanopia.

Conclusion: Uniqueness of this study, reports varied presentation of Visual field defects in Occipital lobe lesions which emphasises the importance of early and systematic evaluation for visual rehabilitation.

Keywords: Occipital Lobe, Visual Field Defect.

Introduction:

The occipital lobe is primarily responsible for vision. The visual field is represented in the striate cortex of occipital lobe based on Holmes map, in which each cerebral hemisphere's primary visual cortex(V1) receives information from contralateral visual hemifield. The peripheral visual field occupies the anterior striate cortex, while the macular region is represented posteriorly at the occipital pole. About 25% of the surface area of the striate cortex is assigned to central 15 degrees of vision. [1]

Damage to the occipital lobe can lead to complete or partial blindness depending on the location and severity of the damage. Vascular insults and traumatic brain injury are the common causes for occipital lobe damage. [2] Most common visual field defect produced by occipital lobe lesion is homonymous hemianopia field defect with macular sparing. [3,4] These defects

impair day-to-day activities like driving and reading which can affect the quality of life.[5] Often these defects are overlooked as patients learn to compensate for their deficit.

The purpose of this study is to report varied presentation of visual field defects caused by occipital lobe lesions which signifies the importance of early and systematic evaluation for visual rehabilitation.

Materials and Methods

A prospective study of 5 patients detected with occipital lobe lesions on neuroimaging who visited the outpatient department of tertiary eye care centre were included in the study for a duration of one year. This study was conducted after obtaining clearance by ethical committee.

After obtaining an informed consent from patients, a detailed history was documented. Patients were then subjected to detailed ophthalmic evaluation which included visual acuity recording with Snellens chart, refraction, anterior segment examination under slit lamp, posterior segment evaluation with fundoscopy. Detailed neurological evaluation done to look for any associated signs.

Location of the lesion on neuroimaging were noted. Visual field defects were examined on the Humphrey visual field analyser.

Results

Total 5 patients with occipital lobe lesions were studied. All 5 patients were males. Age distribution in our study varied from 30-65 years with majority of the cases from the age group 60-65 years.

Various causes of occipital lobe lesion were vascular insult which accounts to nearly 90% of all cases, followed by head injury (10%).

Lesions on neuroimaging included occipital lobe infarct in two patients (40%), parieto-occipital region infarct in two patients (40%) and temporo-occipital lobe ischemia in one patient (20%).

Out of 5 patients, inferior altitudinal defect was seen in two patients (40%) and homonymous inferior quadrantanopia seen in two patients (40%). One patient (20%) had homonymous hemianopia with superior quadrantanopia

.

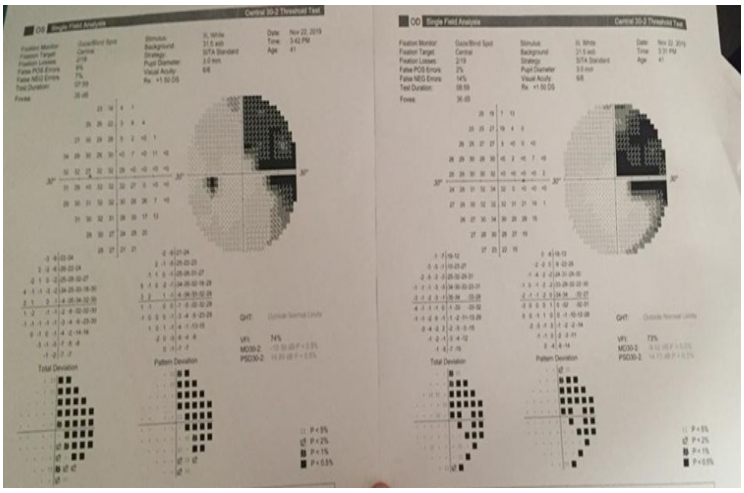

Figure 1: Case 1: 32year old male with right homonymous superior quadrantanopia

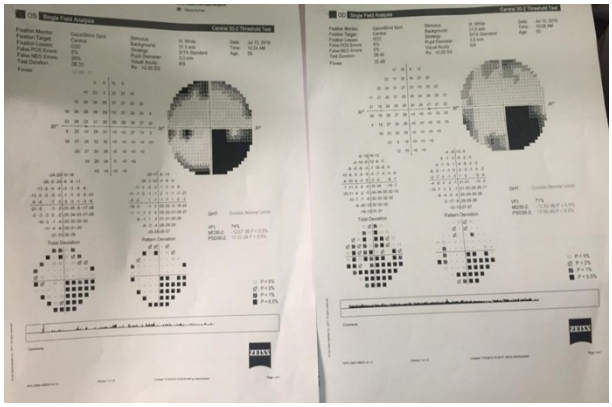

Figure 2: Case 2: 52year old male with inferior altitudinal defect

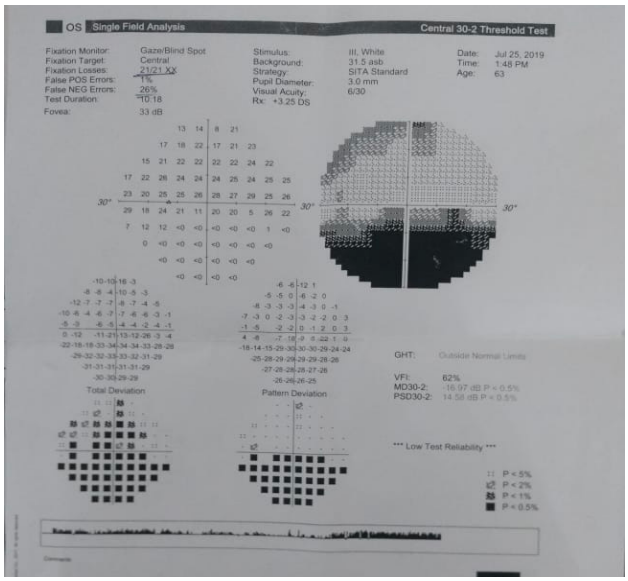

Figure 3: Case 3: 63year old male with right homonymous inferior quadrantanopia



Fig 4: Case 4: 65year old male with inferior altitudinal defect



Figure 5: Case 5: 60year old male with right homonymous inferior quadrantanopia

Discussion

Though homonymous hemianopia field defect with macular sparing is the most common field defect seen in occipital lobe lesion, our study reported other field defects like homonymous inferior quadrantanopia and inferior altitudinal defect. Vascular infarct was the most common cause of occipital lobe damage in our study.

Any patients with documented occipital lobe lesion should be referred to an ophthalmologist for screening neurological visual field loss by confrontation test and more detailed evaluation with automated perimetry.

Visual field defects affect the quality of life as it has an adverse functional effect on day-to-day activities like reading, reduction in mobility, impaired stereovision and most importantly impact on driving which may lead to legal issues. [6] Patients are at higher risk of falls due to bumping onto objects. Hence visual field testing is essential to recognise the defects and create awareness of the area of visual field loss. [7] Visual rehabilitation can be considered in these patients which may help retain independence and improve quality of life. [8]

Conclusion

The study reported varied presentation of visual field defects in occipital lobe lesions which included homonymous inferior quadrantanopia, inferior altitudinal defect and homonymous hemianopia. Commonest cause of occipital lobe lesion was vascular insult. Visual field loss can interfere with daily activities and lead to significant functional impairment. This study emphasises the importance of early detection of visual field defect for further assessment and consideration for visual rehabilitation.

References

1. Horton JC, Hoyt WF. The representation of the visual field in human striate cortex: a revision of the classic Holmes map. Archives of ophthalmology. 1991 Jun 1;109(6):816-24.
2. Zhang X, Kedar S, Lynn MJ, Newman NJ, Biousse V. Homonymous hemianopia in stroke. Journal of Neuro-ophthalmology. 2006 Sep 1;26 (3):180-3.
3. Korogi Y, Takahashi M, Hirai T, Ikushima I, Kitajima M, Sugahara T, Shigematsu Y, Okajima T, Mukuno K. Representation of the visual field in the striate cortex: comparison of MR findings with visual field deficits in organic mercury poisoning (Minamata disease). American Journal of Neuroradiology. 1997 Jun 1;18(6):1127-30.

4. McFadzean RM, Hadley DM, Condon BC. The representation of the visual field in the occipital striate cortex. Neuro-ophthalmology. 2002 Jan 1;27 (1-3):55-78.
5. Goodwin D. Homonymous hemianopia: challenges and solutions. Clinical Ophthalmology (Auckland, NZ). 2014;8:1919.
6. Margolis MK, Coyne K, Kennedy-Martin T, Baker T, Schein O, Revicki DA. Vision-specific instruments for the assessment of health-related quality of life and visual functioning. Pharmacoeconomics. 2002 Oct;20(12): 791-812.
7. Rowe F, Brand D, Jackson CA, Price A, Walker L, Harrison S, Eccleston C, Scott C, Akerman N, Dodridge C, Howard C. Visual impairment following stroke: do stroke patients require vision assessment? Age and Ageing. 2009 Mar 1;38(2):188-93.
8. Perez C, Chokron S. Rehabilitation of homonymous hemianopia: insight into blindsight. Frontiers in integrative neuroscience. 2014 Oct 22;8:82.