e-ISSN: 0975-1556, p-ISSN:2820-2643

Available online on www.ijpcr.com

International Journal of Pharmaceutical and Clinical Research 2023; 15(2); 817-823

Original Research Article

Clinical Study of Carotid Cavernous Fistula in a Tertiary Care Centre

Tanushree V.[1], Ashwathi M.[2], Madhuri P.[3], Ayesha Musthafa[4]

[1]Assistant Professor, Minto Ophthalmic Hospital, Bangalore Medical College and Research Institute, Bangalore, Karnataka, India.

[2]Senior Resident, Minto Ophthalmic Hospital, Bangalore Medical College and Research Institute, Bangalore, Karnataka, India.

[3]Senior Resident, Minto Ophthalmic Hospital, Bangalore Medical College and Research Institute, Bangalore, Karnataka, India.

[4]Junior Resident, Minto Ophthalmic Hospital, Bangalore Medical College and Research Institute, Bangalore, Karnataka, India.

Received: 20-12-2022 / Revised: 17-01-2023 / Accepted: 19-02-2023

Corresponding author: Dr. Tanushree V

Conflict of interest: Nil.

Abstract

Background: CCF is the most common arterio-venous malformation affecting orbit. Hunter in 1757 was the first physician to report the arteriovenousfistula. Benjamin Travers, in 1809, described the first case of unilateral pulsatile exophthalmos probably resulting from CCF. CCF is the abnormal communication between cavernous sinus and carotid arterial system resulting in rise in pressure in sinus and structures draining to it.

Materials and Methods: Nine patients who presented to our tertiary care centrewith symptoms suggestive of Carotid Cavernous Fistula, between January 2019 to March 2020 were subjected to a structured ophthalmic evaluation. All patients clinically diagnosed with CCF underwent imaging of brain with bilateral orbits and were referred to neurology team for further management. Patients were followed up subsequently.

Results: Out of nine patients, seven developed CCF secondary to trauma and 2 patients had spontaneous CCF. Patients presented with diminution of vision, pulsatile proptosis, cork screwing of vessels, restricted eye movements, secondary glaucoma, corneal oedema and orbital bruit. CT orbit and brain with Contrast CT angiography was done in all patients. Eight patients underwent endovascular embolization with coiling.

Conclusion: Carotid cavernous fistula is a rare and sight threatening condition with or without a history of trauma.

Introduction

Carotid Cavernous Fistula is an abnormal communication between arteries and veins within the cavernous sinus. Case reports of carotid cavernous fistula started appearing in literature from 1930's, even-though the pathogenesis was less understood. Major insight towards pathogenesis was first provided by Barrowet alin 1985, who classified CCF into four arteriographic types with respect to communication. [1] Type A of Barrow's classification was Direct CCF and rest were all Dural CCF. CCF is considered Direct CCF, when the fistula is formed due to a defect in the wall of Internal Carotid Artery or its branches within the cavernous sinus. Dural CCF

occurs due to a fistula between cavernous sinus and meningeal branches of Internal Carotid Artery (ICA) or External Carotid Artery (ECA). [2] The pathogenesis of latter is less studied. Miller had described two different theories for development of dural CCF. First, dural CCF developing due to rupture of thin-walled dural arteries and second theory being spontaneous development of fistulas as a response to cavernous sinus venous thrombosis for providing a bypass venous outflow. Second theory is more accepted, as it correlates clinically. Dural CCF is more common in patients with increased risk of thrombosis such as pregnancy, hypertension, atherosclerosis, connective tissue disease. [3]

The importance of an ophthalmologist in CCF management lies in the fact that, these patients usually present with ocular features like conjunctival chemosis, pulsatile proptosis, diplopia, ophthalmoplegia, orbital pain, audible bruits and blindness. These features can be misdiagnosed as manifestations of more common diseases such as thyrotoxicosis, conjunctivitis, orbital cellulitis, and orbitalpseudotumor. [4,5] Hence this study, attempts to consolidate the ophthalmic manifestations of CCF and help front line ophthalmologists to suspect, promptly diagnose and manage this sight threatening rare condition.

Aims and Objectives

To study the ophthalmic manifestations of patients with carotid cavernous fistula (CCF).

Materials and Methods

Inclusion Criteria

1. patients presenting with acute or subacute onset of unilateral proptosis, following trauma
2. any patient with pulsatile proptosis
3. patients with proven carotid cavernous fistula

Exclusion Criteria:

1. Patients who did not consent for detailed evaluation required for study
2. Patients who had unstable vitals, severe systemic symptoms (severe headache, vomiting or seizures), or very sick

Methodology

A hospital based prospective study was conducted on nine patients presenting to Ophthalmology outpatient department of our hospital from January 2019 to march 2020. All patients were subjected to a series of examination as follows;

1. Clinical history with special emphasis to trauma, and pro thrombotic conditions such as hypertensive disorders, history of ischemic heart disease, stroke, pregnancy, DVT, and any embolic events
2. Visual acuity using Snellen's chart. Refraction and correction whenever required
3. Ocular posture, head posture
4. Anterior segment evaluation: lid and adnexa, conjunctiva, cornea, anterior chamber, iris, pupil and lens.
5. Intra-ocular pressure measurement using Goldman's Applanation Tonometer.
6. Fundus examination using 90D and 20D (IDO) lens
7. Extra ocular movements
8. Proptosis evaluation in those who presented with proptosis, including examination using applanation tonometer to look for pulsatile proptosis
9. Auscultation using Bell of stethoscope for any ocular bruit.

All patients clinically suspected with carotid cavernous fistula were subjected to CT Brain with orbits, and CT angiography of brain. All cases were promptly referred to neurologist for further management.

Results

Out of nine participants, seven were males and two were females (Table 1). Out of

nine participants seven had history of trauma (Table 2). Two females who presented with CCF gave no history of trauma, and were in post-menopausal age group, and were on treatment for hypertension and type 2 diabetes mellitus.

All nine patients had chemosis and corkscrewing of vessels. Eight had pulsatile exophthalmos. Seven patients had diminution of vision, while only six had headache. Six patients had audible bruit.Extra ocular movement restrictions; secondary glaucoma and corneal oedema were found in five patients. Fundus changes were noted in five patients and all of them had hyperemic disc with engorged retinal veins. Of them, only one patient had frank disc oedema (Figures 1, 2, 3, 4).

In all nine patients CCF was confirmed with CT orbit and brain with CT angiography. Most common findings in CECT were axial proptosis, prominent superior ophthalmic vein and enlarged cavernous sinus on the affected side (figures 5, 6). Except one female who presented with spontaneous CCF with an indolent course, everyone else underwent conventional angiographic embolization with coiling. One patient with spontaneous CCF was managed conservatively with anti-coagulants, antibiotics along with treatment of systemic hypertension and diabetes mellitus (Table 3, Figure 7).

On follow up after one month, out of seven patients with diminution of vision, four patients had improvement in BCVA with two patients ultimately regaining 6/6 vision. But three patients had no improvement even after treatment

Table 1: Gender distribution

Sex	No.	%
Males	7	80
Females	2	20

Table 2: Aetiology of CCF

Aetiology	No.	%
Traumatic CCF	**7**	**80**
Spontaneous CCF	**2**	**20**

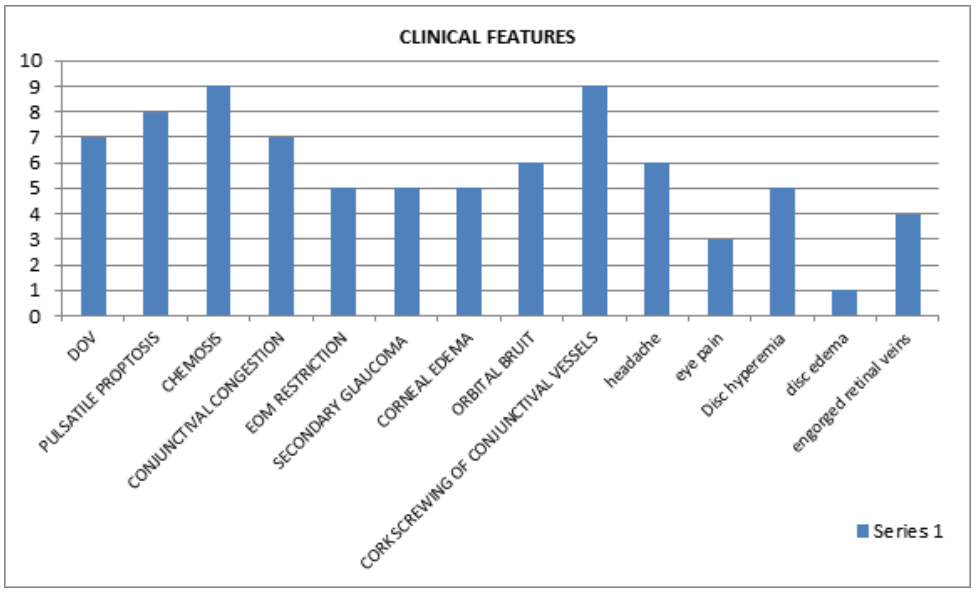

Figure 1: Clinical features of participants

Table 3: Treatment given

Treatment	No.	%
Embolisation with coiling of aneurysm	8	90
Conservative management	1	10

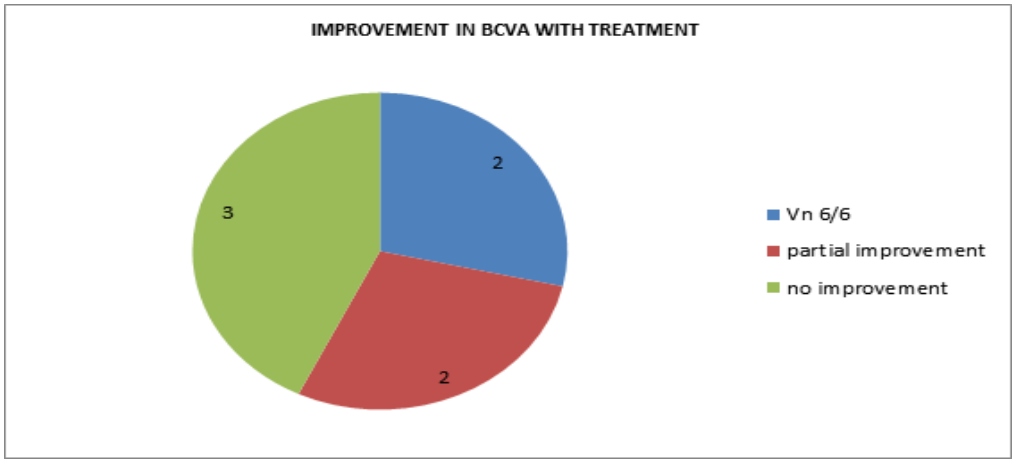

Figure 2: Improvement in BCVA with treatment

Figure 3: Axial proptosis, cork screwing of conjunctival vessels in a patient with traumatic CCF

Figure 4: Chemosis, conjunctival congestion, EOM restriction in a patient with spontaneous CCF

Figure 5: Chemosis, EOM restriction

Figure 6: CT angiography report of patient with spontaneous CCF Filling of cavernous sinus noted during arterial phase with dilatation of right superior ophthalmic vein. Features suggestive of direct carotid cavernous fistula on right side

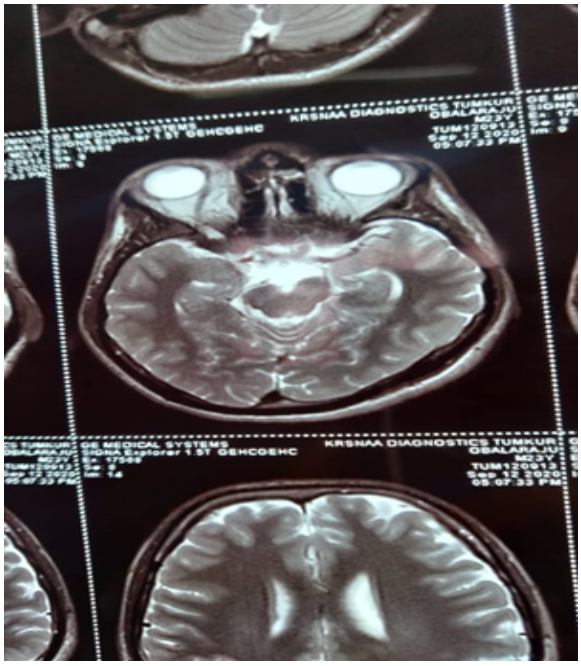

Figure 7: CECT of a patient with traumatic CCF: The film shows axial proptosis with and prominent superior ophthalmic vein and prominent cavernous sinus of right eye.

Discussion

Carotid Cavernous Fistula is a sight threatening condition which involves an abnormal communication between cavernous sinus and any of the following vessels: Internal Carotid Artery, its intra sinus branches, and dural branches of ICA, ECA or both. [6]

Our study found out that the overall incidence of CCF is more common in males, while spontaneous CCF is common in females. Most of the fistulas developed secondary to trauma and were direct. Spontaneous fistulas develop more commonly in those at risk for vascular thrombosis such as hypertensive or diabetic vascular diseases. Also, due to the same reason, it is more common in females who attained menopause. [7]

Most common clinical feature of CCF in our study was conjunctival chemosis, cork screwing of vessels and pulsatile proptosis. Similar features can also be found in severe conjunctivitis, thyrotoxicosis, orbital cellulitis and orbital pseudotumour. Diminution of vision was not universal, and was found only in seven patients. Six patients complained of non-specific headache. Telltale sign described; audible bruit was found only in five patients. These emphasise the importance of maintaining high index of suspicion while dealing with these patients. [8]

Main complications of the condition noted in these patients were acute rise in IOP and corneal oedema. Hyperaemic optic discs and engorgement of retinal veins were also noted in 5 patients, out of which one had frank disc oedema. This is suggestive of increases back pressure and correlates with the CECT finding of enlarged superior ophthalmic vein (SOV). Prompt measures to reduce IOP are invaluable in restoring vision, and appropriate anti-glaucoma medications should be started without waiting for management of fistula.

Our study showed that CECT with CT angiography helps in confirming the diagnosis of CCF in all patients. Most of our patients underwent radiological interventions such as embolization of fistula with coiling of the artery. Hence, the importance of coordination with neurosurgical and interventional radiology departments. On following up the patients after one month of receiving treatment, four out of seven patients with visual impairment had improvement in BCVA, while three had little improvement.

Main limitation of our study was the rarity of the condition. CCF needs multi-speciality management, which required the referral of patients to higher centres. This limited the follow up of some patients.

Conclusion

Most common cause of CCF in our study was trauma. Most common ophthalmic findings of CCF were chemosis, cork screwing of vessels, and pulsatile exophthalmos. Other classical clinical features such as diminution of vision, conjunctival congestion and audible bruit are not mandatory. Visual acuity might not improve even after standard of care treatment; therefore patients should be counselled accordingly. High index of suspicion should be maintained in patients presenting with even milder symptoms, especially if associated with trauma for early diagnosis and treatment of this rare but sight threatening condition.

References

1. Barrow DL, Spector RH, Braun IF, Landman JA, Tindal SC, Tindal GT. Classification and treatment of spontaneous carotid-cavernous sinus fistulas. J Neurosurg 1985;62:248-56.
2. Doran M. Carotid-Cavernous Fistulas: Prompt Diagnosis Improves Treatment. AAO. 2008
3. Miller NR. Diagnosis and management of dural carotid–cavernous sinus

fistulas. Neurosurg Focus 2007;23(5):E13
4. Stanton DC, Kempers KG, Hendler BH, Cutilli BJ, Hurst RW. Posttraumatic carotid-cavernous sinus fistula. J Craniomaxillofac Trauma. 1999;5:39–44
5. Das JK, Medhi J, Bhattacharya P, Borah N, Bhattacharjee K, Kuri GC, Deka H, Goswami BJ. Clinical spectrum of spontaneous carotid-cavernous fistula. Indian J Ophthalmol 2007;55:310-2
6. Gemmete, J.J., Chaudhary, N., Pandey, A. et al. Treatment of Carotid Cavenous Fistulas. Current Options Neurol (2010) 12: 43.
7. Chaudhry IA, Elkhamry SM, Al-Rashed W, Bosley TM. Carotid cavernous fistula: ophthalmological implications. Middle East AfrJ Ophthalmol. 2009;16(2):57–63.
8. Brad Bowling Knaski'S Clinical Ophthalmology-A Systemic Approach. 8th edition, chapter 3:93-95