e-ISSN: 0975-1556, p-ISSN:2820-2643

Available online on www.ijpcr.com

International Journal of Pharmaceutical and Clinical Research 2023; 15 (2); 1051-1063

Original Research Article

To Study the Clinical Profile Evaluation and Management of the Patients with Retrocaval Ureter

Sharanabasappa Rudrawadi[1], Nagabhushana M[2], Keshavamurthy R[3], Gaurav Kochhar[4]

[1]Assistant Professor, Dept of Urology, Sri Aurobindo Institute of Medical Science Indore (M.P)

[2]Professor, Dept of Urology, Institute of Nephro Urology Victoria Hospital Campus Bangalore (Karnataka)

[3]Director and HOD and Professor, Dept of Urology, Institute of Nephro Urology Victoria Hospital Campus Bangalore (Karnataka)

[4]Associate Professor, Dept of Urology, MMIMSR, Mullana, Haryana.

Received: 27-12-2022 / Revised: 29-01-2023 / Accepted: 17-02-2023

Corresponding author: Dr. Gaurav Kochhar

Conflict of interest: Nil

Abstract

Introduction: A rare venous congenital malformation known as the retrocaval ureter (RCU), circumcaval ureter, or postcaval ureter is connected to aberrant embryological development of the inferior vena cava rather than ureter development. It was first thought to be an anomaly in the development of the ureter, but various investigations in embryology have led to the realization that it is actually an anomaly in the formation of the inferior vena cava.

Methodology

- **Study period:** 2007-2016.
- **Site of the study:** Institute of nephro-urology- Bangalore.
- **Sample size:** 14 symptomatic patients were treated for retrocaval ureter at our institute .

Results: There were 14 symptomatic patients with retrocaval ureters. The patients' average age was 31.71 years (range, 18 to 54 years). Three patients were female and eleven patients were men.

Conclusion: Adults with RCU rarely experience upper urinary blockage. Although open surgical exploration is still a prevalent procedure for RCU, laparoscopy has recently gained popularity due to its safety, efficacy, and practicability.

Keywords: Retrocaval Ureter, Laproscopic, Postcaval Ureter.

Introduction

Retrocaval ureter(RCU) or circumcaval ureter or postcaval ureter is a rare venous congenital anomaly related to abnormal embryological development of inferior venacava rather than ureter development .It was initially considered as aberration in ureteric development; however several studies in embryology have led to it being considered as an aberration in the development of the inferior vena cava .The anomaly is usually observed on right side with male preponderance , although left sided circumcaval ureter has been reported in association with a duplicated IVC or in

association with situs inversus .In symptomatic cases, surgical intervention is often required.[1,2] Retrocaval ureter may lead to extrinsic obstruction of the ureter. Although commonly referred to as circumcaval or retrocaval ureter, a more appropriate term may be preureteral vena cava, because it is due to a congenital abnormality in development of the vena cava. The term retrocaval is now primarily used to describe ureters that simply course behind the IVC and reemerge laterally. Formation of the infrahepatic vena cava is based upon the development and regression of three pairs of embryonic veins: the posterior cardinal, the supracardinal, and the subcardinal. It is postulated that the normally developed IVC results from persistence of the right subcardinal vein suprarenally and the right supracardinal infrarenally. The posterior cardinal veins persist as the common iliac veins. The anastomosis between the right subcardinal and supracardinal vein crosses anterior to the fetal ureter. In normal development, this connection regresses, and the supracardinal vein persists as the infrarenal IVC. In retrocaval ureteric anomaly, ureter deviates medially and passes behind the inferior vena cava (IVC), winding around and crossing in front of it from medial to lateral side. It was first reported by Hochstetler in 1893.1 The incidence of retrocaval ureter is one in 1500 cadavers; male to female ratio is 3 or 4:1.Most patients present with right lumbar pain.[18-20]

Methodology

- **Study period:** 2007-2016
- **Site of the study:** Institute of nephro-urology- Bangalore
- **Sample size:** 14 symptomatic patients were treated for retrocaval ureter at our institute .
- **Method of data collection:** The medical history, physical examination, standard tests, radiographic investigation, therapy modality, and treatment outcome were all gathered retrospectively from the hospital records
- The definite diagnosis was made by IVU/CT KUB and retrograde pyelography.
- All patients were symptomatic and had undergone surgery.
- Intravenous urography/renal scan had been performed for all patients 6 months postoperatively

Results:

There were 14 symptomatic patients with retrocaval ureters . The patients' average age was 31.71 years (range, 18 to 54 years). Three patients were female and eleven patients were men.

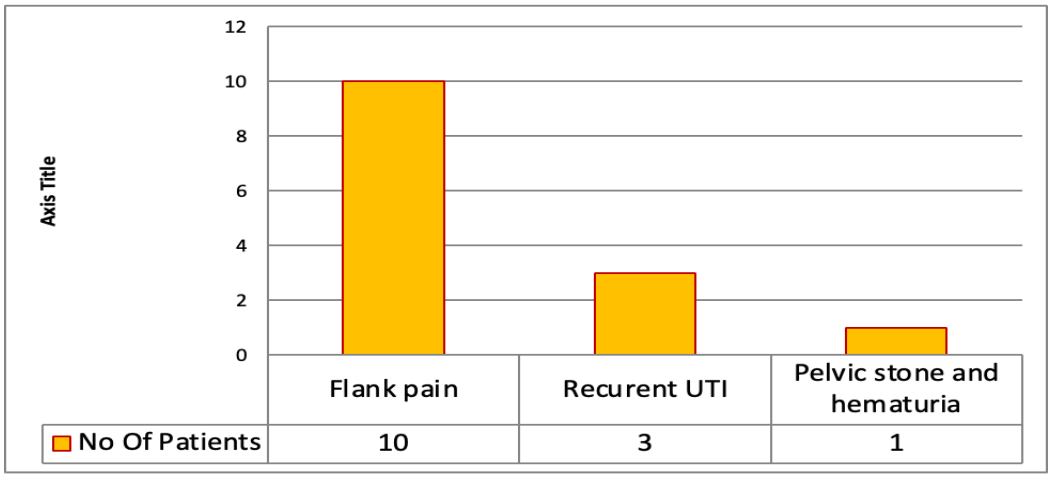

No abnormality was found on physical examination. Complete laboratory evaluation including urinalysis, complete blood count and renal profile were within

normal limits. Diagnosis of retrocaval ureter was made on Intravenous urogram (IVU), retrograde urography and contrast enhanced CT scan by demostrating typical S-shaped or sickel shaped deformity of ureter associated with moderate hydronephrosis and diated proximal ureter.13 Patients were type 1 right-sided retrocaval ureter and 1 patient had left retrocaval ureter with situs inversus

IVP/CECT KUB

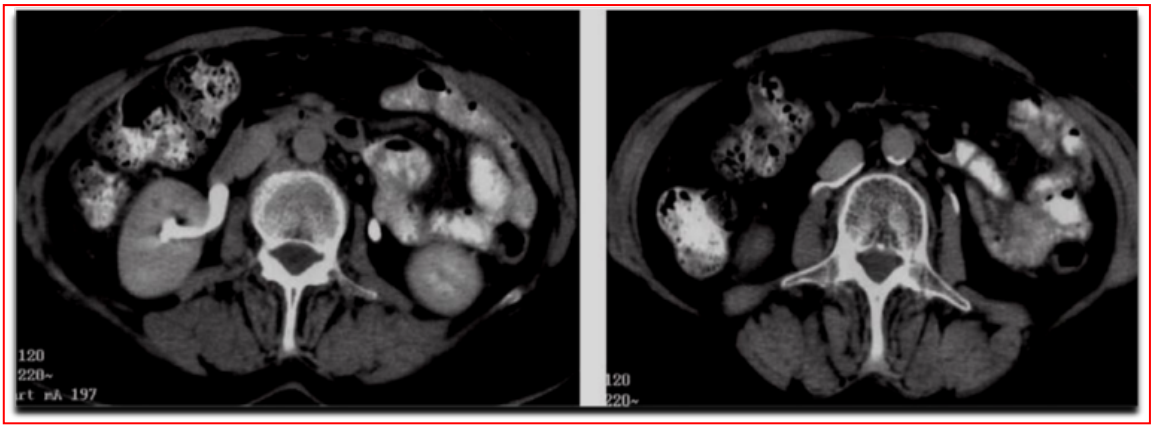

Surgical Methods

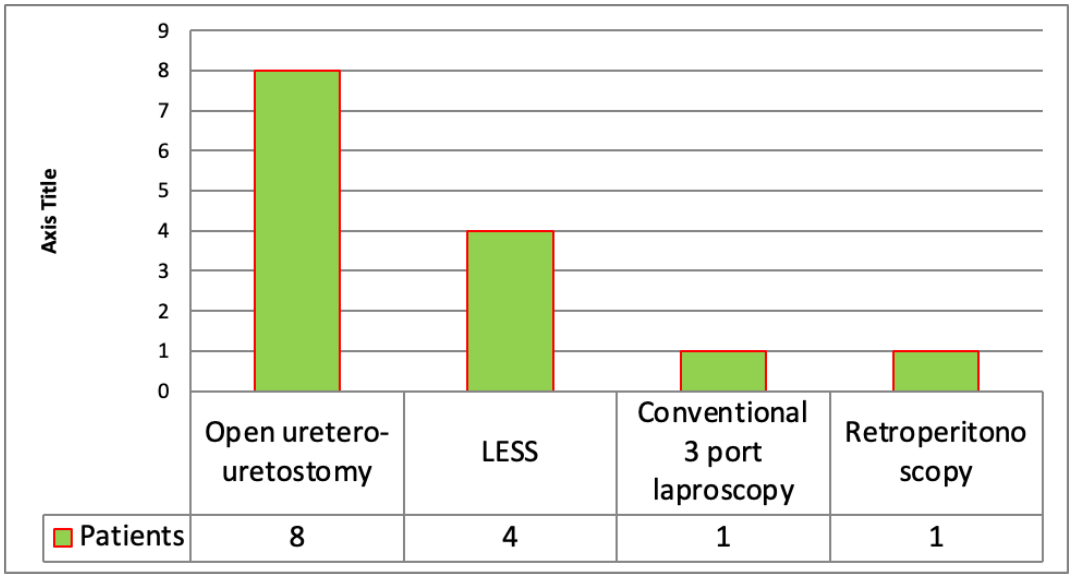

The patient was explored by right lumbar incision. Intraoperatively, dilated right upper ureter was seen compressed, while crossing behind inferior vena cava. The lower ureter was normal in caliber. After meticulous dissection and mobilization, the compressed and a dynamic ureteral segment, behind inferior vena cava was excised. The ureteral continuity was restored by ureteroureterostomy after proximal and distal spatulation and DJ stenting. The incision was closed in layers after keeping a tube drain.

Conventional Transperitoneal Laproscopy

The patient received general anaesthesia. The No. 16Fr size Foley catheter was inserted. The patient was positioned on his or her flank. Carbon dioxide insulation and a Veress needle were used to create a pneumoperitoneum. Three ports were used: a primary port measuring 10 mm at the umbilicus, a secondary port measuring 5 mm at the anterosuperior iliac spine, and a third port measuring 5 mm at the medial costal border. The ascending colon was then reflected medially, followed by the incision of the line of Toldt. It was discovered that the ureter was coursing posterior to the inferior vena cava after the retroperitoneum had been exposed. The dilated ureter was located and removed through the IVC's lateral border. The retrocaval portion was dissected out and excised then an intracorporeal suture was used to close a ureteroureterostomy with DJ Stenting that required 4.0 vicryl.

Laproendoscopic Single Site Incision: Less

The right side umbilicus was cut in a 2.5–3 cm semicircular incision. At the umbilicus, a 10mm standard laparoscopic port was inserted. In order to stop pneumoperitoneum leaking, two more 5mm laparoscopic ports were then inserted through the same incision next to the existing umbilical port. However, these ports entered the rectus sheath separately.

Retroperitoneal Laparoscopy

A three-port strategy was used. After making a 1.5 cm transverse incision in the mid-axiallary line beneath the tip of the 12th rib, which was deepened by splitting the muscle with a hemostat and then by finger dissection, the retroperitoneal space was created. It was then widened by using a self-made dilator made from a surgeon glove inflated with normal saline. CO_2 insufflation was used to produce and sustain pneumoretroperitoneum. After that, endoscopic viewing of the retroperitoneum was performed using the 10mm telescope. The proximal ureter curled medially, then posteriorly, then anteromedially to the infra vena cava IVC before taking a downward route. A 5 mm port was created close to the anterior superior iliac spine at a distance of 1 cm, and a second 5 mm port was created in the renal angle. The ureter was mobilised, divided across the dilated upper end, the retrocaval stenosed section was removed, and after placing a double "J" stent laparoscopically, it was anteriorized and an end-to-end ureterouretrostomy was performed. Near the end of the 12th rib, the major 10-mm port is positioned inferiorly. 3 cm cephalad from the iliac crest, an anterior 05-mm port is positioned close to the anterior axillary line. At the intersection of the lateral border of the paraspinal muscles and the 12th rib, a posterior 5-mm port is positioned. Blunt dissection was initially used to create the retroperitoneal space, then conventional method was used for the remainder of the treatment.

Operative images

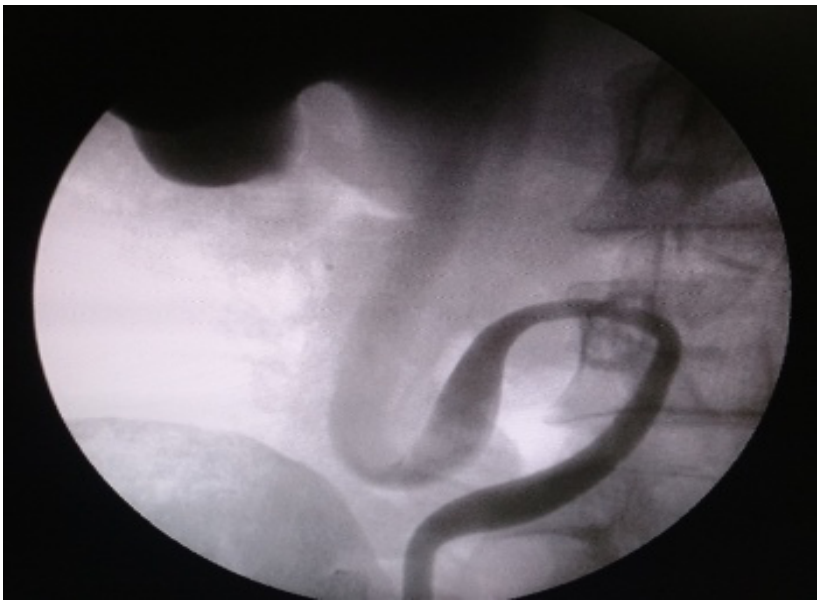

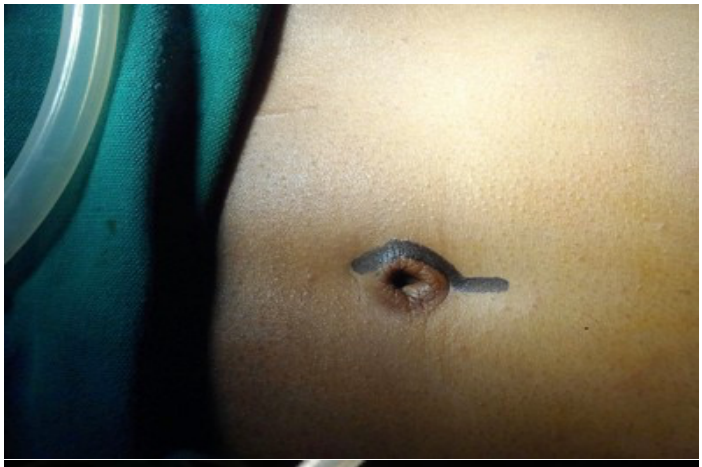

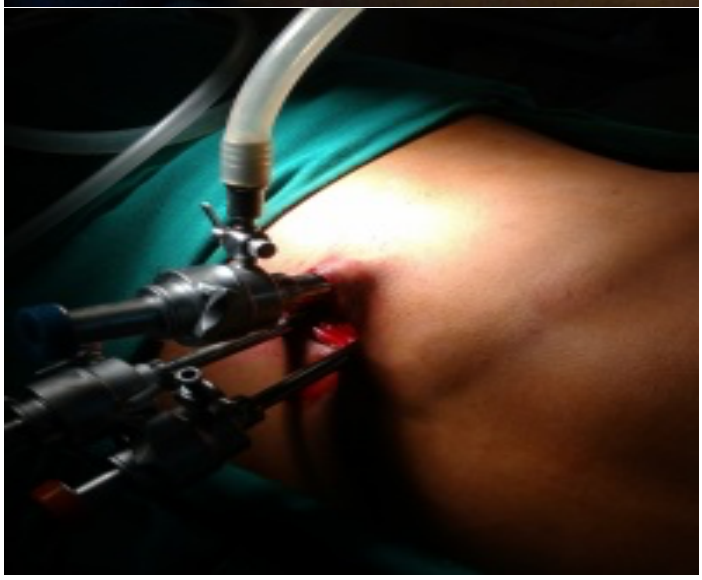

Analgesic Reqirement

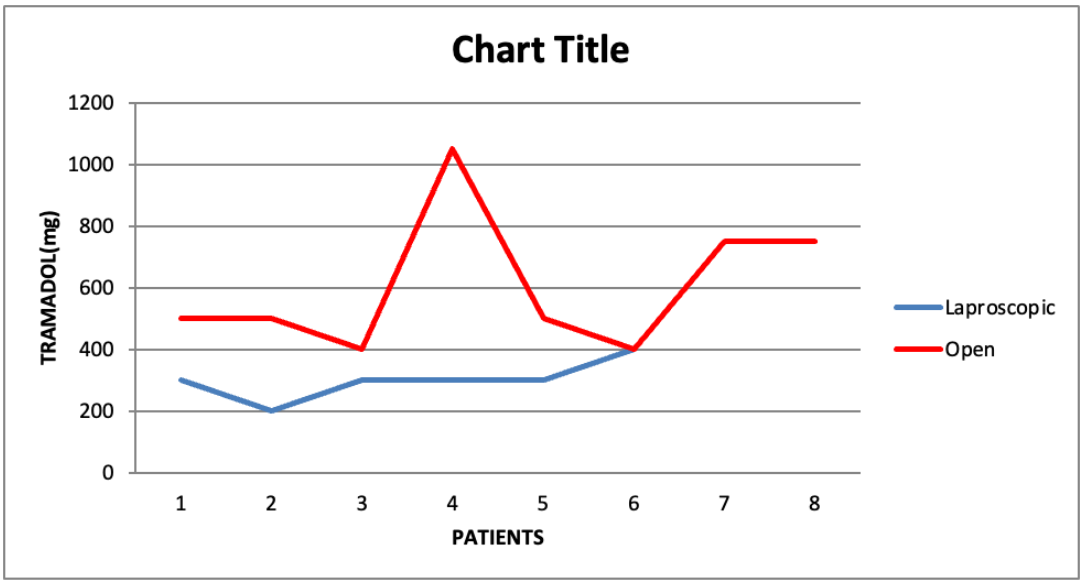

Hospital Stay

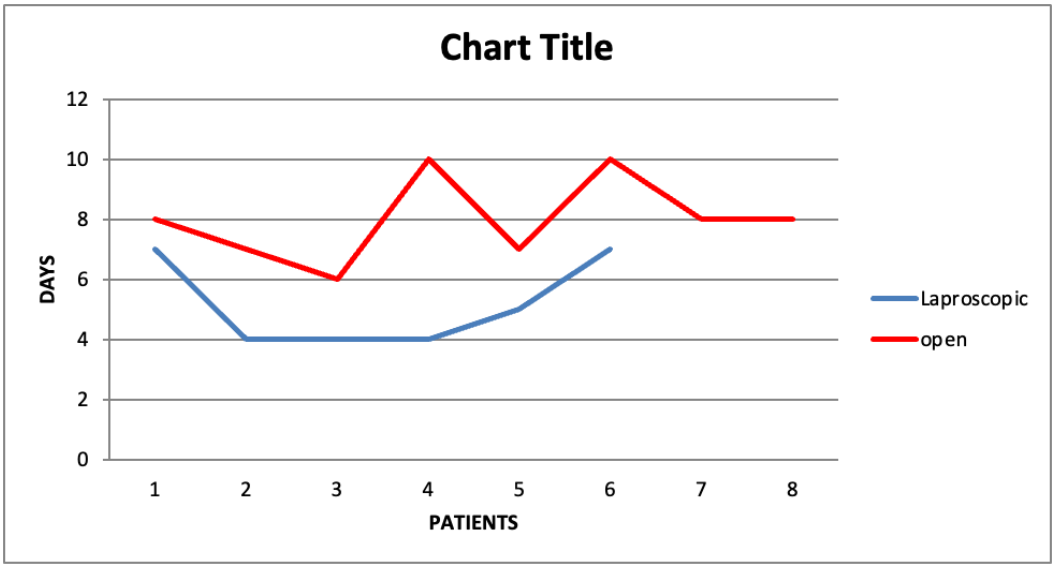

Procedure	Mean Operting Time	Mean Analgesic Reqirement	Mean Hospital Stay
LAPROSCOPIC	162.5 ±22.7	275±41.8	5.1±1.47
Open	120±22.03	537±115.7	8±1.4

All patients underwent double J stenting, which was removed in both groups after 4-6 weeks. Four patients had postoperative problems, two in each group, including urinary leak and fever in LP and surgical site infection in OP. These complications were conservatively treated. At six months, all patients had reviews with positive outcomes, including symptom-free status and a decline in hydronephrosis.

Open technique

Mean operating time -120 ± 20.03min

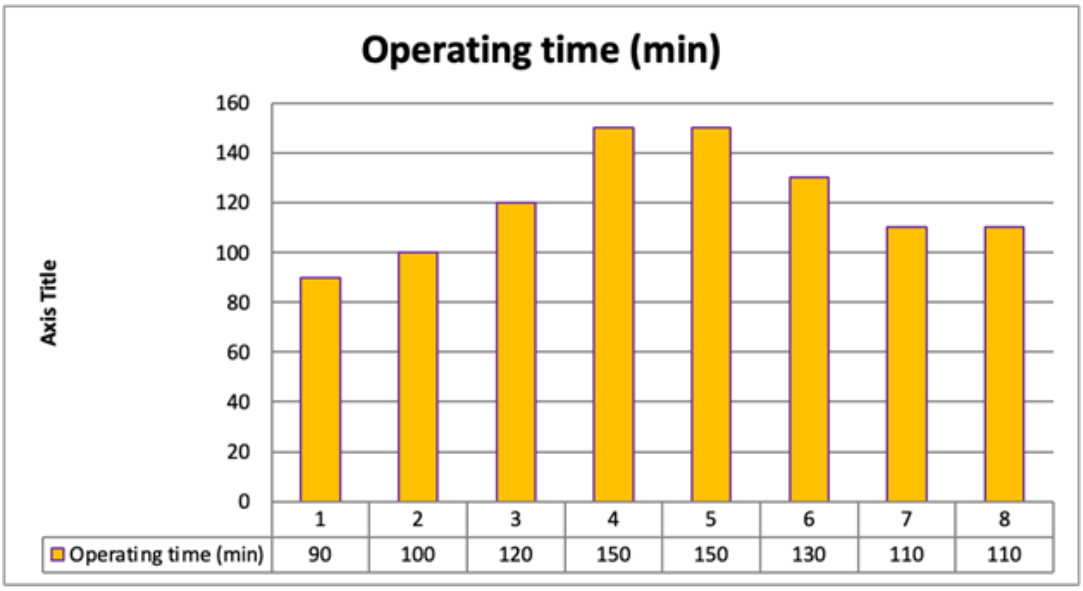

Minimal invasive technique
Post operative analgesic (tramadol) requirement - 275 ± 41.8

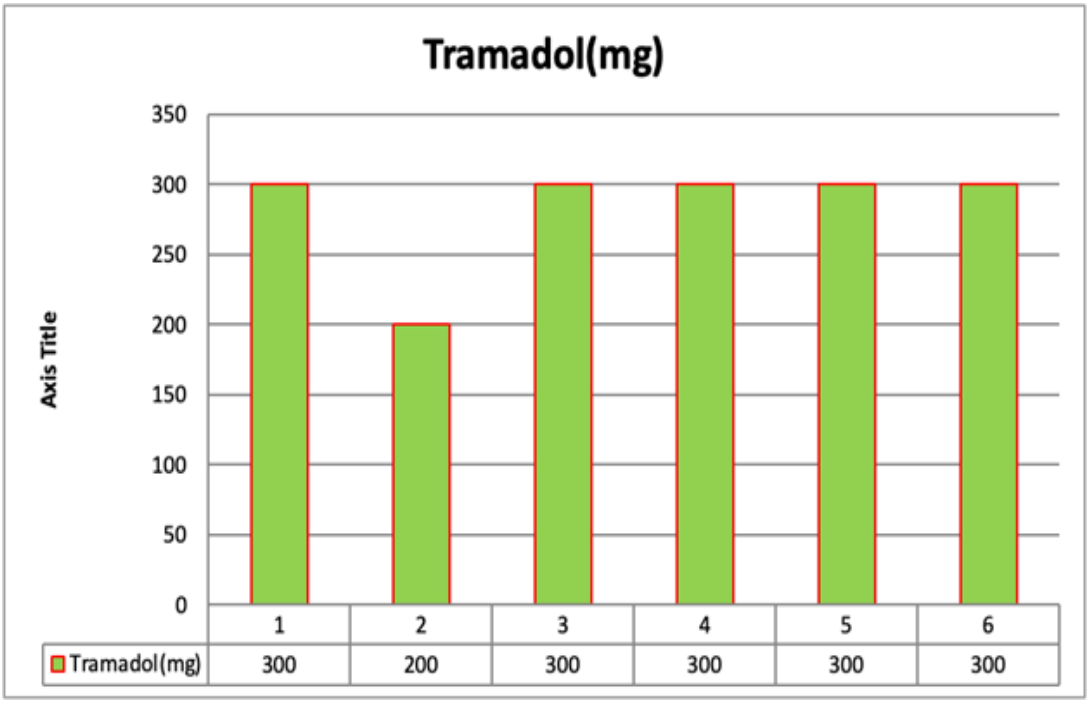

Minimal invasive technique

Mean hospital stay - 5.1± 1.47 (range 2-7 days) and in OP was 8 ± 1.4(range 5-10 days)

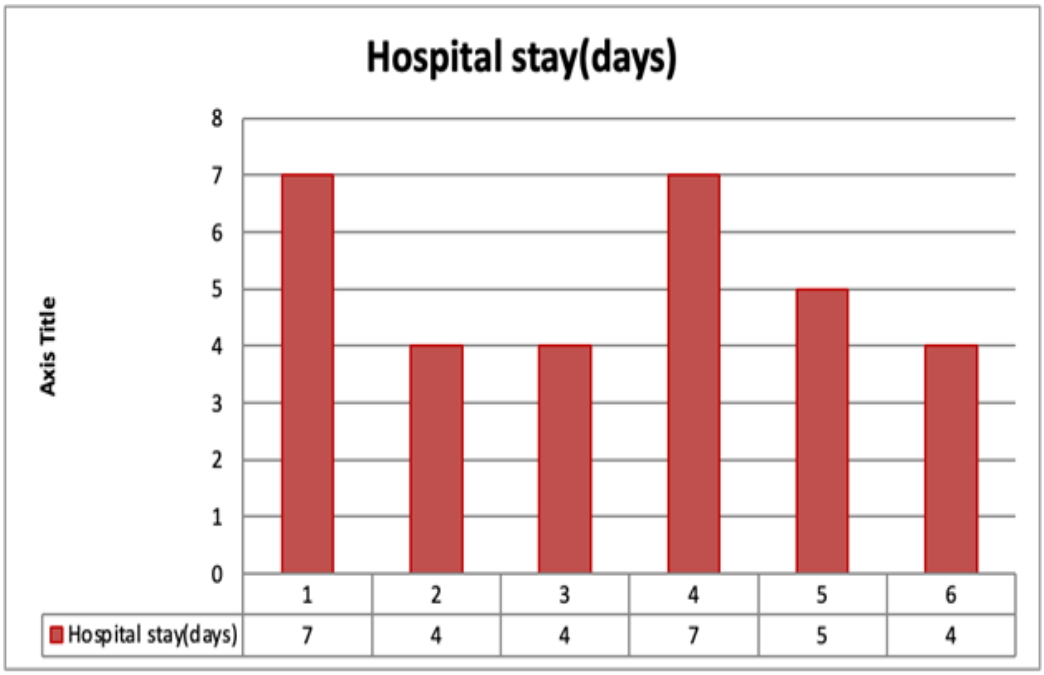

Open technique

Mean hospital stay - 8 ± 1.4 (range 5-10 days)

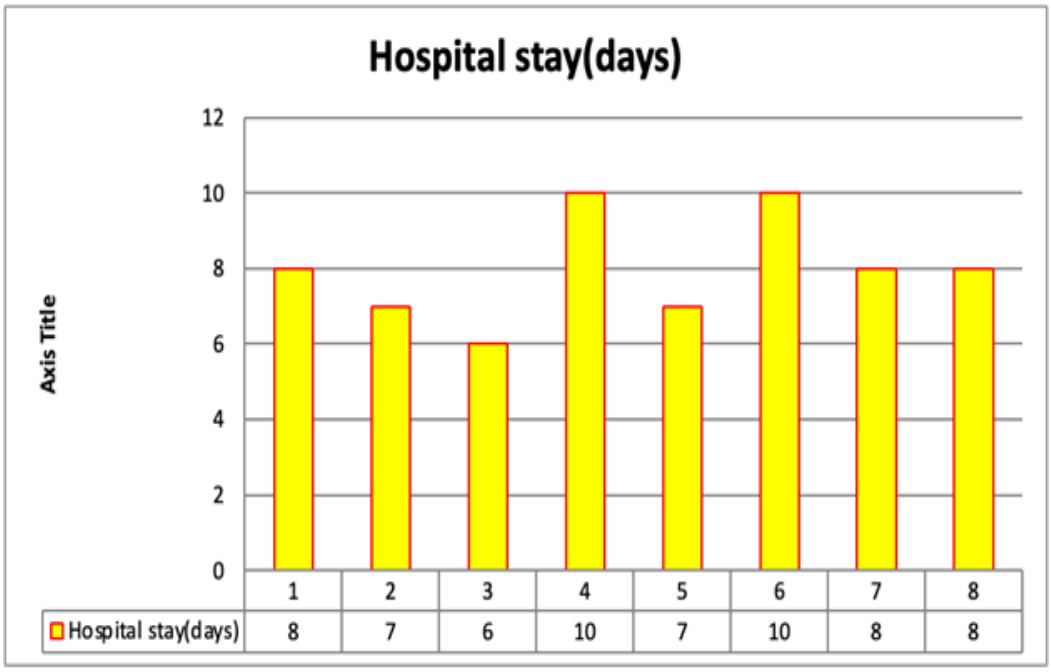

Open technique

Post operative analgesic (tramadol) requirement -537±115.7 mg

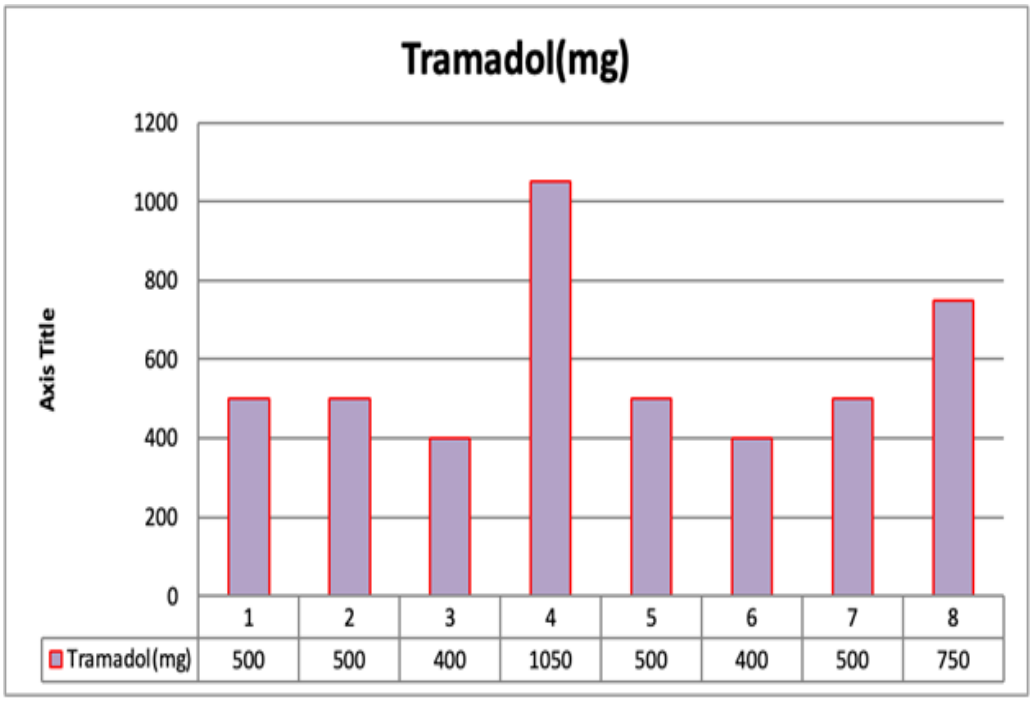

Minimal invasive technique

Mean operating time -162.5 ± 22.50 min

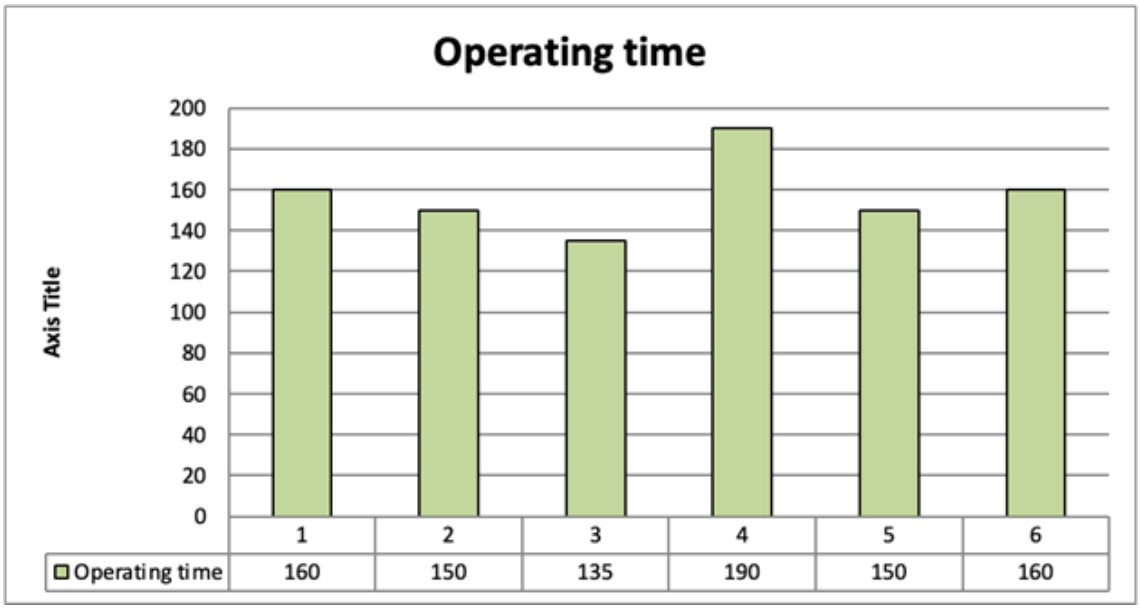

Discussion

Hochstetter published the first description of the retrocaval ureter in 1893, commonly known as the circumcaval ureter. IVC often arises from the veins that are inferior and superior to the kidney, respectively, the supramarginal and sub cardinal veins. If the subcardinal vein creates the inferior vena cava (IVC), it will be placed anterior to the ureter and create a retrocaval ureter. Depending on its radiological appearance and the location of ureteral constriction, the retrocaval ureter was divided into two categories by Bateson and Atkinson. In type 1, the ureter has an S-shaped malformation and crosses behind the inferior vena cava at the third lumber vertebra. Also known as a low loop retrocaval ureter, which 50% of the time has a significant hydronephrosis.

Retrocaval segment is at the same level as the renal pelvis in type 2. Also referred to as a high loop, mild hydronephrosis has a lower incidence than type 1. All of our patients had type 1 retrocaval ureter patterns in radiographic investigations. Retrocaval ureters are typically right-sided, however they can occasionally be left-sided due to situs inversus or IVC duplication. 13 participants in our study had retrocaval ureters on the right side and one patient had situs inversus and RCU on the left side. Only eight examples of the unusual condition known as left retrocaval ureter have been documented in the literature thus far. Left retrocaval ureter linked with situs inversus was reported by Brooks RE, Jr. et al. Left retrocaval ureter coupled with inferior vena caval duplication was observed by Rubinstein I, Cavalcanti, et al. Left retrocaval ureter was reported by Vasudevan Thirugnanasambandam et al. and Gramegna V, Madaro A et al. in conjunction with a persisting left vena cava. According to reports, up to 21% of retrocaval ureter anomalies are associated with the cardiovascular and urogenital systems, with the most common ones being the horseshoe kidney, ureteropelvic junction blockage, congenital absence of the vas deferens, kidney agenesis, and Goldenhar syndrome. These aberrations weren't present in any of our patients. When there are indications of obstruction in the form of symptoms or signs, the retrocaval ureter should be surgically treated. The most common and effective treatment is open surgery. A retrocaval ureter underwent the first successful open dismembered pyeloplasty, which was described by Anderson and Hynes in 1949. The area of urology has expanded the indications for this treatment thanks to the advancement of laparoscopy and urologists' performing abilities. Baba et al. performed the first laparoscopic repair, a ureteroureterostomy, in 9 hours and 20 minutes, with an anastomosis taking 2.5 hours and 5 laparoscopic ports. It is possible to employ either the transperitoneal or retroperitoneal technique. Salomon et al. reported the first case of exclusively retroperitoneal laparoscopic repair of a circumcaval ureter in 1999, suggesting that the more direct approach to the urinary tract in this patient was through retroperitoneal laparoscopy. An continuing endeavour has been made to create a more "minimally intrusive" method of surgery since since the invention of laparoscopic surgery. Laparoendoscopic single site (LESS) surgery is a cutting-edge illustration of such an innovation. A single little incision may be made at the entry location rather than the customary four to five. The small incision is used to insert all surgical tools, and it is situated in the left umbilicus or abdomen. Nevertheless, because LESS calls for operating three articulating devices through a single access channel, it is acknowledged to be a more challenging process. To perform safe singl report surgery, it is evident that experienced laparoscopic skills are required. Theoretically, LESS has advantages over traditional multi-incision laparoscopy, including better cosmesis, less pain, and quicker recovery. Autorino et al. (2010) documented the first successful instance of laparoendoscopic single-site surgery (LESS) repair of retrocaval ureter, which had a nearly scar-free outcome. The surgical time was three hours, which is comparable to the average laparoscopic procedure time. [3-18]

Study	No of cases	Approach	Procedure	Mean Operating time(min)	Hospital stay
Baba et al. (1994)	1	Conventional Transperitoneal	Pyeloplasty	560	Not reported
Simforoosh et al.(2006)	6	Conventional Transperitoneal	uretrouretrostomy	180	4-5
Ding et al. (2012)	9	Conventional Transperitoneal	Pyeloplasty, ueretrouretrostomy	135	5-6
Chen et al. (2011)	12	Retroperitoneal	Ureteroureterostomy	112	3-4
Ricciardulli et al. (2015)	27	Retroperitoneal	Ureteroureterostomy	131	3-6
Autorino et al. (2010)	1	Transperitoneal LESS	Ureteroureterostomy	180	4-6
Santosh Kumar(2014)	1	Transperitoneal LESS	Ureteroureterostomy	105	3-5
Our study (2016)	4	Transperitoneal LESS	Ureteroureterostomy	162.5	5-6
	1	Conventional Transperitoneal	Ureteroureterostomy	150	4-6
	1	Retroperitoneal	Ureteroureterostomy	190	6-8
	8	Open	Ureteroureterostomy	120	7-10

Conclusion

Adults with RCU rarely experience upper urinary blockage. Although open surgical exploration is still a frequently utilised approach for RCU, laparoscopy has lately gained popularity because to its safety, efficacy, and viability. It is also associated with a much reduced need for analgesics and a shorter hospital stay. Although LESS for retrocaval ureters was proven to be safe and feasible with good functional and cosmetic results in our early experience, more research is still needed.

References

1. Simforoosh N, et al. A Laparoscopic pyelopyelostomy for retrocaval ureter without excision of the retrocaval segment: First report of six cases. J Urol. 2006; 175:166-9.
2. Rubinstein I, Cavalcanti AG, Canalini AF, Freitas MA, Accioly PM. Left retrocaval ureter associated with inferior vena caval duplication. J Urol. 1999; 162:1373-4.
3. Hochstetter F. Beitrage zur entwick lungsges chichtedes venen-systemsder amnioten: III. Sauger Morph J ahrb.1893: 20: 542.
4. Wang LT, Lo HC, Yu DS, Sun GH, Wu CC, Fong CJ. Ureteral obstruction caused by a duplicated anomaly of inferior vena cava. Int J Urol. 2005; 12:842-4.
5. Gramegna V, Madaro A, Pellegrini F, et al. A rare case of retrocaval ureter associated with persistent left vena cava. Urol Int. 2003; 70:337-8.
6. Brooks RE, Jr. Left retrocaval ureter associated with situs inversus. J Urol. 1962; 88:484-7.
7. Watanabe M, Kawamura S, Nakada T, Ishii et al. Left preureteral venacava associated with partial situs inversus. J Urol. 1991; 145:1047-8.
8. Rubinstein I, Cavalcanti AG, et al. Lef tretrocaval ureter associated with inferior vena caval duplication. J Urol. 1999; 162:1373-4.

9. Vasudevan Thirugnanasambandam, Prasant Nayak et al., Indian Journal of Urology, Oct-Dec 2015; 31(4).
10. Shigeta M, et al. Horseshoe kidney with retrocaval ureter and ureteropelvic junction obstruction: a case report. Int J Urol. 1997; 4:206-8
11. Ishitoya S, et al. Left retrocaval ureter associated with the Goldenhar syndrome (branchial arch syndrome). J Urol.1997;158:5723.
12. J. C. Anderson and W. Hynes, RETROCAVAL URETER: a case diagnosed pre-operatively and treated successfully by a plastic operation, British Journal of Urology. 1949; 21(3): 209–214.
13. S. Baba, M. Oya, M. Miyahara, N. Deguchi, and H. Tazaki, Laparoscopic surgical correction of circuivicaval ureter, Urology, 1994; 44(1): 122-126.
14. Salomon L, Hoznek A, Balian C, Gasman D, Chopin DK, Abbou CC. Retroperitoneal laparoscopy of a retrocaval ureter. BJU Int. 1999; 84: 1812.
15. Rane A, Rao P, et al. Single port laparoscopic nephrectomy using a novel laparoscopic port (Rport) and evolution of single laparoscopic port procedure (SLiPP) J Endourol. 2007; 21(Suppl 1): A–287
16. R. Autorino, R. Khanna, M. A. White et al., Laparoendoscopic single-site repair of retrocaval ureter: first case report, Urology, 2010; 76(6):1501–1505.
17. N. Kang, J.-H. Zhang, Y.-N. Niu et al., "Retroperitoneal laparoendoscopic single-site surgery for the treatment of retrocaval ureter, World Journal of Urology, 2013; 31(1):205–211.
18. Abdulhadi Z. T., & Muhsin Z. Y. Footprints to achieve digital smile design and esthetic: Narrative review. Journal of Medical Research and Health Sciences. 2023; 6(2): 2430–2440.