e-ISSN: 0975-1556, p-ISSN:2820-2643

Available online on www.ijpcr.com

International Journal of Pharmaceutical and Clinical Research 2023; 15(2); 361-375

Original Research Article

Critical Review of Covid-19 Associated Mucormycosis of Nose and Paranasal Sinuses in A Tertiary Care Hospital in Ongole, Andhra Pradesh

D. Dakshinamurthy[1], Ravindra Babu Kota[2], Sandeep Vemu[3], Tadi Saiprasad[4]

[1]Associate Professor of ENT, Department of ENT, Government Medical College, Ongole, Andhra Pradesh.

[2]Assistant Professor of ENT, Department of ENT, Government Medical College, Ongole, Andhra Pradesh.

[3]Tutor in ENT, Department of ENT Government Medical College, Ongole, Andhra Pradesh

[4]Tutor in ENT, Department of ENT Government Medical College, Ongole, Andhra Pradesh

Received: 26-12-2022 / Revised: 21-01-2023 / Accepted: 03-02-2023

Corresponding author: Dr Tadi Saiprasad

Conflict of interest: Nil

Abstract

Background: Mucormycosis is a fungal infection caused by filaments of Mucoraceae which invades blood vessels culminating in a lethal opportunistic infection. During the second wave of COVID-19, all over India a spurt of increased reporting of Mucoraecea infection was experienced. Compromised individual immunity system was suspected. Its early diagnosis and suitable surgical intervention were essential to decrease morbidity and mortality.

Aim of the Study: To study the demography, clinical features, risk factors, laboratory investigations, and radiological findings of patients with mucormycosis and to evaluate the clinical outcomes in each case.

Materials: A cross sectional study from the Department of ENT of Government Medical College Hospital, Ongole; 350 COVID-19 RT-PCR positive patients presented with clinical symptoms and signs of Mucormycosis between February 2021 and February 2022 were analyzed. All age groups and genders were included. Mucormycosis proved on microscopic examination of the aspirate or histopathologies of tissue specimens were included. Clinical findings, risk factors, comorbidities, outcome of the disease, biochemical and hematological investigations, radiological signs, nature of fungal elements isolated, treatment instituted were noted. Surgical procedures included were Functional Endoscopic sinus surgery, extended Endoscopic sinus surgery, Medial maxillectomy, ethmoidectomy, Sphenoid exploration, frontal sinusotomy, Orbital exenteration and Skull base surgeries. Antifungal treatment consisted of administration of liposomal Amphotericin B and posaconazole.

Results: 350 patients included in this study; 268/350 (76.57%) males and 82/350 (23.42%) females with a male to female ratio of 3.26:1. 211 (60.28%) patients living in rural areas and 139 (39.71%) living in the urban areas. 324 (92.57%) patients were positive for COVID-19 (RT-PCR) test and 26 patients were negative. There were 233 (66.57%) patients who were obese with more than 30 BMI index and 117 (33.42%) who were with less than 30 BMI index. 299 (85.42%) patients were diabetic and 51 (14.57%) patients were non diabetic. Vaccination was taken 188 (53.71%) of the patients and not taken by 162 (46.28%) of the patients. Mortality rate

was 09/350 (02.57%). It was observed that the variables such as Living area, COVID-19 (RT-OCR) test positivity, obesity, Diabetes mellitus and usage of steroids were significantly associated with Mucormycosis in this study.

Conclusions: Mucormycosis was found to be common in males, from the rural areas. Other significant risk factors for Mucormycosis were COVID-19 (RT-OCR) test positivity, obesity, Diabetes mellitus and usage of steroids. The most common clinical symptoms and signs among were nasal obstruction with noisy breathing, blood stained nasal discharge, headache, periorbital swelling, reduced vision, Ptosis, external ophthalmoplegia, and facial pains were common. Surgical management reduced the morbidity and mortality of Mucormycosis in this study.

Keywords: Immunity, mucormycosis, covid-19, fungus, Black fungus and fulminating.

Introduction

COVID-19 pandemic occurred in two waves in India between 2019 and 2021. COVID-19 disease was caused by the SARS-CoV-2 (Severe Acute Respiratory Syndrome Corona virus- 2). It was also called as the (2019-nCoV) novel Corona virus [1]. Mucormycosis is known to invade the blood vessels and caused by a filamentous fungus belonging to the Mucoromycete's [2]. During the second wave of COVID-19 many parts of India simultaneously reported innumerable number of cases in a short period [3]. These Mucormycosis cases were in mild COVID patients and also in patients who were asymptomatic [4]. The patients with COVID-19 disease and on steroidal therapy were affected giving an impression that steroids played an important role in its causation [5]. But patients with immunodeficiency, later age groups, diabetes Mellitus (diabetic ketoacidosis), patients who have undergone solid organ or bone marrow transplantation were the most affected [6]. Patients on prolonged steroids such as Bronchial Asthma, long duration neutropenia, blood cancers (Lymphoma, multiple myeloma and Leukemia) and overloaded iron diseases were also affected [7]. The prevalence of mucormycosis worldwide was from 0.005 to 1.7 per million populations [8]. But in India it was almost 80 times more; 0.14 per 1000 for the year 2019-2020 alone [9]. Which means India had contributed to nearly 70% of the Mucormycosis cases reported all over the world. In India nearly 14,870 patients were reported with Mucormycosis and among them many were from Gujarat (3,725) followed by Maharashtra (3,014), with mortality figures reaching as high as 43330 patients by July 2021 [10]. The filament type fungus included of the genus Rhizopus, Mucor, and Rhizomucor, of the order- Mucorales and class- Zygomycetes [11]. Among these the most common fungus was Rhizopus oryzae accounting for 65% of the total cases in India [12]. The fungus was also common organism causing rhino-orbital-cerebral (ROCM) forms of the disease [13]. Disease transmission was by inhaled fungal spores in the decomposing dead tissues; both vegetable and animal sources [14]. The spores may also get lodged by inoculation into the mucosa or breached tissues [15]. The hyphae of the fungus invade the blood vessels and occludes the blood flow resulting in the infarction of the distal tissue followed by the hyphae invading the dead tissue [16]. The common organs involved were Paranasal sinuses in 39%, lungs in 24%, skin in 19%, brain in 09%. Other sites were intestines in 07%, bone in 03% and disseminated disease in 06% [17] In ENT the most common bones involved were due to vessel thrombosis and tissue necrosis of facial

bones, maxilla, zygoma, orbital walls and oral cavity [18]. Clinically the patients in ENT department presented with nasal obstruction with noisy breathing, blood stained nasal discharge, headache, facial cellulitis, orbital swelling, palatal ulceration or necrosis, and black necrotic eschar in the nasal cavities [19] Surgical debridement remains the main choice of treatment to prevent further growth of the fungus into the new blood vessels [20]. Sometimes cerebral invasion takes place which also requires debridement [21,22]. In the present study an attempt was made to make a profile of Mucormycosis patients who attended the Government General Hospital of Ongole with a view to understand the demography of the patients, clinical features and the long term effect of the surgical debridement.

Materials

The present study was a cross sectional study conducted in the Department of ENT of Government Medical College Hospital, Ongole on patients attending with complaints of Mucormycosis. 350 patients were treated in a span of 13 months between February 2021 and February 2022. An institutional ethics clearance certificate was obtained before commencing the study. An ethic committee cleared proforma was used for the study.

Inclusion Criteria: Patients with proved mucormycosis of all age groups and genders were included. Patients with proven mucormycosis on microscopic examination of the aspirate or histopathology of tissue specimens were included. Patients with all comorbidities were included. Patients with intracranial and extracranial complications were included.

Exclusion criteria: Patients in whom microscopic biological diagnosis could not be established were excluded.

Data collection

Demographic details were collected from the cases sheets. Clinical symptoms on presentation were elicited and noted in the case sheets. ENT examination by DNE were recorded by video in each patient by the authors using staging suggested by Rupa et al.[23] Examination of the organs like eye, and central nervous system was conducted to assess the extent of the disease. Underlying comorbidities, course of the disease, biochemical and hematological investigations, radiological signs, nature of fungal elements isolated, treatment instituted, and disease outcomes were noted. Recently positive RT-PCR or positive more than 14 days before were also noted and studied. They were classified as CAM when mucormycosis was diagnosed within seven days and late CAM when they occurred eight days or more after COVID-19 diagnosis.[24] Also time lapse between turning positive to RT-PCR and appearance of first symptoms of COVID-19 were noted. Laboratory investigations were done immediately and repeated after 72 hours included were CBP, blood and serum glucose levels, LFT, prothrombin time, international normalized ratio (INR), c-reactive protein and renal function tests (blood urea and serum creatinine). CT Scan PNS, MRI PNS with or without contrast were undertaken wherever necessary. The clinical staging of mucormycosis in the study was done in the following method. Stage 1: Involvement of nose and paranasal sinuses only; Stage 2: Spread beyond the confines of para nasal sinuses into surrounding structures such as palate, cheek, sphenopalatine fossaetc., Stage 3: Additional spread to orbit. Stage 4: Intracranial spread. Regular follow up was done every 72 hours to assess the post treatment Mucormycosis.

Identification of Mucor: Potassium hydroxide (KOH) wet mount of the nasal swab taken during DNE was done and presence of broad aseptate, ribbon-like

hyphae with right-angled branching was considered as positive for Mucormycosis. Histopathology and staining with hematoxylin and Eosin (H&E) was undertaken for the tissues obtained from the surgical fields and presence of fungus was confirmed. Lactophenol cotton blue (LPCB) stain was used in doubtful cases.

Radiological Investigations: CT scan of Para nasal sinuses (CT PNS) was undertaken with or without contrast in the study. MRI scan was done when there was suspicion of intracranial extension and involvement of brain.

Surgical Treatment: It was started after confirmation of Mucormycosis on wet swab or tissue biopsy reports. Surgical profile was used to assess the renal, cardiac and pulmonary functions of the patient before subjecting to General Anaesthesia. The surgical procedures adopted were: Functional Endoscopic sinus surgery, Medial maxillectomy, Middle meatus antrostomy, ethmoidectomy, Sphenoid exploration, Orbital exenteration, frontal sinusotomy and Skull base surgeries. Antifungal treatment consisted of liposomal Amphotericin B (LAmB) IV 5 milligrams (mg)/kg body weight administered over three hours in 5% dextrose solution slowly. The patient was adequately hydrated with 500 ml of 0.9% normal saline before and after the infusion. In absence of the above drug amphotericin B deoxycholate (D-AmpB) in 1.0-1.5 mg/kg/day of dose was used. The above regimen was followed by Tab posaconazole 300 mg twice a day on day one followed by 300 mg once daily for three to six months depending upon the severity of the disease.

Clinical Results: They were graded based on duration of Hospital stay, symptomatic relief and DNE findings.

Statistical analysis

The data was collected in Excel sheet, for **c**ontinuous variables mean and ± SD, for categorical variables, the percentage was used. To calculate the association between the risk factors and the severity of mucormycosis, Odds ratio (OR) with 95% confidence limits (CL) and relative risk (RR) were used.

Results

The present study was conducted in the second wave of COVI-19 pandemic in a Government Medical College Hospital of Andhra Pradesh. Totally 350 patients were included in the study who were coming with complaints and symptoms of Mucormycosis of the nose and paranasal sinuses to the Department of ENT of Ongole Government Medical College. The study period was between February 2021 and February 2022. Among the 350 patients included in this study there were 268/350 (76.57%) males and 82/350 (23.42%) were females with a male to female ratio of 3.26:1. The mean age among the males was 43.27±11.35 years and in females it was 46.20±6.34 years. There were 211 (60.28%) patients living in rural areas and 139 (39.71%) living in the urban areas. 324 (92.57%) patients were positive for COVID-19 (RT-PCR) test and 26 patients were negative. There were 233 966.57%) patients who were obese with more than 30 BMI index and 117 (33.42%) who were with less than 30 BMI index. 299 (85.42%) patients were diabetic and 51 (14.57%) patients were non diabetic. There were 179 (51.14%) patients who gave history of smoking and 171 (48.85%) without smoking habit. Steroids were used by 234 (66.85%) patients and not used by 116 (33.14%) patients. Hypertension was observed in 144 (41.14%) patients and not found in 206 (58.85%) patients. Oxygen inhalation was used in the treatment of COVID-19 disease in 208 (59.42%) of the patients and not used in 142 (40.57%) of the patients. Steam inhalation was used by 185

(52.85%) patients and not used by 165 (47.14%) patients. Vaccination was taken 188 (53.71%) of the patients and not taken by 162 (46.28%) of the patients. The mean and median of the Laboratory values were shown in the **Table 1.** It was observed that the variables such as Living area, COVID-19 (RT-OCR) test positivity, obesity, Diabetes mellitus and usage of steroids were significantly associated with Mucormycosis in this study. But variables like Age, Smoking hypertension, oxygen inhalation and steam inhalation were not significantly associated with Mucormycosis in this study. Similarly all the lab values were found to be significantly associated with the Incidence of the Mucormycosis in this study; (P value less than 0.05 was taken as significant). **(Table 1)**

Table 1: Demography details of the study (n-350).

Variable	Number	Percentage	P value
Age in Years			
20 to 30	021	06.00	
31 to 40	069	19.71	
41 to 50	158	45.14	0.235
51 to 60	079	22.57	
61 to 70	066	18.82	
Above 70	057	16.28	
Gender			
Male	268	76.57	**0.001**
Female	082	23.42	
Living Area			
Rural	211	60.28	**0.001**
Urban	139	39.71	
COVID-19 (RT-PCR)			
Positive	324	92.57	**0.001**
Negative	26	07.42	
Obesity (BMI- Kg/m^2)			
< 30	233	66.57	
>30	117	33.42	**0.001**
Diabetes			
Yes	299	85.42	**0.001**
No	51	14.57	
Smoking			
Yes	179	51.14	
No	171	48.85	0.274
Hypertension			
Yes	144	41.14	0.318
No	206	58.85	
Steroids used			
Yes	234	66.85	**0.001**
No	116	33.14	
Oxygen inhaled			
Yes	208	59.42	0.184
No	142	40.57	

Steam inhalation Yes No	 185 165	 52.85 47.14	0.254
Vaccination Yes No	 188 162	 53.71 46.28	0.410
Lab values	Mean	Median	P value
Urea	36	38	**0.001**
Creatinine	0.8	0.9	**0.001**
Sodium	135	139	**0.001**
D-dimer	396	388	**0.001**
Ferritin	1120	1021	**0.001**
Procalcitonin	0.28	0.28	**0.001**

The common symptoms observed in the patients with nasal and Para nasal Mucormycosis in this study were Facial pain in 255 (72.85%), orbital swelling in 76 (21.71%), headache in 178 950.85%), diminution of vision in 30 (08.57%), facial swelling in 145 (41.42%) of the patients **(Table 2).**

Table 2: Symptoms and their incidence in the study (n-350).

Symptoms	Number	Percentage
Headache	178	50.85
Facial swelling	145	41.42
Diminution of vision	30	08.57
Fever	57	20
Orbital swelling	76	21.71
Retro orbital pain	131	37.42
Facial pain	255	72.85
Ptosis	28	08
Black colour nasal discharge	67	19.14
Ulceration over the nasal vestibules	55	15.71
Purulent Nasal discharge	89	25.42
Facial weakness	70	20
Cerebral Thrombosis	21	06
Intracranial Haemorrhage	18	05.14
Brain Abscess	14	04
Meningitis	11	03.14
Brain Infarct	07	02

In this study a **r**evised and restructured staging of Rhino- orbito- cerebral Mucormycosis was used exclusively to stage the disease and initiate appropriate surgical intervention. The incidences of different stages of Mucormycosis were tabled in **Table 3.**

Table 3: Mucormycosis staging used in the study.

Stages	Involvement	Anatomical sites	Number	Percentage
STAGE1	Nasal	Limited to one turbinate	11	03.14

Stage1a	mucosa	(Superior/ Middle/ Inferior)		
Stage 1b	Nasal mucosa	More than 1 turbinate Superior/ Middle/ Inferior or ostium of the nasolacrimal duct	27	07.71
Stage 1c		Involvement of the nasal septum	36	10.28
Stage 1 d		Bilateral nasal mucosal involvement	52	14.85
STAGE2 Stage 2a	Involvement of paranasal sinuses	One sinus involvement (Maxillary/Ethmoidal/Frontal/Sphenoidal)	38	10.85
Stage 2b	Do -	Two ipsilateral sinuses (Maxillary/Ethmoidal/Frontal/Sphenoidal)	23	06.57
Stage 2c	Do -	>2 ipsilateral sinuses (Maxillary/Ethmoidal/Frontal/Sphenoidal) and/or palate/alveolar bone/oral cavity	21	06
Stage 2d		Bilateral paranasal sinus involvement (Maxillary/Ethmoidal/Frontal/Sphenoidal) or involvement of the zygoma or mandible Stage 3 Involvement of the orbit	19	04
STAGE 3 Stage 3a	Adjacent tissue involvement -do-	Nasolacrimal duct, medial orbit, vision unaffected	30	08.57
Stage 3b	-do--	Diffuse orbital involvement (>1 quadrant or >2 structures), vision unaffected	17	04.85
Stage 3c	-do--	Diminution or loss of vision; vascular occlusion (singular or combined occurrence of central retinal artery occlusion/central retinal vein occlusion/ophthalmic artery occlusion/superior ophthalmic vein thrombosis); involvement of the superior orbital fissure, inferior orbital fissure or orbital apex •	29	08.28
Stage 3d	-do--	Bilateral orbital involvement	28	08
STAGE 4 Stage 4a	Involvement of the intracranial structures	Involvement of the cribriform plate, with or without local disease, but with sparing of the brain parenchyma	05	011.42
Stage 4b	-do-	Cavernous sinus involvement, with or without evidence of contiguous disease	08	02.28
Stage 4c	-do-	Involvement of brain parenchyma with evidence of contiguous disease	06	01.71

(Suffix P:---Involvement of Pterygopalatine fossa
Suffix I:---Involvement of Infratemporal fossa
Suffix C;---Cutaneous extension of local disease

Suffix D:---Disseminated disease with isolation of mucormycosis from sites other than ROCM such as pulmonary, gastrointestinal, renal, cutaneous
Prefix:--- Lt/Rt Aids in specifying the side of involvement and, if bilateral, whether one side is more involved than the other (Rt>LT, Lt>Rt, Lt = Rt)
A differentiation should be made from cutaneous extension of the disease in ROCM versus pure cutaneous mucormycosis seen with contaminated cutaneous breaches).

Examination of the Mucormycosis patients with DNE and during the Fess surgery it was observed that patients presented with mass in the nose in 126 (36%) patients, Sequestrum of inferior turbinate was observed in 69 (19.71%) patients , Sequestrum of both middle and inferior turbinates in 143 (40.85%) patients, Sequestrum of all three turbinates in 91 (26%) patients, slough covered necrotic mass in 88 (25.14%) patients, Sequestrum of ehtmoid bone was seen in 96 (27.42%) patients Sequestrum of nasal septum was seen in 73 (20.85%) patients, Mass in the Maxillary Antrum in 108 (30.85%) patients, Mass in the Sphenoid Antrum in 93 (26.57%) patients, orbital invasion in 51 (14.57%) patients, optic nerve damage in 34 (09.71%) patents, skull base invasion was seen in 22 (06.23%) patients, Sloughing of facial skin over maxilla was seen in 67 (19.14%) of the patients **(Table 4).**

Table 4: Incidence of Operative findings in the study (n-350).

Operative findings	Number	Percentage
Mass in the nose	126	36
Sequestrum of turbinates		
Only inferior	69	19.71
Both Inferior and middle	143	40.85
All 3 turbinates	91	26
Slough covered necrotic mass	88	25.14
Sequestrum of ethmoid bone	96	27.42
Sequestrum of Nasal septum	73	20.85
Mass in the Maxillary Antrum	108	30.85
Mass in the Sphenoid antrum	93	26.57
Orbital invasion	51	14.57
Optic nerve damage	34	09.71
Skull base invasion	22	06.28
Sloughing of facial skin over maxilla	67	19.14

Operative procedures adopted in the study were simple debridement of dead tissue including the Mucormycosis in 62 (17.71%) patients, medial maxillectomy in 83 (23.71%) patients, maxillary antral exploration in 70 (20%) patients, ethmoidectomy in 58 (16.57%) patients, orbital exenteration in 12 (03.42%) patients, sphenoid sinus exploration in 91 (26%) patients, skull base surgery in 67 (19.14%) patients, cavernous sinus debris clearance in 09 (02.57%) patients and frontal sinusotomy in 12 (03.42%) patients. IN 50 cases only medical management was done, **(Table 5), (Fig 1to 6).**

Table 5: Surgical procedures done and non-surgical cases in the study (n-350).

Operative Procedure	Number	Percentage
Debridement	62	17.71
Medial Maxillectomy	83	23.71

Maxillary antral exploration	70	20
Ethmoidectomy	58	16.57
Orbital exenteration	12	03.42
Sphenoid sinus exploration	91	26
Skull base surgery	67	19.14
Cavernous sinus debris clearance	09	02.57
Frontal sinusotomy	12	03.42
Non-surgical cases	50	14.28

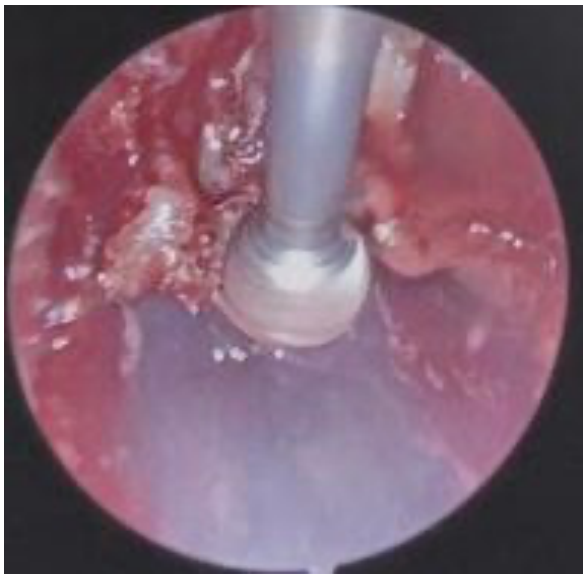

Figure 1: Drilling of frontal beak in Lathrop's procedure for Frontal sinus involvement with Mucormycosis.

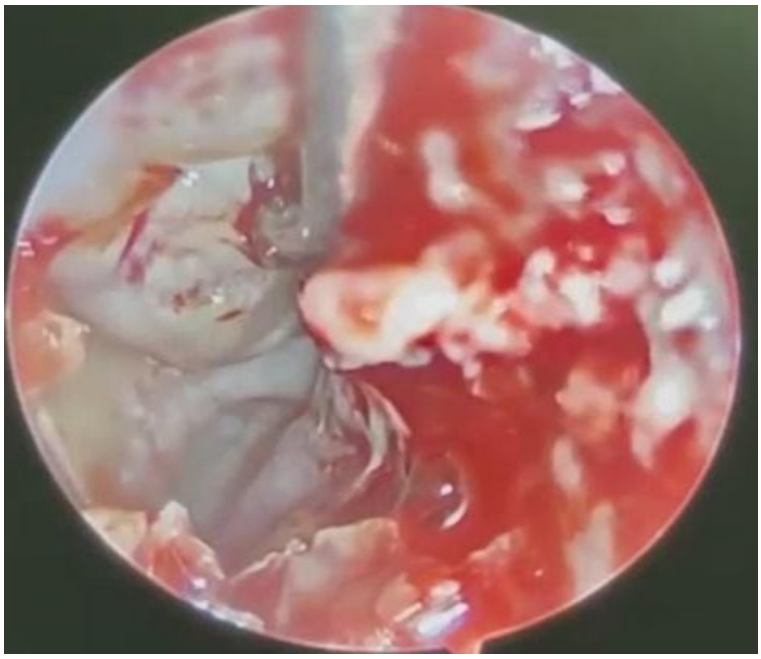

Figure 2: Frontal sinusotomy being done.

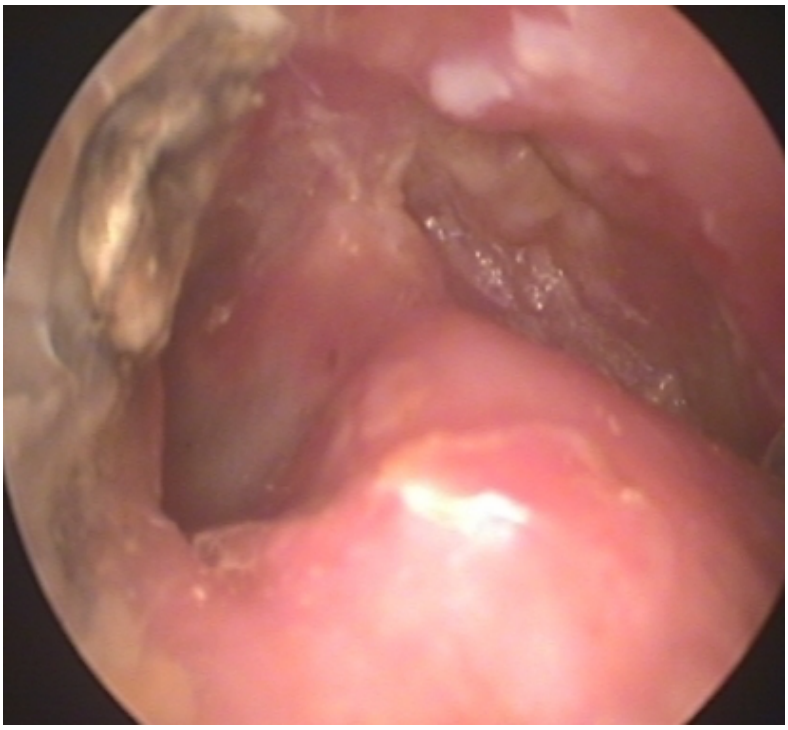

Figure 3: Mucormycosis in the Left Maxillary Antrum.

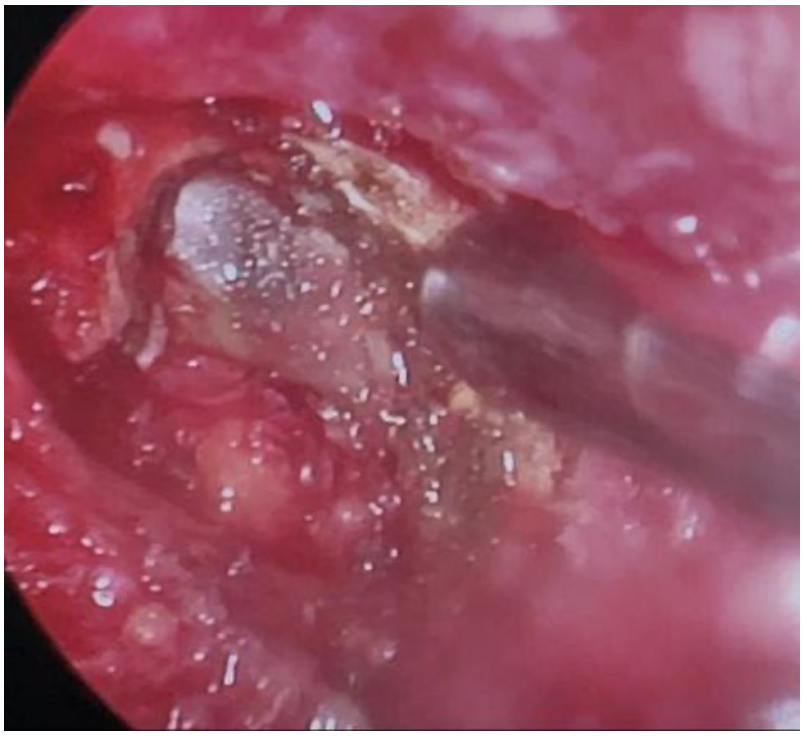

Figure 4: Sequestrated Zygomatic bone due to Mucormycosis.

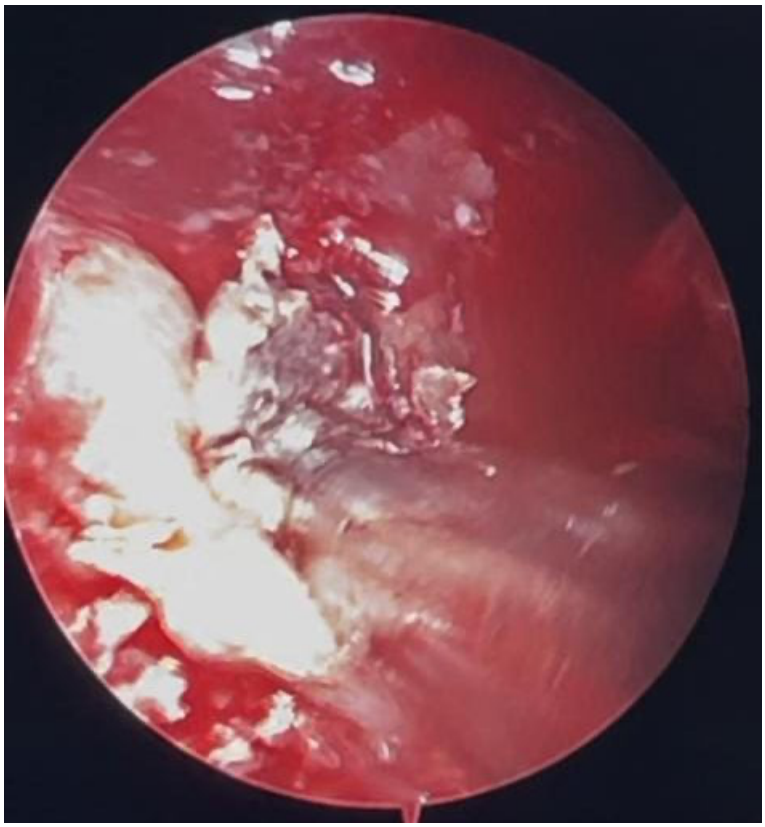

Figure 5: Removal of necrotic tissue from Sphenopalatine fossa.

Discussion

Mucormycosis was reported at an alarming rate during the second wave of COVID-19 disease in India starting from the month of February 2020 to February 2022. The incidence was similar all over the world [24]. Nearly 20 species of the fungus causing Mucormycosis were isolated and identified during that period. Among them the common agents were Aspergillus fumigatus, Candida albicans, and Mucormycosis [25]. Such an incidence of fungal infections was never reported during the outbreaks of coronaviruses such as the severe acute respiratory syndrome-coronavirus (SARS-CoV) and the middle east respiratory syndrome coronavirus (MERS-CoV) [26]. The first reported Mucormycosis was in the year 1876 by Fürbinger in Germany. He showed a hemorrhagic infarct with fungal hyphae and sporangia [27]. The risk factors observed were diabetes, HIV infection, obesity, and malignancies globally. In a similar report by Chakrabarti *et al* from north India, there were 50 patients with Mucormycosis among the 119 positive RT-PCR patients for COVID-19 disease [28], Anushuya G *et al* [29] reported 84 patients out of 738 studied over a seven year period. But in the present study within 9 months 350 patients were reported with Mucormycosis. In this study Among the 350 patients included in this study there were 268/350 (76.57%) males and 82/350 (23.42%) were females with a male to female ratio of 3.26:1. The mean age among the males was 43.27±11.35 years and in females it was 46.20±6.34 years. There were 211 (60.28%) patients living in rural areas and 139 (39.71%) living in the urban areas. 324 (92.57%) patients were positive

for COVID-19 (RT-PCR) test and 26 patients were negative. There were 233 966.57%) patients who were obese with more than 30 BMI index and 117 (33.42%) who were with less than 30 BMI index. 299 (85.42%) patients were diabetic and 51 (14.57%) patients were non diabetic. Whereas Singh AK *et al* [30]. reported 82 cases (81.2%) out of 390 COVID-19 positive patients from India. Diabetes Mellitus was found to be risk factor in a study conducted by Jeong W *et al* from their meta-analysis of 851 cases of Mucormycosis in 2019 especially for rhino-orbital-cerebral Mucormycosis (odds ratio (OR) 2.49; 95% CI 1.77-3.54; $p < 0.001$) [31]. In the present study risk factors were Age, smoking hypertension, oxygen inhalation and steam inhalation were not significantly associated with Mucormycosis in this study. Similarly all the lab values were found to be significantly associated with the Incidence of the Mucormycosis in this study; (P value less than 0.05 was taken as significant). **(Table 1)** It was shown by a molecular study that Hyperglycemia results in glycosylation of transferrin and ferritin which in turn reduce the iron-binding capacity. It results in increased free iron levels. Similarly increased interleukin-6 levels in COVID-19 also augments free iron level through increased production of ferritin. These two factors are superadded by up regulation of the regulator protein 78 (GRP-78) on endothelium cells and fungal ligand spore coat homolog (CotH) protein, which facilitates angio-invasion of the fungus, hematogenous dissemination, and tissue necrosis [32] Other risk factors were prolonged use of steroids. Yohai *et al* [33]. from their review of 208 patients observed ophthalmoplegia in 67% of cases, vision impairment in 65%, proptosis in 64%, peri-orbital edema in 43%, and periorbital pain in 11% in the descending order. Therakathu J *et al* [34]. from their study observed 11/43 (25%) had various cranial nerve palsies. In the present study the common symptoms observed in the patients with nasal and Para nasal Mucormycosis were Facial pain in 255 (72.85%), orbital swelling in 76 (21.71%), headache in 178 (50.85%), diminution of in 30 (08.57%), facial swelling in 145 (41.42%) of the patients **(Table 2).** In this study mass in the nose in 126 (36%) patients, Sequestrum of inferior turbinate was observed in 69 (19.71%) patients , Sequestrum of both middle and inferior turbinates in 143 (40.85%) patients, Sequestrum of all three turbinates in 91 (26%) patients, slough covered necrotic mass in 88 (25.14%) patients, Sequestrum of ethmoid bone was seen in 96 (27.42%) patients Sequestrum of nasal septum was seen in 73 (20.85%) patients, Mass in the Maxillary Antrum in 108 (30.85%) patients, Mass in the Sphenoid Antrum in 93 (26.57%) patients, orbital invasion in 51 (14.57%) patients, optic nerve damage in 34 (09.71%) patents, skull base invasion was seen in 22 (06.23%) patients, Sloughing of facial skin over maxilla was seen in 67 (19.14%) of the patients **(Table 4).** Similar findings were noted by Sharma *et al* [36]. where ethmoids were the most commonly involved sinuses followed by maxillary sinus. Similar reports were presented by Therakathu J *et al* (34) from South India. They also reported unilateral sinus involvement was more common (79.1%) than bilateral sinus involvement (20.9%). Though treatment is surgical always but it required a multi-disciplinary approach and planning and involved a multidisciplinary team approach. The survival rate of mucormycosis increased with meticulous debridement and regular follow up debridement wherever necessary. It increased by 60% in this study when surgery was combined with antifungal treatment. Intravenous amphotericin B was the treatment of choice as antifungal agent in

this study. The penetration of the drug was better in the cases where debridement was complete and total in this study. In the present study were simple debridement of dead tissue including the Mucormycosis in 62 (17.71%) patients, medial maxillectomy in 83 (23.71%) patients, maxillary antral exploration in 70 (20%) patients, ethmoidectomy in 58 (16.57%) patients, orbital exenteration in 12 (03.42%) patients, sphenoid sinus exploration in 91 (26%) patients, skull base surgery in 67 (19.14%) patients, cavernous sinus debris clearance in 09 (02.57%) patients and frontal sinusotomy in 12 (03.42%) patients. In 50 cases only medical management was done, **(Table 5).** Overall mortality in the present study was 09/350 (02.57%). Similar reports were published by Sarkar S *et al* [35-38] in a post COVISD study of 210 cases. Another study by White *et al* [16]. reported significantly higher mortality in patients with invasive fungal infections (53% vs 31%). The high mortality associated with mucormycosis was attributed to the spread of the fungus intravascular route with its dissemination. A simple delay in the diagnosis by 12 hours changed the incidence of morbidity and mortality in this study. Intracranial involvement added up on to the increased mortality of Mucormycosis [39-42].

Conclusions

Mucormycosis was found to be common in males, from the rural areas. Other significant risk factors for Mucormycosis were COVID-19 (RT-OCR) test positivity, obesity, Diabetes mellitus and usage of steroids. The most common clinical symptoms and signs among were nasal obstruction with noisy breathing, blood stained nasal discharge, headache, periorbital swelling, diminution of vision, ptosis, external ophthalmoplegia, and facial pain are common. Demonstration of fungal hyphae, its culture, and histopathology were necessary in addition to study the extent of the disease by radio-imaging and DNE tests to confirm the diagnosis of Mucormycosis. Surgical debridement was proved to be the choice of immediate treatment followed by IV antifungal agents. As Mucormycosis demands a challenging approach in the diagnosis and management, high index of suspicion should be exercised by the ENT surgeon. Surgical management reduced the morbidity and mortality of Mucormycosis in this study.

References

1. Kaneria MV, Baligeri K and Budhe A. Post COVID-19 mucormycosis: A case series. Asian Pacific Journal of Tropical Medicine. 2021; 14(11):517-524.
2. Kim JG, Park HJ and Park JH. Importance of immediate surgical intervention and antifungal treatment for rhino cerebral mucormycosis: a case report. Journal of the Korean Association of Oral and Maxillofacial Surgeons, 2013; 39(5): 246–250.
3. Roden MM, *et al*. Epidemiology and outcome of zygomycosis: A review of 929 reported cases. Clinical Infectious Diseases. 2005;41(5): 634–653.
4. Bouchara JP, *et al*. Attachment of spores of the human pathogenic fungus Rhizopus oryzae to extracellular matrix components. European Journal of Cell Biology. 1996;70(1): 76-83.
5. Ibrahim AS, *et al*. Pathogenesis of mucormycosis. Clinical Infectious Diseases. 2012;54(1): 16-22.
6. Balai E and Mummadi S. Rhino cerebral Mucormycosis: A Ten-Year Single Centre Case Series. Cureus, 12(11): e11776.
7. Ezeokoli OT, Gcilitshana O and Pohl CH. Risk factors for fungal co-infections in critically ill COVID-19 patients, with a focus on immunosuppressants. Journal of Fungi, 2021;7(7): 545.
8. Epidemiology and diagnosis of mucormycosis: an update. Skiada A,

Pavleas I, Drogari-Apiranthitou M. J Fungi (Basel) 2020;6.
9. Emerging cases of mucormycosis under COVID-19 pandemic in India: misuse of antibiotics. Gupta G, S R, Singh Y, *et al*. Drug Dev Res. 2021;82:880–882.
10. Pal R, Singh B and Bhadada SK. COVID-19-associated mucormycosis: An updated systematic review of literature. Mycoses, 2021;64(12): 1452-1459.
11. Mucormycoses. Eucker J, Sezer O, Graf B, *et al*. Mycoses. 2001; 44:253–260.
12. Kamath S, Kumar M and Sarkar N. Study of Profile of Mucormycosis During the Second Wave of COVID-19 in a Tertiary Care Hospital. Cureus,2022;14(1): e21054.
13. Nagalli S and Kikkeri NS. Mucormycosis in COVID-19: A systematic review of literature. Le Infezioni in Medicina, 2021;29(4): 504-512.
14. Sugar AM. Mandell, Douglas, and Bennett's principles and practice of infectious diseases. USA: Churchill Livingstone; 2000.
15. Ezeokoli OT, Gcilitshana O, Pohl CH. J. Risk factors for fungal co-infections in critically ill COVID-19 patients, with a focus on immunosuppressants. Fungi (Basel) 2021; 7:545.
16. Bawankar P, Lahane S, Pathak P, *et al*. Central retinal artery occlusion as the presenting manifestation of invasive rhino-orbital-cerebral mucormycosis. J Ophthal. 2020; 10:62–65.
17. Chakrabarti A, Sharma SC, Chandler. Epidemiology and pathogenesis of paranasal sinus mycoses. J. Otolaryngol Head Neck Surg. 1992; 107:745–750.
18. Anushuya G, Chandramohan A, Karkuzhali P, Saraswathi M. Fungal rhinosinusitis: a clinicomorphological study in a tertiary institute. Indian J Pathol Oncol. 2019; 6:35–38.
19. Singh AK, Singh R, Joshi SR, Misra A. Mucormycosis in COVID-19: a systematic review of cases reported worldwide and in India. Diabetes Metab Syndr. 2021; 15:102146.
20. Jeong W, Keighley C, Wolfe R, Lee WL, Slavin MA, Kong DC, Chen SC. The epidemiology and clinical manifestations of mucormycosis: a systematic review and meta-analysis of case reports. Clin Microbiol Infect. 2019; 25:26–34.
21. Baldin C, Ibrahim AS. Molecular mechanisms of mucormycosis-The bitter and the sweet. PLoS Pathog. 2017; 13:0.
22. Tortorano AM, Peman J, Bernhardt H, *et al*. Epidemiology of candidaemia in Europe: results of 28-month European Confederation of Medical Mycology (ECMM) hospital-based surveillance study. Eur J Clin Microbiol Infect Dis. 2004; 23:317–322.
23. White PL, Dhillon R, Cordey A, *et al*. A national strategy to diagnose coronavirus disease 2019-associated invasive fungal disease in the intensive care unit. Clin Infect Dis. 2021; 73:0–44.
24. Riche CV, Cassol R, Pasqualotto AC. Is the frequency of candidemia increasing in COVID-19 patients receiving corticosteroids? J Fungi (Basel) 2020; 6:286.
25. Ibrahim AS, Spellberg B, Edwards J Jr. Iron acquisition: a novel perspective on mucormycosis pathogenesis and treatment. Curr Opin Infect Dis. 2008; 21:620–625.
26. Selarka L, Sharma S, Saini D, *et al*. Mucormycosis and COVID-19: an epidemic within a pandemic in India. Mycoses. 2021; 64:1253–1260.
27. Mucormycosis. Sugar AM. Clin Infect Dis. 1992; 14:0–9.
28. Karadeniz Uğurlu Ş, Selim S, Kopar A, Songu M. Turk. Rhino-orbital Mucormycosis: Clinical Findings and

Treatment Outcomes of Four Cases. J Ophthalmol. 2015; 45:169–174.
29. Yohai RA, Bullock JD, Aziz AA, Markert RJ. Survival factors in rhino-orbital-cerebral mucormycosis. Surv Ophthalmol. 1994; 39:3–22.
30. Rupa V, Maheswaran S, Ebenezer J, Mathews SS. Current therapeutic protocols for chronic granulomatous fungal sinusitis. Rhinology. 2015; 53:181–186.
31. Ezeokoli OT, Gcilitshana O, Pohl CH. Risk factors for fungal co-infections in critically ill COVID-19 patients, with a focus on immune-suppressants. J Fungi (Basel) 2021; 7:545.
32. Bawankar P, Lahane S, Pathak P, *et al*. Central retinal artery occlusion as the presenting manifestation of invasive rhino-orbital-cerebral mucormycosis. J Ophthal. 2020; 10:62–65.
33. Hendrickson RG, Olshaker J, Duckett O. a case of a rare, but deadly disease. J Emerg Med. 1999; 17:641–645.Rhinocerebral mucormycosis:
34. Patel A, Agarwal R, Rudramurthy SM, *et al*. Multicenter epidemiologic study of coronavirus disease-associated mucormycosis, India. Emerg Infect Dis. 2021; 27:2349–2359.
35. Chakrabarti A, Sharma SC, Chandler. Epidemiology and pathogenesis of paranasal sinus mycoses. J. Otolaryngol Head Neck Surg. 1992; 107:745–750.
36. Anushuya G, Chandramohan A, Karkuzh ali P, Saraswathi M. Fungal rhinosinusitis: a clinicomorphological study in a tertiary institute. J Pathol Oncol. 2019; 6:35–38.
37. Singh AK, Singh R, Joshi SR, Misra A. Diabetes Metab Syndr. 2021; 15:102146. Mucormycosis in COVID-19: a systematic review of cases reported worldwide and in India.
38. Jeong W, Keighley C, Wolfe R, Lee WL, Slavin MA, Kong DC, Chen SC. The epidemiology and clinical manifestations of mucormycosis: a systematic review and meta-analysis of case reports. Clin Microbiol Infect. 2019; 25:26–34.
39. Molecular mechanisms of mucormycosis-The bitter and the sweet. Baldin C, Ibrahim AS. Pathog. 2017; 13:0.
40. Yohai RA, Bullock JD, Aziz AA, Markert RJ. Survival factors in rhino-orbital-cerebral mucormycosis. Surv Ophthalmol. 1994; 39:3–22.
41. Therakathu J, Prabhu S, Irodi A, Sudhakar SV, Yadav VK, Rupa V. Imaging features of rhinocerebral mucormycosis: a study of 43 patients. Egypt J Radiol Nucl Med. 2018; 49:447–452.
42. Dubey S, Mukherjee D, Sarkar P, *et al*. COVID-19 associated rhino-orbital-cerebral mucormycosis: an observational study from Eastern India, with special emphasis on neurological spectrum. Diabetes Metab Syndr. 2021; 15:102267.