e-ISSN: 0975-1556, p-ISSN:2820-2643

Available online on www.ijpcr.com

International Journal of Pharmaceutical and Clinical Research 2023; 15(3); 657-667

Original Research Article

Comparative Study of Conventional Ultrasound with Strain Elastography in Breast Lesions

Priyal Chouhan[1], Khan Mohammad Faraz Mohammad Farid Khan[1], Pranav Kumar Dave[2], Reshu Sharma[*], Kuldeep Yadav[3]

[1]Assistant Professor, Department of Radio Diagnosis, MGM Medical College, Indore, MP.
[2]Professor of Radiology, Department of Radiodiagnosis., L N Medical College and J K Hospital, Kolar Road, Bhopal, MP, India.
[*]Associate Professor of Radiology, Department of Radiodiagnosis., L N Medical College and J K Hospital, Kolar Road, Bhopal, MP, India.
[3]Resident Radiology, Department of Radiodiagnosis., L N Medical College and J K Hospital, Kolar Road, Bhopal, MP, India.

Received: 10-01-2023 / Revised: 15-02-2023 / Accepted: 22-02-2023
Corresponding author: Dr Reshu Sharma
Conflict of interest: Nil

Abstract

Breast cancer is the most common cancer among women all over the world. Similar trend is noted in India. An estimated 1.6 lakh new cases were diagnosed in India and 2 million across the world in the year 2018. Five-year survival of patients with breast cancer post-treatment in India is only 60 percent as compared to 89 percent in the United States of America. The high mortality rate in our country is probably due to lack of awareness and delay in diagnosis and treatment. The aim of this study is to compare the diagnostic performance of elastography with that of conventional ultrasound for characterizing breast lump.

Material and Methods: A prospective study was conducted to evaluate 61 adult patients of both sexes above the age of 15 years with history of clinically palpable breast lump. An informed consent was taken from all the participants to perform ultrasound and elastography. The lesions were assessed according to BI-RADS criteria on ultrasound and afterwards, in the same sitting, elastography was performed by the same observer assigning the grades and strain score. Simple descriptive analysis, mean, median, proportions and frequency distribution with 95% CI were used in the study sample. Categorical data was analysed using percentage and chi square test. A p-value of <0.05 was considered significant.

Results: Out of 61 cases, 56 cases were females and 5 cases were males. This indicated high incidence of breast abnormality in females. 49 cases were found to be benign on elastography. 48 out of 49 cases were found to be benign on cytology. 12 cases were malignant on elastography; on cytology correlation, 11 cases were malignant. 92% of sensitivity and 87% of specificity respectively was seen for ultrasound. Sensitivity and specificity of elastography score was 97.9 % and 87% and that of strain ratio was 92.3% and 97.9%. Combined sensitivity and specificity of 84.64% and 98.31% respectively was noted for cumulative analysis of elastography technique.

Conclusions: Our study concluded that elastography is useful in all breast lesions, when used along with conventional grey scale ultrasound. This technique helps to downgrade or upgrade the categorization of the ultrasound breast lesion, subsequently avoids unnecessary cytology or biopsy, which in turn is beneficial as it is cost effective and time saving method and avoids psychological stress or trauma to the individual.

Keywords: Fine Needle Aspiration Cytology, Confidence Index, Breast Imaging and Reporting Data System, Blue Green Red Artifact, Breast Lump.

Introduction

Breast carcinoma is the most common cancer among women worldwide with number reaching up to 1.5 million in 2016 in India [1] and accounts for 27% of all cancers in women [2,3] and therefore, its a leading cause of cancer deaths among women.

The incidence of breast cancer increases with increasing age, and in individuals with early menarche and late menopause. Nulliparity and child birth in late age also increase risk of breast cancer development. The level of risk also increases with positive medical or family history.

The most common presenting complaint in case of carcinoma is breast lump. Other presentations include nipple discharge, nipple retraction, skin eczema etc [4].

Mammography and ultrasound are standard modalities for breast screening and diagnosis. They are highly sensitive in detecting breast cancer, however, they have some limitations. To overcome such limitations and obtain more accurate results through diagnostic procedure, ultrasound elastography was first reported in 1991 by Cespedes and Ophir.

Elastography is a non-invasive technique based on the principle of tissue stiffness in disease conditions [5]. There are two methods for assessing elasticity of the lesion, that is strain elastography and shear wave elastography [6]. In this study, we are using strain elastography technique for tissue evaluation. Strain is computed as the rate of change of axial tissue displacement as a function of depth, and therefore, it is a semiquantitative technique in estimating stiffness.

Material and Methods

This is a prospective study conducted in Department of Radiodiagnosis, in a tertiary care teaching hospital in central part of India. A total of 61 adult subjects of both sexes participated in the study. An informed consent was taken from all participants to perform ultrasound and strain elastography. Both procedures were conducted in the same sitting and was performed by same observer.

Ultrasound examinations were performed using a conventional ultrasound with real-time elastography software using Versana Premier GE ultrasound machine with a high frequency 7.5-10 MHz linear array probe and focus of minimum 3-4 cm depth. The examination was done in fairly low lighting with patients in supine position, by rolling the patient on one side or other side and ipsilateral hand behind the head. All the cases having a lesion on B-mode ultrasound were subsequently subjected to elastography. The lesions were assessed according to BI-RADS criteria on ultrasound.

Elastography mode was used on the machine. Split screen image displays were on screen, one of the screens showing grey scale images and another screen showing grey scale images with a chromatic scale box. This chromatic scale was used to assign green colour to soft tissue and blue colour to non-compressed hard tissue. Slight light pressure was applied by moving probe in superior and inferior direction. While doing so, normal breast tissue was included on the screen. Optimal light pressure was applied on the breast lesions; this was shown by green signals on the screen. Appropriate images were obtained, which were called elastogram, and were saved for analysis. Elasticity scoring (Tsukuba score) is a chromatic scale

used to assign colour depending on nature of tissue. Green colour corresponds to compressible soft tissue and blue colour to non- compressible hard tissue. The categorization was given by Ueno et al[7].

Strain score - 1-3 score are considered benign and 4-5 score is malignant.

Grade 1: Indicates equal strain for hypoechoic lesion (i.e., the entire lesion was displayed as green colour.)

Grade 2: Indicates mixed pattern of high and low strain throughout the hypoechoic lesion (i.e. mosaic pattern of green and blue within the hypoechoic lesion).

Grade 3: Indicates high strain at the periphery of the hypoechoic lesion, with low strain at the centre of the lesion (i.e., the peripheral part of lesion was green, and the central part was blue).

Grade 4: Indicates no strain in the entire hypoechoic lesion (i.e. the entire lesion was blue, but its surrounding area was green in colour)

Grade 5: Indicates no strain in the entire hypoechoic lesion or in the surrounding area (i.e., both the entire hypoechoic lesion and its surrounding area were blue).

Strain ratio was calculated in all lesions by placing region of interest (ROI) on the lesion and another ROI was placed in adjacent soft tissue at same height. With help of the software, the ratio was displayed on a static image. Deniz Özel et al[8] in his study calculated cut-off value to be 3.1 with help of ROC curve. This cut off value is used in our study to differentiate benign lesions from malignant.

The patients were referred to pathology department for cytological correlation. Assembled data was analysed by simple descriptive analysis such as mean, median proportions and frequency distribution and 95% CI were used in the study sample. Categorical data was analysed using percentage and chi square test. A p-value of <0.05 was considered statistically significant.

Results

A total of 61 patients participated in our study. Consent was obtained from all the patients for doing ultrasound breast and elastography, both were performed in the same sitting. All the patients were considered to study the sensitivity and specificity of ultrasound, elastography score and strain ratio in detection and assessment of breast lesions and its role in differentiating benign and malignant nature. All patients then underwent fine needle aspiration cytology (FNAC) and findings were confirmed.

The minimum age of presentation at our hospital was 18 years and maximum age was 75 years. Maximum number of patients belonged to the age group of 15-30 years. Out of 61 patients, 26 (42.6%) belonged to 15-30 years age group and only 1 patient (1.6%) belonged to >75 years age group. (Fig 1)

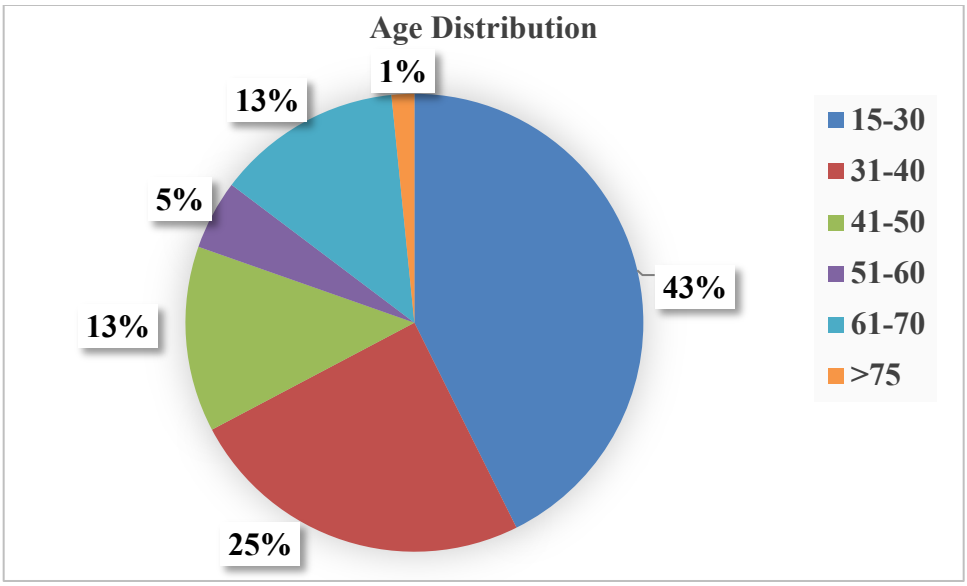

Figure 1: Age distribution

Majority of patients reviewed were females (92%), and the rest were male patients (8%). The median age was 37.22 years. (Fig 2)

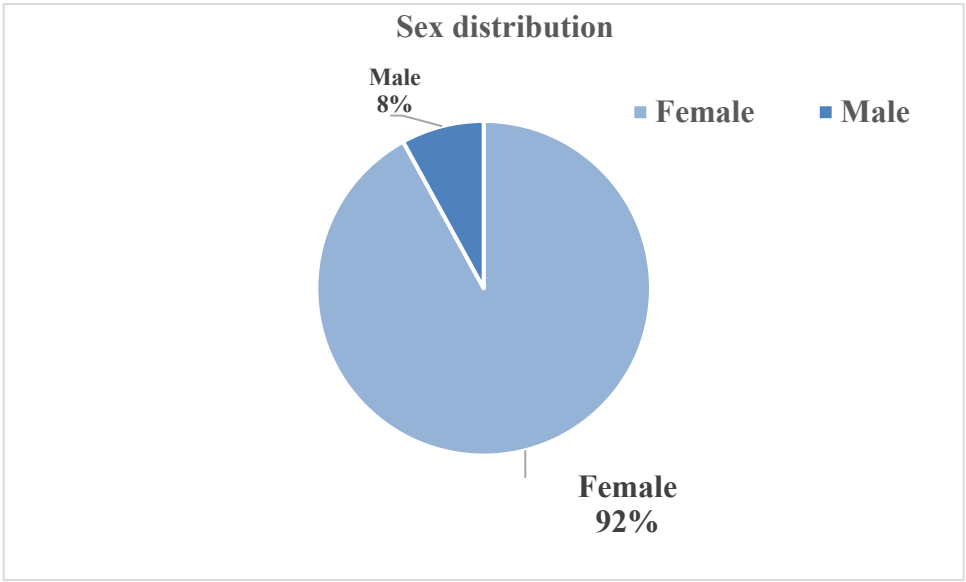

Figure 2: Sex distribution

Out of 48 benign cases, 25 cases belonged to 15-30 years of age group, 15 cases were in 31-40 years age group, 4 cases were in 41-50 years, 2 cases were in 61-70 years of age group and 1 case was >75 years. Similarly, out of 13 malignant cases, 1 case was in 15-30 years of age group, no cases were in 31-40 years of age, 4 cases were in 41-50 years age group, 4 cases in 41-50 years age group, 2 cases in 51-60 years age group, 6 cases were in 61-75 years age group. (Figure 3)

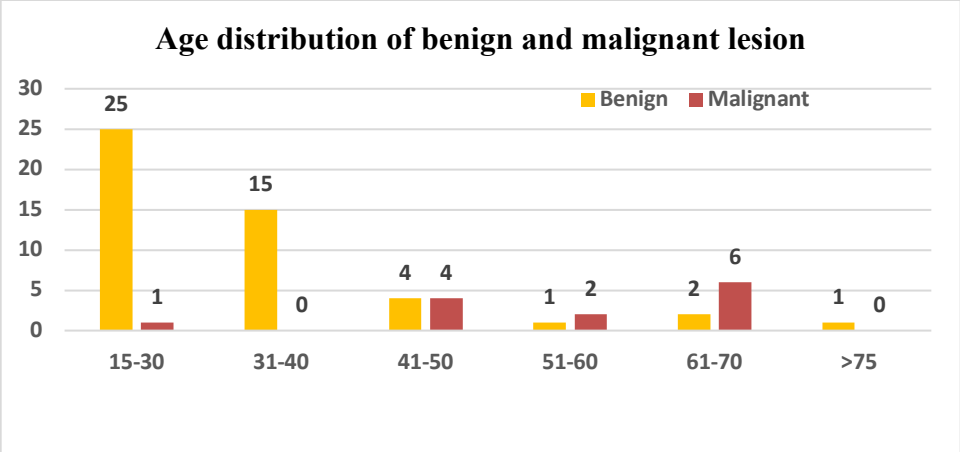

Figure 3: Age distribution of benign and malignant lesion

Out of 61 patients, 48 (79%) were cytologically benign in nature and 13 (21%) were cytologically malignant. (Figure 4)

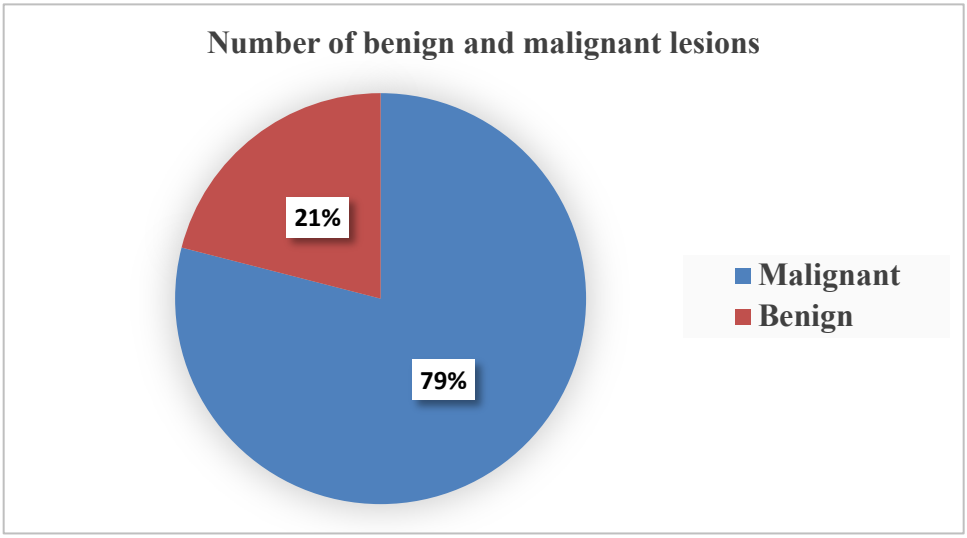

Figure 4: Number of benign and malignant lesions

Elasticity score: An elastogram is a visual colour coded representation of tissue deformation under compression. A five-point scoring system is called Tsukuba score. Elasticity score of 1-3 were noted in all benign cases except 2 cases. And score of ≥4 was noted in 1 benign case and all malignant cases. (Table 1)

Table 1: Distribution of cases according to Elastography score

Elasticity score	Grade I	Grade II	Grade III	Grade IV	Grade V
No. of cases	10	29	10	5	7
No. of benign cases (FNAC)	10	28	9	1	0
No of malignant cases (FNAC)	0	1	1	4	7
Mean elasticity score of benign lesions: 1.9 Mean elasticity score of malignant lesions: 4.5					

Strain score (E/B Ratio): This is a semi-quantitative method to quantify the relative stiffness between the lesion and adjacent tissue. A strain ratio of more than 3 indicates high possibility of malignancy. All benign lesions (48) in our study had strain ratio <3 except 1. Among 13 malignant cases, 1 had strain ratio< 3 and 12 cases had strain ratio >3. (Table 2)

Table 2: Distribution of cases according to Strain Ratio

Strain ratio	**<3**	**>3.1**
No of cases	48	13
No. of benign	47	1
No. of malignant	1	12
Mean strain ratio of benign lesion: 1.51 **Mean strain ratio malignant lesion: 4.73**		

Among the total 61 cases, on the basis of ultrasound BI-RADS categories, 18 (29.5%) cases showed features of malignant lesion. On cytology correlation, 12 cases out of 18 cases were found to be malignant. BI-RADS categories I, II and III were taken as benign and BI-RADS categories IVa, IVb, IVc and V were taken as malignant. On the basis of this categorisation, 43 cases showed benign features. Further correlation with cytology showed that out of 61 cases, 42 were benign and 1 case was malignant. Therefore, for 61 cases, the sensitivity and specificity of ultrasound was 92% and 87% respectively, with an accuracy rate of 88% (CI 95%). (Table 3)

Table 3: Comparison of USG with FNAC

Parameter	**FNAC (Malignant)**	**FNAC (Benign)**	
USG (Malignant)	12	6	18
USG (Benign)	1	42	43
Total	13	48	61
Sensitivity 92%; specificity 87%; PPV 50.1%; NPV 98.8%; Accuracy 88%			

Out of 61 cases on basis of elastography score (Tsukuba score), 13 (21.3%) had features of malignancy. FNAC was done in all these 13 cases, 12 cases were found to be malignant. Based on elastography (Tsukuba score), 48 (78.6%) cases showed benign features and on cytology correlation, 47 cases exhibited benign features and 1 case revealed malignant features. The sensitivity and specificity between elastography score and FNAC findings was 92.3% and 97.9% respectively, with an accuracy rate of 97.2% (CI 95%). (Table 4).

Table 4: Comparison of Elastography score with FNAC

Parameter	**FNAC (Malignant)**	**FNAC (Benign)**	
Elastography (Malignant)	12	1	13
Elastography (Benign)	1	47	48
Total	13	48	61
Sensitivity 92.3%; specificity 97.9%; PPV 85.8%; NPV 98.9%; Accuracy 97.2%			

Out of total 61 cases, on the basis of strain ratio, 13 cases showed score of >3 corresponding to malignant lesions. On cytology correlation of these 13 cases, 12 cases were found to be malignant. On the basis of strain ratio, a total of 48 cases showed score of <3 corresponding to benign lesion and on cytology correlation of these 48 cases, 47 were found to be benign and 1 case was malignant. The sensitivity and specificity between strain ratio and FNAC was 92.3 % and 97.9% respectively, with accuracy rate of 96% (CI 95%). (Table 5)

Table 5: Comparison of Strain Ratio with FNAC

Parameter	FNAC (Malignant)	FNAC (Benign)	
Strain Ratio (Malignant)	12	1	13
Strain Ratio (Benign)	1	47	48
Total	13	48	61
Sensitivity 92.3%; specificity 97.9%; PPV 92.3%; NPV 97.9%; Accuracy 96%			

The sensitivity and specificity correlation between ultrasound, elastography score and strain ratio with FNAC is shown in Table 6.

Table 6: Correlation of Ultrasound and Elastography with FNAC

Modalities	Sensitivity	Specificity	PPV	NPV	Accuracy
Ultrasound	92%	87%	50.1%	98.8%	88%
Elastography score	92.3%	97.9%	85.8%	98.9%	97.2%
Strain Ratio	92.3%	97.9%	92.3%	97.9%	96%

On cumulative analysis of elastography technique, combined sensitivity and specificity was noted to be 84.64% and 98.31% respectively.

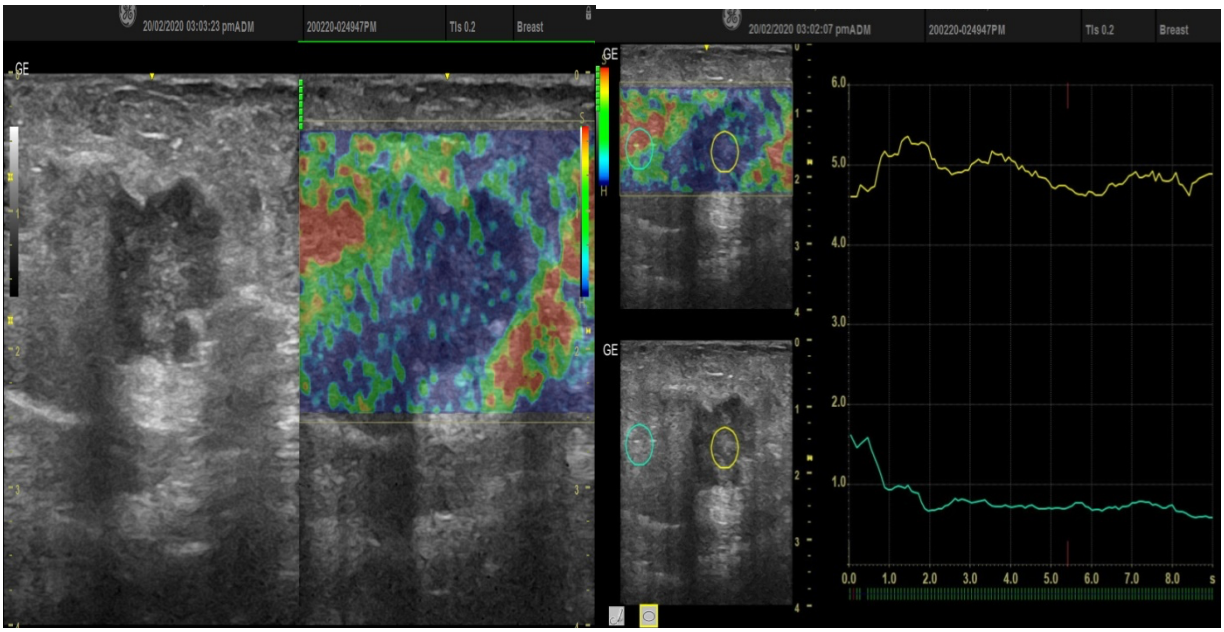

A 70-year female presented with lump for 2 weeks associated with pain.
BI-RADS 5
Elastography score 5
Strain ratio: 5.8/0.9

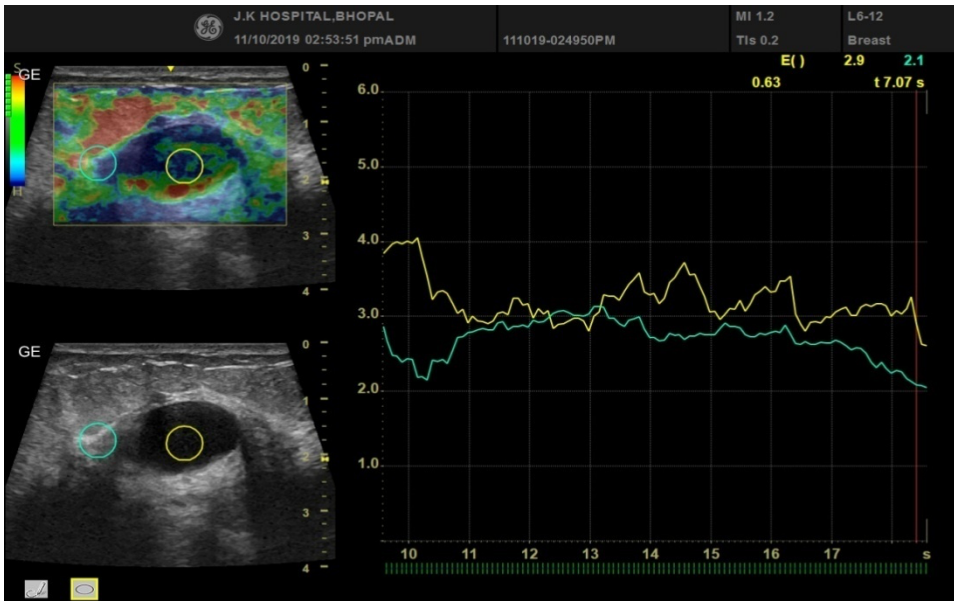

A 35-year female presented with lump in right breast for 1 year

BI-RADS 2

Elastography score 1* (BGR pattern)

FNAC fibrocystic diseases

Discussion

Ours was a prospective study for assessment of elastography in characterizing and differentiating benign from malignant breast lesions. Majority of the patients were females accounting for 92% and 8% of patients were males (Table- 5.2, Figure-5.2). The median age of patients presenting with complain of breast lump was 37.2 years and 79% of lesions were benign (Table 5.4, Figure 5.4) which reflects that breast lesions were more common and predominantly occurred in young females. These findings were similar to the study done by Olu-Eddo A.N. El al [9].

This study showed specificity of 87% with ultrasound, whereas on elastography, specificity increased to 97.9%. Elastography showed sensitivity of 92.3% which was better than ultrasound showing sensitivity of 92%. These results were similar to study done by Navarro B [10], his study showed sensitivity of 69.5% and specificity of 83.1% for breast elastography. Another study done by Cho N also showed similar results [10]. Therefore, ultrasound when used in conjunction with elastography has ability to improve diagnostic accuracy (Table 6). On cumulative analysis of elastography score and strain ratio, the combined specificity rises to 98.31%. Hence, this technique helps in early identification of malignant lesions and reducing false positive results.

BI-RADS protocol was followed as category 1, 2, and 3 as benign lesions and BI-RADS 4a, 4b, 4c and 5 as suspicious and malignant lesions on ultrasound. In our study of 61 cases, 10 cases were categorized as BI-RADS grade 3. Out of 10, 9 of them turned out to be benign, whereas 1 was malignant on cytology. This particular case showed elastography score of grade IV. These results are similar to other studies [9-13] which showed that elastography has a beneficial role in evaluation of low suspicion lesions by early detection of malignant potential.

Cho N *et al* (2012) evaluated 13 suspicious cystic lesions mimicking as solid mass on ultrasound and elastography, subsequently all lesions showed BGR artifact and were found

to be fibrocystic disease on histology [11]. In our study, 3 lesions showed BGR pattern and 3 out of 4 lesions were found out to be fibrocystic disease on cytological correlation. Elastography examination of BI-RADS 4a lesions showed characteristics of benign lesions and help in down grading the lesion to BI-RADS 3 or even BI-RADS 2 [14]. In this study, 6 lesions were categorized BI-RADS 4a, all the lesions showed benign elastography score and strain ratio of <3. On FNAC correlation, subsequently all lesions were found to be benign, thus increasing the confidence in technique and its diagnostic performance.

5 lesions were categorized as BI-RADS 4b, 4 out of 5 lesions had strain ratio of >3.1 and these 4 lesions later proved to be malignant on cytology. There were 6 BI-RADS 4c lesions and 3 BI- RADS 5 lesions, of these lesions, elastography score showed grade 4 and 5, and strain ratio of >3.1. All the lesions were found to be malignant on cytology. Based on clinical presentation and BI-RADS imaging, 61 lesions underwent FNAC, resulting in 21% positive biopsy rate (13/61). Elastography score grade 1 and 2 accounts for 32/61 (52.4%) lesions which were benign and therefore, these many biopsies would have been avoided while at the same time not missing suspicious malignant lesions. Thus, refining the potential of elastography may decrease the number of invasive diagnostic procedures. The mean elasticity score analysis showed significant high value for malignant lesions (4.5) as compared to benign lesions (1.9) with a p-value of <0.001, sensitivity of 92.3%, specificity of 97.9%, PPV of 85.8%, NPV of 98.9% and diagnostic accuracy of 97.2%. This is in accordance with results reported by Schnitt SJ *et al* [15] who showed that when cut-off of elasticity score of 3 and 4 were used, elastography had sensitivity of 86.5%, specificity of 89.8% and diagnostic accuracy of 88.3 %. Singh M *et al* [16] also reported similar results with sensitivity of 85.7%, specificity of 96.49% and accuracy of 93.5%. This was also found to be in concordance with the study conducted by Sohn Y-M [17]. Gheonea *et al* [18] study showed sensitivity of 86.7% and a specificity of 92.9% for elasticity score. Thomas A *et al* [19] study also showed sensitivity and specificity of 81% and 89% for elastography.

Based on strain ratio analysis considering the cut-off value of >3.1, this study showed sensitivity of 92.3%, specificity of 97.9%, PPV of 92.3%, NPV of 97.9% and accuracy of 96%. Mean strain ratio value for malignant lesions was 4.73 which was significantly higher than benign lesion worth value of 1.5. Similar results were observed by Esinger F *et al* [20] in which the cut-off was 3.67, and showed sensitivity of 93.3% and a specificity of 92.9% for strain ratio. Ioana A.G. *et al* [18] in Romania noted that one of the lesions (3.57%) with grade 4 elastography score and one lesion (3.57%) with grade 5 elastography score turned out to be benign after FNAC and histopathology.

In the same study, one of the lesions (3.57%) with grade 1 elastography score and 3 lesions (10.72%) with grade 3 elastography score were found to be malignant. Likewise, study done by Singh M [16] found that 2 lesions with elastography score of grades 4 turned out to be benign. In this study, there was one lesion with grade 3 elastography score which was found out to be malignant and one lesion with grade 4 elastography score turned out to be benign.

Conclusion

Ultrasound Elastography is a newer, simple, effective, non-invasive method that can be used as a compliment along with ultrasound examination of breast. Ultrasound elastography was found to have high sensitivity and specificity in differentiating benign and malignant lesions of breast. Therefore, it reduces the need for

unnecessary cytology or biopsy in benign breast lesions. This technique increases the diagnostic confidence in diagnosing malignant lesions.

Under ultrasound guided-biopsy, elastography demonstrates the stiffest part of the lesion and sample can be collected from that focus for biopsy/cytology for better yield. While performing Ultrasound Elastography, elasticity score and strain ratio are dependent variables and for a more confident diagnosis, both techniques should be used.

Reference

1. Cancer Statistics| Drupal. Nciindia. aiims. edu. http://nciindia.aiims.edu/en/cancer-statistics. Published 2020. Accessed December 15, 2022.
2. Ferlay J, Soerjomataram I, Ervik M, *et al*. GLOBOCAN 2012 v1.0, Cancer Incidence and Mortality Worldwide. IARC Cancer Base No. 11 [Internet]. Lyon, France: International Agency for Research on Cancer; 2013.
3. Bray F, Ren JS, Masuyer E, *Et al*. Estimates of global cancer prevalence for 27 sites in the adult population in 2008. Int J Cancer. 2013; 132(5): 1133-45.
4. J Micheal Dixon, ABC of breast diseases 1997 ISBN 0-7279-0915- 0. Page1
5. Berg WA, Bandos AI, Mendelson EB, Lehrer D, Jong RA, Pisano ED. Ultrasound as the Primary Screening Test for Breast Cancer: Analysis from ACRIN 6666. J Natl Cancer Inst. 2015; 108(4):367. Published 2015 Dec 28.
6. S., Anil & Tanwar, Nandini. Evaluation of breast lump using elastography, histopathology and its diagnostic accuracy. International Surgery Journal. 2019;6. 574.
7. Ueno E, Iboraki P. Clinical application of US elastography in the diagnosis of breast disease. ECR 5e9 March, Vienna, Austria; 2004.
8. ÖzelD, ÖzelBD. Evaluating the role of strain ratio elastography in determining malignancy potential and csalculating objective BIRADS US scores using ultrasonography and elastography features. Pol J Radiol. 2018;83: e268-e274. Published 2018 Jun 8.
9. Cho N, Moon WK, Chang JM, *et al*. Aliasing artifact depicted on ultrasound (US)-elastography for breast cystic lesions mimicking solid masses. Acta Radiol. 2011; 52:3–7.
10. Shah VI, Raju U, Chitale D, *et al*. False-negative core needle biopsies of the breast: an analysis of clinical, radiologic, and pathologic findings in 27 consecutive cases of missed breast cancer. Cancer. 2003; 97:1824–1831.
11. Liberman L, Ernberg LA, Heerdt A, *et al*. Palpable breast masses: is there a role for percutaneous imaging-guided core biopsy? AJR Am J Roentgenol. 2000; 175:774–787.
12. Ward ST, Shepherd JA, Khalil H. Freehand versus ultrasound-guided core biopsies of the breast: reducing the burden of repeat biopsies in patients presenting to the breast clinic. Breast. 2010; 19:105–108.
13. Pijnappel RM, van Dalen A, Borel Rinkes IH, *et al*. The diagnostic accuracy of core biopsy in palpable and non-palpable breast lesions. Eur J Radiol. 1997; 24:120–123.
14. Wojcinski S, Boehme E, Farrokh A. Ultra sound real time elastography can predict malignancy in BI-RADS US- 3 lesions. BMC Cancer. 2013; 13:159.
15. Schnitt SJ, Guidi AJ. Pathology of invasive breast cancer. In diseases of the breast. Harris JR, Lipmann ME, Morrow M, Osborne CK. 3rd edition, Lippincott, William and Wilkins. Philadelphia. 2004. Pp 393

16. Singh M. Evaluation of Diagnostic Accuracy of Ultrasound Elastography in Differentiating benign and Malignant Solid Breast Masses in Correlation with Mammography, Fine Needle Aspiration Cytology (FNAC) and Biopsy. www.ijcmr.com. Published 2020. Accessed December 16, 2022.
17. Sohn Y-M, Kim MJ, Kim E-K, *et al*. Sonographic elastography combined with conventional sonography how much is it helpful for diagnostic performance? J Ultrasound Med. 2009; 28:413–20.
18. Gheonea IA, Donoiu L, Camen D, Popescu FC, Bondari S. Sonoelastography of breast lesions: a prospective study of215 cases with histopathological correlation. Rom J Morphol Embryol. 2011; 52:1209-14.
19. Cho N, Jang M, Lyou CY, Park JS, Choi HY, Moon WK. Distinguishing Benign from Malignant Masses at Breast US: Combined US Elastography and Color Doppler US—Influence on Radiologist Accuracy Radiology. 2012; 262:1.
20. Eisinger F, Jacquemier J, Charpin C, Stoppa-Lyonnet D, Bressac-de Paillerets B, Peyrat JP, Longy M, Guinebretière JM, Sauvan R, Noguchi T, Birnbaum D, Sobol H. Mutations at BRCA1: the medullary breast carcinoma revisited. Cancer Res. 1998 Apr 15;58(8):1588-92.