e-ISSN: 0975-1556, p-ISSN:2820-2643

Available online on www.ijpcr.com

International Journal of Pharmaceutical and Clinical Research 2023; 15(4); 93-100

Original Research Article

Outcome of Bi-Columnar Plating in Tibial Plateau Fractures

Ravi Kumar A S[1], Surya Kiran Killi[2], Anmol Kshirsagar[3], Anuj Dixit[4]

[1]Associate Professor, Sri Siddhartha Medical College and Hospital, Tumkur.
[2]Senior Resident, Sri Siddhartha Medical College and Hospital, Tumkur.
[3]Senior Resident, SDM Medical College and Hospital, Dharwad.
[4]Senior Resident, Sri Siddhartha Medical College and Hospital, Tumkur.

Received: 30-01-2023 / Revised: 27-02-2023 / Accepted: 29-03-2023
Corresponding author: Dr. Surya Kiran Killi
Conflict of interest: Nil

Abstract

Background: The tibial plateau, a significant component of the knee joint, is crucial for both mobility and the transfer of weight. 1.2% of all fractures are proximal tibial fractures, whose incidence is more in 3rd& 5th decade & increasing because of high velocity road traffic accidents followed by fall from height, sport injuries etc. Tibial plateau fractures alter the knee kinematics, joint stability, and result in joint incongruity. Complex joint biomechanics, ligamentous stability, and articular congruency all have an impact on treatment results and long-term impairment. Open reduction and stable internal fixation helps in maintaining the articular congruity and restoration of the mechanical alignment which allows early mobilization of knee.

Result: The study by using MODIFIED RASMUSSEN SCORE reported the functional outcome to be 70% Excellent, 23.33% Good, 3.33% Fair and 3.33% Poor results. The Radiological outcome showed 73.33% Excellent, 20% Good, 3.33% Fair and 3.33% Poor results.

Conclusion: These fractures involving more than one column have excellent to good functional and radiological outcomes if articular reconstruction and stabilization with bicolumnar plating is done which allows for early mobilization of joint. Stabilization of postero-medial fragments by plating prevents subsequent varus collapse.

Keywords: Bicolumnar Plating, Tibial Plateau, Schatzker's Classification, Modified Rasmussen Score.

Introduction

The tibial plateau, a significant component of the knee joint, is crucial for both mobility and the transfer of weight. 1.2% of all fractures are proximal tibial fractures, which are more common between the third and fifth decades of life and are on the rise due to high-speed traffic accidents, falls from great heights, sports injuries, and other factors [1,2]

Tibial plateau fractures alter the knee kinematics, joint stability, and result in joint incongruity [6]. Complex joint biomechanics, ligamentous stability, and articular congruency all have an impact on treatment results and long-term impairment [5,11]. Schatzker's type IV, V &VI fractures are due to high energy trauma and contribute to 20 – 40 % of these fractures and are more associated with local soft tissue injury, compartment syndrome and ligament instability [7].

There is considerable debate over the best way to treat high-energy tibial plateau fractures. Early mobilisation of the knee is made possible by open reduction and stable internal fixation, which maintains articular congruency and restores mechanical alignment [8,11,12].

Schatzker's classification is relatively simple and familial system but considering only AP view X-ray for defining columns of proximal tibia. Luo *et al* developed 3 column concept based on Axial CT images for better identification of postero-medial fragments missed on regular X-rays [13]. This classification helps surgical plan in terms of patient positioning, surgical approach and incision placement [2].

The purpose of this study is to evaluate the radiological and functional outcomes of Schatzker type IV, V and VI tibial plateau fractures treated primarily with bicolumnar plating using **MODIFIED RASMUSSEN SCORE.**

Materials & methods

According to inclusion and exclusion criteria, patients with complex tibial plateau fractures who were admitted to Sri Siddhartha Hospital Tumkur between August 2020 and July 2022 were taken into consideration and chosen for the study. Six months are allowed for follow-up. To select the best patients for surgery, SCHATZKER IV, V, and VI grading of tibial plateau fractures were employed in all cases.

A detailed history taking, meticulous clinical examination, X-rays, routine haematological investigations followed by written and informed consent was done.

Inclusion criteria

- All skeletally mature patients with age 18-70 yrs.
- SCHATZKER type IV, V & VI fractures.
- Gustilo - Anderson type-I & type-II compounds proximal tibial fractures.
- Complex Intra-articular tibial plateau fractures.

Exclusion criteria:

- Gustilo-Anderson type-III fractures
- Extra-articular fractures.
- SCHATZKER type I, II & III fractures.
- Fractures with same side intra-articular distal femur.
- Non-walking patients
- Neurovascular deficit.
- Fractures with dislocation of knee joint.

Pre op X-ray

CT view

Surgical procedure:

Iv antibiotics were administered intravenously before to surgery as normal prophylaxis.

The patient is lying on his or her side with a folded pillow under each knee and a sandbag under the opposite gluteal area to facilitate an anterior-posterior approach.

Incision marking

Postero-medial plating position.

Put a sandbag under the opposite hip with the ipsilateral leg in the figure-four posture for the posteromedial approach. If necessary, a femoral distractor was employed. With longitudinal traction and C-arm guiding, the first indirect fracture reduction was accomplished. The pieces were held in reduction by percutaneous K wires. If the medial condyle is broken, the lateral condyle is fixed in order to achieve length.

Through posteromedial approach to proximal tibia with approximately 6 - 15cm incision over posteromedial border of proximal tibia. The long saphenous vein and nerve identified and preserved. Pes anserinus expansions identified, incised longitudinally in the line of skin and approached tibia. The gastrocnemius muscle was gently freed from posteromedial surface by blunt dissection.

The fracture fragments visualised, reduced under C-arm guidance. A bone punch was used to elevate the depressed articular portion if any and the void was filled with bone graft. The reduced fragments were fixed with 3.5 mm proximal tibia Tor L Buttress Plate Or Recon Plate and screws, after contouring.

The lateral condyle fracture was approached anterolaterally. “S” shaped incision was made starting 5 cm proximal to joint line curving the incision anteriorly over gerdy’s tubercle and extend it distally 1cm lateral to anterior border of tibia. Joint capsule was incised.

Tibialis anterior retracted

Capsule is incised

The proximal tibia lateral locking compression plate is used to treat the fracture after the proximal tibialis anterior is resected under C-arm guidance. Depression in the articular surface, elevated and bone grafting were performed.

With the aid of a Y connector, a drain was kept for each wound.

Wound closure with Drain insitu **C-arm image of final fixation**

Post-Operative Protocol:

A clean, well-padded dressing was finished. A brace was on the knee. On the second post-operative day, a drain was removed. As much active knee mobilisation as the patient could tolerate was recommended. The sutures were removed on the 14th post-operative day. Subject was released with crutch walking but not weight bearing.

Post Operative wound image

Depression fractures: start quadriceps exercises as soon as pain tolerance allows; avoid weight-bearing (NWB) for six weeks. High energy, unstable fracture patterns are retained NWB until there are evident evidence of union, which is typically 8 to 12 weeks after surgery.

Ten to fourteen days after surgery, range-of-movement exercises are begun to promote wound healing.

Post op X-ray 1mnth follow 6mnths follow.

Results

The observation made on data collected from the group of 30cases as follows

All pts ranged from 20 – 50yrs The Mean SD of all participants involved in our study were of 40.30+-12.38yrs.

Out of the 30 participants 28(93%) were males 2(7%) were females, Here male: female ratio is 14:1.

Mode of injury is 23(76.7%) due to road traffic accident and 7(23.3%) due to fall from height.

According to Schatzker type of injury 7(23%) participants have sustained Type IV fracture, 13(43%) participants have sustained Type V fracture, 10(33%) participants have sustained Type VI fracture

Immobilization period before surgery is 6(20%) for 1-10 days, 15(50%) for 11-20 days, 9(30%) for 21-30 days. The Mean SD of all the participants were 15.67±5.88.

Table 1 : Functional outcome assessment by Modified Rasmussen Score

Time	Poor	Fair	Good	Excellent	Mean Rank	Chi-Square	P-value*
1 Month	0 (0.0%)	21 (70.0%)	9 (30.0%)	0 (0.0%)	1.12	46.242	<0.001
3 Month	1 (3.3%)	1 (3.3%)	20 (66.7%)	8 (26.7%)	2.22		
6 Month	1 (3.3%)	1 (3.3%)	7 (23.3%)	21 (70.0%)	2.67		

* Friedmans's test

At the end of 6months, 1(3.3%) participant showed Poor outcome, 1(3.3%) participant showed Fair outcome, 7(23.3%) participants showed Good outcome and 21(70%) participants showed Excellent outcome.

The mean P-value being <0.001.

Graph 1: Functional Outcome assessment by Modified Rasmussen Score

Table 2 : Radiological Outcome assessment by Modified Rasmussen Score

Time	Poor	Fair	Good	Excellent	Mean Rank	Chi-Square	P-value
1 Month	0 (0.0%)	17 (56.7%)	13 (43.3%)	0 (0.0%)	1.22	41.216	<0.001
3 Month	1 (3.3%)	2 (6.7%)	20 (66.7%)	7 (23.3%)	2.08		
6 Month	1 (3.3%)	1 (3.3%)	6 (20.0%)	22 (73.3%)	2.70		

At the end of 6months, 1(3.3%) participant showed Poor outcome, 1(3.3%) participant showed Fair outcome, 6(20%) participants showed Good outcome with 22(73.3%) participants showed Excellent outcome.

The mean P-value being <0.001.

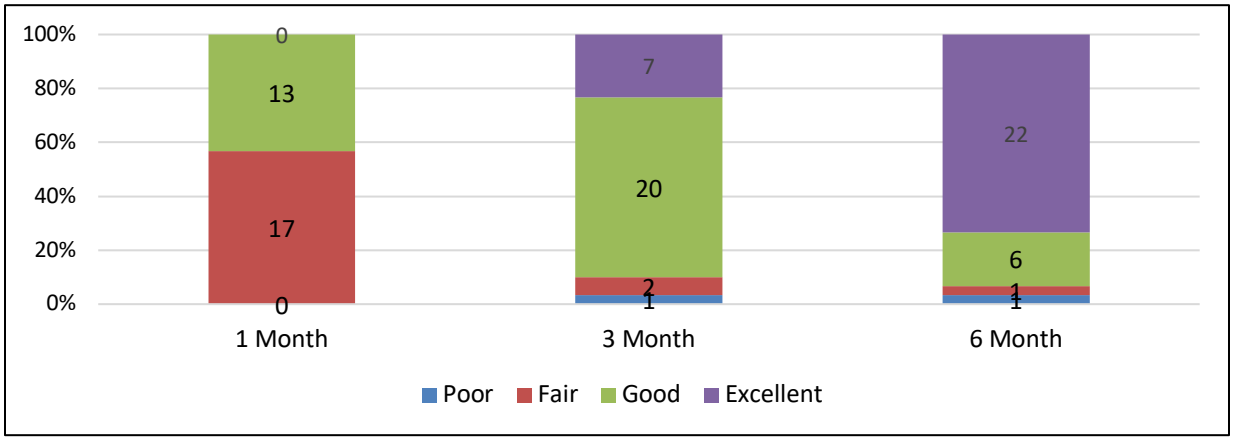

Graph 2: Radiological Outcome assessment by Modified Rasmussen Score

Table 3: Complications

Complications	Frequency	Percent
Nil	22	73.3
Secondary Osteoarthritis	3	10.0
Osteoarthritis & Varus Angulation	1	3.3
Infection	2	6.7
Extensor Lag	2	6.7
Total	30	100.0

3(10%) participants developed Secondary Osteoarthritis due to old age 1(3.3%) participant developed Secondary Osteoarthritis with Varus angulation of knee 2(6.7%) participants developed surgical site Infection, 1 participant was treated with debridement, intravenous antibiotics and regular sterile dressings which improved subsequently. 1 participant infection didn't subside even after debridement added by uncontrolled Diabetes, which has led to implant removal. He was immobilised with above knee cast with partial weight bearing mobilisation till bony union and consolidation. 2(6.7%) participants have Extensor Lag due to flexion contractures which was treated with physiotherapy and extension exercises of the knee 22(73.3%) participants have no Complications at all

Discussion

In our study out of 30 participants males outnumbered females in the ratio of 14: 1, 28(93%) participants were males, 2(7%) were females. This is same with 20 participants by BORA SS *et al*, in which 12 were male and 8 were female. Ufuk Ozkaya *et al*, in a series of 22 participants 16 were male and 6 were female. MANJUNATH J *et al*, reported that 21 were male and 9 were female in a study consisting of 30 participants. Somasheka RA SA *et al* reported in a series of 30 participants 25 were male and 5 were female. Which is also

comparable by having more number of male participants.

In our study the injury is high velocity trauma as stated by 23(76.7%) participants sustaining road traffic accidents, 7(23.3%) participants sustained injury due to fall from height. Road traffic accidents are the leading cause of injury. In similar studies by UFUK Ozkaya *et al*, Manjunath J *et al*, Somashekara SA *et al* reported that road traffic accidents are the major cause, which is similar to our study.

Out of 30 participants with tibial plateau fractures, 7(23.3%) participants had sustained Type IV fracture, 13(43.3%) participants had Type V fracture and 10(33.3%) participants had Type VI fracture in our study, where the incidence of Type IV, Type V and Type VI Schatzker's fracture were comparable with similar studies reported by Manjunath J *et al*, Somashekara SA *et al*.

In our study, duration from injury to surgery was 5-10 days in 6(20%) participants, 11-20 days in 15(50%) participants and 21-25 days in 9(30%) participants. Average duration was 10 to 20 days because of soft tissue injuries and leg swelling as comparable with similar studies reported by SOMASHEKARA SA *et al* and MANJUNATH J *et al*

Table 4: Functional Outcome

Studies	PTS	Excellent	Good	Fair	Poor
Our Study	30	70%	23.3%	3.3%	3.3%
Manjunath *et al*	30	73%	18.7%	7.3%	3%
Bora SS *et al*	20	70%	25%	5%	NIL
Somashekara *et al*	30	68%	20%	8.7%	3.3%

Table 5: Radiological Outcome

Studies	PTS	Excellent	Good	Fair	Poor
Our Study	30	73.3%	20%	3.3%	3.3%
Manjunath *et al*	30	79%	20.6%	0.4%	NIL
Bora SS *et al*	20	65%	20%	15%	NIL
Somashekara *et al*	30	66.68%	33.3%	NIL	NIL

Conclusion

From this high velocity proximal tibial fractures involving more than one column are relatively more common in young males with age group between 31- 40yrs, most commonly by road accidents. These fractures involving more than one column have excellent to good functional and radiological outcomes if articular reconstruction and stabilization with bicolumnar plating is done which allows for early mobilization of joint.

Identification of complex fracture fragments like posteromedial/postero-lateral is important. Column-specific fixation as described by Luo *et al* based-on CT scan is superior to fixation using Schatzker's classification which uses only AP view X-ray. Stabilization of posteromedial fragments by plating prevents subsequent varus collapse.

References

1. Yong Z, De-Gang F, Bao-An Ma, Si-Guo S. Treatment of complicated tibial plateau fractures with dual plating via a 2-incision technique. Orthop. 2012; 35: e359-64.
2. Shi-Min C, Sun-Jun H, Ying-Qi Z, Meng-Wei Y, Zuo Ma, Xin W, Jens D, Peer E. A surgical protocol for bicondylar four

quadrant tibial plateau fractures. Int J O rthop. 2014; 38: 2559-64.
3. Lee *et al*.: Comparison of outcome of unilateral locking plate and dual plating in the treatment of bicondylar tibial plateau fractures. Journal of Orthopaedic Surgery and Research 2014 9:62.
4. Ufuk O, Atilla SP. Dual locked plating of unstable bicondylar tibial plateau fracturs Int J Care Injured. 2016;46S:9-13.
5. Shah T, Gohiya A, Rai N, Gupta U, Sharma P, Verma R, Gaur S. Outcome Analysis of dual plating in bicondylar fracture of Tibia. Orthop JPMC. 2016; 22(2):42-46.
6. Mayank P, Jayant S, Sunil J. Functional outcome of dual plate osteosynthesis in type V & VI proximal tibial plateau fracture. Indian Journal of Orthopaedics Surgery. 2017;3(1):78-83.
7. Satveer S, Mahk N, Jayeshkumar D, Kurup CS. Study of dual plating in bicondylar fracture. Journal Orthopaedics. 2018; 6:856-60.
8. Bhalotia AP, Ingle MV, Koichade MR. Necessity of dual plating in bicondylar tibial plateau fracture dislocations: A prospective case series. J Orthop Traumatol Rehabil. 2018; 10:29-33.
9. Manjunath J, Ashish BC, Shashidhara H, Venkataramana R. A prospective study of surgical management of bicondylar schatzker type V & VI tibial plateau fracture by dual plating and dual incision. Int J of Orthop. 2019;5(3):46-54.
10. Caner C, Cemil K, Firat O, Taskin A, Huseyin GK, Kamil Y. Lateral locked plating or Dual plating: A comparison of two methods in simple bicondylar tibial plateau fractures. Clinics in Orthopaedic. 2019; 11:151-8.
11. Yadav RS, Venkatachalam K. A short-term prospective study of the clinical, functional and radiological outcomes of displaced intra-articular tibial plateau fractures treated surgically by dual incision and dual plating. Int J of Orthop. 2019 issue 7; 8:51-54
12. Bora SS, Senthil L, Thiyagarajan U, Pradeep JP, Raj GD.Unusual medial tibial plateau fracture fixation using dual plating. Int J Res Orthop. 2019; 5:1113-7.
13. Somashekara SA, Manoj HV, Ajay VM, Abhijit P, Preetham N. Functional outcome assessment of columnar fixation in proximal tibia fractures: A prospective study. Int J Orthop. 2020;6(1):491-6.