e-ISSN: 0975-1556, p-ISSN:2820-2643

Available online on www.ijpcr.com

International Journal of Pharmaceutical and Clinical Research 2023; 15(4); 1517-1528

Original Research Article

Study on Diaphyseal Humerus Fracture Treated with Plate Osteosynthesis by Anterolateral and Posterior Approach and Incidence of Iatrogenic Radial Nerve Injury

Gautam Chandra Paul[1], Shamim Ahmed Barbhuiya[2], Nagesh C S[3], Ch Rakesh Singha[4]

[1,2]Assistant Professor, Department of Orthopaedics, Silchar Medical College, Silchar, Assam

[3,4]Junior Resident, Department of Orthopaedics, Silchar Medical College, Silchar, Assam

Received: 05-02-2023 / Revised: 10-03-2023 / Accepted: 04-04-2023

Corresponding author: Dr. Nagesh C S

Conflict of interest: Nil

Abstract

Background: Humerus shaft fractures represent 3-5% of all fractures. Several methods have been used to treat diaphyseal humerus fractures. Open reduction and internal fixation by plate osteosynthesis for diaphyseal humerus fractures are alternatives that can be performed anteriorly, posterior, or minimally invasive. There haven't been many trials or studies to find the most effective treatment for diaphyseal humerus fractures.

Objectives: to compare the results of diaphyseal humerus fractures treated with open reduction and internal fixation with a plate using the anterolateral and posterior methods.

Methodology: It was a prospective comparison of the two methods for treating diaphyseal humerus fractures. All regular radiological and hematological studies were completed after the first evaluation and initial stabilization of the patients. Patients were informed about the procedure, given adequate consent, and prepped for surgery. Each patient received a randomly chosen management strategy. Patients were evaluated postoperatively using the American Shoulder and Elbow Surgeon (ASES) rating system at six weeks, three months, and six months.

Results: Simple transverse fractures of the AO type accounted for 36% of all fractures, according to Müller, followed by simple oblique fracture (28%), simple spiral fracture (16%), Spiral wedge fractures 6(12%), Bending wedge fracture (4%) and Fragmented wedge fractures (2%) and Complex spiral fracture 1(2%). 94% of patients who underwent anterolateral treatment had good results, compared to 96% of individuals who underwent posterior treatment. Three of the five difficulties included the anterolateral approach, and two involved the posterior approach.

Conclusion: For diaphyseal humerus fractures in the upper third and middle third, an anterior approach is a favorable choice; for fractures in the distal third, a posterior approach is preferable. In the posterior technique, iatrogenic radial nerve damage is less frequent.

Keywords: Diaphyseal humerus fractures, anterolateral, posterior approach.

Introduction

3-5% of all fractures [1] are humerus shaft fractures. Most humerus shaft fractures may be managed conservatively without surgery using devices like abduction casts, hanging

casts, and functional braces [2-4]. Conservative treatment frequently results in stiff shoulders and elbows, as well as a significant likelihood of non-union [5-9]. Today, more surgical intervention is being used to treat shaft humerus fractures, enabling earlier mobilisation and a quicker return to work [10,11]. A dynamic compression plate or an interlocking nail are two most common methods of fixation. Frequently occurring complications of nailing include restricted shoulder movements and delayed union [12-14]. Up to 20% of patients report shoulder pain as a result of rotator cuff damage, nail protrusion, or adhesive capsulitis [12-15]. According to Shao *et al*, secondary radial nerve palsy is another frequent consequence related to humeral plating [16]. Even though there are advantages and drawbacks to each treatment The gold standard for surgical treatment, according to Paris H *et al*, is plate and screw fixation for the middle part of the humerus' shaft [17].

The tension surface, which is theoretically posterior surface of humerus, is widely acknowledged as ideal surface of a long bone for the implantation of plates [18]. However, by adopting an anterolateral approach and positioning the plate on the antero-lateral surface of the humeral shaft, several authors have found outstanding results for plate osteosynthesis [19]. In the current series, we examined the surgical outcome of humerus plating using two different approaches and contrasted both methods in terms of procedural challenges, shoulder and elbow joint functions, outcome in terms of period of fracture consolidation, functional result, union rates and complication. The purpose of the study was to recommend appropriate management strategies for a better functional outcome and few problems.

The study's objective was to examine the results of diaphyseal humerus fractures managed by open reduction and internal fixation with plate using two alternative techniques, anterolateral and posterior.

Methods

Between January 2021 and December 2022, Silchar Medical College and Hospital will perform a prospective comparative research of the therapy of 50 humerus shaft fractures with locking compression plates using anterolateral and posterior methods. To minimize surgeon prejudice for any method, every patient had surgery in a different way. 25 patients underwent anterolateral surgery, while the remaining 25 underwent posterior surgery.

Age between 18 and 65 years, humerus shaft fracture, and trauma that occurred less than three weeks ago are the inclusion criteria. Patients with skeletal immaturity, primary radial nerve palsy, complex fractures, pathological fractures, and segmental fractures are excluded from the study. Following a standard pre-anaesthetic examination, each patient chose one of the two procedures in turn. Two orthopaedic surgeons experienced in both methods execute all procedures.

Surgical technique:

Anterolateral approach

Following general or brachial anesthesia, depending on the anesthesiologist's discretion and the patient's overall condition, the patient is put in the supine position. After painting and draping, a skin incision is made along the lateral border of the biceps tendon. To reveal the fracture site along the lateral border of the biceps, the brachialis muscle was separated. The lateral edge of the humerus was visible subperiosteally. After reduction, locking compression plates were installed with or without interfragmentary screws. For suitable stability, fixation was performed with a minimum of four screws (8 cortices) in each

section. A negative suction drain was used to close the incision after plate fixation. For two weeks, the arm was splinted. A clinical examination was performed to check for secondary radial nerve palsy, and post-operative radiographs were taken to check for adequate reduction. Beginning as tolerated, the shoulder and elbow physical treatment, **Figure 1.**

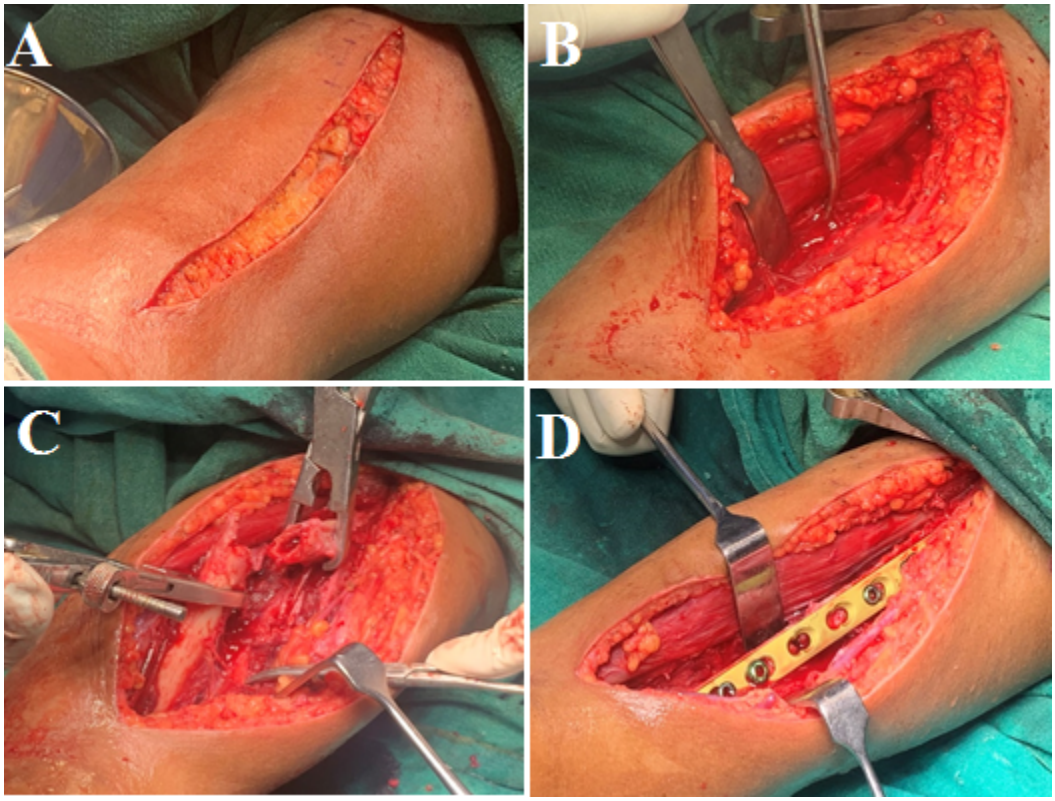

Figure 1: (A) Incision, (B) Lateral border of Biceps brachii muscle, (C) Fracture ends, (D) Fixation with Narrow LCP

Posterior approach

Following anesthesia, the patient was positioned to the side. After applying paint and drapes, a palpable midline longitudinal skin incision is made. The fracture location was revealed when the triceps muscle was divided along its fibers. A tube is used to investigate and hold the radial nerve. The radial nerve dynamic compression plate is fixed with a minimum of 8 cortices on each side with suitable handling. According to the anterolateral method, rest closure, postoperative protocol, and physical therapy are practiced, **Figure 2.**

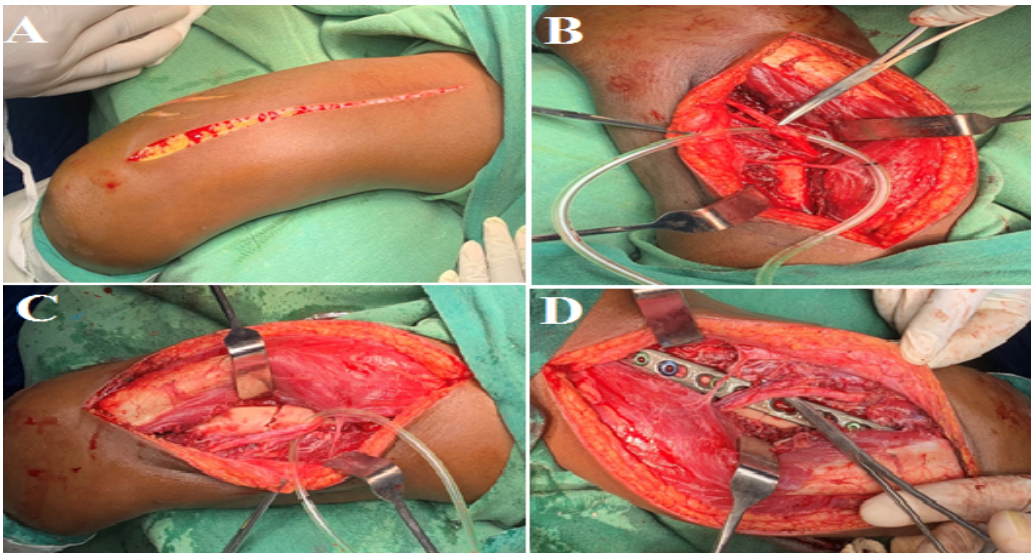

Figure 2: (A) Incision, (B) Radial nerve dissection, (C) Fracture reduction, (D) Fixation with Narrow LCP

Regardless of surgical method, all 50 patients are monitored with radiographs and clinical exams on the second post-operative day, two weeks, six weeks, three months, six months, and one year after surgery. The American Shoulder and Elbow Surgeons (ASES) grading system was used to evaluate patients' radiographic union, subsequent radial nerve palsy, and its recovery.

Results

50 individuals with humeral diaphyseal fractures were enrolled in the research over the course of a year. The youngest patient was 19 years old and the oldest patient was 60 years old in all 50 cases of diaphyseal humerus fractures treated with open reduction and internal fixation by plate osteosynthesis using anterolateral or posterior methods. One of the two approaches was randomly assigned to patients. Anterolateral open reduction and internal fixation was performed on 25 (50%) patients with diaphyseal humerus fractures, while posterior open reduction and internal fixation was performed on 25 (50%) patients with diaphyseal humerus fractures,

Table 1: Age wise distribution of all patients

Age groups (years)	Number	Percentage (%)
20-30	21	42
31-40	13	26
41-50	10	20
51-60	6	12
Total	50	100

The age range most frequently affected was 20 to 30 years (42%) and majority of patients (68%) were under age of 40, **Table 1.**

Table 2: Gender wise distribution

Gender	No.	%
Male	33	66
Female	17	34
Total	50	100

Out of 50 patients in our research, 33 (66%) were men and 17 (34%) were women, **Table 2.**

Table 3: Side wise distribution

Side	Number	Percentage (%)
Right	30	60
Left	20	40
Total	50	100

Out of 50 patients in this study, 30 (60%) had fractures of the right side of the diaphyseal humerus, and 20 (40%) had fractures of the left side of the diaphyseal humerus **Table 3.**

Table 4: Mode of injury distribution

Mode of injury	No.	%
Road traffic accident	28	56
Fall on outstretched hand	13	26
Fall from height	09	18
Total	50	100

28 patients (56%) had road traffic accidents as their most prevalent mode of injury. Among 13 (26%) patients, falling on an outstretched hand was the second-most frequent injury, **Table 4.**

Table 5: Diaphyseal level of injury

Level	Number	Percentage (%)
Upper third	08	16
Middle third	24	48
Lower third	18	36
Total	50	100

In the current study, 8 diaphyseal humerus fractures occurred at the level of the upper third of the diaphysis, 24 at the level of the middle third of the diaphysis, and 18 at the level of the lower third of the diaphysis, **Table 5.**

Table 6: Fracture Classification

Muller AO type (fracture)	Number	Percentage (%)
A1 -Simple spiral	08	16
A2- Simple oblique	14	28
A3-Simple transverse	18	36
B1- Spiral wedge	06	12
B2-Bending wedge	02	04
B3-Fragmented wedge	01	02
C1- Complex spiral	01	02
C2-Complex segment	00	00
C3-Complex irregular	00	00
Total	50	100

According to the Müller AO classification of diaphyseal humerus fractures, simple transverse fractures were the most frequent kind of fracture in 18 (36%) individuals. Simple oblique fractures (14, 28%), Simple spiral fractures (8, 16%), Spiral wedge fractures (6, 12%), Bending wedge fractures (2, 4%), Fragmented wedge fracture (1, 2%), and Complex spiral fracture (1, 2%) were other prevalent types of fractures, **Table 6.**

Table 7: Time for union

Time in weeks	Number	Percentage (%)
20-22 weeks	06	12
22-24 weeks	26	52
24-28 weeks	10	20
28-30 weeks	08	16
Total	50	100

The first indication of union in the 50 patients was assessed. In the following time frames: 6 (12%) patients showed radiological union signals in the first 20–22 weeks; 26 (52%) patients in the second 22–24 weeks; 10 (20%) patients in the second 24-28 weeks; and 8 (16%) patients in the second 28–30 weeks. The average time for union of the 50 patients with diaphyseal humerus fractures treated with plate osteosynthesis was 23.24 weeks, **Table 7.**

Table 8: Results in patients after operative procedure

Results	Number	Percentage (%)
Excellent	47	94
Good	03	06
Poor	00	00
Total	50	100

Of the 25 patients, five had anterolateral open reduction and internal fixation by plate osteosynthesis. 2 (4% of patients) got good results, whereas 23 (46%) had great results. 25 individuals had posterior approach surgery as well. A total of 24 patients (48%) got outstanding results, 1 patient (2%), good results, and none, bad results, **Table 8.**

Table 9: ASES scoring of each patient at the time of follow up

ASES score	Number	Percentage (%)
81-100	47	94
71-80	03	06
61-70	00	00
51-60	00	00
<50	00	00

Of all the patients, 47 (94%) had ASES scores between 81 and 100, and 3 (6%), between 71 and 80, **Table 9.**

Table 10: Complications in patients with both approach

Complication	Approach		Total
	Anterolateral	Posterior	
Iatrogenic nerve injury (Neuropraxia)	02	00	02
Infection	00	01	02
Residual pain	00	01	02
Post-operative malalignment	01	00	01
Nonunion	-	-	-
Plate breakage	-	-	-
Delayed union	-	-	-
Total	03	02	05

Total 5 complications encountered among all patients. Among them 3(6%) were with anterolateral and 2 (4%) were with posterior approach. The common complications were iatrogenic nerve injury (radial nerve neuroproxia) with anterolateral approach in 2(4%) patients, post-operative malalignment with anterolateral approach seen in 1(2%) patient, residual pain seen in 1(2%) patient in posterior approach, and infection in 1(2%) patient in posterior approach, **Table 10, Figure 3-6.**

Figure 3: ANTEROLATERAL APPROACH: Movements at final follow up

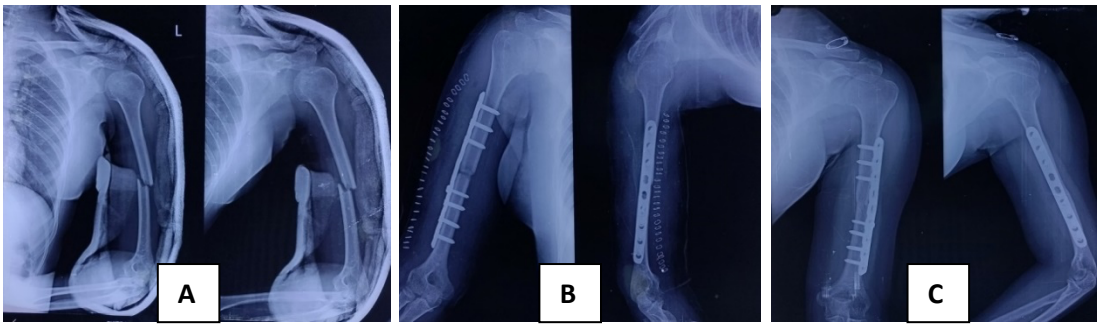

Figure 4: ANTEROLATERAL APPROACH: X-rays; (A) Pre-op x-ray, (B) Post-op X-ray, (C) Final follow up X-ray

Figure 5: POSTERIOR APPROACH: Movements at final follow up

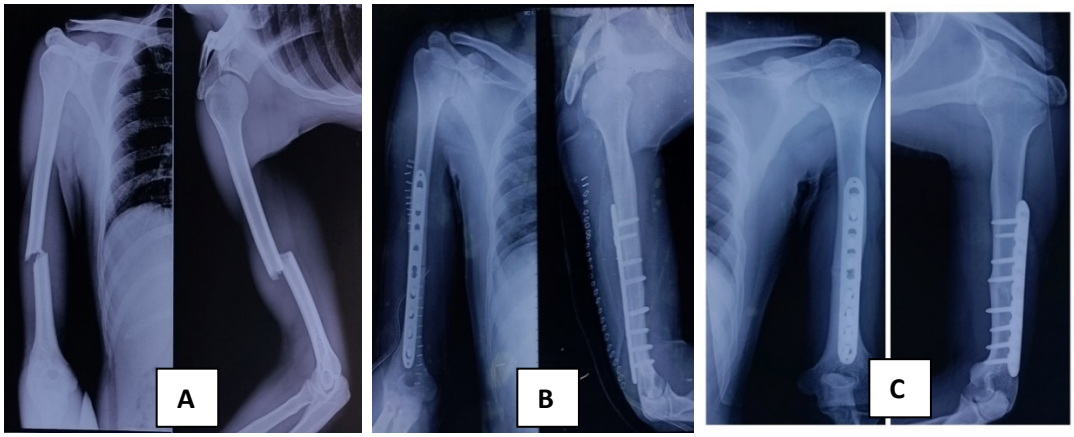

Figure 6: POSTERIOR APPROACH: X-rays: Pre-op, Post-op, Final follow up

Discussion

The most frequent long bone fracture in the upper limb is a fracture of the humerus, which accounts for 3-5% of all fractures [1]. Road traffic accidents are the most prevalent cause of humerus fracture, which is more common in men and peaks in occurrence in the third decade [25].

The following are indications for surgical treatment..

- Failed reduction by closed method
- Primary radial nerve palsy
- Pathological fracture
- Floating elbow
- Compound fracture
- Associated with neurovascular injury.
- Segmental fracture

Although most shaft fractures may be treated conservatively, surgical fixation is becoming more and more popular in order to

achieve early mobilization and avoid stiffness.

In this study, anterolateral and posterior methods were used to treat diaphyseal humerus fractures with open reduction and internal fixation with plate osteosynthesis. A total of 50 patients might be enrolled throughout a two-year period. Patients in this research ranged in age from 20 to 65, with a mean of 32. Younger age groups had increased rates of diaphyseal fractures. A similar pattern of age distribution was seen in the study of Singisetti K. *et al* [20]. The highest occurrence occurred in the age range of 21 to 40 years. The male to female ratio reached 1.94:1. McCormack *et al* [21] (4:1) and Rommen's *et al* [5] (5:1) both described similar findings. The study's mostly male population can be attributed to the study's mechanism of injury, which is road traffic injuries and falls on outstretched hands, which frequently include men. In the current study, 25% of patients had left side dominance and 75% had right side dominance. 60% of the 75% of patients with right side dominance who also had fractures of the diaphyseal humerus on the right side and 15% of those with fractures on the left did so. Out of 25% of patients who were left-sided dominant, 18% had a left-sided diaphyseal humerus fracture, and 7% suffered a right-sided diaphyseal humerus fracture. These outcomes mirrored those noted by Gichunge P *et al* [22]. This suggests that the dominant side has higher fracture risk than the non-dominant location.

In this study, road traffic accidents were the most frequent mode of injury, accounting for 56% of patients. Similar findings were made in other studies by Crates *et al*[23] and Romans *et al*[24], which identified automobile accidents as the most prevalent cause of humeral diaphyseal fractures. Young people frequently fracture as a result of road accidents. Additionally, given that diaphyseal fractures of the humerus are frequently found in young people, road traffic accidents may be a prevalent source of these injuries. In this study, there were 16% patients with fractures in the top third of the diaphysis, 48% patients with fractures in the middle third, and 36% patients with fractures in the bottom third. The middle part of the humerus diaphysis, however, has the largest risk of fracture, according to the majority of research. Simple transverse diaphyseal humerus fractures occur in 36.0% of patients.

96% of the patients had fantastic results, while 4% had fair results. These findings concurred with research by Mccormack RG, *et al* [21]. 46% of patients who had open reduction and internal fixation by plate osteosynthesis using the anterolateral technique had excellent outcomes, while 4% had satisfactory results. Furthermore, 48% of patients who underwent surgery for a diaphyseal humerus fracture had excellent results, whereas 2% had good results. There is little research on the subject of contrasting plate osteosynthesis and other diaphyseal humerus fracture treatment methods. The majority of patients (52%) and patients with fracture union between 24-28 weeks (20%). 23.24 weeks on average were spent in a union. The American Shoulder and Elbow Surgeons (ASES) Score method was employed in the current investigation. 94% of all patients had an ASES score between 81 and 100, while 6% had an ASES score between 71 and 80. This performance was comparable to investigations carried out by Ginchunge *et al* [22]. For plating with an anterior approach, the mean ASES score was 94%, and for plating with a posterior approach, it was 96%. Both strategies had comparable average ASES scores. These results demonstrate that, when plating, the anterolateral and posterior methods produce functional results that are equivalent as shown by the ASES score. According to this study, neither group significantly

outperformed the other in terms of expected outcomes. One (2% of patients) experienced residual discomfort, whereas two (4% of patients) experienced neuropraxia of the radial nerves. These outcomes matched those of the research by Abalo *et al* [26], which found an 8.7% rate. Radial nerve palsy was shown to occur in 4.7% of people in another investigation by Bernard de Dompsure *et al* [27]. Because 75% of the humerus shaft is accessible after mobilization of the radial nerve, the posterior approach to shaft humerus fracture is advantageous. For nerve exploration in preoperative radial nerve palsy with diaphyseal shaft fractures, the posterior route is preferable. Iv antibiotics were used to treat infection in one (2% of) the patients with the posterior route, but none of the patients with the anterior method. Results from the two methods were equivalent. This study's overall infection rate was modest, matching that of studies by Foster R *et al* [28], which had a 3% infection rate, and McCormack *et al* [21], which had a 5% infection rate. Significant soft tissue exposure and periosteal stripping are related with infection. For the treatment of diaphyseal humerus fractures, both methods are equally beneficial in terms of fracture union and functional result.

Even though Henry's [29], anterolateral approach can expose the entire humeral shaft without the need to see the radial nerve, placing a plate on the lateral surface could endanger the nerve during the retraction of soft tissues or by the implant itself, particularly if it is placed over the middle to distal thirds of the shaft where the radial nerve is in close contact with the bone. Placing plates on the lateral surface is associated with a 12% documented worldwide incidence of iatrogenic radial nerve damage [30]. As there was iatrogenic nerve injury(neuropraxia) in 2(4%) patients in anterolateral approach, patients were advised physiotherapy with dynamic cockup splint and both the patients improved radial nerve function within 3 months of operative procedure. In posterior approach, as radial nerve is explored and the dissected in its length at the fracture site. As the nerve is explored and visualised there is less chances of iatrogenic nerve injury in posterior approach. Post-operative malalignment was seen 1(2%) patient with anterolateral approach.

Conclusion

For diaphyseal humerus fractures in the upper third and middle third, an anterior approach is a favorable choice; for fractures in the distal third, a posterior approach is preferable. The incidence of iatrogenic radial nerve damage is lower with the posterior approach. The sample size was far smaller, though. To draw precise conclusions, a research with a large patient group is necessary.

References

1. Court-Brown CM, Caesar B. Epidemiology of adult fractures: a review. Injury. 2006 Aug 1;37(8):691-7.
2. Böhler L. Conservative treatment of fresh closed fractures of the shaft of the humerus. Journal of Trauma and Acute Care Surgery. 1965 Jul 1;5(4):464-8.
3. Sarmiento A, Zagorski JB, Zych GA, Latta LL, Capps CA. Functional bracing for the treatment of fractures of the humeral diaphysis. JBJS. 2000 Apr 1;82(4):478.
4. Koch PP, Gross DF, Gerber C. The results of functional (Sarmiento) bracing of humeral shaft fractures. Journal of shoulder and elbow surgery. 2002 Mar 1;11(2):143-50.
5. Rommens PM, Verbruggen J, Broos PL. Retrograde locked nailing of humeral shaft fractures. A review of 39 patients. The Journal of bone and joint surgery. British volume. 1995 Jan;77(1):84-9.

6. Patra BP, Patra SK. Radial nerve palsy following plate osteosynthesis of shaft humerus in relation to posterior verses anterolateral approach. Int J Res Med Sci. 2016 Mar;4(3):913-9.
7. Foulk DA, Szabo RM. Diaphyseal humerus fractures: natural history and occurrence of nonunion. Orthopedics. 1995 Apr 1;18(4):333-5.
8. Healy WL, White GM, Mick CA, Brooker JR AF, Weiland AJ. Nonunion of the humeral shaft. Clinical Orthopaedics and Related Research (1976-2007). 1987 Jun 1; 219:206-13.
9. Jupiter JB, von Deck M. Ununited humeral diaphyses. Journal of Shoulder and Elbow Surgery. 1998 Nov 1;7(6):644-53.
10. Heim D, Herkert F, Hess P, Regazzoni P. Surgical treatment of humeral shaft fractures—the Basel experience. Journal of Trauma and Acute Care Surgery. 1993 Aug 1;35(2):226-32.
11. Heim D, Herkert F, Hess P, Regazzoni P. Surgical treatment of humeral shaft fractures—the Basel experience. Journal of Trauma and Acute Care Surgery. 1993 Aug 1;35(2):226-32.
12. Brumback RJ, Bosse MJ, Poka A, Burgess AR. Intramedullary stabilization of humeral shaft fractures in patients with multiple trauma. JBJS. 1986 Sep 1;68(7):960-70.
13. Chao TC, Chou WY, Chung JC, Hsu CJ. Humeral shaft fractures treated by dynamic compression plates, Ender nails and interlocking nails. International orthopaedics. 2005 Apr;29(2):88-91.
14. Chapman JR, Henley MB, Agel J, Benca PJ. Randomized prospective study of humeral shaft fracture fixation: intramedullary nails versus plates. Journal of orthopaedic trauma. 2000 Mar 1;14(3):162-6.
15. Bhandari M, Devereaux PJ, D Mckee M, H Schemitsch E. Compression plating versus intramedullary nailing of humeral shaft fractures—a meta-analysis. Acta orthopaedica. 2006 Jan 1;77(2):279-84.
16. Shao YC, Harwood P, Grotz MR, Limb D, Giannoudis PV. Radial nerve palsy associated with fractures of the shaft of the humerus: a systematic review. The Journal of bone and joint surgery. British volume. 2005 Dec;87(12):1647-52.
17. Shetty MS, Kumar MA, Sujay KT, Kini AR, Kanthi GK. Minimally invasive plate osteosynthesis for humerus diaphyseal fractures. Indian journal of orthopaedics. 2011 Dec;45(6):520-6.
18. Dalal B, Damor H, Suthar R, Rathod D, Panchal H. Comparative Study of Results of Anterior Vs Posterior Plating for Shaft Humerus Fractures. National Journal of Integrated Research in Medicine. 2017 Jul 1;8(4).
19. Reynders P, Nijs S, Broos PL, Stoffelen D. Posterior Approach to the Humeral Shaft. Osteosynthesis and Trauma Care. 2003 Mar;11(01):10-2.
20. Singisetti K, Ambedkar M. Nailing versus plating in humerus shaft fractures: a prospective comparative study. International orthopaedics. 2010 Apr; 34:571-6.
21. McCormack RG, Brien D, Buckley RE, McKee MD, Powell J, Schemitsch EH. Fixation of fractures of the shaft of the humerus by dynamic compression plate or intramedullary nail: a prospective, randomised trial. The Journal of bone and joint surgery. British volume. 2000 Apr;82(3):336-9.
22. Gichunge PM. Functional outcome of operative management of humeral shaft fractures (Doctoral dissertation, University of Nairobi).
23. Crates J, Whittle AP. Antegrade interlocking nailing of acute humeral shaft fractures. Clinical Orthopaedics and Related Research®. 1998 May 1; 350:40-50.

24. Ricchetti ET, DeMola PM, Roman D, Abboud JA. The use of precontoured humeral locking plates in the management of displaced proximal humerus fracture. JAAOS-Journal of the American Academy of Orthopaedic Surgeons. 2009 Sep 1;17(9):582-90.
25. Tsai CH, Fong YC, Chen YH, Hsu CJ, Chang CH, Hsu HC. The epidemiology of traumatic humeral shaft fractures in Taiwan. International orthopaedics. 2009 Apr; 33:463-7.
26. Walla A, Ayouba G, Landoh DE, Bakriga B, Towoezim T, Abalo A, Dossim AM. Predictors of Nonunion in Humerus Shaft Fractures in Adults in Lomé (Togo). Open Journal of Orthopedics. 2015;5(11):361.
27. de Dompsure RB, Peter R, Hoffmeyer P. Uninfected nonunion of the humeral diaphyses: review of 21 patients treated with shingling, compression plate, and autologous bone graft. Orthopaedics & Traumatology: Surgery & Research. 2010 Apr 1;96(2):139-46.
28. Foster RJ, Dixon Jr GL, Bach AW, Appleyard RW, Green TM. Internal fixation of fractures and non-unions of the humeral shaft. Indications and results in a multi-center study. JBJS. 1985 Jul 1;67(6):857-64.
29. Kuhne MA, Friess D. Supine extensile approach to the anterolateral humerus. Orthopedics. 2016 Jan 1;39(1):e193-5.
30. KettelkamP DB, Alexander H. Clinical review of radial nerve injury. Journal of Trauma and Acute Care Surgery. 1967 May 1;7(3):424-32.