e-ISSN: 0975-1556, p-ISSN:2820-2643

Available online on www.ijpcr.com

International Journal of Pharmaceutical and Clinical Research 2023; 15(4); 164-170

Original Research Article

Histological Grading, Histochemical (Agnors) and Immunohistochemical (P53) Profile of Oral Squamous Cell Cancer

Neelima Verma[1], Saumya Singh Rajput[2]

[1]Professor, Department of Pathology, GSVM Medical College, Kanpur, Uttar Pradesh
[2]Junior Resident-3, Department of Pathology, GSVM Medical College, Kanpur, Uttar Pradesh

Received: 15-01-2023 / Revised: 11-02-2023 / Accepted: 20-03-2023
Corresponding author: Dr. Saumya Singh Rajput
Conflict of interest: Nil

Abstract

Background: A significant contributor to cancer morbidity and mortality globally, oral cancer is the sixth most prevalent malignancy. Studies using the immunohistochemical technique (IHC) have examined OSCC to learn more about its biology, prognosis, and therapeutic options. The proliferation potential of a specific tumour can be quantitatively assessed through the immunohistochemical detection of p53. So, the present study was conducted with an aim to analyse the correlation of the histo-morphological grading using Anneroth's grading with the nuclear proliferative markers (AgNORs and p53 protein) in oral squamous cell carcinoma.

Methods: The present hospital based cross-sectional study was carried out under the department of Pathology, among biopsy samples of 53 patients of Oral squamous cell carcinoma of GSVM Medical College, for a duration of one year. Hematoxylin and eosin (H&E) stain was used to perform histopathology on sections of specimens that had been embedded in paraffin. Using Anneroth's multifactorial grading approach for SCC, the tumor's histological grade was established. Smears and sections were stained with AgNOR silver and the AgNOR score was expressed as the mean AgNOR count (mAgNOR) One-Way Analysis of Variance (ANOVA) was used to find out the significant correlations and a p-value of <0.05 was considered significant.

Results: Most of patients were males (69.8%) and most commonly affected age group were 41-50 years (34.0%) and 51-60 years (37.7%). The most affected site of OCSS was buccal mucosa (41.5%) and gingivo-buccal sulcus (32.1%). Anneroth's multifactorial grading system for OSCC showed that 32.1% of patients belonged to Grade I, 37.7% were having Grade II, and Grade III was seen in 30.2% of patients. The ANOVA analysis was used to find the difference of mean AgNOR score (per nucleus) and mean p53 score (% of cells stained) in different grades of Anneroth grading for OSCC and it was found that difference was statistically significant mean AgNOR score (F=126.234, df=2, p=0.000) and mean p53 score (F=12.343, df=2, p=0.000).

Conclusion: To improve treatment outcomes for patients with OSCC, pathologists and clinicians should make it normal procedure to determine the histochemical and immunohistochemical profile and its relationship to the histo-pathological grade and clinical features.

Keywords: immunohistochemical, p53, oral squamous cell carcinoma, AgNOR, ANOVA

This is an Open Access article that uses a funding model which does not charge readers or their institutions for access and distributed under the terms of the Creative Commons Attribution License (http://creativecommons.org/licenses/by/4.0) and the Budapest Open Access Initiative (http://www.budapestopenaccessinitiative.org/read), which permit unrestricted use, distribution, and reproduction in any medium, provided original work is properly credited.

Introduction

A significant contributor to cancer morbidity and mortality globally, oral cancer is the sixth most prevalent malignancy. Squamous cell carcinoma (SCC), an epithelial-derived tumour, accounts for more than 90% of cancers that start in the head and neck region. Clinically obvious premalignant lesions can appear before oral squamous cell carcinoma (OSCC) [1,2,3].

For the majority of malignant neoplasms, histological grading is a well-established pathological prognostic factor, and evaluating the genes that influence these grades is a common characteristic tool to determine a patient's prognosis. In clinical laboratories, the Squamous Cell Carcinoma (SCC) grading system developed by Borders in 1921 is frequently employed [4].

In order to grade squamous cell carcinoma, Jakobsson developed a new histological grading system based on the microscopic features of the tumour cells and the interactions between the tumour and the host components. Pathologists and oncologists used this approach well; nevertheless, due to its time-consuming nature, it did not gain widespread appeal. By Anneroth et al. and Bryne et al., this histological grading system of Jakobsson was improved upon and updated, and a select few characteristics were only used to assess the tumor-host interface. It has been demonstrated to be more time efficient, prognostically beneficial, and to have strong inter- and intraobserver reliability [5,6].

Studies using the immunohistochemical technique (IHC) have examined OSCC to learn more about its biology, prognosis, and therapeutic options. The understanding of the underlying cell cycle control and other molecular mechanisms in mammalian cells has advanced quickly in recent years. The proliferation potential of a specific tumour can be quantitatively assessed through the immunohistochemical detection of p53. Also related to tumour grade, high grade and aggressive carcinomas exhibit upregulated p53 expression. Cell growth and proliferation are closely synchronised [7,8].

By regulating both ribosome synthesis and cell cycle progression, the tumour suppressor proteins pRb and p53 play a crucial part in regulating growth and proliferation. Upregulation of rRNA synthesis ensures adequate growth of cancer cells with uncontrolled cell cycle in tumours with altered pRb and p53 function [9,10].

So, the present study was conducted with an aim to analyse the correlation of the histo-morphological grading using Anneroth's grading with the nuclear proliferative markers (AgNORs and p53 protein) in oral squamous cell carcinoma.

Materials and Methods

The present hospital based cross-sectional study was carried out under the department of Pathology, among biopsy samples of 53 patients of Oral squamous cell carcinoma admitted or attending IPD/OPD of Departments of Otorhinolaryngology and Dentistry, GSVM Medical College, for a duration of one year between July 2021 to June 2022. The ethical approval was obtained from the institutional review board.

Hematoxylin and eosin (H&E) stain was used to perform histopathology on sections of specimens that had been embedded in paraffin. Using Anneroth's multifactorial grading approach for SCC, the tumor's histological grade was established. Three parameters describing tumour cell characteristics, including keratinization, polymorphism, and mitoses, were assessed in the entire of the tumor's thickness and each was given a score between 1 and 4.

The most invasive margins were graded for invasion mode and inflammatory infiltration indicative of the interaction between the tumour and the host, and scores ranged from 1 to 4. According to the degree of each parameter, points 1, 2, 3, and 4 were assigned. The sum of the total points by each patient for each parameter was calculated. The final grading was done as, Grade I: score 6-12; Grade II: score 13-18 and Grade III: score 19-24 [11].

Smears and sections were stained with AgNOR silver. Smears were examined with a 40X objective, and sections using a 100X objective. 100 tumour cells in each smear and section were given an AgNOR score. Dark brown or black intranuclear dots were recognised as AgNORs, and the number and appearance of dots in each nucleus were determined. If the little AgNORs could not be distinguished from one another, they were grouped together and counted as a single unit. The AgNOR score was expressed as the mean AgNOR count (mAgNOR) [12].

IHC was carried out employing an HRP detection technique based on non-biotin polymers. As instructed by the manufacturer, slides were incubated with p53 (Biogenix, USA) at room temperature. By counting the number of brown-stained tumour nuclei in hotspots, the percentage of p53 was calculated. In each case approximately 1000 tumor cells were examined [13].

Data Analysis

The collected data was entered in the MS excel sheet. The variables were presented as frequency and percentages. One-Way Analysis of Variance (ANOVA) was used to find out the significant correlations and a p-value of <0.05 was considered significant. Data analysis was conducted using Statistical Package for Social Sciences (SPSS) version 21.0.

Results

In our study, a total of 53 biopsy samples of patients with Oral squamous cell carcinoma was examined. Most of patients were males (69.8%) and most commonly affected age group were 41-50 years (34.0%) and 51-60 years (37.7%). The most affected site of OCSS was buccal mucosa (41.5%) and gingivo-buccal sulcus (32.1%). Anneroth's multifactorial grading system for OSCC showed that 32.1% of patients belonged to Grade I, 37.7% were having Grade II, and Grade III was seen in 30.2% of patients (Table 1).

Table 1: Baseline characteristics of the patients with OSCC.

Variables	Frequency	%
Gender		
Male	37	69.8
Female	16	30.2
Age group (in years)		
<40	6	11.3
41-50	18	34.0
51-60	20	37.7
61-70	8	15.1
>70	1	1.9
OSCC site		1.4
Buccal mucosa	22	41.5
Gingivo-buccal sulcus	17	32.1
Tongue	8	15.1
Alveolus	6	11.3
Anneroth grading for OSCC		

Grade I	17	32.1
Grade II	20	37.7
Grade III	16	30.2

Figure 1. shows that OSCC of grade I as per Anneroth's multifactorial grading system was well differentiated, OSCC of grade II as per Anneroth's multifactorial grading system was moderately differentiated and OSCC of grade III as per Anneroth's multifactorial grading system was poorly differentiated.

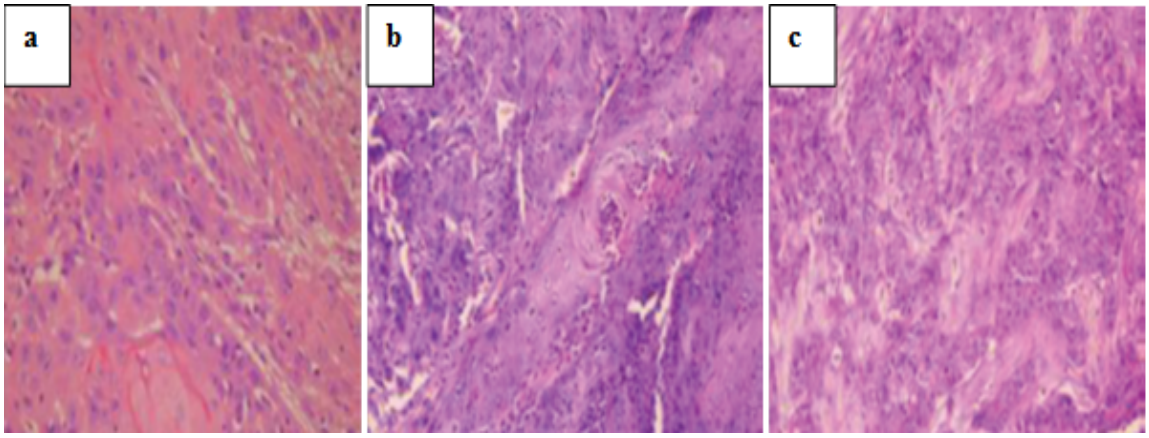

Figure 1: H&E, 20x. A. Anneroth Grade I OSCC. b. Anneroth Grade II OSCC. c. Anneroth Grade III OSCC.

OSCC of grade I as per Anneroth's multifactorial grading system showed few nucleolar organizer regions (NORs)/nucleus, OSCC of grade II as per Anneroth's multifactorial grading system showed several different sized nucleolar organizer regions (NORs)/nucleus; and OSCC of grade III as per Anneroth's multifactorial grading system showed great amount and highly stained nucleolar organizer regions (NORs) (Figure 2).

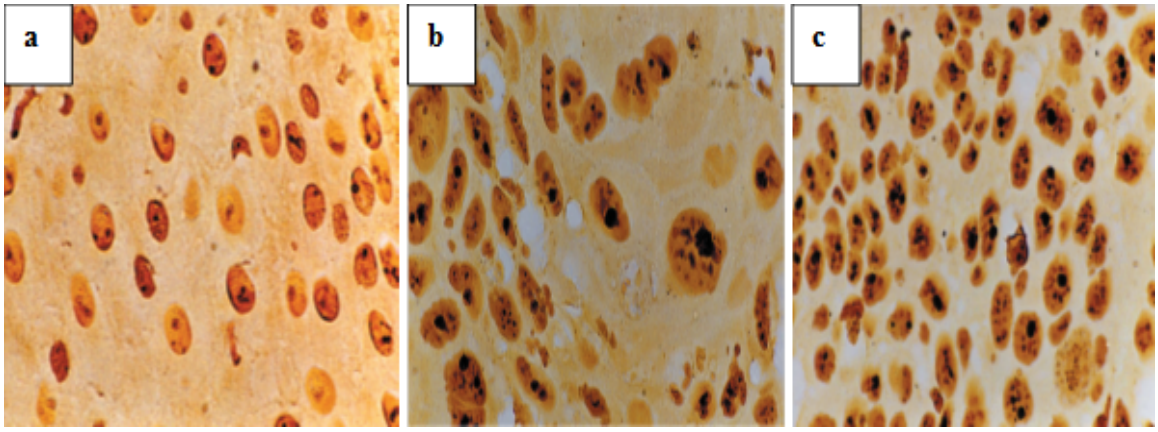

Figure 2: AgNOR, 400x. a. AgNOR in Anneroth Grade I OSCC. b. AgNOR in Anneroth Grade II OSCC. c. AgNOR in Anneroth Grade III OSCC.

OSCC of grade I as per Anneroth's multifactorial grading system showed p53 expression and negative staining in central keratinized areas, OSCC of grade II as per Anneroth's multifactorial grading system showed the tumor cells positively staining with p53; and OSCC of grade III as per Anneroth's multifactorial grading system showed great amount tumor cells positively staining with p53 (Figure 3).

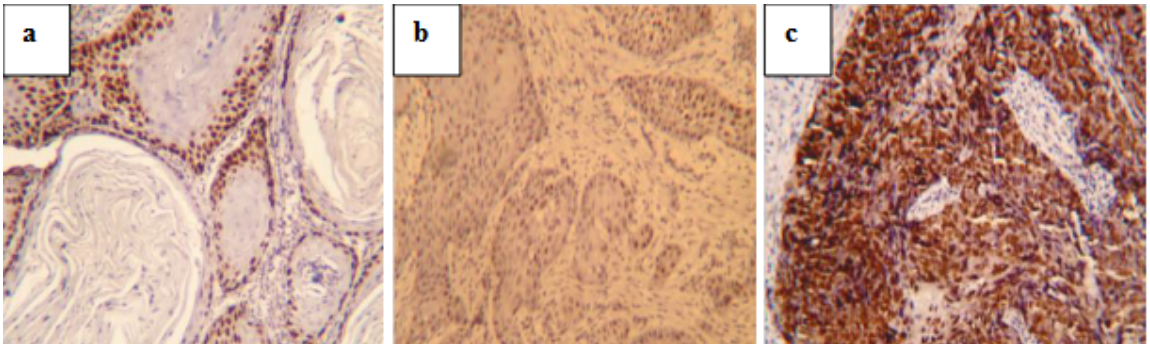

Figure 3: p53 IHC, 100x. a. p53 expression in Anneroth OSCC. b. p53 expression in Anneroth Grade II OSCC. c. p53 expression in Anneroth Grade III OSCC.

The ANOVA analysis was used to find the difference of mean AgNOR score (per nucleus) in different grades of Anneroth grading for OSCC and it was found that difference was statistically significant (F=126.234, df=2, p=0.000). Similarly, the ANOVA analysis was used to find the difference of mean p53 score (% of cells stained) in different grades of Anneroth grading for OSCC and it was found that difference was statistically significant (F=12.343, df=2, p=0.000).

Table 2: Correlation between histo-morphological grading using Anneroth's grading with the nuclear proliferative markers (AgNORs and p53 protein) in OSCC.

Anneroth grading for OSCC	Mean AgNOR score (Per nucleus)	Mean p53 score (% of cells stained)
Grade I	3.37±0.81	25.47±21.72
Grade II	5.28±0.74	43.53±29.48
Grade III	7.21±0.46	73.39±31.57
Test of significance	**F=126.234, df=2, p=0.000**	**F=12.343, df=2, p=0.000**

Discussion

Anoxia, improper signaling by mutant oncoproteins, DNA damage, and other stressors can all cause the p53 protein to become active, which serves as the cell's main stress sensor. Cell cycle arrest, DNA repair, cellular senescence, and apoptosis are all regulated by the protein p53, which also regulates their expression and function. Immunohistochemical analyses (IHC) can be performed often to show the mutant p53 protein in tissue samples because the mutant p53 protein is stabilised, whilst the normal p53 protein is undetectable [14].

In our study, squamous cell carcinoma with well-differentiated and moderately-differentiated tumour islands exhibited p53 staining in peripheral cells and lacked staining in regions of keratin pearl production; squamous cell carcinoma with poorly differentiated tumour islands had p53 staining of malignant nuclei. P53 staining intensity varied between mild and high in various cases. No matter how intense the staining was, cases were declared positive.

In our study the mean p53 score (% of cells stained) in Anneroth grade I (25.47±21.72), grade II (43.53±29.48) and grade III (73.39±31.57) were significantly increasing ($p<0.05$). The mean p53 score (% of cells stained) in Anneroth grade I, grade II, and grade III were significantly increasing in studies by Kaur et al., (grade I: 14, grade II: 78 and grade III: 100, $p<0.001$), Pandya et al., (grade I: 42.625, grade III: 48.888, grade III: 70.285, $p<0.001$), and Kaur et al., (grade I: 20, grade II: 72, and grade III: 88, p=0.004) [15,16,17].

A significant amount of study has been done recently on the possible diagnostic and prognostic uses of AgNOR staining. AgNOR quantification can serve as an

effective method for analysing cell kinetics. AgNOR build up during interphase is linked to an increased need for ribosome biogenesis in cells beginning the mitotic cycle. It is well known that when compared to slowly proliferating cells, rapidly dividing cells produce proteins more quickly. As a result, it is anticipated that the nucleolar structures (AgNORs), where rRNA synthesis occurs, will grow. These factors have led to the AgNOR parameter being suggested as a valid marker for determining the rate of cell proliferation in routinely handled histopathological samples [18].

Because the yellow staining made it simple to see individual NORs in our study, AgNORs were visible as black to brownish specks inside the cell nucleus under a light microscope. The NORs, which are typically round in shape, varied in size and distribution throughout the nuclear area. They were also gathered into a large, circular structure with less intense staining. AgNORs that were clustered had a smaller diameter and varied in number more than those that were diffusely arranged.

In our study the mean AgNOR score (per nucleus) in Anneroth grade I (3.37±0.81), grade II (5.28±0.74) and grade III (7.21±0.46) were significantly increasing ($p<0.05$). The mean AgNOR score (per nucleus) in Anneroth grade I, grade II, and grade III were significantly increasing in studies by Gulia et al., (grade I: 4.71±0.81, grade II: 6.34±0.89, and grade III: 8.70±0.65), Hanemann et al., (grade I: 3.20±0.61, grade II: 5.33±1.42, and grade III: 8.27±0.39), Manu et al., (grade I: 3.296±0.631, grade II: 4.29±0.789, and grade III: 5.21±0.16), Sharma et al., (grade I: 3.305±0.11, grade II: 5.324±0.43, and grade III: 8.167±0.22,), and Chauhan et al., (grade I: 2.36, grade II: 3.72, and grade III: 5.83) [19,20,21,22,23,24].

Conclusion

According to the findings of our study, there is a positive association between the histopathological grades of OSCC and nuclear proliferative indicators on histochemistry (AgNOR count) and immunohistochemistry (p53 expression). It suggests that these nuclear proliferative markers give the clinician and the histopathologist a helpful hint to forecast the rate of proliferation and aid in understanding the biological behaviour of the tumour. To improve treatment outcomes for patients with OSCC, pathologists and clinicians should make it normal procedure to determine the histochemical and immunohistochemical profile and its relationship to the histo-pathological grade and clinical features.

References

1. Warnakulasuriya S. Global epidemiology of oral and oropharyngeal cancer. Oral Oncol. 2009; 45:309-16.
2. Moore MA, Ariyaratne Y, Badar F, et al. Cancer epidemiology in South Asia-past, present and future. Asian Pac J Cancer Prev. 2010;11:49-66.
3. Kalyani R, Das S, Bindra Singh MS, Kumar H. Cancer profile in the Department of Pathology of Sri Devaraj Urs Medical College, Kolar: A ten years study. Indian J Cancer. 2010;47:160-5.
4. Chang YC, Nieh S, Chen SF, Jao SW, Lin YL, Fu E. Invasive pattern grading score designed as an independent prognostic indicator in oral squamous cell carcinoma. Histopathology. 2010; 57:295-303.
5. Bryne M. Prognostic value of various molecular and cellular features in oral squamous cell carcinomas: A Review. J Oral Pathol Med. 1991;20:413-20.
6. Odell EW, Jani P, Sherriff M, et al. The prognostic value of individual histologic grading parameters in small lingual squamous cell carcinomas. The importance of the pattern of invasion. Cancer. 1994;74:789-94.
7. Liu Y, Kulesz-Martin M. p53 regulation and function in normal cells

and tumors. Medicina (B Aires). 2000; 60:9-11.
8. Khanna R, Vidhyarthi AK, Khanna S, Singh S, Singh UC. Expression of p53 protein in leukoplakia and oral squamous cell carcinoma. World J Sur Med Rad Oncol. 2012;1:16.
9. Duraiyan J, Govindarajan R, Kaliyappan K, Palanisamy M. Applications of immunohistochemistry. J Pharm Bioallied Sci. 2012;4:307–3 09.
10. Lavieille JP, Brambilla E, Riva-Lavieille C, Reyt E, Charachon R, Brambilla C. Immunohistochemical detection of p53 protein in preneoplastic lesions and squamous cell carcinoma of the head and neck. Acta Otolaryngol. 1995;115:334-9.
11. Frare JC, Sawazaki-Calone I, Ayroza-Rangel AL, et al. Histopathological grading systems analysis of oral squamous cell carcinomas of young patients. Med Oral Patol Oral Cir Bucal. 2016;21(3):e285-98.
12. Tomazelli KB, Modolo F, Rivero ER. Evaluation of AgNORs in Oral Potentially Malignant Lesions. J Oncol. 2015;2015:218280.
13. Li Y, Zhang J. Expression of mutant p53 in oral squamous cell carcinoma is correlated with the effectiveness of intra-arterial chemotherapy. Oncol Lett. 2015;10(5):2883-7.
14. Humayun S, Prasad VR. Expression of p53 protein and ki-67 antigen in oral premalignant lesions and oral squamous cell carcinomas: An immunohistochemical study. Natl J Maxillofac Surg. 2011;2(1):38-46.
15. Kaur J, Mannan R, Manjari M, Bhasin TS, Sharma S. P53 Expression in oral squamous cell carcinoma as a predictor of high grade malignancy and regional metastasis- an experience from a tertiary care hospital. Indian J Pathol Oncol. 2017;4(4):591-4.
16. Pandya JA, Boaz K, Natrajan S, Manaktala N, Nandita KP, Lewis AJ. A correlation of immunohistochemical expression of TP53 and CDKN1A in oral epithelial dysplasia and oral squamous cell carcinoma. J Can Res Ther. 2018;14:666-70.
17. Kaur J, Mannan R, Manjari M, et al. Can p53 expression and staining intensity correlate with histopathological prognostic parameter and clinical staging in head and neck squamous cell carcinoma. J Pathol Nepal. 2017;7:1141-8.
18. Ray JG, Chattopadhyay A, Caplan DJ. Usefulness of AgNOR counts in diagnosing epithelial dysplasia. J Oral Pathol Med. 2003;32(2):71-6.
19. Gulia SP, Sitaramam E, Reddy PK. The role of silver staining nucleolar organizer regions (AgNORs) in the lesions of the oral cavity. J Clin Diag Res. 2011;5(5):1011-5.
20. Hanemann JA, Miyazawa M, Souza MS. Histological grading and nucleolar organizer regions in oral squamous cell carcinomas. J Appl Oral Sci. 2011;19 (3):280-5.
21. Manu V, Rajaram T, Rai R. Value of silver binding nucleolar organizer regions (AgNOR) in squamous cell carcinomas of upper aero-digestive tract. Med J Armed Forces India. 2006 ;62(2):123-8.
22. Chauhan S, Chauhan B, Joshi DS. AgNORs in squamous cell carcinoma of head and neck. Indian J Applied Basic Med Sci. 2011;13B(17):01-5.
23. Sharma R, Kumar G. Significance of silver binding nucleolar organizer regions in oral squamous cell carcinomas. Int J Sci Study. 2016;3 (12):193-7.
24. Abdulabbas H. S., Abed S. Y., Mahdi Z. A. A., Al-Hindy H. A. A. M., Akram M., Laila U., Zainab R., Al Khafaji N. S., Al-Dahmoshi H. O., & Chabuck Z. A. G. Antiviral effects of medicinal plants: Minireview. Journal of Medical Research and Health Sciences. 2023; 6(2): 2424–2429.